



# Hemiarthroplasty through Direct Anterior Approach for Unstable Femoral Intertrochanteric Fractures in the Elderly: Analysis of Early Cases

Ji-Hun Park, MD, Young-Yool Chung, MD, Sung-Nyun Baek, MD, Tae-Gue Park, MD

*Department of Orthopaedic Surgery, Kwangju Christian Hospital, Gwangju, Korea*

**Purpose:** The purpose of this study was to determine whether the direct anterior approach (DAA) can be applied to hemiarthroplasty for treatment of unstable femoral intertrochanteric fractures in elderly patients.

**Materials and Methods:** We conducted a retrospective review of 34 cases (34 patients) who underwent bipolar hemiarthroplasty using a DAA from February 2019 to April 2020. The mean age of the patients was 82.68 years (range, 67-95 years). A cementless distal fixation hip system was used in all cases. Operation time, total amount of blood loss, intraoperative and postoperative fractures, infections, and reoperations were measured. The patients performed weight-bearing walking as tolerated immediately after surgery. Measurement of migration of the greater trochanter (GT) and progressive subsidence of the femoral stem was performed using follow-up radiographs.

**Results:** The mean operative time was 83.50 minutes (range, 60-120 minutes). The mean amount of bleeding was 263.53 mL (range, 112-464 mL). Walking started a mean of 3.03 days (range, 3-4 days) after surgery. There was no case of progressive migration of the GT more than 5 mm even though it was not fixed. There were no cases of infection, dislocation, or reoperation.

**Conclusion:** Bipolar hemiarthroplasty using the DAA for treatment of unstable femoral intertrochanteric fractures could be considered a useful option that provides many advantages in elderly patients.

**Key Words:** Hip fracture, Hemiarthroplasty, Direct anterior approach

**Submitted:** January 11, 2022 **1st revision:** February 8, 2022  
**2nd revision:** February 14, 2022 **Final acceptance:** February 14, 2022  
**Address reprint request to**

**Young-Yool Chung, MD**

(<https://orcid.org/0000-0002-4959-1230>)

Department of Orthopaedic Surgery, Kwangju Christian Hospital,  
37 Yangrim-ro, Nam-gu, Gwangju 61661, Korea

**TEL:** +82-62-650-5064 **FAX:** +82-62-650-5066

**E-mail:** wonderchung@naver.com

This is an Open Access article distributed under the terms of the Creative Commons Attribution Non-Commercial License (<http://creativecommons.org/licenses/by-nc/4.0>) which permits unrestricted non-commercial use, distribution, and reproduction in any medium, provided the original work is properly cited.

## INTRODUCTION

Femoral intertrochanteric fractures commonly occur in elderly people. These fractures are usually the result of a fall from standing height. Osteoporosis with life-threatening chronic diseases is also common in this population. Osteosynthesis is the preferred treatment of choice. However, a high failure rate (3-16.5%) was reported after osteosynthesis in unstable intertrochanteric fractures<sup>1-5</sup>. Arthroplasty could be considered a surgical option instead of osteosynthesis for treatment of unstable femoral intertrochanteric fractures in elderly patients with chronic medical diseases. The rate of mortality one year after the fracture was 21.6%<sup>6</sup>. Arthroplasty can be helpful to patients by providing relief

from pain, facilitating early rehabilitation, and improving the quality of life<sup>7,8</sup>). Regarding early mobilization after surgery, superior functional outcomes for arthroplasty compared to osteosynthesis have been reported<sup>9</sup>). Use of a less-invasive surgical approach without damage to soft tissue for treatment of elderly patients, could reduce the amount of bleeding and result in earlier initiation of mobilization.

The direct anterior approach (DAA) was introduced as a less invasive surgical approach for use in total hip arthroplasty (THA); it is associated with reduced muscle damage and pain as well as more rapid postoperative recovery<sup>8,10</sup>). With use of this less-invasive surgical approach patients are able to start rehabilitation sooner and avoid medical complications; therefore, its use is more important for elderly patients with hip fractures.

The DAA for bipolar hemiarthroplasty was used for treatment of unstable intertrochanteric fractures in elderly patients and the safety and advantages were estimated according to operation time and early complications.

## MATERIALS AND METHODS

### 1. Materials

This study included 34 patients who underwent bipolar hemiarthroplasty for treatment of unstable femoral intertrochanteric fractures from February 2019 to April 2020 in our hospital. The inclusion criteria were type A2 and A3 in AO classification. The study included 25 female patients and nine male patients. The mean age of the patients was  $82.68 \pm 6.99$  years (range, 67-95 years). The mean body mass index was  $22.86 \pm 1.77$  kg/m<sup>2</sup> (range, 16.87-29.25 kg/m<sup>2</sup>). The mean bone mineral density T-score was  $-3.36 \pm 0.91$  (range,  $-5.9$  to  $-1.6$ ) (Table 1). Four types of classification criteria according to the previous work of Kim et al.<sup>11</sup>) were used for classifying fractures of the greater trochanter (GT). Five cases were type A, 21 cases were type B, five cases were type C, and three cases were type D.

The cementless femoral Wagner SL revision<sup>®</sup> Hip stem (Zimmer, Warsaw, IN, USA) was used in 30 cases and the Wagner Cone Prosthesis<sup>®</sup> Hip stem (Zimmer) was used in four cases. Radiographs were taken regularly in the outpatient department after discharge from the hospital. Cases followed up for a minimum of six months after surgery were included.

### 2. Operative Technique

The patient was placed in the supine position on a special fracture table (Hana<sup>®</sup> Orthopedic Fracture/Trauma Surgical Table; Mizuho OSI, Union City, CA, USA). A skin incision was started 2 cm lateral and 2 cm distal from the anterior superior iliac spine and continued obliquely approximately 15 cm in length over the tensor fascia latae (TFL). The TFL was retracted laterally and the rectus femoris medially. Following cauterization of the lateral femoral circumflex artery, a Cobb elevator was used to elevate fibers of the rectus femoris that were still attached to the anterior capsule. An incision of the superior capsule was made along the femoral head and brought to the intertrochanteric line. A 90° rotated H-shaped (∩) capsulotomy was created as the capsulotomy was taken down the intertrochanteric line toward the GT and lesser trochanter (LT). Double neck cutting was performed for easy removal of the femoral head. Hip joint traction was performed using a fracture table, and the junction of the head and neck was confirmed. Therefore, neck cutting was performed using the anatomically intact femoral head, rather than the LT, as a land mark. The neck cutting level was cut one finger breadth below the head neck junction. The femur elevation hook was placed just distal of the vastus ridge and the proximal femur was elevated into the wound. The leg was rotated externally 90° and then down toward the floor with adduction. A retractor was placed along the calcar and a curved retractor was placed in the bare area on the tip of the GT. Once the GT was comminuted, a curved retractor was placed in the intact bone through

**Table 1.** Demographic Data

Variable	Value
Age (yr)	82.68±6.99 (67 to 95)
Sex	
Male	9 (26.5)
Female	25 (73.5)
Bone mineral density (T-score)	-3.36±0.91 (-5.9 to -1.6)
Body mass index (kg/m <sup>2</sup> )	22.86±1.77 (16.87 to 29.25)
GT classification	
Type A	5 (14.7)
Type B	21 (61.8)
Type C	5 (14.7)
Type D	3 (8.8)

Values are presented as mean ± standard deviation (range) or number (%).

GT: greater trochanter.

the fracture fragments. The femoral canal was identified using a canal finder. Rasping was performed until a stable size was obtained. The trial components were placed and reduced. An image intensifier was used to confirm the fitness of the femoral stem and leg lengths. The definitive cementless femoral stem was inserted and the bipolar cup was mounted and then reduced by leg elevation and internal rotation. The LT and GT were neither reduced nor fixed. Following irrigation of the wound with normal saline, the capsule was closed (Fig. 1). The patient practiced weight-bear using walking aids as tolerated immediately after surgery.

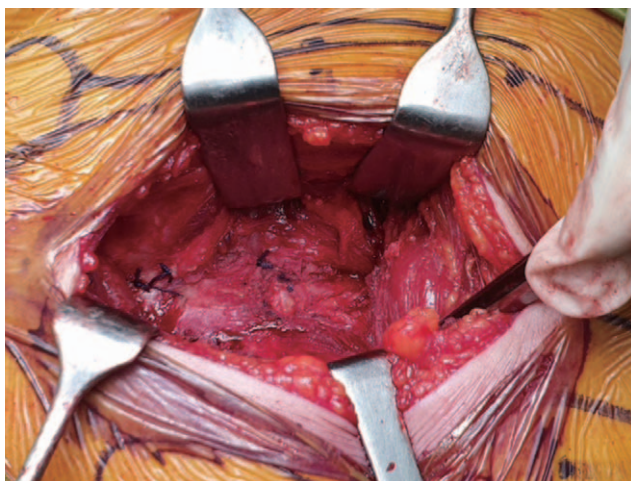


Fig. 1. Intraoperative photograph of capsule repair.

### 3. Methods

The operation time, bleeding amount, time to walk after the operation, and complications were used for evaluation of the clinical results. The operation time was the time from skin incision to closure. The bleeding amount was the total intraoperative bleeding and postoperative collection in a drainage bag. Complications included periprosthetic fractures, infections, dislocations, revisions for any reason, and deaths related to surgery.

Radiographic evaluation of subsidence of the femoral stem and displacement of the GT was performed. The distance from the top of the shoulder of the stem to a horizontal line drawn across the bottom of each teardrop on the follow-up radiograph was measured for evaluation of subsidence of the femoral stem<sup>12)</sup>. Displacement of the fractured fragment of the GT was defined as progressive migration of more than 5 mm on follow-up radiographs.

This research was approved by the Institutional Review Board (IRB) of Kwangju Christian Hospital (IRB No. KCHIRB-M-2021-03-002). Consent for publication, including photographs, was obtained from all patients. Statistical analyses were performed using PASW Statistics (ver. 18.0; IBM, Armonk, NY, USA).

### RESULTS

The mean operation time was 83.50 minutes (range, 70-120 minutes). First, the mean operation time for three early cases was 112 minutes and then was reduced to a mean of

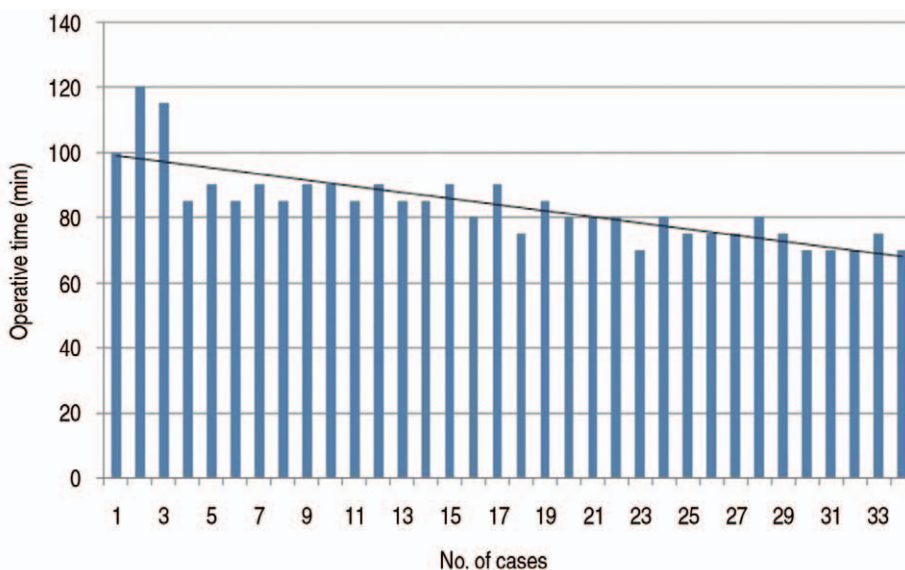


Fig. 2. Distribution of operative time. The mean operation time was 83.50±10.56 minutes.

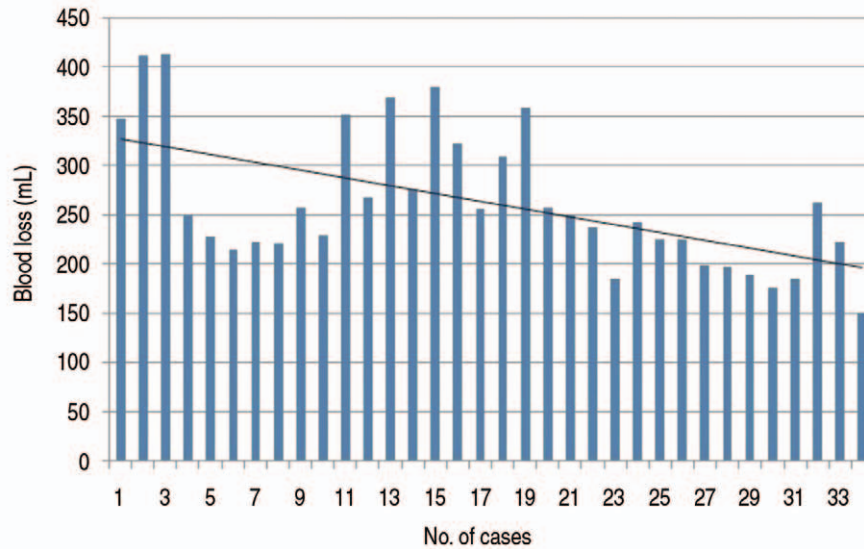


Fig. 3. Distribution of blood loss. The mean blood loss was 263.53±85.80 mL.

Table 2. Clinical and Radiological Assessment

Variable	No. of patients
Operation time (min)	83.50±10.56 (70-120)
Blood loss (mL)	263.53±85.80 (151-414)
Time to start walk (day)	3.03±0.17 (3-4)
Intraoperative or postoperative fractures	0
Infection	0
Dislocation	0
Revision	0
Progressive migration of GT	0
Progressive subsidence of stem	0

Values are presented as mean±standard deviation (range) or number only.

GT: greater trochanter.

81 minutes in 31 cases (Fig. 2). The mean amount of bleeding was 263.53 mL (range, 151-414 mL) (Fig. 3). None of the patients required a blood transfusion after surgery. The patients started walking using walking aids within a mean of 3.03 days (range, 3-4 days) after surgery (Table 2). All patients were discharged from the hospital after stitch out within three weeks.

There were no cases of intraoperative periprosthetic fracture. The mean follow-up period was 3.53 months. On the last follow-up radiographs, displacement of the fracture fragments of the GTs was a mean of 2.15 mm (range, 0-4 mm); 0.6 mm for type A, 1.38 mm for type B, 0.6 mm in for type C, and 3.67 mm for type D. None of the cases had progressive migration more than 5 mm. This study included an analysis of patients who could be followed up for at

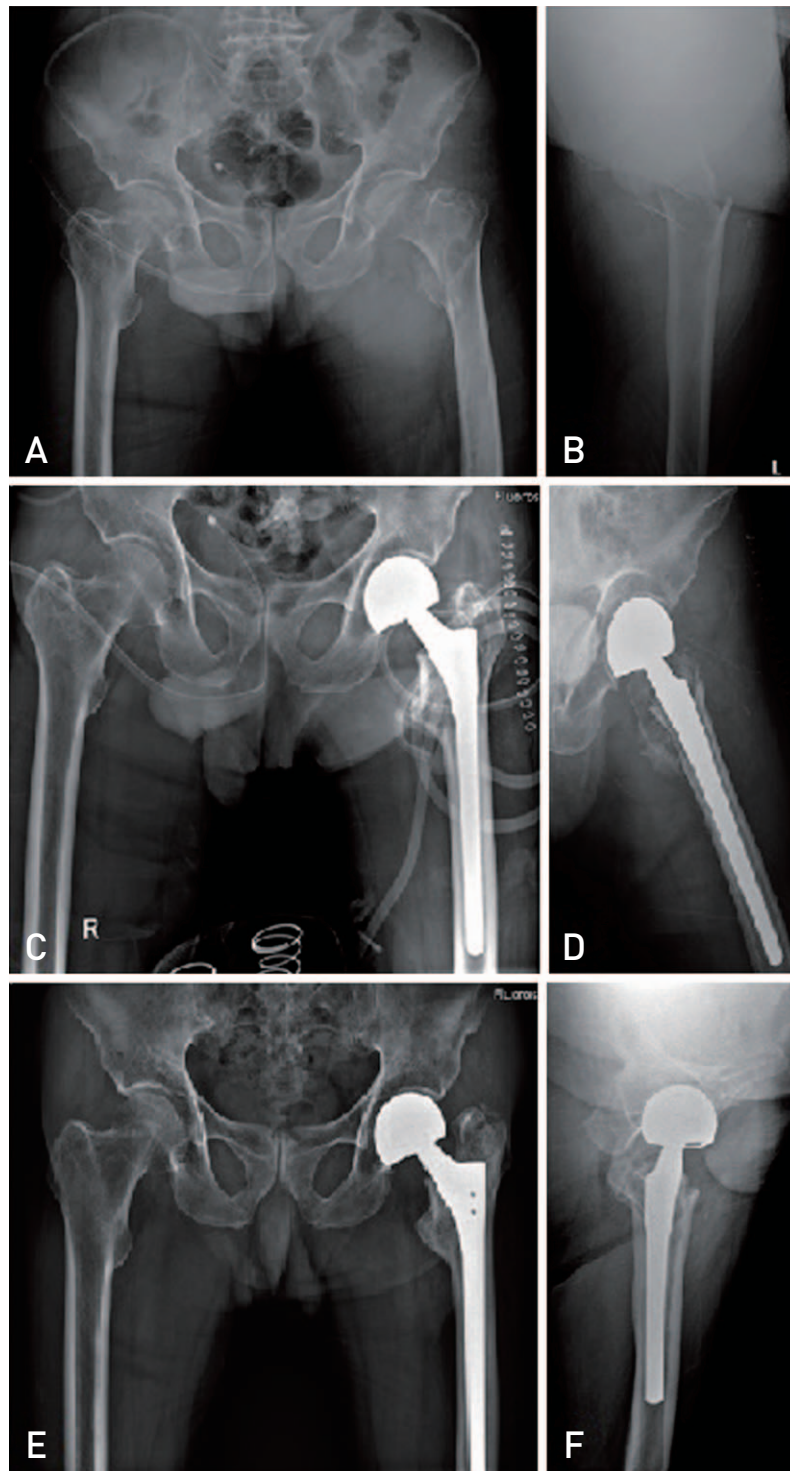
least three months at the outpatient clinic. Progressive migration was defined as a case of stem subsidence or GT displacement of more than 5 mm as observed on a hip anteroposterior X-ray image. There were no cases of infection, dislocation, or reoperation for any reason. None of the patients died during the follow-up period.

## DISCUSSION

The elderly population is increasing in our society and many elderly people have chronic medical diseases. A number of life-threatening complications occur after a hip fracture in these elderly patients. Serious complications from hip fractures in elderly patients could be prevented with early time out of bed and weight-bearing after surgery<sup>13,14</sup>. Because arthroplasty could allow the patients to get out of bed early and perform weight-bearing walking after surgery, we considered it as an option for treatment of unstable intertrochanteric fractures in elderly patients despite the greater soft tissue damage and large amount of bleeding compared to osteosynthesis<sup>15-17</sup>. Although arthroplasty requires a longer operation time and involves more blood loss compared with nailing, with achievement of less damage to soft tissue and shorter operation times, it would be accepted as an alternative surgical option for treatment of intertrochanteric fractures in elderly patients with chronic medical diseases. We used a two-incision minimal invasive approach for treatment of femoral neck fractures in patients with stroke, dementia, and psychogenic disorders. These patients who had muscle weakness had advantages in rehabilitation. All of the patients recov-

ered pre-injury activities after the operation except one<sup>18)</sup>. Using a conventional posterolateral (PL) surgical approach

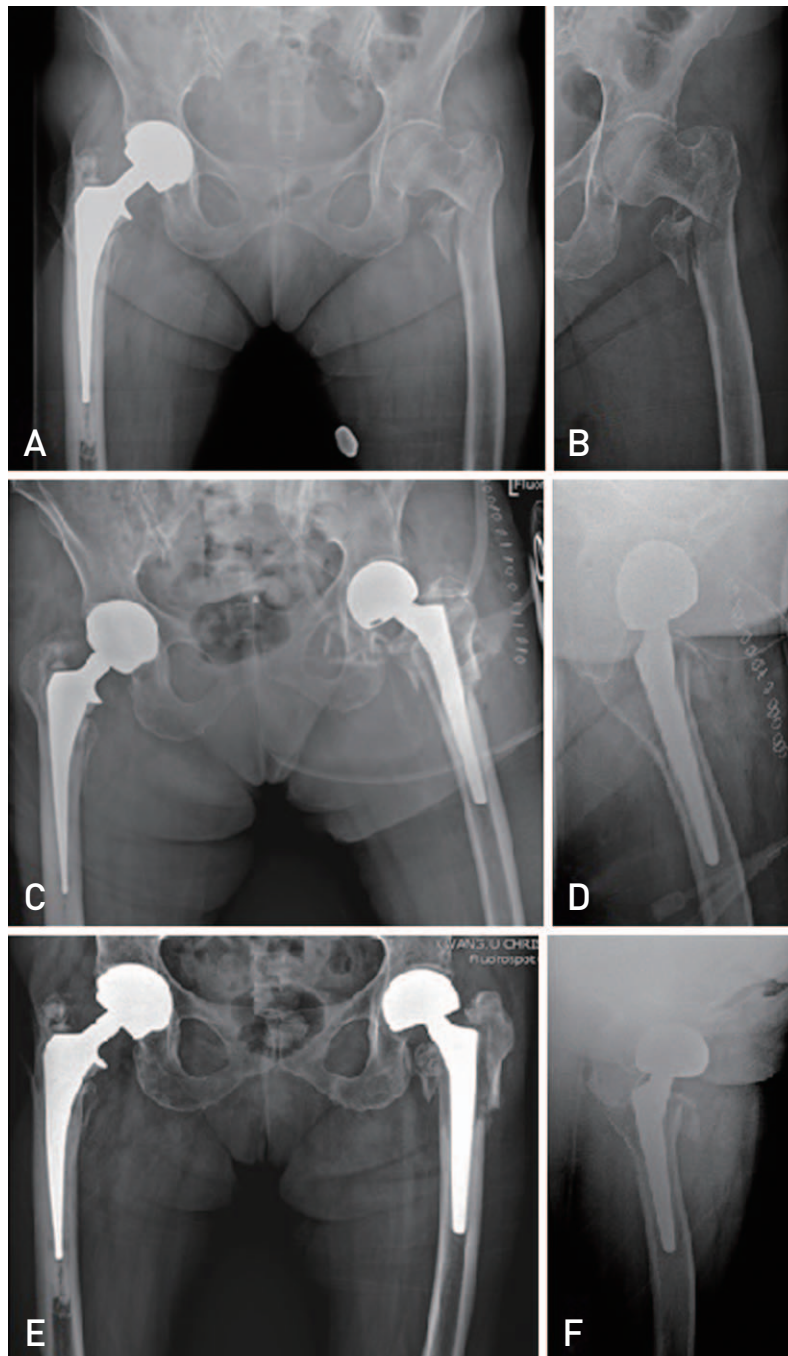
we struggled to minimize muscle and soft tissue damage in hip arthroplasty for treatment of intertrochanteric fractures;



**Fig. 4.** No fragment migrated more than 5 mm on the follow-up radiographs. (A) Greater trochanter classification type B intertrochanteric fracture radiograph anteroposterior (AP), (B) type B lateral radiograph, (C) postoperative AP radiograph, (D) postoperative lateral radiograph, (E) postoperative five months follow-up AP radiograph, and (F) postoperative five months follow-up lateral radiograph.

however, it could not be significantly reduced. Thus, we decided to change the surgical approach to a DAA that is less invasive and less painful, with a faster recovery<sup>8,10</sup>. To the best of our knowledge, this was the first report of arthroplasty through DAA for treatment of unstable intertrochanteric fractures in elderly patients.

In arthroplasty for treatment of intertrochanteric fractures the fracture fragments of the GT are usually fixed with cerclage wiring or a cable system<sup>19</sup>. However there was no need to fix the fracture fragments of the GT in DAA. Additional fixation was not performed on the GT because we thought that dislocation of the GT would not occur due to soft tis-



**Fig. 5.** Greater trochanter (GT) classification type D. (A) GT classification type D intertrochanteric fracture radiograph anteroposterior (AP), (B) type D lateral radiograph, (C) postoperative AP radiograph, (D) postoperative lateral radiograph, (E) postoperative three months follow-up AP radiograph, and (F) postoperative three months follow-up lateral radiograph.

sue fibrosis. In DAA, we did not disturb posterior soft tissues such as the short external rotators, hip abductors, and posterior capsule attached to the GT. This could reduce the operation time and damage to soft tissue. We neither touched nor fixed the fracture fragment, but none migrated more than 5 mm on the follow-up radiographs (Fig. 4). The patient did not complain of pain or limping despite little migration of the GT. The non-fixation of the fractured GT fragment did not appear to affect the clinical results. However, patients with type D fracture fragments of the GT experienced a little pain when walking. Therefore performance of cerclage wiring may be required in patients with type D (Fig. 5).

In our study the mean amount of bleeding was 263.53 mL (range, 151-414 mL). None of the patients required a blood transfusion after surgery. Blood loss was reduced significantly from approximately 700 mL in the previous study reported by Park et al.<sup>20)</sup> in which the conventional PL approach was used for treatment of unstable intertrochanteric fractures in elderly patients. The mean visible blood loss in unstable intertrochanteric fractures treated using intramedullary nails was a 200 mL<sup>21)</sup>. In our study the amount of blood loss was close to that of intramedullary nailing. We thought DAA might have resolved the concerns regarding soft tissue damage and increased blood loss in arthroplasty for treatment of unstable intertrochanteric fractures.

In our study the mean operation time was 83.50 minutes (range, 70-120 minutes). The mean operation time was 112 minutes in the first early three cases and was then reduced to 81 minutes in the later 31 cases. It was longer than that of intramedullary nailing, which was approximately one hour in a multicenter study<sup>22)</sup>. However, as we are familiar with DAA, the operation time from the skin incision to skin closing was reduced to approximately one hour. The results of our study might have demonstrated how DAA could solve the problems of surgeons with regard to longer operation time, and larger bleeding amount in arthroplasty than in osteosynthesis for treatment of unstable intertrochanteric fractures in elderly patients.

This study included no intraoperative or postoperative periprosthetic fractures. Barnett et al.<sup>22)</sup> reported 48 periprosthetic fractures in 5,090 THAs who underwent the procedure early in the surgeon's learning curve. Jewett and Collis<sup>23)</sup> reported 3% periprosthetic fractures in DAA THAs on a fracture table. Identification of the bare area on the tip of the GT and placement of a curved retractor deeply behind the GT and elevation of the proximal femur using a femur elevation hook to avoid periprosthetic fracture is most important. Use of the fracture table designed for DAA would be

helpful in the early learning period for prevention of periprosthetic fracture.

Following removal of the epidural catheter inserted to control pain after surgery, patients began rehabilitation exercises according to the state of their pre-injury activity and were discharged from the hospital within three weeks. There were no cases of infection or reoperation. No deaths related to surgery occurred during the follow-up period.

There were limitations to this study. First, the sample size was too small to support our conclusion. Second, the follow-up duration was relatively short for evaluation of the long-term clinical and radiological results. Conduct of additional studies with larger samples, and a longer follow-up period is needed.

## CONCLUSION

We believe that hemiarthroplasty through DAA could be a safe and reproducible surgical option for treatment of unstable intertrochanteric fractures in elderly patients without increasing the risk of complications.

## CONFLICT OF INTEREST

The authors declare that there is no potential conflict of interest relevant to this article.

## REFERENCES

1. Park BJ, Cho HM, Min WB. *A comparison of internal fixation and bipolar hemiarthroplasty for the treatment of reverse oblique intertrochanteric femoral fractures in elderly patients.* *Hip Pelvis.* 2015;27:152-63.
2. Green S, Moore T, Proano F. *Bipolar prosthetic replacement for the management of unstable intertrochanteric hip fractures in the elderly.* *Clin Orthop Relat Res.* 1987;(224):169-77.
3. Lee YK, Ha YC, Chang BK, Kim KC, Kim TY, Koo KH. *Cementless bipolar hemiarthroplasty using a hydroxyapatite-coated long stem for osteoporotic unstable intertrochanteric fractures.* *J Arthroplasty.* 2011;26:626-32.
4. Davis TR, Sher JL, Horsman A, Simpson M, Porter BB, Checketts RG. *Intertrochanteric femoral fractures. Mechanical failure after internal fixation.* *J Bone Joint Surg Br.* 1990;72:26-31.
5. Haentjens P, Casteleyn PP, Opdecam P. *Hip arthroplasty for failed internal fixation of intertrochanteric and subtrochanteric fractures in the elderly patient.* *Arch Orthop Trauma Surg.* 1994;113:222-7.
6. White BL, Fisher WD, Laurin CA. *Rate of mortality for elderly patients after fracture of the hip in the 1980's.* *J Bone Joint Surg Am.* 1987;69:1335-40.
7. Grimsrud C, Monzon RJ, Richman J, Ries MD. *Cemented*

- hip arthroplasty with a novel cerclage cable technique for unstable intertrochanteric hip fractures. *J Arthroplasty*. 2005;20:337-43.
8. Rachbauer F, Kain MS, Leunig M. The history of the anterior approach to the hip. *Orthop Clin North Am*. 2009;40:311-20.
  9. Yoo JI, Ha YC, Lim JY, Kang H, Yoon BH, Kim H. Early rehabilitation in elderly after arthroplasty versus internal fixation for unstable intertrochanteric fractures of femur: systematic review and meta-analysis. *J Korean Med Sci*. 2017;32:858-67.
  10. Sibia US, Turner TR, MacDonald JH, King PJ. The impact of surgical technique on patient reported outcome measures and early complications after total hip arthroplasty. *J Arthroplasty*. 2017;32:1171-5.
  11. Kim MW, Chung YY, Lim SA, Shim SW. Selecting arthroplasty fixation approach based on greater trochanter fracture type in unstable intertrochanteric fractures. *Hip Pelvis*. 2019;31:144-9.
  12. Malchau H, Kärrholm J, Wang YX, Herberts P. Accuracy of migration analysis in hip arthroplasty. Digitized and conventional radiography, compared to radiostereometry in 51 patients. *Acta Orthop Scand*. 1995;66:418-24.
  13. Hwang DS, Jung HT, Kim SB, Kim JS. Recovery of walking ability after operation for unstable intertrochanteric fractures of the femur in elderly: timing on weight bearing. *J Korean Soc Fract*. 1998;11:296-303.
  14. Ceder L, Thorngren KG, Wallden B. Prognostic indicators and early home rehabilitation in elderly patients with hip fractures. *Clin Orthop Relat Res*. 1980;(152):173-84.
  15. Stern MB, Angerman A. Comminuted intertrochanteric fractures treated with a Leinbach prosthesis. *Clin Orthop Relat Res*. 1987;(218):75-80.
  16. Chan KC, Gill GS. Cemented hemiarthroplasties for elderly patients with intertrochanteric fractures. *Clin Orthop Relat Res*. 2000;(371):206-15.
  17. Kurtz S, Ong K, Lau E, Mowat F, Halpern M. Projections of primary and revision hip and knee arthroplasty in the United States from 2005 to 2030. *J Bone Joint Surg Am*. 2007;89:780-5.
  18. Kim BH, Chung YY, Jun SH, Choi DH. Two-incision bipolar hemiarthroplasty for treating femoral neck fracture: analysis of 15 cases. *J Korean Hip Soc*. 2010;22:203-8.
  19. Hamadouche M, Zniber B, Dumaine V, Kerboull M, Courpied JP. Reattachment of the ununited greater trochanter following total hip arthroplasty. The use of a trochanteric claw plate. *J Bone Joint Surg Am*. 2003;85:1330-7.
  20. Park SE, Kim YY, Jeong JJ, Choi SG, Jeong DS, Kim WY. Comparison of postoperative bleeding and complications between cemented and non-cemented bipolar hemiarthroplasty in treatment of unstable pertrochanteric fracture. *Hip Pelvis*. 2013;25:37-43.
  21. Yoo JH, Kim SM, Jung HJ, Hwang JH. Clinical outcomes of U-blade Gamma3 nails used to treat patients with trochanteric fractures: retrospective multicenter study. *Hip Pelvis*. 2019;31:95-101.
  22. Barnett SL, Peters DJ, Hamilton WG, Ziran NM, Gorab RS, Matta JM. Is the anterior approach safe? Early complication rate associated with 5090 consecutive primary total hip arthroplasty procedures performed using the anterior approach. *J Arthroplasty*. 2016;31:2291-4.
  23. Jewett BA, Collis DK. High complication rate with anterior total hip arthroplasties on a fracture table. *Clin Orthop Relat Res*. 2011;469:503-7.