



The Short-term Outcomes of Physiotherapy for Patients with Acetabular Labral Tears: An Analysis according to Severity of Injury in Magnetic Resonance Imaging

Makoto Kawai, PT, MSc^{*,†}, Kenji Tateda, MD, PhD[†], Yuma Ikeda, PT, MSc^{*},
Ima Kosukegawa, MD, PhD[†], Satoshi Nagoya, MD, PhD[‡], Masaki Katayose, PT, PhD^{*,†}

Department of Rehabilitation, Sapporo Medical University Hospital, Sapporo, Japan^{}*

Second Division of Physical Therapy, School of Health Sciences, Sapporo Medical University, Sapporo, Japan[†]

Department of Orthopaedic Surgery, Sapporo Medical University School of Medicine, Sapporo, Japan[‡]

Department of Musculoskeletal Biomechanics and Surgical Development, Sapporo Medical University, Sapporo, Japan[§]

Purpose: The aim of this study was to evaluate the short-term outcome of physiotherapy in patients with acetabular labral tears and to assess the effectiveness of physiotherapy according to the severity of the labral tear.

Materials and Methods: Thirty-five patients who underwent physiotherapy for treatment of symptomatic acetabular labral tears were enrolled. We evaluated the severity of the acetabular labral tears, which were classified based on the Czerny classification system using 3-T MRI. Clinical findings of microinstability and extra-articular pathologies of the hip joint were also examined. The International Hip Outcome Tool 12 (iHOT12) was used for evaluation of outcome scores pre- and post-intervention.

Results: The mean iHOT12 score showed significant improvement from 44.0 to 73.6 in 4.7 months. Compared with pre-intervention scores, significantly higher post-intervention iHOT12 scores were observed for Czerny stages I and II tears (all $P < 0.01$). However, no significant difference was observed between pre-intervention and post-intervention iHOT12 scores for stage III tears ($P = 0.061$). In addition, seven patients (20.0%) had positive microinstability findings and 22 patients (62.9%) had findings of extra-articular pathologies. Of the 35 patients, eight patients (22.9%) underwent surgical treatment after failure of conservative management; four of these patients had Czerny stage III tears.

Conclusion: The iHOT12 score of patients with acetabular labral tears was significantly improved by physiotherapy in the short-term period. Improvement of the clinical score by physiotherapy may be poor in patients with severe acetabular labral tears. Determining the severity of acetabular labral tears can be useful in determining treatment strategies.

Key Words: Hip joint, Femoroacetabular impingement, Physical therapy modalities, Conservative treatment, Magnetic resonance imaging

Submitted: March 19, 2021 1st revision: June 2, 2021
2nd revision: June 21, 2021 Final acceptance: June 25, 2021

Address reprint request to

Makoto Kawai, PT, MSc

(<https://orcid.org/0000-0002-2372-9932>)

Department of Rehabilitation, Sapporo Medical University Hospital,
16-291, Minami1-jonishi, Chuo-ku, Sapporo 060-8543, Japan

TEL: +81-11-611-2111 FAX: +81-11-621-8059

E-mail: mkt1031pc@yahoo.co.jp

This is an Open Access article distributed under the terms of the Creative Commons Attribution Non-Commercial License (<http://creativecommons.org/licenses/by-nc/4.0>) which permits unrestricted non-commercial use, distribution, and reproduction in any medium, provided the original work is properly cited.

INTRODUCTION

The hip acetabular labrum contributes to the stability of the hip joint by deepening the cover of the acetabulum and providing a sealing effect¹. Abnormal bone morphology, such as femoroacetabular impingement (FAI) or acetabular dysplasia, and hip joint dysfunction are factors that increase the load on the acetabular labrum². Inguinal pain and joint instability may be caused by damage to the acetabular labrum^{3,4}.

Recently, use of arthroscopic labral repair has become common, and many facilities have reported excellent outcomes^{5,6}. However, regarding conservative therapy, no consensus has been reached on the usefulness of physiotherapy for treatment of acetabular labral tears. Previous studies reported that physiotherapy can improve clinical symptoms^{7,8}, although it has been reported that outcome scores of conservative treatments showed no difference from or were significantly lower than those for arthroscopic surgery^{9,10}.

Inguinal pain can be caused by many tissues around the hip joints¹¹, and there may be coexistence of multiple pathologies¹². In addition, abnormal bone morphologies, such as pincer and cam deformity, have been reported in asymptomatic individuals¹³. Nonetheless, in previous studies referring to conservative therapy for acetabular labral tear, diagnosis was based on bone morphology, and the assessment of damaged tissue was insufficient.

The purpose of the current study was to investigate the short-term clinical outcome of physiotherapy in patients with acetabular labral tears confirmed by magnetic resonance imaging (MRI). In addition, the effectiveness of physiotherapy was evaluated according to the severity of the acetabular labral tear.

MATERIALS AND METHODS

1. Participants and Search Procedure

The study was approved by the Institutional Review Board (IRB) of Sapporo Medical University Hospital (No. 282-215), and the informed consent was waived by the IRB. The records of 107 patients who underwent physiotherapy for treatment of hip pain in Sapporo Medical University Hospital from August 2013 to July 2018 were reviewed retrospectively. Of these patients, those diagnosed with acetabular labral tear were included in this study. The inclusion criteria were as follows: symptomatic patients with acetabu-

lar labral tears confirmed by 3-T MRI, a positive anterior impingement test (AIT), and patients who underwent physiotherapy for >2 months. A total of 72 patients were excluded due to osteoarthritis (Tönnis grade ≥ 2), developmental dysplasia of the hip, spinal disease, hip dislocation, tumor, injury from traffic trauma, femoral head necrosis, septic arthritis of the pubic symphysis, rheumatoid arthritis, juvenile idiopathic arthritis, tuberculous arthritis, intervention period <2 months, lack of MRI evaluation, and lack of follow-up (Fig. 1). The study population included 13 male patients and 22 female patients with a mean age of 43.0 years (range, 11-72 years). The mean follow-up period was 4.7 months (range, 2-9 months), and the mean number of physiotherapy sessions per month was 3.3 (range, 1.7-7.7). The demographic data of patients are shown in Table 1.

2. Clinical Evaluation and Imaging

The International Hip Outcome Tool 12 (iHOT12) score was obtained at the first (pre-intervention) and final (post-intervention) treatments. The iHOT12, a 12-item patient-reported measure (Table 2), utilizes a visual analog scale format in order to be intuitive for the examinees¹⁴. A prone external rotation test and a traction test were performed to assess the microinstability of the hip joint (Fig. 2). The prone external rotation test was performed with the patient in a prone position and the affected hip in maximal external rotation; then, the greater trochanter was pushed anteriorly by the examiner to translate the femoral head¹⁵. The traction test is the method preferred by the senior author for detecting inferior laxity of the hip joint. The association between hip joint distraction by axial traction and microinstability has been previously reported¹⁶. This test was performed by pulling the patient's lower limb to separate the femoral head from the acetabulum. If the patient felt apprehension, the test finding was considered positive. Extra-articular pathologies, including adductor-, iliopsoas-, inguinal-, and pubic-related groin pain, were also evaluated according to the diagnostic criteria of the Doha agreement¹¹. Anterior inferior iliac spinitis (AIISpinitis), recently reported by Kaya¹⁷, is tendinitis of the direct head of the rectus femoris muscle and is considered an extra-articular inflammatory pathology. A diagnosis of AIISpinitis was suspected in patients with anterior hip pain according to Patrick's test and tenderness at Scarpa's triangle. All radiographs and MRIs were assessed by a hip surgeon. The patients were diagnosed with acetabular dysplasia if the lateral center-edge angle (LCEA) was $<20^\circ$ or with borderline dysplasia if the LCEA was between

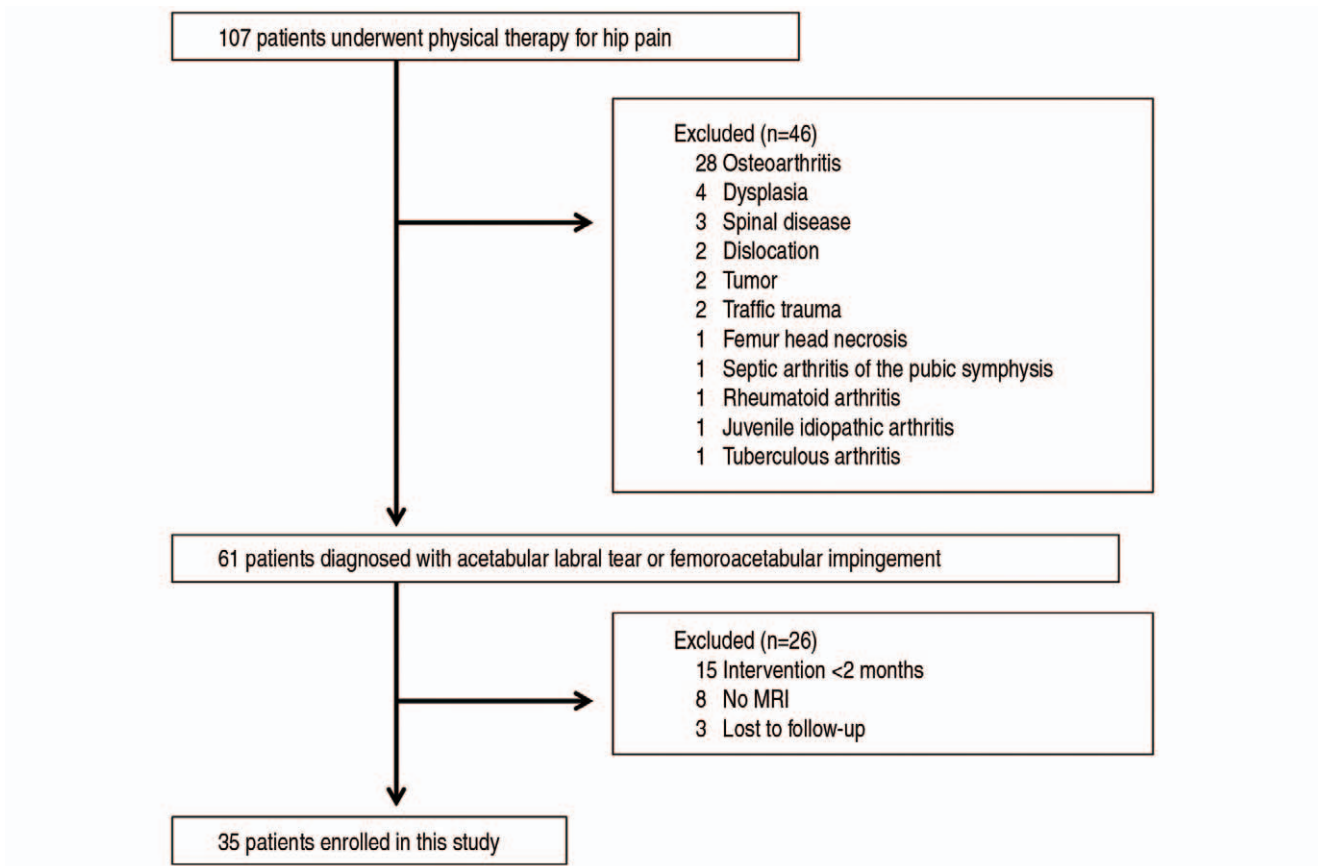


Fig. 1. Flowchart of the recruitment of patients with acetabular labral tear or femoroacetabular impingement in this study.

Table 1. Patient Information

Variable	Stage of Czerny classification			Total	P-value
	I	II	III		
No. of patients	9	16	10	35	-
Age (yr)	33.0±18.0	42.6±18.7	49.8±10.7	43.0±17.3	0.093
Sex	Male	6	4	13	-
	Female	6	10	22	-
Height (cm)	162.7±9.8	161.1±6.0	163.7±8.7	162.4±7.6	0.670
Weight (kg)	57.9±11.6	57.7±9.9	62.9±16.2	59.2±12.2	0.903
Body mass index (kg/m ²)	21.6±2.4	22.2±3.4	23.2±4.1	22.3±3.3	0.695
Radiological diagnoses	Pincer-type FAI	3	3	7	-
	Cam-type FAI	1	5	7	-
	Mixed-type FAI	2	3	6	-
	Borderline Dysplasia	2	4	8	-
	Normal	3	1	3	7

Values are presented as number only or mean±standard deviation. FAI: femoroacetabular impingement.

20° and 25°. The radiographic FAI subtypes were classified as cam, pincer, or combined (Fig. 3). Cam type was defined as head/neck offset ratio <0.14, deformity of pistol grip, or herniation pit, in addition to an alpha angle >55° on any radi-

ograph, computed tomography image, or MRI. Pincer type was defined as LCEA ≥40°, LCEA ≥30° and acetabular roof obliquity ≤0°, or LCEA ≥25° and a positive crossover sign. Evaluation of the severity of the acetabular labral tear

Table 2. The Original Questions of International Hip Outcome Tool 12

Q1	Overall, how much pain do you have in your hip/groin?
Q2	How difficult is it for you to get up and down off the floor/ground?
Q3	How difficult is it for you to walk long distances?
Q4	How much trouble do you have with grinding, catching, or clicking in your hip?
Q5	How much trouble do you have pushing, pulling, lifting, or carrying heavy objects at work?
Q6	How concerned are you about cutting/changing directions during your sport or recreational activities?
Q7	How much pain do you experience in your hip after activity?
Q8	How concerned are you about picking up or carrying children because of your hip?
Q9	How much trouble do you have with sexual activity because of your hip?
Q10	How much of the time are you aware of the disability in your hip?
Q11	How concerned are you about your ability to maintain your desired fitness level?
Q12	How much of a distraction is your hip problem?

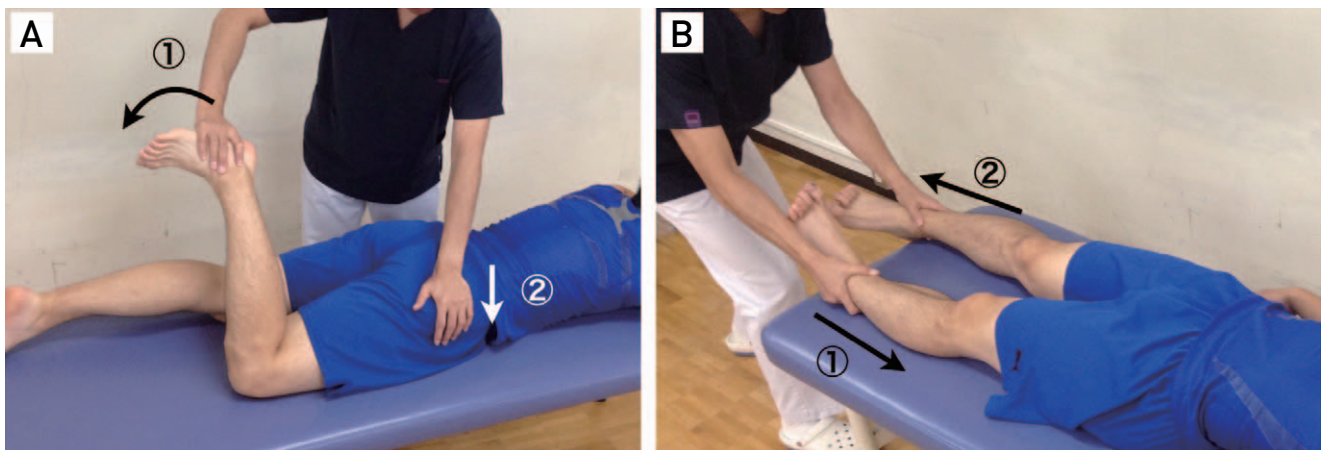


Fig. 2. (A) The prone external rotation test was performed with the patient in a prone position and the affected hip in maximal external rotation (①); then, the examiner pushed the greater trochanter anteriorly to translate the femoral head (②). (B) The traction test was conducted by pushed the unaffected lower limb for stabilize the pelvis (①), then, pulling the affected lower limb to separate the femoral head from the acetabulum (②).

was also based on the Czerny classification from 3-T MRI radial or coronal slice images. The Czerny classification was based on the presence or absence of intrasubstance degeneration, tear, and detachment¹⁸⁾, which were categorized as follows: stage I, intrasubstance degeneration; stage II, labral tear; and stage III, labral detachment (Fig. 4). In this study, the Czerny classification was stage I in 9 patients, II in 16 patients, and III in 10 patients (Table 1). The radiological diagnoses were FAI in 20 patients (pincer, 7; cam, 7; mixed, 6), borderline dysplasia in 8 patients, and normal in 7 patients.

3. Conservative Treatment

The conservative treatment used in this study included physiotherapy, patient education based on activity modification, and the use of nonsteroidal anti-inflammatory drugs (NSAIDs). Prior to the beginning of the intervention, six

patients discontinued sports activities because of groin pain, and three patients continued sports activities despite groin pain. During the intervention period, patients were instructed to refrain from activities of daily living and sports activities that caused groin pain. NSAIDs were used by seven patients when the pain was severe. A physiotherapy plan was established according to the patient's symptoms and physiological findings, including mobility restriction and loss of stability. Muscle stretching and joint mobilization associated with the hip, pelvic girdle, and lumbar spine was performed for improvement of mobility (Fig. 5). Exercises that improved hip joint and trunk muscle strength, coordination, and movement stabilization were recommended for improvement of stability (Fig. 6). If the microinstability test was positive, acquisition of femoral head centripetal position was performed for the acetabulum. This was achieved by activation of the iliopsoas and rotator muscles (Fig. 7).

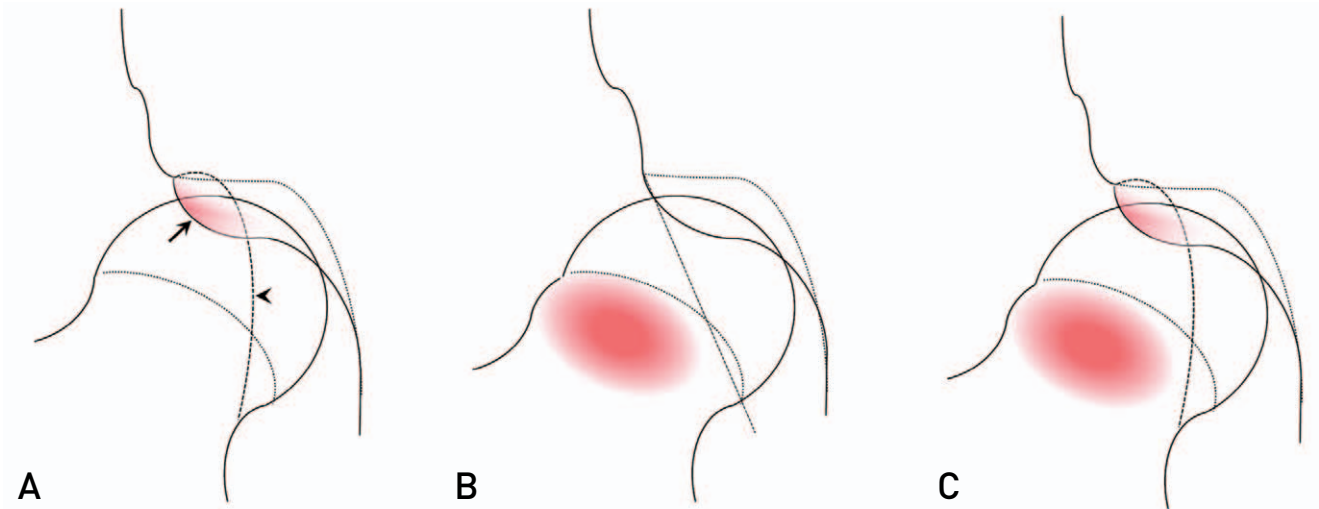


Fig. 3. The femoroacetabular impingement subtypes. **(A)** Pincer type was characterized by excessive acetabular over-coverage and acetabular retroversion. The crossover sign describes the appearance of the anterior acetabular wall lying anterior to the posterior acetabular wall in the superior portion of the joint, on a frontal pelvic radiograph. A line drawn down the anterior wall (arrow) will intersect with a line drawn along the posterior wall (arrowhead). **(B)** Cam type was characterized by aspherical portion of femoral head-neck junction. **(C)** Mixed type was characterized by combination of pincer type and cam type.

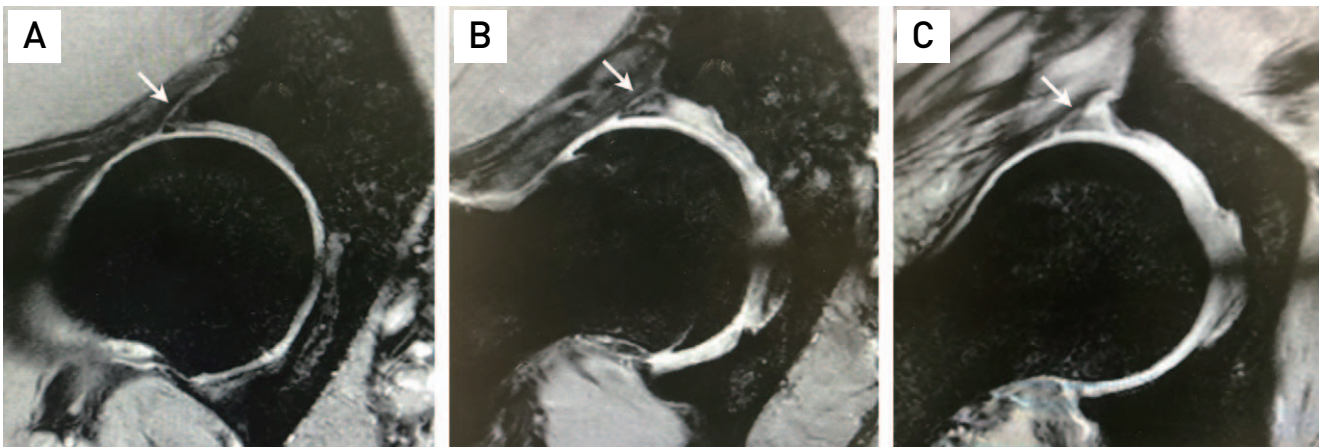


Fig. 4. Radial T2 star-weighted images demonstrates representative Czerny classification cases (arrows). Czerny stage I **(A)**, II **(B)**, and III **(C)**.

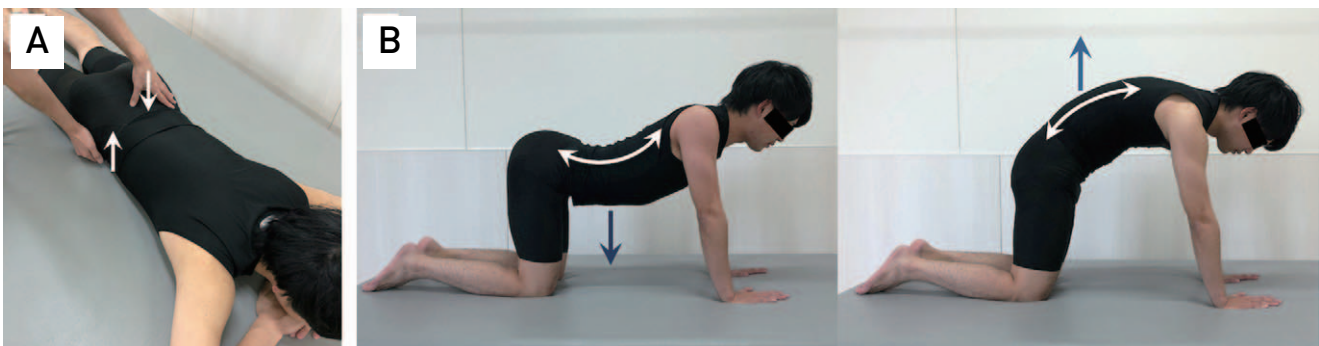


Fig. 5. Mobilization exercises of the sacroiliac joint **(A)** and lumbar spine **(B)**.

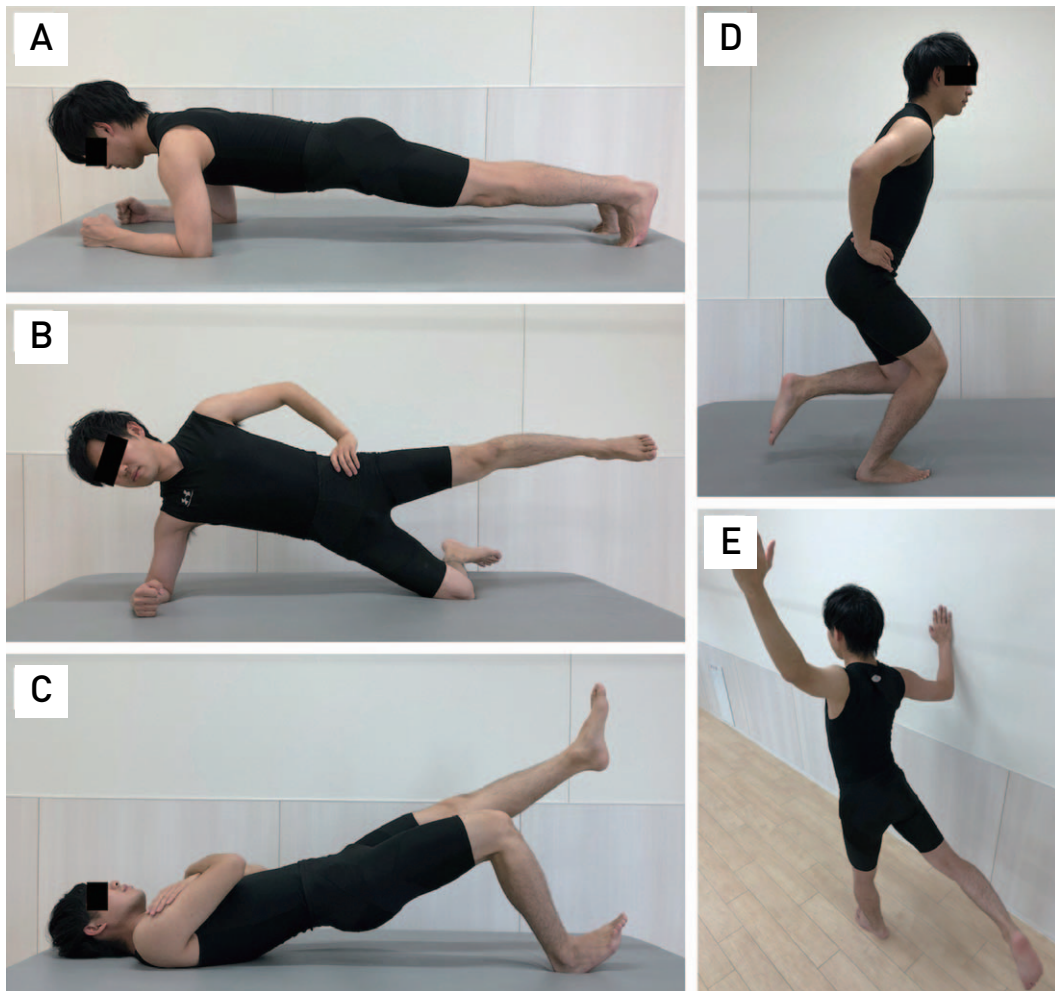


Fig. 6. Stabilization exercises of the trunk and hip joint muscles (A-C), the single leg squat (D), and the cross-motion exercise (E).

Rehabilitation was provided once or twice a week by three physiotherapists.

4. Statistical Analyses

All data are presented as means and standard deviations. Kruskal–Wallis tests were used for evaluation of differences in patients' pre-intervention parameters. A Wilcoxon signed-rank test was used for comparison of the pre-intervention iHOT12 scores with the post-intervention iHOT12 scores for each Czerny classification stage and bony deformity type. Age, body mass index, follow-up duration, and number of physiotherapy sessions per month were also compared between patients who only underwent physiotherapy (non-surgical group) and those who underwent surgery after physiotherapy intervention (surgical group). The level of significance was set at $P < 0.05$. Statistical analyses were performed using JMP (ver. 14.0.0; SAS Institute, Cary, NC,

USA).

RESULTS

1. Short-term Outcome of Physiotherapy

With physiotherapy, the mean iHOT12 score of the 35 patients with acetabular labral tears showed significant improvement from 44.0 to 73.6 ($P < 0.001$) in 4.7 months. Of these 35 patients, eight patients (22.9%) underwent surgical treatment after failure of conservative therapy. No significant differences in age, body mass index, follow-up duration, or number of physiotherapy sessions per month were observed between the non-surgical and surgical groups (Table 3). The mean iHOT12 score in the non-surgical group showed significant improvement from 45.4 to 80.6 ($P < 0.001$). The scores in the surgical group increased from 39.5 to 50.3; however, this improvement was not signifi-

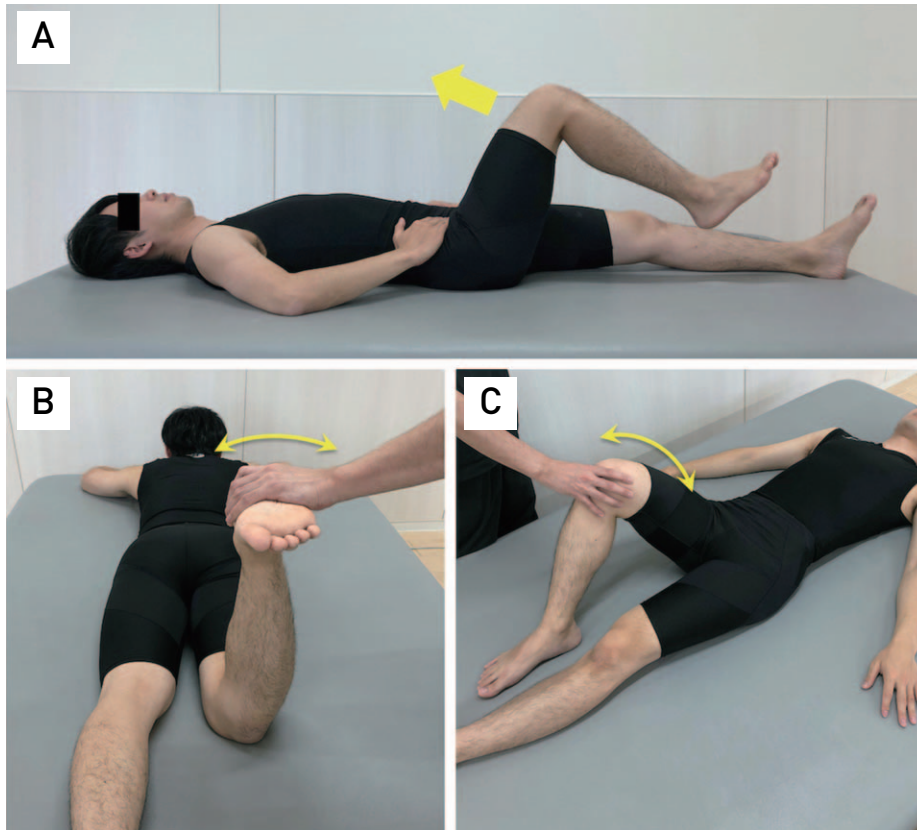


Fig. 7. Exercises to increase the centripetal of the femoral head to the acetabulum. The iliopsoas muscle training (A) and rotator muscle training (B, C).

Table 3. Characteristics of the Patients in the Non-surgical Group and the Surgical Group

Variable	Non-surgical group	Surgical group	P-value
No. of patients	27	8	
Age (yr)	42.7±17.9	40.4±16.0	0.568
Body mass index (kg/m ²)	21.9±3.2	23.7±3.8	0.356
Follow-up period (mo)	4.8±2.2	4.5±1.8	0.843
No. of physiotherapy sessions per month	3.1±1.1	4.3±1.9	0.054
iHOT12 Pre	45.4±22.6	39.5±11.5	0.387
iHOT12 Post	80.6±17.6	50.3±20.6	0.002

Values are presented as number only or mean±standard deviation.
iHOT12: International Hip Outcome Tool 12.

cant ($P=0.110$). Significantly lower post-intervention iHOT12 scores were observed for the surgical group compared with those of the non-surgical group ($P=0.002$).

2. Effectiveness of Physiotherapy according to Labral Tear Severity

The clinical findings for each stage of the Czerny classification are shown in Table 4. Of the 35 patients, seven patients (20.0%) had positive microinstability tests. Of these, four

patients had Czerny stage III. Twenty-two patients (62.9%) had findings of extra-articular pathologies. Tenderness and resisted pain around the hip joint, classified based on the Doha agreement, were detected in seven patients (20.0%). In addition, 12 patients (34.3%) had AIISpinitis. The mean iHOT12 scores according to each Czerny classification stage and bony deformity type are shown in Table 5. Significantly higher post-intervention iHOT12 scores compared with pre-intervention scores were observed for Czerny stages I ($P=0.004$) and II tears ($P<0.001$). However, no significant

Table 4. Patient Clinical Findings and Czerny Classifications

Clinical findings	Stage of Czerny classification			Total (n)
	I	II	III	
Microinstability	1	2	4	7
Iliopsoas-related lesions	2	3	-	5
Inguinal-related lesions	1	-	-	1
Pubic-related lesions	-	1	-	1
AllSpinitis	4	7	1	12
Others: Iliopsoas snapping	-	2	-	2
Tenderness and motion pain in the sacroiliac joint	1	-	-	1
Tenderness and resisted pain in muscles (quadriceps, hamstrings, sartorius, and gluteus minimus muscles)	-	3	2	5
Tenderness in the greater trochanter and pain during hip abduction	-	1	-	1

AllSpinitis: anterior inferior iliac spinitis.

Table 5. Pre-intervention and Post-intervention iHOT12 Scores according to the Czerny Classification Stage and Bony Deformity Type

Czerny classification stage and bony deformity type	iHOT12		P-value
	Pre	Post	
Total	44.0±20.6	73.6±22.1	<0.001
Czerny classification stage			
I	51.0±25.7	74.4±20.5	0.004
II	44.8±18.7	81.2±15.8	<0.001
III	36.6±18.1	60.8±28.0	0.061
Bony deformity type			
Pincer-type FAI	52.9±16.6	81.4±20.8	0.031
Cam-type FAI	46.0±23.7	74.7±16.9	0.016
Mixed-type FAI	33.5±16.0	70.0±26.0	0.031
Borderline dysplasia	37.4±15.8	75.6±25.3	0.016
Normal	49.9±27.6	65.1±24.6	0.031

Values are presented as mean±standard deviation.

iHOT12: International Hip Outcome Tool 12, FAI: femoroacetabular impingement.

Table 6. Characteristics of the Patients Who Underwent Surgical Treatment

Case No.	Age (yr)	BMI (kg/m ²)	iHOT12		Bony deformity	Stages of Czerny classification	Clinical findings
			Pre	Post			
1	16	23.4	25	29	Mixed	I	Sacroiliac joint pain Iliopsoas-related lesions AllSpinitis
2	18	24.3	48	50	Mixed	II	
3	35	21.9	35	58	Borderline dysplasia	II	Microinstability
4	42	21.2	59	67	Normal	II	
5	50	22.2	39	58	Normal	III	Microinstability Microinstability
6	51	18.8	40	36	Pincer	III	
7	55	25.9	45	83	Pincer	III	Microinstability Microinstability
8	56	31.6	25	21	Borderline dysplasia	III	

BMI: body mass index, iHOT12: International Hip Outcome Tool 12, AllSpinitis: anterior inferior iliac spinitis.

difference was observed between the pre-intervention and post-intervention iHOT12 scores for Czerny stage III tears ($P=0.061$). In contrast, significantly higher post-intervention iHOT12 scores compared with pre-intervention iHOT12 scores were observed for all bony deformity types. Of the eight patients who underwent surgery, four patients (50.0%) had Czerny classification stage III tears (Table 6). Patients in cases 1 and 2 underwent surgical treatment because they had severe extra-articular symptoms. Half of the patients with Czerny stage II and III tears who underwent surgery had microinstability.

DISCUSSION

To the best of our knowledge, this is the first study to examine the short-term outcome of physiotherapy in patients with acetabular labral tears. Two major findings were demonstrated in our study. First, when considering the entire cohort of patients with acetabular labral tears, the iHOT12 score improved significantly by physiotherapy. Second, when the severity of the tear was considered, there was no significant improvement of the iHOT12 score of patients with severe acetabular labral tears.

In recent years, several studies have reported on conservative treatment for patients with acetabular labral tears and FAI^{7,8}. However, in most studies the diagnostic accuracy of acetabular labral tear was relatively low because the diagnosis of labral tear was only dependent on bone morphology and the AIT. Pennock et al.⁸ reported the results of conservative treatment for symptomatic FAI patients; when MRI was performed in 55% of the patients, 22% had no acetabular labral tears. In this study, all patients were evaluated by 3-T MRI, so that the acetabular labral tear was effectively visualized and confirmed¹⁹.

Several randomized controlled trials on conservative treatment for FAI patients have recently been reported. Griffin et al.⁹ reported that the iHOT33 scores were significantly improved by conservative treatment, although the post-intervention iHOT33 score was only 49.7. Mansell et al.¹⁰ also reported that the iHOT33 score was significantly improved by conservative treatment, but the final iHOT33 score was only 43.9. In these two studies the clinical scores were obviously lower than the score in the current study, which may be due to differences in the frequency of physiotherapy. The number of physiotherapy sessions per month was 3.3 ± 1.4 in the current study, and Griffin et al.⁹ reported between six and 10 rehabilitation sessions over 12-24 weeks. In addition, it is possible that the cause of hip pain was mis-

understood, and there may have been differences in the overall concept of physiotherapy. In this study, all patients had acetabular labral tears. Positive signs in the microinstability tests were observed for four (40.0%) of the 10 patients with Czerny stage III tears. In an in vitro study, Smith et al.⁴ measured the strain on the anterior and anterior-superior labrum when a compression load and anterior translation were applied to the acetabulum through the femoral head. There was no significant change in strain with a 1-cm circumferential tear of acetabular labral compared with that in intact condition; however, the strain was significantly higher when there was a 2-cm circumferential tear. These findings suggest that the load on the acetabular labrum changes depending on the severity of the acetabular labral tear, and it may cause apprehension during the microinstability tests. Therefore, we established a therapy plan for improvement of joint stability and the clinical outcome of patients with acetabular labral tears. However, a significantly poor clinical outcome was observed for patients with Czerny stage III tears, and they may be poor candidates for physiotherapy. Rankin et al.¹² reported high rates of coexisting extra-articular lesions in patients with hip joint pathology. In the current study, 22 (62.9%) of the 35 patients had extra-articular pathologies, and physiotherapy was performed according to the patients' symptoms. Kaya¹⁷ reported that extra-articular debridement could provide pain relief for the hip when it has not undergone labral repair. Physiotherapy outcomes for acetabular labral tears may be further improved by paying close attention to the external articular pathology. Because the pathogenesis of hip joint pain varies, determining the damaged tissue in relation to the symptoms and verifying the effects of treatment is important.

In the current study, significantly improved clinical outcomes were observed in patients with all bony deformity types. Although no study to date has examined the outcome of conservative therapy according to differences in bone morphology, we believe that bone morphology does not have a considerable effect on the outcome of physiotherapy. In addition, this result showed no association between age and clinical outcome. Relation between age and poor outcome factor of surgical treatment has been reported, while one study reported good results even in elderly patients if there was no cartilage damage²⁰. In this study, cartilage damage was not clearly observed by MRI in any case. If there is no cartilage damage, results of physiotherapy might not be related to age.

In previous studies, 8% or 70% of the patients who underwent conservative treatment eventually underwent arthro-

scopic surgery^{9,10}), although the reasons were not evaluated. In this study, the duration and frequency of intervention may not have affected the outcomes of physiotherapy. Four of the eight patients in the surgical group had severe acetabular labral tears. In addition, associated microinstability was observed in some patients with severe acetabular labral tears, which may be a limitation for conservative treatment and may thus be an indication for arthroscopic surgery. In the future, conduct of studies to examine these effects by increasing the number of patients with acetabular labral tears is needed.

This study had a few limitations. The 3-T MRI that we used is effective for visualization of acetabular labral tears. However, in previous studies, the sensitivity and specificity of 3-T MRI was 61% to 100% and 50% to 100%, respectively^{19,21,22}). Therefore, a normal labral sulcus may have been mistaken for a lesion. This is considered a weakness in this study. It is unknown whether the main cause of hip joint pain in patients of the current study was acetabular labral tear. In all patients, acetabular labral tear was confirmed by MRI, and AIT was also positive, but identification of the etiology was insufficient. The findings of extra-articular pathologies were detected in 63% of patients. However, in Czerny stage III, there were few patients who had recognized clinical findings of extra-articular, and it was inferred that acetabular labral tear was the main cause. In the future, the effect of intraarticular injection should be added to the inclusion criteria and the possibility that the main cause is intraarticular tissues should be increased. In addition, determining the main cause associated with pain relief is difficult. Many diseases of the hip joint usually respond to conservative treatment. Therefore, establishment of a control group in which labral tear is recognized by MRI is important, and we would like to conduct a prospective study in the future. A small number of patients were included in the current study, and the follow-up duration was short. Conduct of a study including a larger number of patients is necessary to improve the accuracy of the results. To confirm the effectiveness of physiotherapy for acetabular labral tears, long-term observation of disease recurrence, deterioration of the acetabular labrum tear, and degenerative changes in the hip joint will be necessary. Because the current study was retrospective, it will be developed into a prospective study in the future.

CONCLUSION

The iHOT12 score of patients with acetabular labral tears was significantly improved by physiotherapy. However,

improvement of symptoms was poor with physiotherapy in patients with severe acetabular labral tears, and many such patients had to undergo surgery. Our findings support the hypothesis that the severity of acetabular labral tears is an important factor affecting treatment outcomes, and thus, determining the severity of injury may be useful in determining appropriate treatment strategies.

ACKNOWLEDGEMENTS

This study was supported by a grant from the Japan Society for the Promotion of Science (grant No. 20K19380).

We are grateful for support from Mitsunori Kaya, PhD, on supporting the diagnosis and Ryosuke Motomura, PT, on performing functional evaluations and physiotherapy for patients.

CONFLICT OF INTEREST

S.N. belongs to the endowed institutes of Zimmer Biomet and Smith & Nephew. The other authors declare that there is no potential conflict of interest relevant to this article.

REFERENCES

1. Ferguson SJ, Bryant JT, Ganz R, Ito K. *An in vitro investigation of the acetabular labral seal in hip joint mechanics. J Biomech.* 2003;36:171-8.
2. Nepple JJ, Carlisle JC, Nunley RM, Clohisey JC. *Clinical and radiographic predictors of intra-articular hip disease in arthroscopy. Am J Sports Med.* 2011;39:296-303.
3. Burnett RS, Della Rocca GJ, Prather H, Curry M, Maloney WJ, Clohisey JC. *Clinical presentation of patients with tears of the acetabular labrum. J Bone Joint Surg Am.* 2006;88:1448-57.
4. Smith MV, Panchal HB, Ruberte Thiele RA, Sekiya JK. *Effect of acetabular labrum tears on hip stability and labral strain in a joint compression model. Am J Sports Med.* 2011;39 Suppl:103S-10S.
5. Jo S, Lee SH, Wang SI, Smith B, O'Donnell J. *The role of arthroscopy in the dysplastic hip—a systematic review of the intra-articular findings, and the outcomes utilizing hip arthroscopic surgery. J Hip Preserv Surg.* 2016;3:171-80.
6. Riff AJ, Kunze KN, Movassaghi K, et al. *Systematic review of hip arthroscopy for femoroacetabular impingement: the importance of labral repair and capsular closure. Arthroscopy.* 2019;35:646-56.e3.
7. Emara K, Samir W, Motasem el H, Ghafar KA. *Conservative treatment for mild femoroacetabular impingement. J Orthop Surg (Hong Kong).* 2011;19:41-5.
8. Pennock AT, Bomar JD, Johnson KP, Randich K, Upasani VV. *Nonoperative management of femoroacetabular impingement: a prospective study. Am J Sports Med.* 2018;46:3415-22.

9. Griffin DR, Dickenson EJ, Wall PDH, et al. *Hip arthroscopy versus best conservative care for the treatment of femoroacetabular impingement syndrome (UK FASHIoN): a multicentre randomised controlled trial. Lancet. 2018;391:2225-35.*
10. Mansell NS, Rhon DI, Meyer J, Slevin JM, Marchant BG. *Arthroscopic surgery or physical therapy for patients with femoroacetabular impingement syndrome: a randomized controlled trial with 2-year follow-up. Am J Sports Med. 2018;46:1306-14.*
11. Weir A, Brukner P, Delahunt E, et al. *Doha agreement meeting on terminology and definitions in groin pain in athletes. Br J Sports Med. 2015;49:768-74.*
12. Rankin AT, Bleakley CM, Cullen M. *Hip joint pathology as a leading cause of groin pain in the sporting population: a 6-year review of 894 cases. Am J Sports Med. 2015;43:1698-703.*
13. Frank JM, Harris JD, Erickson BJ, et al. *Prevalence of femoroacetabular impingement imaging findings in asymptomatic volunteers: a systematic review. Arthroscopy. 2015;31:1199-204.*
14. Griffin DR, Parsons N, Mohtadi NG, Safran MR; *Multicenter Arthroscopy of the Hip Outcomes Research Network. A short version of the International Hip Outcome Tool (iHOT-12) for use in routine clinical practice. Arthroscopy. 2012;28:611-6; quiz 616-8.*
15. Domb BG, Stake CE, Lindner D, El-Bitar Y, Jackson TJ. *Arthroscopic capsular plication and labral preservation in borderline hip dysplasia: two-year clinical outcomes of a surgical approach to a challenging problem. Am J Sports Med. 2013;41:2591-8.*
16. Economopoulos KJ, Kweon CY, Gee AO, Morris ST, Hassebrock JD, Chhabra A. *The Pull Test: a dynamic test to confirm hip microinstability. Arthrosc Sports Med Rehabil. 2019;1:e67-74.*
17. Kaya M. *Impact of extra-articular pathologies on groin pain: an arthroscopic evaluation. PLoS One. 2018;13:e0191091.*
18. Czerny C, Hofmann S, Neuhold A, et al. *Lesions of the acetabular labrum: accuracy of MR imaging and MR arthrography in detection and staging. Radiology. 1996;200:225-30.*
19. Crespo-Rodríguez AM, De Lucas-Villarrubia JC, Pastrana-Ledesma M, Hualde-Juvera A, Méndez-Alonso S, Padron M. *The diagnostic performance of non-contrast 3-Tesla magnetic resonance imaging (3-T MRI) versus 1.5-Tesla magnetic resonance arthrography (1.5-T MRA) in femoroacetabular impingement. Eur J Radiol. 2017;88:109-16.*
20. Horner NS, Ekhtiari S, Simunovic N, Safran MR, Philippon MJ, Ayeni OR. *Hip arthroscopy in patients age 40 or older: a systematic review. Arthroscopy. 2017;33:464-75.e3.*
21. Tian CY, Wang JQ, Zheng ZZ, Ren AH. *3.0 T conventional hip MR and hip MR arthrography for the acetabular labral tears confirmed by arthroscopy. Eur J Radiol. 2014;83:1822-7.*
22. Linda DD, Naraghi A, Murnaghan L, Whelan D, White LM. *Accuracy of non-arthrographic 3T MR imaging in evaluation of intra-articular pathology of the hip in femoroacetabular impingement. Skeletal Radiol. 2017;46:299-308.*