

All that elongates is not a polyp

Atsushi Iraha, Moemi Kanemoto, Akira Hokama

Department of Endoscopy, Graduate School of Medicine, University of the Ryukyus, Okinawa, Japan

Quiz

An 83-year-old woman with Sjögren syndrome presented to the emergency unit with acute painless hematochezia. Her physical examination revealed unremarkable findings. Laboratory investigations showed a white blood cell count of 7,600/ μ L, hemoglobin of 13.8 g/dL, and C-reactive protein of <0.1 mg/dL (reference range, <0.26 mg/dL). An enhanced abdominal computed tomography (CT) revealed an air bubble (arrow) and an extravasation of contrast (arrowhead) in the sigmoid colon (Fig. 1). The subsequent colonoscopy (Fig. 2) and narrow-band imaging

(NBI) (Fig. 3) revealed a hemorrhagic lesion. What is the most likely diagnosis?

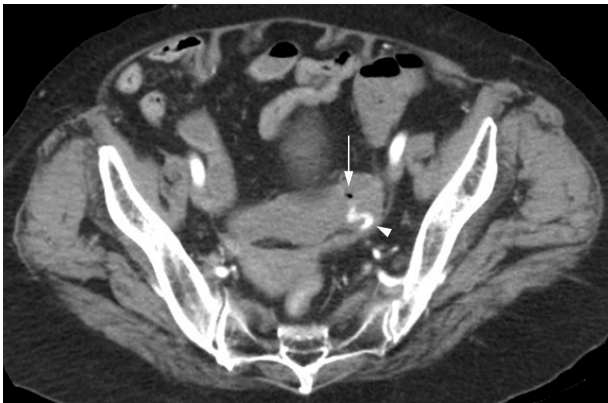

Fig. 1. The abdominal computed tomography image showing an air bubble (arrow) and an extravasation of contrast (arrowhead) in the sigmoid colon.

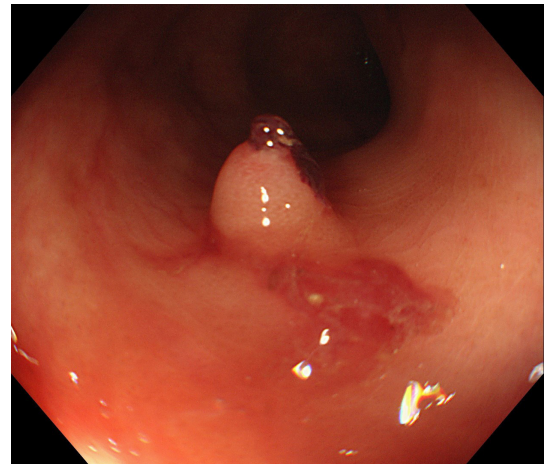


Fig. 2. Colonoscopy revealing a polypoid lesion with an exposed vessel.

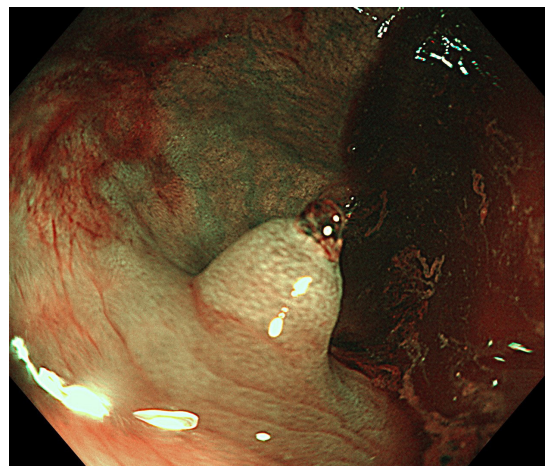


Fig. 3. Enhancement of the normal mucosal pattern and the concentric rings surrounding the polypoid lesion in narrow-band imaging.

Received: May 19, 2022 Revised: June 2, 2022 Accepted: June 3, 2022

Correspondence: Akira Hokama

Department of Endoscopy, Graduate School of Medicine, University of the Ryukyus, 207 Uehara, Nishihara, Okinawa 903-0215, Japan

E-mail: hokamaakira@gmail.com

© This is an Open Access article distributed under the terms of the Creative Commons Attribution Non-Commercial License (<http://creativecommons.org/licenses/by-nc/4.0/>) which permits unrestricted non-commercial use, distribution, and reproduction in any medium, provided the original work is properly cited.

Answer

We suspected the air bubble revealed in the abdominal CT to be a colonic diverticulum before performing colonoscopy (Fig. 1, arrow). NBI disclosed a normal mucosal pattern and concentric rings surrounding the polypoid lesion with an exposed vessel that made the diagnosis of an inverted colonic diverticulum (ICD) in the sigmoid colon (Fig. 3). The exposed vessel was treated with endoscopic hemostatic clips following which hematochezia has not recurred.

Although colonic diverticular disease is common, ICD has been rarely reported.¹⁻³ It often appears indistinguishable from the colon polyps.² The concentric rings, which are enhanced by NBI or indigo carmine dye, can help in diagnosing the ICD without maneuvers, such as the use of air insufflation, reverting the ICD with forceps, and the water jet deformation.^{2,3} To the best of our knowledge, this is the first documentation of ICD associated with an exposed vessel that causes diverticular bleeding. This case emphasized the importance of recognition of ICD for endoscopists to avoid potentially risky procedures.

Conflicts of Interest

The authors have no potential conflicts of interest.

Funding

None.

Author Contributions

Conceptualization: AI, AH; Data curation: AI, MK; Supervision: AH; Writing–original draft: AI; Writing–review & editing: AI, MK, AH.

ORCID

Atsushi Iraha	https://orcid.org/0000-0001-8546-2770
Moemi Kanemoto	https://orcid.org/0000-0003-1661-3349
Akira Hokama	https://orcid.org/0000-0002-8310-9989

REFERENCES

1. Triadafilopoulos G. Inverted colonic diverticulum. *N Engl J Med* 1999;341:1508.
2. Share MD, Avila A, Dry SM, et al. Aurora rings: a novel endoscopic finding to distinguish inverted colonic diverticula from colon polyps. *Gastrointest Endosc* 2013;77:308–312.
3. Adioui T, Seddik H. Inverted colonic diverticulum. *Ann Gastroenterol* 2014;27:411.