

Safe implementation of transoral incisionless fundoplication as a new technique in a tertiary care center

Shivanand Bomman, Sofya Malashanka, Adil Ghafoor, David J. Sanders, Shayan Irani, Richard A. Kozarek, Andrew Ross, Michal Hubka, Rajesh Krishnamoorthi

Center for Digestive Health, Virginia Mason Franciscan Health, Seattle, WA, USA

Background/Aims: Transoral incisionless fundoplication (TIF) is an accepted anatomic treatment for gastroesophageal reflux disease in selected patients. In this report, we analyze our institution's programmatic allocation of resources during the safe implementation of TIF as a new procedure.

Methods: A retrospective analysis of all patients who underwent TIF from January 2020 to February 2021 at our institution was performed. The process of initially allocating the operating room (OR) with overnight admission and postoperative esophagram for added safety, and subsequently transitioning TIF to the endoscopy suite (ES) as an outpatient procedure was described. Patient safety and outcomes were evaluated during transition.

Results: Thirty patients who underwent TIF were identified. The mean age was 51.2±16.0 years. TIF was performed in an OR in nine patients (30%) and 21 (70%) in the ES. All the OR patients were admitted overnight and had routine esophagram. In contrast, four (19%) from the ES group required clinically-indicated admission and three (14.2%) required esophagram. The mean procedure duration was significantly lower in the ES group (65.7 min vs. 84 min, $p=0.02$).

Conclusions: A stepwise, resource-efficient process was described that allowed safe initiation of TIF as a new technique and its effective transition to a fully outpatient procedure.

Keywords: Gastroesophageal reflux disease; Health resources; Implementation; Transoral incisionless fundoplication

INTRODUCTION

Gastroesophageal reflux disease (GERD) is one of the most common gastrointestinal disorders causing substantial morbidity in the United States.¹ GERD symptoms occur when stomach contents are refluxed into the esophagus, which results in dis-

comfort and eventually leads to mucosal erosion. The symptoms of GERD are present in about 28% of the United States population.² However, the cardinal symptoms of GERD may not always be present in some patients with endoscopic esophagitis or Barrett's esophagus.^{3,4}

Depending on the severity of symptoms, general management of GERD involves lifestyle and dietary modifications, antacids, surface agents, histamine 2 receptor antagonists, and proton pump inhibitors (PPIs).⁵ Despite multiple medical treatment options, GERD symptoms that are refractory to PPIs occur anywhere between 17% and 45% of the patients.⁶ Long-term PPI use has been implicated in increased risk of osteopenia, acute kidney injury, microscopic colitis, and *Clostridium difficile* infections.^{7,8} GERD is an anatomic problem, and other interventions may be considered in patients refractory to medi-

Received: November 10, 2021 **Revised:** January 12, 2022

Accepted: January 17, 2022

Correspondence: Rajesh Krishnamoorthi

Center for Digestive Health, Virginia Mason Franciscan Health, 1100, 9th Avenue, Mail stop: C3-GAS, Seattle, WA 98101, USA

E-mail: Rajesh.krishnamoorthi@commons.pirrit.org

© This is an Open Access article distributed under the terms of the Creative Commons Attribution Non-Commercial License (<http://creativecommons.org/licenses/by-nc/4.0/>) which permits unrestricted non-commercial use, distribution, and reproduction in any medium, provided the original work is properly cited.

cal therapy or those who opt to discontinue PPIs. These include surgical fundoplication, magnetic sphincter augmentation, lower esophageal sphincter radiofrequency application, and transoral incisionless fundoplication (TIF).⁵ Historically, surgical methods have been the definitive management for GERD.

TIF was introduced in 2009 as an alternative to surgical intervention and has shown promise as an anatomical treatment option in the symptom management of GERD.⁹ However, certain challenges in maintaining patient safety and training personnel are met when introducing a new and effective procedure. The correct balance involves maintaining patient safety and effective outcomes while navigating procedural learning curves, complications, and institutional costs. In this report, we share our institution's TIF implementation experience, where a programmatic allocation of resources to implement a new technique was performed. The TIF procedure was initially performed in the operating room (OR) to ensure extra safety with a planned overnight admission. With clinical experience, we systematically transitioned the procedure to be performed at the endoscopy suite (ES) as an outpatient procedure. Herein, we report our data to aid in the dissemination of this implementation technique.

METHODS

A retrospective qualitative study involving all patients who underwent TIF from January 2020 to February 2021 was performed. This study aimed to describe the implementation of TIF procedure at our center.

Patients

TIF was introduced in our tertiary care center in January 2020. All patients who underwent TIF were identified from our institution's procedure scheduling database and electronic medical records. A thorough chart review was performed to analyze patient characteristics, clinical parameters, location of procedure, and outcomes of interest.

Indications and preoperative evaluation

The main indications for a TIF procedure were adults with medically refractory GERD or patients with the goal of stopping PPI therapy. Medically refractory GERD was defined as subjective and/or objective findings of GERD despite optimal lifestyle modifications and maximal medical treatment with pharmacotherapy such as PPI for at least 3 months or more. Pa-

tients were excluded if hiatal hernias (≥ 2 cm) were present. In addition, patients with Los Angeles (LA) grade C or D esophagitis were excluded. Depending on their comorbidities, all patients underwent appropriate evaluation with their primary care physicians, cardiologists, and pulmonologists for pertinent preoperative work-up and evaluation. All patients underwent consultation with a thoracic surgeon in addition to preoperative upper endoscopy, esophageal pH testing, esophageal manometry, and barium esophagography. Further imaging studies such as gastric emptying and computed tomography scans were performed based on symptoms and comorbidities at the physician's discretion.

Procedure

The TIF procedure was performed under general anesthesia by two operators (gastroenterologist and a thoracic surgeon). One operator acted as an endoscopist while the second performed the fundoplication. Insertion of the video upper endoscope was done through the mouth and advanced to the stomach. After evaluation of the esophagus and the stomach, the Esophyx with Serofuse (Endogastric Solutions, Redmond, WA, USA) incisionless fundoplication device was advanced into the stomach using the endoscope as a guide. With the endoscope retroflexed for appropriate visualization, endoscopic fundoplication was performed to create a full-thickness plication that was 200–300 degrees in circumference and 3–5 cm in length. A total of 14–26 fasteners were used for plication. Post-procedure appearance was examined, and the endoscope and Esophyx device were withdrawn once deemed satisfactory. The patient was extubated and transferred to the post-anesthesia care unit (Fig. 1).

Location and post-procedural care

Upon introduction of the TIF procedure at our tertiary care center, all initial procedures were performed at the OR for added safety. The OR team and surgical instruments were readily available in the OR for immediate intervention, if needed. The patients were transferred to the post-anesthesia care unit after the procedure, and a planned overnight admission was done on all patients for close monitoring. Postoperative esophagram (EG) on postoperative day 1 was routinely performed on all patients prior to discharge. Post-procedural diet instructions were provided to the patients (clear liquid diet for 2 days, then a pureed diet for 7–10 days, followed by a soft diet for 2 weeks, with transition to a regular diet thereafter). Discharge with outpa-

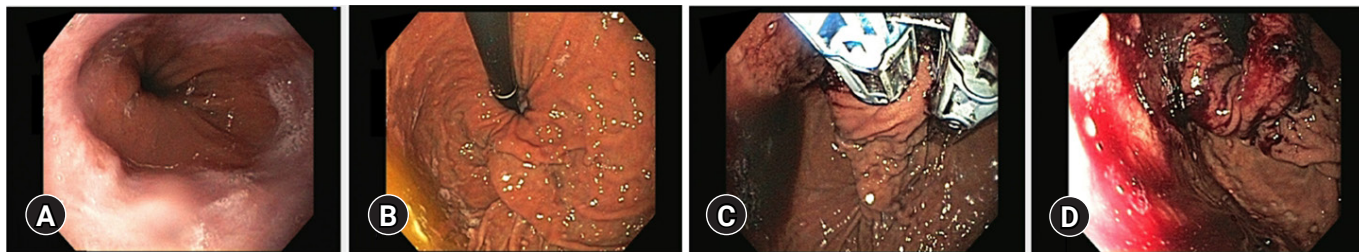


Fig. 1. Illustrations of transoral incisionless fundoplication procedure. (A) Demonstration of the squamocolumnar junction with reflux esophagitis. (B) Retroflexed view showing the fundus and hiatal hernia. (C) The transoral incisionless fundoplication device seen in retroflexion. (D) Creation of a full thickness, partial circumference, gastroesophageal fundoplication.

tient follow-up care was done on postoperative day 1 if: (1) pain was well-controlled with an oral analgesic regimen; (2) diet was tolerated without nausea or vomiting; and (3) labs, vital signs, and imaging studies were unremarkable. This plan was deliberated for three procedural sessions (nine procedures). In the meantime, the ES staff underwent training and the procedure was transitioned to the ES after three successful TIF sessions in the OR without any major complications. In addition, the procedure was also transitioned to an outpatient set up where patients were discharged the same day after meeting previously defined criteria. Hospital admission and routine EG were performed only when clinically indicated. Patients were discharged with narcotic analgesic elixir as needed for pain, anti-emetics, and any home doses of acid suppressive therapy were continued.

Follow-up

The first postoperative follow-up visit was arranged via telemedicine/phone call 7–10 days after the procedure. In person follow-up with an EG was arranged at 3 months and at 12 months post-procedure. If no further symptoms of reflux and/or no reflux was noted on EG at 3 months, acid suppressive therapy was discontinued. Any further follow-up care, imaging studies, or endoscopies were performed as needed at the physicians' discretion based on patients' symptoms and progression.

Objectives and statistical analysis

The primary objective of this study was to describe our experience of implementing a new procedure at an institution by programmatically allocating resources and navigating training processes while maintaining patient safety. Procedural outcomes of technical success and patient safety outcomes in terms of adverse events were analyzed during the transition from OR to ES. Adverse events were defined according to the American

Society of Gastrointestinal Endoscopy (ASGE) lexicon. The secondary objective was to analyze the impact of experience and training on the duration of the procedure during this transition.

The analysis was descriptive in nature where categorical variables were reported as frequencies and percentages, and continuous variables were reported as means and standard deviations (SD) or medians with ranges. Student *t*-test was used to compare continuous variables whereas Fisher exact test was used for categorical variables. Statistical significance was set at $p < 0.05$. All statistical analyses were performed using IBM SPSS ver. 23 (IBM Corp., Armonk, NY, USA).

Ethical statements

The study was approved by the Institutional Review Board (IRB No: 20-094) of Virginia Mason Franciscan Health, Seattle [VMFH]).

RESULTS

Over a period of 14 months (January 2020 to February 2021), 30 patients underwent TIF. The mean age was 51.17 ± 16.01 years, the mean body mass index was 28.01 ± 6.94 kg/m² and 18 of patients (60%) were female (Table 1).

The mean duration of GERD in patients undergoing TIF was 12 ± 10.5 years. All patients were on acid suppressive therapy with PPI and/or H2 receptor blockers prior to the procedure. Evidence of esophagitis was seen in 50% of patients, while 63.3% of patients had evidence of a small hiatal hernia. The mean DeMeester score was 57.12 ± 46.4 . The initial nine patients (30%) underwent the procedure in the OR, and 21 subsequent patients (70%) underwent TIF at the ES. All initial patients had planned admission to the hospital with a median length of stay of 1 day (range, 1–7 days), while only four patients (19%) in the latter group required admission based on their symptoms with

Table 1. Demographics and clinical characteristics of study patients

Patient characteristic	Value
Age (yr)	51.2±16.0
Female sex	18 (60.0)
Body mass index (kg/m ²)	28.0±6.9
GERD duration (yr)	12.0±10.5
Esophagitis	15 (50.0)
Hiatal hernia	11 (36.7)
Symptom	
Heartburn	30 (100)
Regurgitation	11 (36.7)
Dysphagia	3 (10.0)
Nausea	1 (3.3)
Other	4 (13.3)
Esophageal pH monitoring	
DeMeester score	57.1±46.5
Fraction time pH <4 (%)	19.4±19.6
Symptom index (%)	54.6±36.7
Manometry	
Resting mean LES pressure (mmHg)	18.4±10.1
Acid suppressive therapy	
Proton pump inhibitor	29 (96.7)
Histamine type-2 receptor blocker	3 (10.0)

Values are presented as mean±standard deviation or number (%).

GERD, gastroesophageal reflux disease; LES, lower esophageal sphincter.

a median length of stay of 1 day. Two of these patients were admitted for nausea and vomiting, one had significant pain, and one patient necessitated overnight admission due to lack of transportation (patient resided out of town). As the procedure transitioned towards ES, 81% of patients were successfully discharged on the same day of procedure. All patients in the OR group had routine EG, while only three patients (14.2%) in the ES required EG based on suspicious symptoms such as nausea, vomiting, and pain. Two patients required readmission within 30 days, one from the OR and ES groups respectively. One patient from the OR group had a peripherally inserted central catheter (PICC) line dysfunction and a PICC-associated deep vein thrombosis which required admission for anticoagulation and eventual replacement of PICC line (non-TIF-related issue). In contrast, the other patient from the ES group had an emergency room visit for post-procedural pain requiring intravenous pain medications.

The TIF procedure was technically successful in 29/30 patients (96.6%) except in one who had undergone sleeve gastrectomy. Three patients (10%) who had successful TIF had minor intraoperative complications. One patient experienced

bleeding at a fastener site in the distal esophagus, which was treated with epinephrine and coaptive coagulation. Another patient had mild mucosal and submucosal tears at the cricopharyngeus from the device passage, but no full-thickness perforation was noted. The third patient had difficult esophageal passage requiring dilation, causing mucosal stretching and tearing without perforation. A total of three patients (10%) had minor postoperative adverse events. Two had intractable pain requiring an ER visit and/or hospital admission after being discharged, and one had persistent nausea and vomiting requiring overnight admission. All these adverse events were observed in patients from the ES group. No major adverse events were noted. Esophageal leak or perforation did not occur in any patient. The mean duration of the procedure was significantly lower in procedures performed at the ES (65.71±10.15 min vs. 84±18.42 min; $p=0.002$) (Fig. 2). Among the successful TIF patients who had 3 months follow-up (25/29 patients), 17/25 patients (68%) had stopped or reduced acid suppressive therapy while pre-procedural doses of acid suppressive therapy was continued in 8/25 (32%). Similarly, 20/25 (80%) had no reflux on follow-up EG, 2/25 (8%) had reflux only with provocative maneuvers, 2/25 (8%) had reduced reflux compared to pre-procedural EG, and 1/25 (4%) continued to have spontaneous reflux. No symptom improvement was noted in 2/25 (8%), with subsequent arrangement of further studies and additional follow-up. Table 2 shows procedural characteristics and post-procedural outcomes.

DISCUSSION

Historically, surgery has been the mainstay for the definitive anatomic management of refractory GERD. Randomized controlled trials comparing TIF and PPI therapy have demonstrated the superiority of TIF in eliminating troublesome refractory reflux symptoms with durable results.¹⁰ Studies have shown TIF to be comparable to Nissen fundoplication (NF) for symptom relief in a subset of patients without a large hiatal hernia.¹¹ A systematic review and network meta-analysis by Richter et al.¹² reported TIF to be superior to laparoscopic NF in improving health-related quality of life. However, the same study showed laparoscopic NF was better than TIF in achieving improved % time pH <4. Compared to other anti-reflux surgeries, the main advantages of TIF include its minimally invasive nature, short and reliable postoperative recovery, and its ability to be performed as an outpatient procedure. The data on short-term effectiveness of TIF is robust and although some studies

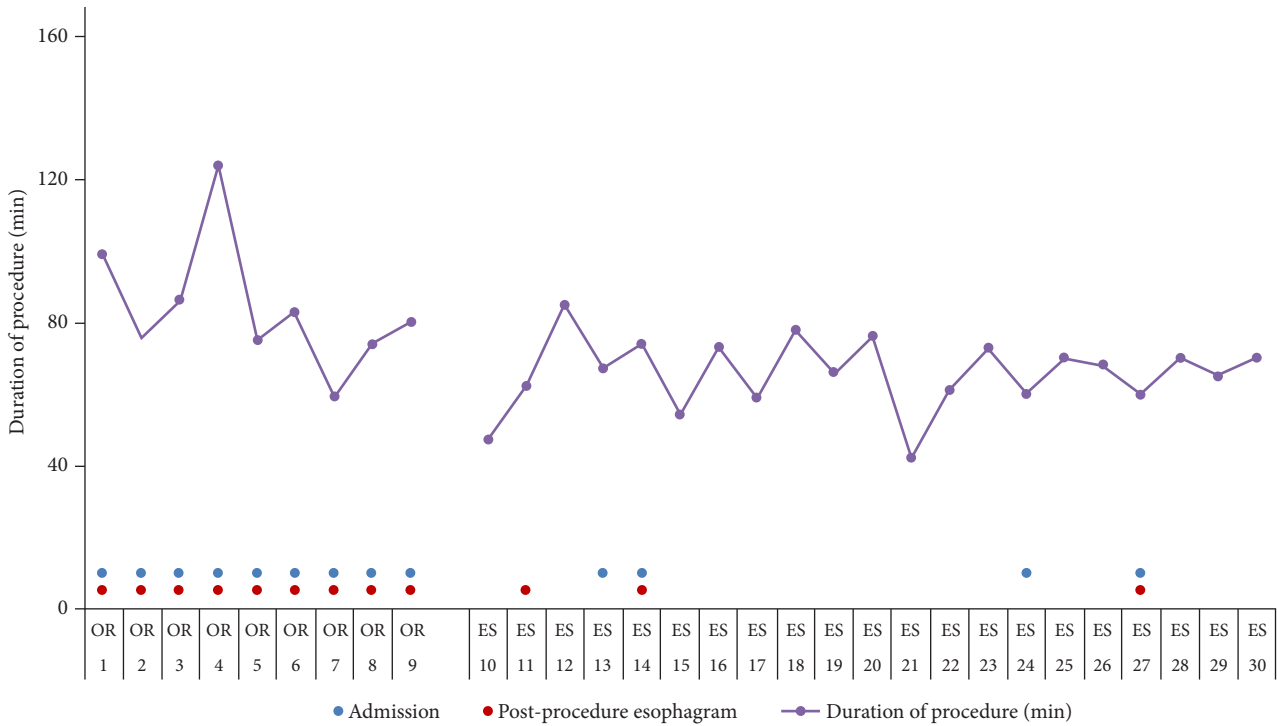


Fig. 2. Implementation and transition of transoral incisionless fundoplication procedure from operating room (OR) to endoscopy suite (ES).

Table 2. Procedural characteristics and post-procedural outcomes

Procedural and post-procedural characteristics	Operating room (n=9)	Endoscopy suite (n=21)	p-value
Duration of procedure (min)	84.0±18.4	65.7±10.2	0.020
Fasteners used	20.0±3.0	18.0±3.6	
Unplanned admission	0	4 (19.0)	0.287
Length of stay (day)	1 (1-7)	1 (1)	
Significant pain requiring in-hospital care after procedure	1 (11.1)	2 (9.5)	1.000
Intraprocedural complication	0	3 (14.3)	0.534
Esophagram	9 (100)	3 (14.3)	
Readmission <30 days	1 (11.1)	1 (4.8)	0.517
3-Month follow-up (n=25)			
Symptom improvement		23 (92.0)	
Follow-up esophagram			
No reflux		20 (80.0)	
Reflux with provocative maneuvers		2 (8.0)	
Spontaneous reflux, but improved		2 (8.0)	
Spontaneous reflux		1 (4.0)	
PPI use (at 3 months post-procedure)			
Stopped		10 (40.0)	
Reduced dose		7 (28.0)	
Still using at same dose		8 (32.0)	

Values are presented as mean±standard deviation, median (range), or number (%). PPI, proton pump inhibitor.

have reported sustained results, further studies are required to demonstrate long-term efficacy.¹⁰ The need to create a protocol for safely introducing this minimally invasive approach for definitive treatment of GERD at our VMFH was identified. Utilizing the resources available at VMFH, we have described the development of a protocol to implement the TIF procedure. Moreover, the challenges and accomplishments of protocolizing this minimally invasive approach to treating refractory GERD was discussed.

There are no protocols or guidelines in place to guide the safe introduction and implementation of a novel procedure such as TIF. A multidisciplinary approach was used to introduce the procedure at our center. A decision was made to introduce this procedure using two attending physicians (gastroenterologist and thoracic surgeon) based on the clinical expertise associated with the two operators. All operators underwent training according to the manufacturer's guidelines and all procedures were supervised by the manufacturer representatives with extensive experience in the technique. Both OR and ES staffs underwent the necessary mandatory training. The procedure was initially implemented in the OR, with all patients requiring overnight admission. While the length of hospital stay among all OR patients was 1 day, one patient who had multiple chronic medical and psychosocial conditions and a history of multiple prior hospitalizations was admitted for 7 days due to issues related to her comorbidities. A prolonged admission like the one mentioned is unusual in TIF patients, and this admission was due to a non-gastroenterology-related issue. The OR was adequately equipped with the necessary instruments and staff on standby for the possibility of an emergent thoracic surgery in case any complications arose. As the providers gained experience, resource utilization was systematically reduced. The procedure was then transitioned to the ES, with overnight admission and postoperative EG was no longer considered a routine procedure unless a clinical indication was present. The initial demonstration of safety with routine postoperative EG led to the omission of this study in the cohort. Currently, more than 80% of patients who undergo TIF are discharged on the same day.

With the introduction of TIF at our institution, a technical success rate of nearly 97% in our experience with the first 30 patients was observed. One technical failure occurred at the ES in a patient with prior gastric sleeve surgery, which is a technically difficult procedure given the altered anatomy. Four other patients had successful TIF despite altered anatomy. Two

of these patients had previously undergone DaVinci robotic-assisted hiatal and paraesophageal hernia repair with partial fundoplication. One patient had prior open paraesophageal hernia repair, while the other had hiatal hernia repair with partial fundoplication. No major complications were associated with TIF. Furthermore, the tapering or discontinuation of PPI medications in patients was generally initiated at their 3-month appointments. However, earlier discontinuation of PPIs was possible in 40% of patients.

Anatomic endoscopic treatments for GERD have been available for more than 20 years,^{5,13} with radiofrequency application and TIF being the two main endoscopic treatment options currently available.⁵ Endoscopic fundoplication was first introduced in 2005 and involved gastro-gastric plication below the Z line. The next iterations were TIF 1.0 and the currently performed TIF 2.0, which were introduced in 2007 and 2009 respectively.¹³ TIF 2.0 involves esophagogastric plication 1–3 cm above the Z line using around 12–23 fasteners to form a 270°–300° plication.^{13,14} As of 2019, it has been reported that more than 22,000 patients have undergone TIF.¹³ An abstract by Brewer Gutierrez et al.¹⁵ reported their experience with the learning curve of TIF, which showed a progressive decrease in the total procedure time with experience. They also reported that endoscopists required at least 23 procedures to achieve procedure times <1 hour. This is in line with the findings of our study, which shows consistently lower procedure times after 20 procedures with an average time of 65 minutes (Fig. 2).

The strength of this study lies in the fact that this is the first to report the experience of systematically implementing the TIF procedure at a tertiary referral center with extensive previous experience in surgical repair of reflux. The process of planned resource allocation with subsequent transition to a resource-optimal, cost-effective process for outpatient TIF has been implemented. The limitations of this study are the retrospective nature and the small sample size with inherent limitations and risks of bias. Moreover, qualitative scales such as the GERD Health-Related Quality of Life Questionnaire were not used to assess the impact of TIF on symptom improvement and quality of life. Finally, four patients (13.8%) were unable to comply with the 3-month postoperative ES follow-up.

We share our TIF introduction experience to aid in the dissemination of our implementation technique. A stepwise process of planned reduction in-hospital resource allocation over time for the safe implementation of TIF was described. With this process, we were able to introduce a new technique without

major complications while successfully transitioning to a fully outpatient procedure. The introduction of a new procedure in a hospital or healthcare system requires the understanding that despite initial extended safety protocols and additional costs in the form of training time and resource utilization, the new procedure will be more cost-effective and efficient once implementation is complete.

Conflicts of Interest

Shayan Irani is a consultant for Boston Scientific and Gore; Richard A. Kozarek received research support from Boston Scientific and NIH; Andrew Ross is a consultant for Boston Scientific. The others have no potential conflicts of interest.

Funding

None.

Author Contributions

Conceptualization: MH; Data curation: SB, AG, DJS; Formal analysis: SB, SM, DJS; Investigation: SB, MH; Methodology: SB, MH, RK; Project administration: MH, RK; Supervision: SI, RAK, AR, MH, RK; Validation: all authors; Visualization: SB, SM, DJS; Writing-original draft: SB, SM, DJS, RK; Writing-review and editing: all authors.

ORCID

Shivanand Bomman	https://orcid.org/0000-0002-3324-9502
Sofya Malashanka	https://orcid.org/0000-0002-6318-7162
Adil Ghafoor	https://orcid.org/0000-0002-6851-0045
David J. Sanders	https://orcid.org/0000-0003-1410-4049
Shayan Irani	https://orcid.org/0000-0002-5490-692X
Richard A. Kozarek	https://orcid.org/0000-0002-9745-7538
Andrew Ross	https://orcid.org/0000-0002-6587-7503
Michal Hubka	https://orcid.org/0000-0001-5586-9959
Rajesh Krishnamoorthi	https://orcid.org/0000-0002-1889-2129

REFERENCES

1. Peery AF, Crockett SD, Murphy CC, et al. Burden and cost of gastrointestinal, liver, and pancreatic diseases in the United States: update

2018. *Gastroenterology* 2019;156:254–272.
2. Camilleri M, Dubois D, Coulie B, et al. Prevalence and socioeconomic impact of upper gastrointestinal disorders in the United States: results of the US Upper Gastrointestinal Study. *Clin Gastroenterol Hepatol* 2005;3:543–552.
3. Maret-Ouda J, Markar SR, Lagergren J. Gastroesophageal reflux disease: a review. *JAMA* 2020;324:2536–2547.
4. Spechler SJ, Souza RF. Barrett's esophagus. *N Engl J Med* 2014;371:836–845.
5. Gyawali CP, Fass R. Management of gastroesophageal reflux disease. *Gastroenterology* 2018;154:302–318.
6. El-Serag H, Becher A, Jones R. Systematic review: persistent reflux symptoms on proton pump inhibitor therapy in primary care and community studies. *Aliment Pharmacol Ther* 2010;32:720–737.
7. Keszthelyi D, Jansen SV, Schouten GA, et al. Proton pump inhibitor use is associated with an increased risk for microscopic colitis: a case-control study. *Aliment Pharmacol Ther* 2010;32:1124–1128.
8. Kwok CS, Arthur AK, Anibueze CI, et al. Risk of *Clostridium difficile* infection with acid suppressing drugs and antibiotics: meta-analysis. *Am J Gastroenterol* 2012;107:1011–1019.
9. Jafri SM, Arora G, Triadafilopoulos G. What is left of the endoscopic antireflux devices? *Curr Opin Gastroenterol* 2009;25:352–357.
10. Trad KS, Barnes WE, Prevou ER, et al. The TEMPO trial at 5 years: transoral fundoplication (TIF 2.0) is safe, durable, and cost-effective. *Surg Innov* 2018;25:149–157.
11. Toomey P, Teta A, Patel K, et al. Transoral incisionless fundoplication: is it as safe and efficacious as a Nissen or Toupet fundoplication? *Am Surg* 2014;80:860–867.
12. Richter JE, Kumar A, Lipka S, et al. Efficacy of laparoscopic nissen fundoplication vs transoral incisionless fundoplication or proton pump inhibitors in patients with gastroesophageal reflux disease: a systematic review and network meta-analysis. *Gastroenterology* 2018;154:1298–1308.
13. Ihde GM. The evolution of TIF: transoral incisionless fundoplication. *Therap Adv Gastroenterol* 2020;13:1756284820924206.
14. Chang KJ, Bell R. Transoral incisionless fundoplication. *Gastrointest Endosc Clin N Am* 2020;30:267–289.
15. Brewer Gutierrez OI, Dbouk M, Kannadath BS, et al. Mo1283 Learning curve of transoral incisionless fundoplication: a single endoscopist experience. *Gastrointest Endosc* 2020;91Suppl:AB416.