

# Endoscopic treatment for rectal neuroendocrine tumor: which method is better?

Seung Min Hong<sup>1,2</sup>, Dong Hoon Baek<sup>1,2</sup>

<sup>1</sup>Department of Internal Medicine, Pusan National University College of Medicine, Busan; <sup>2</sup>Biomedical Research Institute, Pusan National University Hospital, Busan, Korea

Recently, research on rectal neuroendocrine tumors (NETs) has increased during the last few decades. Rectal NETs measuring <10 mm without atypical features and confined to the submucosal layer have only 1% risk of metastasis, and the long-term survival probability of patients without metastasis at the time of diagnosis is approximately 100%. Therefore, the current guidelines suggest endoscopic resection of rectal NETs of <10 mm is regarded as a safe therapeutic option. However, there are currently no clear recommendations for technique selection for endoscopic resection. The choice of treatment modality for rectal NETs should be based on the lesion size, endoscopic characteristics, grade of differentiation, depth of vertical involvement, lymphovascular invasion, and risk of metastasis. Moreover, the complete resection rate, complications, and experience at the center should be considered. Modified endoscopic mucosal resection is the most suitable resection method for rectal NETs of <10 mm, because it is an effective and safe technique that is relatively simple and less time-consuming compared with endoscopic submucosal dissection. Endoscopic submucosal dissection should be considered when the tumor size is >10 mm, suctioning is not possible due to fibrosis in the lesion, or when the snaring for modified endoscopic mucosal resection does not work well.

**Keywords:** Endoscopic mucosal resection; Endoscopic submucosal dissection; Neuroendocrine tumor; Rectum

## INTRODUCTION

Neuroendocrine tumors (NETs) originate from heterogeneous neuroendocrine cells and peptidergic neurons, and exhibit various biological behaviors according to anatomical sites and pathological features.<sup>1,2</sup> The incidence of gastrointestinal NETs (GI-NETs) in Japan and the United States is reported to be

similar (annual incidence rates of 2.10 per 100,000 and 2.53 per 100,000, respectively).<sup>3,4</sup> However, marked differences in the distribution of GI-NETs have been observed between Asian and Western countries. In reports from the United States and Europe, midgut NETs occupy a large portion (38.7% in the United States, 30%–60% in Europe), and the small intestine is the most common site of GI-NETs. However, in Korea and Japan, the ratio of midgut NETs is low (the incidence of small intestinal NETs was only 7.7% in Korea, which is similar to 9.6% in a Japanese study), and the rectum was the most common site for GI-NETs in Korea.<sup>1,3</sup> Recently, the number of rectal NETs and related clinical research has increased during the last decades due to advancements in endoscopic technology, such as endoscopy and imaging, the popularization of colonoscopy, and clinical endoscopists' increased awareness of the disease.<sup>5-7</sup> However, whether this increase is due to an increase in the detection rate of tumors or the incidence rate due to the widespread use of

**Received:** March 30, 2022    **Revised:** May 12, 2022  
**Accepted:** May 23, 2022

**Correspondence:** Dong Hoon Baek  
Department of Internal Medicine, Pusan National University College of Medicine and Biomedical Research Institute, Pusan National University Hospital, 179 Gudeok-ro, Seo-gu, Busan 49241, Korea  
**E-mail:** dhbeak@naver.com

© This is an Open Access article distributed under the terms of the Creative Commons Attribution Non-Commercial License (<http://creativecommons.org/licenses/by-nc/4.0/>) which permits unrestricted non-commercial use, distribution, and reproduction in any medium, provided the original work is properly cited.

colonoscopy remains unclear. Most rectal NETs are more indolent than other epithelial malignancies although they can be aggressive and resistant to therapy. Rectal NETs are pathologically categorized according to the World Health Organization classification system, and their pathological grade is based on the mitotic and Ki-67 indices (Table 1).<sup>8</sup>

Although studies on rectal NETs are mostly retrospective with small sample sizes, and the efficacies of different treatment methods are still controversial with insufficient medical evidence, the treatment of this disease is gradually becoming standardized according to the proposal of corresponding guidelines.<sup>9,10</sup> Rectal NETs are typically small (approximately 80% are <10 mm in diameter) single yellowish subepithelial lesions with intact overlying mucosa, not deeper than the submucosal layer, and are frequently located in the midrectum (within 10 cm from the anorectal junction).<sup>8</sup> In a recent report of a series of 788 T1 rectal NETs, rectal NETs measuring <10 mm had 1% risk of metastasis, with the long-term survival probability of patients without metastasis at the time of diagnosis being 100%.<sup>11</sup> Therefore, endoscopic resection is recommended for NETs <10 mm, because they have benign behavior and a low risk of metastasis in the absence of muscular and lymphovascular invasion.<sup>12,13</sup> Meanwhile, for rectal NETs >20 mm, the metastatic risk is 60% to 80%; therefore, radical surgery and lymphadenectomy are recommended. There is an area of uncertainty regarding tumors between 10 and 20 mm, in which the metastatic risk is intermediate, and endoscopic treatment can be challenging. Since the risk of metastasis is approximately 10% to 15% for 10 to 20-mm NETs, the treatment method is determined according to endoscopic features, endoscopic ultrasound findings, grade, and muscularis propria invasion.<sup>14</sup> Surgery, rather than endoscopic resection, should be considered when the NET size is  $\geq 14$  mm, an atypical endoscopic appearance indicates an ulcerofungating growth, central depression or ulcer, semipedunculated hyperemic color change, or muscularis propria invasion is present on endoscopic ultrasound and magnetic resonance imaging of the pelvis.<sup>8,15</sup>

**Table 1.** Grading for rectal neuroendocrine tumors

Grading	Pathologic findings
G1 (low grade)	<2 mitoses/10 HPFs and <2% Ki-67 index
G2 (intermediate grade)	2–20 mitoses/10 HPFs or 3%–20% Ki-67 index
G3 (high grade)	>20 mitoses/10 HPFs or >20% Ki-67 index

G, grading; HPF, high power field.

Therapeutic endoscopists select the endoscopic resection method according to tumor characteristics, such as size, morphology, and mucosal and submucosal appearance.<sup>16</sup> The most important factor in predicting aggressive disease is the size of the primary tumor. Endoscopic resection of rectal NET can be divided into standard indications (tumor size <10 mm) and expanded indications (tumor size, 10–19 mm) according to tumor size. This review article describes which endoscopic resection method is the best standard modality according to each clinical situation.

## ENDOSCOPIC RESECTION METHODS FOR RECTAL NEUROENDOCRINE TUMORS

Rectal NETs constitute approximately 1% of all rectal neoplastic lesions and are mostly asymptomatic.<sup>17</sup> One key issue for endoscopic resection of rectal NETs is identifying them based on macroscopic features before improperly performing forceps biopsy, snare polypectomy, or conventional endoscopic mucosal resection (EMR). The complete resection rate was 68.2% when rectal NET was considered as a polyp before endoscopic resection, and 94.5% when diagnosed or suspected as NET before endoscopic resection.<sup>9,18</sup> In addition, a preceding biopsy performed before endoscopic resection can interfere with complete resection by causing blurred tumor borders and fibrosis of the tissue.<sup>19</sup> Therefore, the endoscopic findings of rectal NETs, such as smooth/round/sessile and yellow-discolored subepithelial nodules (reflecting the presence of chromogranin) <10 mm in diameter with intact overlying mucosa, typically observed within 5 to 10 cm from the anal verge, are strongly suggestive of rectal NETs and must be completely resected.

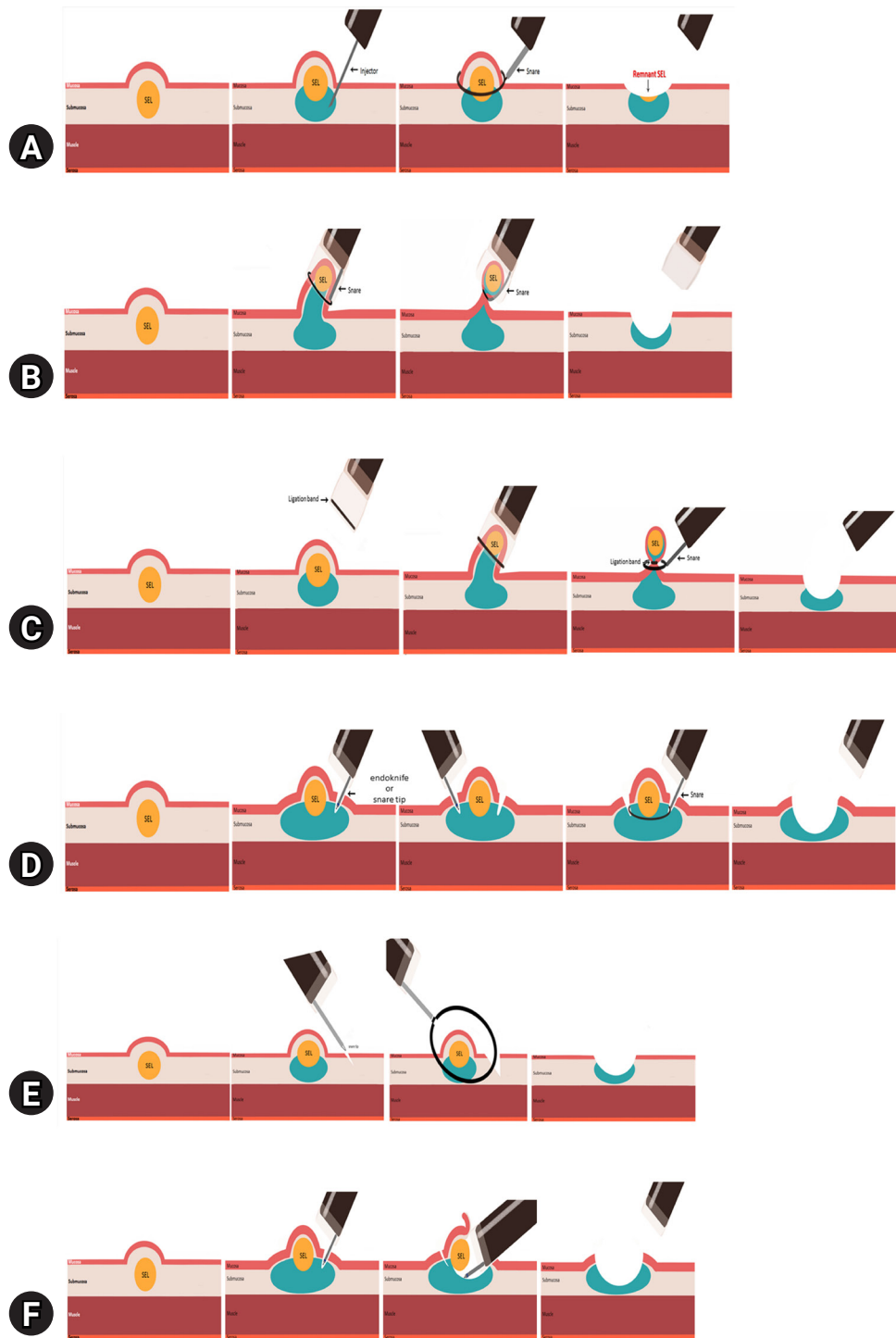
Endoscopic resection of rectal NETs should be aimed at *en bloc* and complete resection, as incomplete resection puts patients at risk for metastasis, resulting in repeated endoscopic and follow-up radiologic examinations and the need for salvage therapy.<sup>20</sup> Various endoscopic resection methods, such as snare polypectomy, EMR, modified EMR (m-EMR), and endoscopic submucosal dissection (ESD), have been used to treat rectal NETs.

### Conventional endoscopic mucosal resection

Complete resection rate of snare polypectomy is 20 to 30%.<sup>21,22</sup> Conventional EMR proceeds snare cautery resection after lifting the lesion by submucosal injection to elevate the mucosal lesion away from the muscularis propria (Fig. 1A). Its

advantages include being simple, less invasive, shorter procedure time (2–5 minutes), and a low complication rate (1.8%).<sup>23</sup> However, similar to snare polypectomy, conventional EMR

cannot adequately and completely resect lesions in the submucosal layer, and additional salvage interventions may be needed. Since 76% of rectal NETs extend into the submucosal layer,<sup>24,25</sup>



**Fig. 1.** Each endoscopic resection procedure for rectal neuroendocrine tumor. (A) Conventional endoscopic mucosal resection (EMR). (B) EMR with a cap. (C) EMR with band ligation. (D) EMR after circumferential incision/precutting. (E) anchored snare-tip EMR. (F) Endoscopic submucosal dissection.

snare polypectomy and conventional EMR, which do not sufficiently capture the submucosal layer, are generally not selected because of the high risk of incomplete histologic resection. That's why it is not possible to sufficiently capture the submucosal part of the lesion by submucosal injection or snaring alone. Additionally, snare polypectomy and conventional EMR can cause crushing injury of the resection specimen, so it is disadvantageous for pathological evaluation, which is also why these methods are not commonly used.<sup>26</sup> Several studies have reported that the complete resection rate of conventional EMR is 30% to 80%<sup>7,27-31</sup> and an adverse event rate of 4.1%.<sup>28</sup>

**Modified endoscopic mucosal resection**

To overcome the limitations of standard polypectomy and conventional EMR, various m-EMR techniques have been utilized: EMR using a transparent cap (EMR-C); EMR with a ligation device (EMR-L), endoscopic submucosal resection with band ligation (ESMR-L); EMR using a dual-channel endoscope (EMR-D); EMR after circumferential incision/precutting (EMR-P), which is also called EMR with circumferential submucosal incision; and anchored snare-tip EMR (ASEMR). m-EMR has been classified in detail according to the specific procedure process. First, it can be divided into methods that use suction and those that do not. Methods using suction include EMR-C and EMR-L, whereas those that do not use suction include conventional EMR, EMR-P, ASEMR, and EMR-D (Table 2). The principle of m-EMR is to help the snare capture the deeper submucosal layer using suctioning and precutting. Thus,

a higher complete resection rate is expected.

In EMR-C, the lesion is brought into the transparent cap by suction after submucosal injection. The lesion in the transparent cap is then captured with a snare to perform resection (Fig. 1B). EMR-C is technically easier and faster than ESD; therefore, it is an effective and safe technique for endoscopic resection of rectal NETs.<sup>32,33</sup> The complete resection rate of EMR-C is reported to be 83.3% to 100%, the procedure time is 5 to 10 minutes, and the complication rate is 2.9% to 4.8%.<sup>7,30</sup>

First introduced in 1999, EMR-L uses suction with a transparent cap fitted to the scope, binding the bottom of the lesion with a ligation band, such as endoscopic variceal ligation, followed by closure of a snare beneath the ligation band so that it can be easily resected using a snare (Fig. 1C).<sup>34</sup> Like EMR-C, EMR-L is technically easier and faster than ESD; therefore, it is an effective and safe technique for the endoscopic resection of rectal NETs. The complete resection rate of EMR-L is reported to be 95.5% to 100%, the procedure time is 5 to 10 minutes, and the complication rate is 0% to 4.8%.<sup>7,35</sup> EMR-L with endoscopic ultrasonography is performed to confirm complete ligation of the lesion before snaring. Li et al.<sup>36</sup> reported that ESMR with endoscopic ultrasonography demonstrated a slightly higher pathological complete resection rate than EMR-L (97.9% vs. 88.7%,  $p=0.152$ ). They assessed this result as having practical clinical significance, although it was not statistically significant. Comparing EMR-C and EMR-L, EMR-L may be the preferable treatment method, considering both the endoscopic *en bloc* resection rate and histologic complete resection rate.<sup>7</sup>

EMR-P is performed by lifting the mucosa with a submucosal injection, making a circumferential incision/precutting along a margin that is 2 mm outside the tumor using the tip of the snare. Subsequently, the snare is securely positioned in the cut groove and tightened, and the tumor is resected using electrical current (Fig. 1D). The complete resection rate of EMR-P is reported to be 93.1% to 99.4%, the procedure time is 2.5 to 30 minutes, and the complication rate is 5.5%.<sup>37,38</sup>

In ASEMR, a small mucosal slit is made using the snare tip after submucosal injection, and then the snare tip is anchored into the mucosal slit, so it will not slip off the lesion (Fig. 1E). In comparison with EMR using suction, ASEMR achieves similar complete resection rates with minor complications. The complete resection rate of ASEMR is reported to be 94.1%, the procedure time is 2.8 minutes, and the complication rate is 6.7%.<sup>39</sup> ASEMR has a shorter procedure time than EMR-P. In addition, compared to EMR using suction, there is the advantage that

**Table 2.** Various endoscopic resection technique for rectal neuroendocrine tumor

Techniques without suction	Techniques with suction
Conventional method	
Conventional snare polypectomy without injection	
Conventional snare polypectomy with injection, lift and cut method (EMR)	
Modified EMR	
Inject, precut, and cut method (EMR after circumferential incision/precutting)	EMR with cap
Anchored snare-tip EMR	EMR with band ligation
EMR using a dual-channel endoscope	

EMR, endoscopic mucosal resection.

there is no need for a dedicated cap as in EMR-C or a band ligation device as in EMR-L.

EMR using a dual-channel endoscope is referred to as an EMR-D or strip biopsy. Recently, Lee et al.<sup>27</sup> reported that the histological complete resection rate of EMR-D was 90.7%; this was significantly higher than that of conventional EMR (74.5%), and no significant differences were identified between EMR-L (93.1%) and EMR-P (90.9%). Sung et al.<sup>40</sup> compared conventional EMR, EMR-D, and ESD in their prospective study. Although not significant ( $p=0.41$ ), the histologic complete resection rate of EMR-D was 74.1%, which was lower than that of ESD (100%).

### Endoscopic submucosal dissection

ESD is a minimally invasive advanced endoscopic technique used for *en bloc* and complete resection of GI tumors. ESD consists of the following three steps: submucosal injection to elevate the tumor, precutting the mucosa surrounding the tumor, and dissection of the connective tissue of the submucosa beneath the tumor (Fig. 1F). ESD has a high complete resection rate for rectal NETs. Several studies have reported the complete resection rate of ESD as 87.1% to 100%.<sup>29,31,38,40-43</sup> Hybrid ESD is an effective and safe endoscopic resection technique for rectal NETs as an alternative to conventional ESD. Hybrid ESD involves a circumferential incision after submucosal injection similar to ESD. After circumferential incision, submucosal dissection proceeds to at least the bottom margin of the lesion, and then snaring is performed to excise the undissected lesion instead of using an endoknife. Recently, Wang et al.<sup>44</sup> reported that hybrid ESD had a similar complete resection rate and safety profile as ESD, and the procedure time of hybrid ESD was shorter than that of ESD (complete resection rate, 94.1% vs. 90%; mean procedure time, 13.2 vs. 18.1 minutes, respectively). According to the endoscopist's decision, changing the resection method from ESD to hybrid ESD can be considered if an appropriate vertical margin is secured during the procedure.

### WHICH METHOD IS BEST?

Current guidelines recommend endoscopic resection for small rectal NETs that are <10 mm in size, with no atypical endoscopic appearance, and confined to the mucosa and submucosa.<sup>9,10</sup> However, currently, there are no clear recommendations for the selection of any technique for endoscopic resection. As the options for endoscopic resection of rectal NETs have increased,

a number of studies have been conducted to identify the methods with better outcomes. Data comparing different endoscopic methods used for the management of rectal NETs, including complete resection rates and complications, are presented in Table 3.<sup>7,27-31,35-42,44-48</sup> Various factors should be considered to determine which method is better. Although a method with a high histologic complete resection rate is mandatory, the complication rate, status of the equipment in the hospital, proficiency of the therapeutic endoscopists and assistants, short procedure time, and length of hospital stay should be considered.

Snare polypectomy and conventional EMR are the easiest and simplest endoscopic resection methods, although they are not generally used as standard treatment because of the risk of incomplete resection. Zheng et al.<sup>45</sup> reported that the odds ratio (OR) for histologic complete resection was 0.23 (95% confidence interval [CI], 0.10%–0.51%,  $p<0.01$ ) when conventional EMR was compared to m-EMR. Kim et al.<sup>29</sup> reported that the complete resection rate of conventional EMR was 77.4%, which was significantly lower than 97.7% of ESD. In a meta-analysis, Zhou et al.<sup>46</sup> reported that the complete resection rate of conventional EMR was lower than that of m-EMR (relative risk, 0.72; 95% CI, 0.60%–0.86%) and ESD (relative risk, 0.89; 95% CI, 0.79%–0.99%). Therefore, snare polypectomy and conventional EMR are not considered standard options for endoscopic resection.

Both EMR-C and EMR-L are useful for removing rectal NETs <10 mm in diameter.<sup>42,43</sup> In a recently published meta-analysis comparing the efficacy and safety of EMR with suction and ESD for small rectal NETs, EMR with suction was superior to ESD for small rectal NETs ( $\leq 10$  mm) with a higher complete resection rate (OR, 4.08; 95% CI, 2.42–6.88,  $p<0.00001$ ), shorter procedure time (standard mean difference,  $-1.59\%$ ; 95% CI,  $-2.27\%$  to  $-0.90\%$ ,  $p<0.00001$ ), and similar overall complication rate (OR, 0.56; 95% CI, 0.28–1.14;  $p=0.11$ ) and recurrence rate (OR, 0.76; 95% CI, 0.11–5.07;  $I^2$ , 48%).<sup>47</sup> In a study comparing ESD with EMR-L, EMR-L had a higher complete resection rate than ESD (95.5% vs. 75.0%,  $p=0.025$ ).<sup>35</sup> Additionally, one of the most important reasons for the superiority of EMR-L is its low vertical margin positivity rate. When the lateral and vertical margin distances from the tumor were measured, the lateral and vertical margins were more distant in the EMR-L group than in the ESD group (lateral margin distance,  $1,661\pm 849$  vs.  $1,514\pm 948$   $\mu\text{m}$ ; vertical margin distance,  $277\pm 308$  vs.  $202\pm 171$   $\mu\text{m}$ , respectively).<sup>35</sup> In another study measuring vertical margin distances from the tumor, EMR-L had a higher

**Table 3.** Summary of studies on endoscopic resection methods for rectal neuroendocrine tumors

Study	Country	Resection technique	Design	No. of patients	Results	
					En bloc & complete resection	Procedure time
Lee et al., <sup>7</sup> 2020	Korea	EMR-L, EMR-C	Retrospective	158	En bloc resection: EMR-L 100% vs. EMR-C 92.9% ( $p=0.003$ ) Complete resection: EMR-L 92.5% vs. EMR-C 83.3% ( $p=0.087$ )	
Lee et al., <sup>27</sup> 2021	Korea	EMR, EMR-P, EMR-L, strip biopsy	Retrospective	215	Complete resection: EMR 74.5%, EMR-P 90.9%, EMR-L 93.1%, strip biopsy 90.7%	Postoperative bleeding: cEMR 0%, EMR-P 0%, EMR-L 3.4%, strip biopsy 4.7% Perforation: none
Im et al., <sup>28</sup> 2014	Korea	EMR, EMR-L	Prospective for EML-L, retrospective for EMR	109	Complete resection: EMR 75.7% vs. EMR-L 94.3% ( $p=0.019$ )	Postoperative bleeding: EMR 4.1% vs. EMR-L 2.9% ( $p=0.756$ ) Perforation: none
Kim et al., <sup>29</sup> 2013	Korea	EMR, EMR-L, ESD	Retrospective	115	Complete resection: EMR 77.4%, EMR-L 100%, ESD 97.7%	Bleeding: none Perforation: 1 case on EMR-L group
Yang et al., <sup>30</sup> 2016	Korea	EMR, EMR-C	Retrospective	122	Complete resection: EMR 76.8% vs. EMR-C 94.1% ( $p=0.032$ )	Intraprocedural bleeding: EMR 0% vs. EMR-C 8.8% ( $p=0.051$ )
Zhao et al., <sup>31</sup> 2012	China	EMR, EMR-C, ESD	Retrospective	30	Complete resection: EMR 80%, EMR-C 100%, ESD 100%	Postprocedural bleeding: EMR 1.8% vs. EMR-C 2.9% ( $p>0.999$ ) Perforation: none
Lim et al., <sup>35</sup> 2019	Korea	EMR-L, ESD	Retrospective	82	Complete resection: EMR-L 95.5% vs. ESD 75.0% ( $p=0.025$ ) Lateral and vertical margins: EMR-L vs. ESD - Lateral margin distance, 1,661±849 vs. 1,514±948 µm - Vertical margin distance, 277±308 vs. 202±171 µm	
Li et al., <sup>36</sup> 2022	China	EMR-L, EMR-IUS	Retrospective	101	Complete resection: EMR-L 88.7% vs. ESMR-LUS 97.9% ( $p=0.152$ )	Immediate bleeding: EMR-L 13.2% vs. ESMR-LUS 4.2% ( $p=0.214$ ) Delayed bleeding: none Perforation: EMR-L 3.8% vs. ESMR-LUS 0% ( $p=0.496$ )

(Continued to the next page)

**Table 3.** Continued

Study	Country	Resection technique	Design	No. of patients	Results	
					<i>En bloc</i> & complete resection	Procedure time
So et al., <sup>37</sup> 2017	Korea	EMR-P	Retrospective	72	Complete resection: 93.1%	9.0±5.6 (min, mean±SD) Immediate and delayed bleeding: 8.3% and 5.6%
Chen et al., <sup>38</sup> 2016	China	EMR-P, ESD	Retrospective	61	Complete resection: EMR-P 93.9% vs. ESD 96.4% ( <i>p</i> =1.000)	EMR-P 25.7 vs. ESD 41.7 min ( <i>p</i> <0.0001) Complication: no significant difference Hospital day (day): EMR-P 4.85 vs. ESD 6.42 ( <i>p</i> <0.0001)
Kim et al., <sup>39</sup> 2021	Korea	ASEMR, EMR-C	Retrospective	86	Complete resection: ASEMR 94.1% vs. EMR-C 88.2% ( <i>p</i> =0.673)	ASEMR 3.1 vs. EMR-C 4.6 min ( <i>p</i> =0.002) 3 cases in ASEMR group vs. 1 case in EMR-C group ( <i>p</i> =0.618)
Sung et al., <sup>40</sup> 2012	Korea	EMR, 2-channel EMR ESD	Prospective	77	Complete resection: EMR 71.4%, 2-channel EMR 74.1%, ESD 100%	None
Yong et al., <sup>41</sup> 2021	Singapore	EMR, ESD	Meta-analysis	1360	Complete resection: EMR 80%, ESD 92%	Bleeding: EMR 4%, ESD 7% Perforation: EMR 1%, ESD 2%
Zheng et al., <sup>42</sup> 2021	China	m-EMR, ESD	Retrospective	98	Complete resection: m-EMR 86.1% vs. ESD 87.1% ( <i>p</i> =1.000)	Delayed bleeding: 1 case (m-EMR group)
Wang et al., <sup>44</sup> 2020	China	ESD, hybrid ESD	Retrospective	272	Complete resection: ESD 90.9% vs. hybrid ESD 94.1% ( <i>p</i> =0.641)	Postoperative bleeding: ESD 0.6% vs. hybrid ESD 2.5% ( <i>p</i> =0.313) Perforation: none
Zheng et al., <sup>45</sup> 2020	China	EMR, m-EMR	Meta-analysis	811	Complete resection (EMR vs. m-EMR): OR, 0.23; 95% CI, 0.10–0.51; <i>p</i> <0.01	No significant difference
Zhou et al., <sup>46</sup> 2014	China	EMR, m-EMR, ESD	Meta-analysis	650	Complete resection: ESD vs. EMR (RR, 0.89; 95% CI, 0.79–0.99) - m-EMR vs. EMR (RR, 0.72; 95% CI, 0.60–0.86) - ESD vs. m-EMR (RR, 1.03; 95% CI, 0.95–1.11)	Postoperative bleeding: EMR 2 cases (2/328), m-EMR 1 case (1/90), ESD 3 cases (3/209) m-EMR vs. ESD (standard mean differences: -1.37%; 95% CI, -1.99% to -0.8%) Perforation: EMR 2 cases (2/328), m-EMR 1 case (1/90), ESD 3 cases (3/209)
Pan et al., <sup>47</sup> 2018	China	m-EMR (EMR with suctioning), ESD	Meta-analysis	823	Complete resection: m-EMR 93.7% vs. ESD 84.1%; m-EMR vs. ESD (OR, 4.08; 95% CI, 2.42–6.88, <i>p</i> <0.00001) Overall recurrence rate: no significant difference (OR, 0.76; 95% CI, 0.11–5.07)	No significant difference

(Continued to the next page)

Table 3. Continued

Study	Country	Resection technique	Design	No. of patients	Results	
					En bloc & complete resection	Procedure time
Kamigaichi et al., <sup>48</sup> 2021	Japan	EMR, EMR-L, ESD	Retrospective	42	Complete resection: EMR 80%, EMR-L 100%, ESD 85.7% Vertical margin distance: EMR 189±199.1 μm, EMR-L 641.5±763.8 μm, ESD 202.8±125.4 μm	EMR 3.3±0.8, EMR-L 5.7±1.2, ESD 13.5±3.1 (min, mean±SD) No significant difference

EMR, endoscopic mucosal resection; EMR-L, EMR with a ligation device; EMR-C, EMR with a cap; EMR-P, EMR with precutting; cEMR, conventional EMR; SD, standard deviation; ESD, endoscopic submucosal dissection; ESMR-LUS, ligation-assisted endoscopic submucosal resection combined with endoscopic ultrasonography; ASEMR, anchored snare-tip EMR; m-EMR, modified EMR; OR, odds ratio; CI, confidence interval; RR, relative risk.

complete resection rate than ESD (100% vs. 85.7%) and a more distant vertical margin from the tumor in the EMR-L group than in the ESD group (vertical margin distance, 641.5±763.8 vs. 202.8±125.4 μm, EMR-L vs. ESD).<sup>48</sup> In a study comparing the clinical outcomes of EMR-L and EMR-C, the endoscopic *en bloc* resection rate was higher in the EMR-L group (100% vs. 92.9%,  $p=0.003$ ), although the complete resection rate was similar (92.5% vs. 83.3%,  $p=0.087$ , respectively).<sup>7</sup> The reason EMR-L has a higher complete resection rate than EMR-C is that when using a band, lateral and deep margins are more easily secured in EMR, where EMR-L uses a technique that resects the tumor by snaring below the band ligation. Therefore, EMR-L may be the preferable treatment method relative EMR-C, because it is a simple and reliable procedure, regardless of operator skill.

EMR with suction cannot secure the resection margin when the lesion is larger than the cap or ligation band (for tumors ≥10 mm in size), which is limited because of the short diameter of the caps fitted to colonoscopies. In contrast, EMR-P has no size limitations for resection, because it captures the lesion by fitting the snare to the precut mucosa after circumferential incision/precutting.<sup>37</sup> EMR-P has a complete resection rate that is comparable to that of EMR with suction. Several studies have reported that the complete resection rates of EMR-C, EMR-L, and EMR-P were 88.2% to 100%,<sup>30,31,39</sup> 88.7% to 100%,<sup>27-29,36</sup> and 93.1% to 93.9%,<sup>37,38</sup> respectively. ASEMR is a simple procedure that does not require a cap or ligation device. In a retrospective study, the histologic complete resection rate of ASEMR was 94.1%, which was not significantly different from that of EMR-C (88.2%).<sup>39</sup> ASEMR had a shorter procedure time than EMR-C and a similar complication rate that was not significantly different from that of EMR-C.<sup>39</sup> In this study, 11-mm and 12-mm rectal NETs were also completely resected using ASEMR with a 13-mm oval stiff snare, and their deep safety resection margins were 230 μm and 1,900 μm, respectively. Unfortunately, studies on ASEMR for rectal NETs are limited, although there are studies showing that ASEMR increases the complete resection rate and specimen size<sup>49-51</sup>; thus, the potential use of ASEMR in the future may be promising. Therefore, EMR without suctioning (EMR-P and ASEMR methods) using only a simple injector and snare is also useful for the resection of small rectal NETs <10 mm.

ESD results in high *en bloc* and complete resection rates for rectal NETs. However, ESD has the disadvantage that the technique is difficult to learn, the procedure time is long, and



the risks of bleeding and perforation are higher than those of m-EMR.<sup>27,29,40,43,45,46</sup> Yong et al.<sup>41</sup> reported a perforation rate of 2% and a bleeding rate of 7%. Incomplete resection and complications may occur if ESD is performed by an inexperienced operator. In addition, it has the disadvantage of requiring an expensive endoknife. In terms of complete resection, the effects of m-EMR and ESD are equivalent. Kim et al.<sup>29</sup> compared the complete resection rate of EMR-L with that of ESD, and no significant difference was observed (EMR-L 100%, ESD 97.7%,  $p=1.000$ ). Zhao et al.<sup>31</sup> compared the outcomes of EMR-C with ESD in a retrospective study and reported that the complete resection rates of both EMR-C and ESD were 100%. In a meta-analysis, Pan et al.<sup>47</sup> reported that EMR with suction for treating small rectal NETs ( $\leq 10$  mm) had a higher complete resection rate than ESD (OR, 4.08; 95% CI, 2.42–6.88;  $p < 0.00001$ ). Chen et al.<sup>38</sup> compared EMR-P with ESD, and the histologic complete resection rates were 93.9% and 96.4% ( $p=1.000$ ), respectively, indicating no significant difference. Nevertheless, ESD is required if the lesion is too large, suctioning is not possible due to fibrosis in the lesion, or if the snaring for EMR does not work well. In a meta-analysis including 1,360 lesions, Yong et al.<sup>41</sup> reported that ESD for rectal NETs  $> 10$  mm demonstrated a higher complete resection rate and lower vertical margin involvement than EMR.

## CONCLUSIONS

The appropriate treatment for rectal NETs should be selected in consideration of the lesion size, endoscopic characteristics, proliferative index, grade, depth of vertical involvement, lymphovascular invasion, and risk of metastasis. Moreover, the complete resection rate, complications, and experience of the center should be considered when selecting an endoscopic method. m-EMR is the most suitable resection method for rectal NETs  $< 10$  mm in size, because it is an effective and safe technique that is relatively simple and less time-consuming than ESD. ESD is required when the tumor size is larger than 10 mm, suctioning is not possible due to fibrosis in the lesion, or when the snaring for m-EMR does not work well.

## Conflicts of Interest

The authors have no potential conflicts of interest.

## Funding

None.

## Author Contributions

Conceptualization: DHB; Data curation: SMH, DHB; Formal analysis: SMH, DHB; Supervision: DHB; Writing—original draft: SMH, DHB; Writing—review & editing: SMH, DHB.

## ORCID

Seung Min Hong <https://orcid.org/0000-0002-6393-0809>  
 Dong Hoon Baek <https://orcid.org/0000-0003-1512-9475>

## REFERENCES

1. Gastrointestinal Pathology Study Group of Korean Society of Pathologists, Cho MY, Kim JM, et al. Current trends of the incidence and pathological diagnosis of gastroenteropancreatic neuroendocrine tumors (GEP-NETs) in Korea 2000-2009: multicenter study. *Cancer Res Treat* 2012;44:157–165.
2. Lim CH, Lee IS, Jun BY, et al. Incidence and clinical characteristics of gastroenteropancreatic neuroendocrine tumor in Korea: a single-center experience. *Korean J Intern Med* 2017;32:452–458.
3. Ito T, Sasano H, Tanaka M, et al. Epidemiological study of gastroenteropancreatic neuroendocrine tumors in Japan. *J Gastroenterol* 2010;45:234–243.
4. Yao JC, Hassan M, Phan A, et al. One hundred years after “carcinoid”: epidemiology of and prognostic factors for neuroendocrine tumors in 35,825 cases in the United States. *J Clin Oncol* 2008;26:3063–3072.
5. Dasari A, Shen C, Halperin D, et al. Trends in the incidence, prevalence, and survival outcomes in patients with neuroendocrine tumors in the United States. *JAMA Oncol* 2017;3:1335–1342.
6. Ito T, Igarashi H, Nakamura K, et al. Epidemiological trends of pancreatic and gastrointestinal neuroendocrine tumors in Japan: a nationwide survey analysis. *J Gastroenterol* 2015;50:58–64.
7. Lee J, Park YE, Choi JH, et al. Comparison between cap-assisted and ligation-assisted endoscopic mucosal resection for rectal neuroendocrine tumors. *Ann Gastroenterol* 2020;33:385–390.
8. Basuroy R, Haji A, Ramage JK, et al. Review article: the investigation and management of rectal neuroendocrine tumours. *Aliment Pharmacol Ther* 2016;44:332–345.
9. Delle Fave G, O’Toole D, Sundin A, et al. ENETS consensus guidelines update for gastroduodenal neuroendocrine neoplasms. *Neuroendocrinology* 2016;103:119–124.
10. Anthony LB, Strosberg JR, Klimstra DS, et al. The NANETS consen-

- sus guidelines for the diagnosis and management of gastrointestinal neuroendocrine tumors (NETs): well-differentiated nets of the distal colon and rectum. *Pancreas* 2010;39:767–774.
11. Ngamruengphong S, Kamal A, Akshintala V, et al. Prevalence of metastasis and survival of 788 patients with T1 rectal carcinoid tumors. *Gastrointest Endosc* 2019;89:602–606.
  12. Caplin M, Sundin A, Nillson O, et al. ENETS consensus guidelines for the management of patients with digestive neuroendocrine neoplasms: colorectal neuroendocrine neoplasms. *Neuroendocrinology* 2012;95:88–97.
  13. Kim GU, Kim KJ, Hong SM, et al. Clinical outcomes of rectal neuroendocrine tumors  $\leq$  10 mm following endoscopic resection. *Endoscopy* 2013;45:1018–1023.
  14. Maione F, Chini A, Milone M, et al. Diagnosis and management of rectal neuroendocrine tumors (NETs). *Diagnostics (Basel)* 2021;11:771.
  15. de Mestier L, Brixi H, Gincul R, et al. Updating the management of patients with rectal neuroendocrine tumors. *Endoscopy* 2013;45:1039–1046.
  16. He L, Deng T, Luo H. Efficacy and safety of endoscopic resection therapies for rectal carcinoid tumors: a meta-analysis. *Yonsei Med J* 2015;56:72–81.
  17. Ramage JK, De Herder WW, Delle Fave G, et al. ENETS consensus guidelines update for colorectal neuroendocrine neoplasms. *Neuroendocrinology* 2016;103:139–143.
  18. Wang AY, Ahmad NA. Rectal carcinoids. *Curr Opin Gastroenterol* 2006;22:529–535.
  19. Lee SP, Sung IK, Kim JH, et al. The effect of preceding biopsy on complete endoscopic resection in rectal carcinoid tumor. *J Korean Med Sci* 2014;29:512–518.
  20. Judd S, Nangia S, Levi E, et al. Rectal carcinoid tumor: a delayed localized recurrence 23 years after endoscopic resection. *Endoscopy* 2014;46 Suppl 1 UCTN:E555–E556.
  21. Onozato Y, Kakizaki S, Iizuka H, et al. Endoscopic treatment of rectal carcinoid tumors. *Dis Colon Rectum* 2010;53:169–176.
  22. Son HJ, Sohn DK, Hong CW, et al. Factors associated with complete local excision of small rectal carcinoid tumor. *Int J Colorectal Dis* 2013;28:57–61.
  23. Zhang HP, Wu W, Yang S, et al. Endoscopic treatments for rectal neuroendocrine tumors smaller than 16mm: a meta-analysis. *Scand J Gastroenterol* 2016;51:1345–1353.
  24. Ono A, Fujii T, Saito Y, et al. Endoscopic submucosal resection of rectal carcinoid tumors with a ligation device. *Gastrointest Endosc* 2003;57:583–587.
  25. Soga J. Carcinoids of the rectum: an evaluation of 1271 reported cases. *Surg Today* 1997;27:112–119.
  26. Matsui K, Iwase T, Kitagawa M. Small, polypoid-appearing carcinoid tumors of the rectum: clinicopathologic study of 16 cases and effectiveness of endoscopic treatment. *Am J Gastroenterol* 1993;88:1949–1953.
  27. Lee HS, Moon HS, Kwon IS, et al. Comparison of conventional and modified endoscopic mucosal resection methods for the treatment of rectal neuroendocrine tumors. *Surg Endosc* 2021;35:6055–6065.
  28. Im YC, Jung SW, Cha HJ, et al. The effectiveness of endoscopic submucosal resection with a ligation device for small rectal carcinoid tumors: focused on previously biopsied tumors. *Surg Laparosc Endosc Percutan Tech* 2014;24:264–269.
  29. Kim KM, Eo SJ, Shim SG, et al. Treatment outcomes according to endoscopic treatment modalities for rectal carcinoid tumors. *Clin Res Hepatol Gastroenterol* 2013;37:275–282.
  30. Yang DH, Park Y, Park SH, et al. Cap-assisted EMR for rectal neuroendocrine tumors: comparisons with conventional EMR and endoscopic submucosal dissection (with videos). *Gastrointest Endosc* 2016;83:1015–1022.
  31. Zhao ZF, Zhang N, Ma SR, et al. A comparative study on endoscopy treatment in rectal carcinoid tumors. *Surg Laparosc Endosc Percutan Tech* 2012;22:260–263.
  32. Oshitani N, Hamasaki N, Sawa Y, et al. Endoscopic resection of small rectal carcinoid tumours using an aspiration method with a transparent overcap. *J Int Med Res* 2000;28:241–246.
  33. Park SB, Kim HW, Kang DH, et al. Advantage of endoscopic mucosal resection with a cap for rectal neuroendocrine tumors. *World J Gastroenterol* 2015;21:9387–9393.
  34. Berkelhammer C, Jasper I, Kirvaitis E, et al. “Band-snare” resection of small rectal carcinoid tumors. *Gastrointest Endosc* 1999;50:582–585.
  35. Lim HK, Lee SJ, Baek DH, et al. Resectability of rectal neuroendocrine tumors using endoscopic mucosal resection with a ligation band device and endoscopic submucosal dissection. *Gastroenterol Res Pract* 2019;2019:8425157.
  36. Li D, Xie J, Hong D, et al. Efficacy and safety of ligation-assisted endoscopic submucosal resection combined with endoscopic ultrasonography for treatment of rectal neuroendocrine tumors. *Scand J Gastroenterol* 2022 Feb 2 [Epub]. <https://doi.org/10.1080/00365521.2022.2033828>.
  37. So H, Yoo SH, Han S, et al. Efficacy of precut endoscopic mucosal resection for treatment of rectal neuroendocrine tumors. *Clin Endosc* 2017;50:585–591.
  38. Chen R, Liu X, Sun S, et al. Comparison of endoscopic mucosal resection with circumferential incision and endoscopic submucosal dissection for rectal carcinoid tumor. *Surg Laparosc Endosc Percutan Tech* 2019;29:260–263.

- cutan Tech 2016;26:e56–e61.
39. Kim J, Kim J, Oh EH, et al. Anchoring the snare tip is a feasible endoscopic mucosal resection method for small rectal neuroendocrine tumors. *Sci Rep* 2021;11:12918.
  40. Sung HY, Kim SW, Kang WK, et al. Long-term prognosis of an endoscopically treated rectal neuroendocrine tumor: 10-year experience in a single institution. *Eur J Gastroenterol Hepatol* 2012;24:978–983.
  41. Yong JN, Lim XC, Nistala KR, et al. Endoscopic submucosal dissection versus endoscopic mucosal resection for rectal carcinoid tumor: a meta-analysis and meta-regression with single-arm analysis. *J Dig Dis* 2021;22:562–571.
  42. Zheng Y, Guo K, Zeng R, et al. Prognosis of rectal neuroendocrine tumors after endoscopic resection: a single-center retrospective study. *J Gastrointest Oncol* 2021;12:2763–2774.
  43. Wang XY, Chai NL, Linghu EQ, et al. The outcomes of modified endoscopic mucosal resection and endoscopic submucosal dissection for the treatment of rectal neuroendocrine tumors and the value of endoscopic morphology classification in endoscopic resection. *BMC Gastroenterol* 2020;20:200.
  44. Wang XY, Chai NL, Linghu EQ, et al. Efficacy and safety of hybrid endoscopic submucosal dissection compared with endoscopic submucosal dissection for rectal neuroendocrine tumors and risk factors associated with incomplete endoscopic resection. *Ann Transl Med* 2020;8:368.
  45. Zheng JC, Zheng K, Zhao S, et al. Efficacy and safety of modified endoscopic mucosal resection for rectal neuroendocrine tumors: a meta-analysis. *Z Gastroenterol* 2020;58:137–145.
  46. Zhou X, Xie H, Xie L, et al. Endoscopic resection therapies for rectal neuroendocrine tumors: a systematic review and meta-analysis. *J Gastroenterol Hepatol* 2014;29:259–268.
  47. Pan J, Zhang X, Shi Y, et al. Endoscopic mucosal resection with suction vs. endoscopic submucosal dissection for small rectal neuroendocrine tumors: a meta-analysis. *Scand J Gastroenterol* 2018; 53:1139–1145.
  48. Kamigaichi Y, Yamashita K, Oka S, et al. Clinical outcomes of endoscopic resection for rectal neuroendocrine tumors: advantages of endoscopic submucosal resection with a ligation device compared to conventional EMR and ESD. *DEN Open* 2021;2:e35.
  49. Noh SM, Kim JY, Park JC, et al. Tip-in versus conventional endoscopic mucosal resection for flat colorectal neoplasia 10 mm or larger in size. *Int J Colorectal Dis* 2020;35:1283–1290.
  50. Pioche M, Wallenhorst T, Lepetit H, et al. Endoscopic mucosal resection with anchoring of the snare tip: multicenter retrospective evaluation of effectiveness and safety. *Endosc Int Open* 2019;7:E1496–E1502.
  51. Jacques J, Legros R, Charissoux A, et al. Anchoring the snare tip by means of a small incision facilitates en bloc endoscopic mucosal resection and increases the specimen size. *Endoscopy* 2017;49(S 01):E39–E41.