

Intralesional steroid infusion using a spray tube to prevent stenosis after endoscopic submucosal dissection of esophageal cancer

Atsushi Goto¹, Takeshi Okamoto², Ryo Ogawa¹, Kouichi Hamabe¹, Shinichi Hashimoto¹, Jun Nishikawa³, Taro Takami¹

¹Department of Gastroenterology and Hepatology, Yamaguchi University Graduate School of Medicine, Ube; ²Department of Gastroenterology and Hepatology, Yamaguchi Prefectural Grand Medical Center, Hofu; ³Faculty of Laboratory Science, Yamaguchi University Graduate School of Medicine, Ube, Japan

Background/Aims: Intralesional steroid injections have been administered as prophylaxis for stenosis after esophageal endoscopic submucosal dissection. However, this method carries a risk of potential complications such as perforation because a fine needle is used to directly puncture the postoperative ulcer. We devised a new method of steroid intralesional infusion using a spray tube and evaluated its efficacy and safety.

Methods: Intralesional steroid infusion using a spray tube was performed on 27 patients who underwent endoscopic submucosal dissection for superficial esophageal cancer with three-quarters or more of the lumen circumference resected. The presence or absence of stenosis, complications, and the number of endoscopic balloon dilations (EBDs) performed were evaluated after treatment.

Results: Although stenosis was not observed in 22 of the 27 patients, five patients had stenosis and dysphagia requiring EBD. The stenosis in these five patients was relieved after four EBDs. No complications related to intralesional steroid infusion using the spray tube were observed.

Conclusions: Intralesional steroid infusion using a spray tube is a simple and safe technique that is adequately effective in preventing stenosis (clinical trial number, UMIN000037567).

Keywords: Endoscopic submucosal dissection; Esophageal cancer; Intralesional steroid infusion; Spray tube; Stenosis

INTRODUCTION

Endoscopic submucosal dissection (ESD) for superficial esophageal cancer allows for *en bloc* resection of lesions of almost any size, contributing to its widespread use. However, postoperative stenosis of the esophagus can be a potential complication after

wide resection using ESD. This condition is particularly likely to occur in resections involving more than three-quarters of the lumen.¹ Severe stenosis requires frequent endoscopic balloon dilation (EBD), leading to complications and a significant decrease in quality of life.²

Intralesional steroid injection for post-ESD ulcers^{3,4} and oral steroids⁵ have been reported to be effective as prophylactic treatments for stenosis. However, fatal complications such as brain abscesses have been reported with prolonged use of oral steroids.⁶ The method of steroid injection is technically difficult and carries risks of perforation, drug leakage outside the esophageal wall, and abscess formation^{7,8} because a fine needle is used to directly puncture the postoperative ulcer. We devised an intralesional steroid infusion method using a spray tube and evaluated its efficacy and safety in a case series study.

Received: October 24, 2021 **Revised:** December 11, 2021

Accepted: December 23, 2021

Correspondence: Atsushi Goto

Department of Gastroenterology and Hepatology, Yamaguchi University Graduate School of Medicine, Minami-kogushi 1-1-1, Ube, Yamaguchi 755-8505, Japan

E-mail: agoto@yamaguchi-u.ac.jp

© This is an Open Access article distributed under the terms of the Creative Commons Attribution Non-Commercial License (<http://creativecommons.org/licenses/by-nc/4.0/>) which permits unrestricted non-commercial use, distribution, and reproduction in any medium, provided the original work is properly cited.

METHODS

Patients

This study included patients who underwent ESD for superficial esophageal cancer at Yamaguchi University Hospital between November 2018 and May 2021 and had a mucosal defect involving more than three-quarters of the lumen after resection. When a lesion with a tumor diameter >5 cm was resected in its entire circumference, a combination of steroid injection and oral steroids was deemed necessary, and the patient was excluded from the study.⁹ Patients who underwent additional surgical resections after ESD were also excluded because of their need for rapid treatment.

Procedure

Immediately after resection of the lesion, intralesional steroid infusion using a spray tube (fine jet spraying type; Top Co., Tokyo, Japan) (Fig. 1) was performed, in which 40 mg of triamcinolone acetonide diluted in 20 mL of saline was locally infused (the product was not labeled for this use). By gently pressing the spray tube toward the base of the ulcer, 0.5 mL of the solution

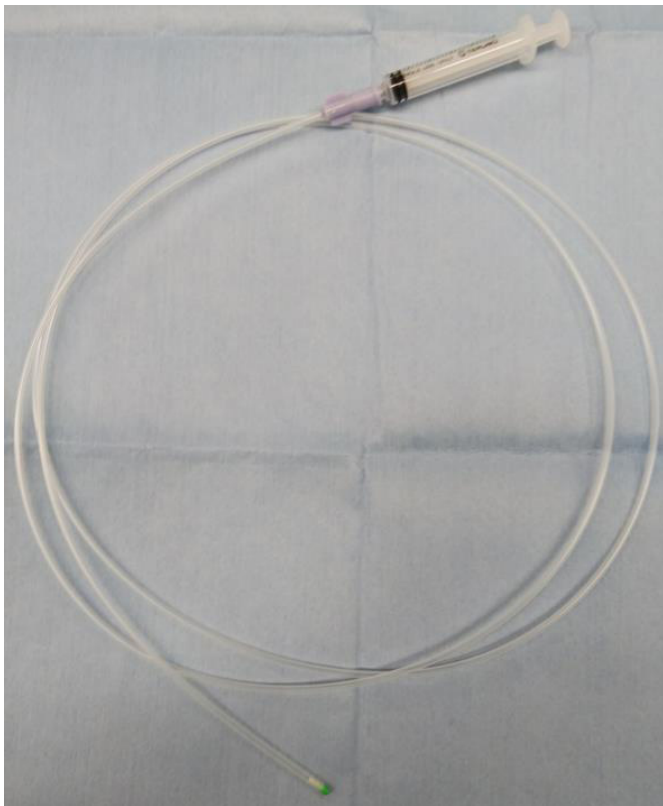


Fig. 1. Spray tube (fine jet spraying type; Top Co., Tokyo, Japan).

was infused with a 2.5-mL syringe. A white, cloudy bulge was formed when the triamcinolone acetonide solution was infused into the remaining submucosal layer. Triamcinolone acetonide was used in the range of 40–80 mg, depending on the size of the ulcer, and infusions were performed to cover the entire ulcer. The details of the procedure are shown in Figure 2 and Supplementary Video 1.

Outcomes

Endoscopic examination was performed before treatment, and follow-up examinations were performed 1 week, 1 month, and 2 months after treatment to test scope passage. The dysphagia score (on a scale of 0–5) was assessed at the same time as follows: 0, can eat a normal diet; 1, can swallow some solid foods; 2, can swallow only semi-solid foods; 3, can swallow liquids only; and 4, cannot swallow anything.¹⁰ Stenosis was determined if an upper gastrointestinal endoscope (GIF-H290; Olympus Medical System Co., Tokyo, Japan) with an 8.9-mm tip diameter could not be passed through the lesion after ESD or if the dysphagia score increased by 1 point or more compared to the pretreatment score. EBD was performed if stenosis was determined. The EBD procedure was performed until the endoscope could

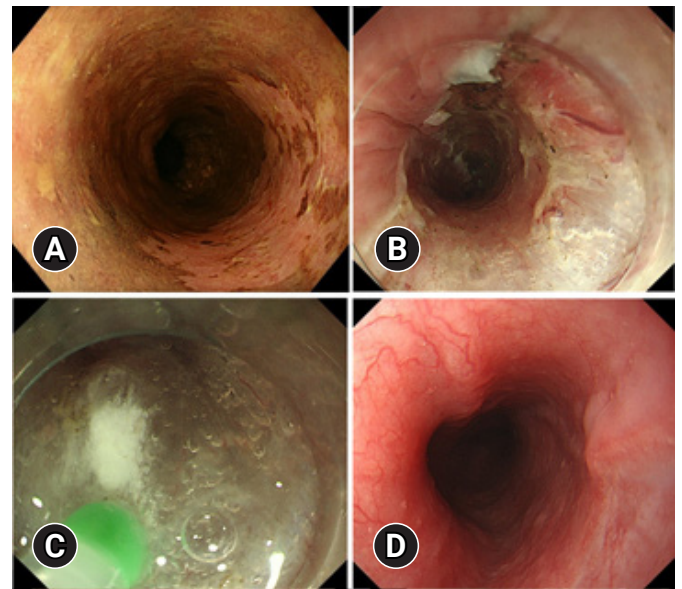


Fig. 2. (A) A patient with early esophageal cancer in the upper esophagus (patient no. 22 in Table 2). (B) Sub-circumferential resection was performed by endoscopic submucosal dissection. (C) Immediately after resection of the lesion, intralesional steroid infusion using a spray tube was performed. (D) The resected surface was completely re-epithelialized without stenosis 2 months after endoscopic submucosal dissection.

be passed and the dysphagia was improved, and the number of EBDs performed until the stenosis was relieved was recorded.

Complications of ESD such as bleeding, perforation, and mediastinal abscess formation were evaluated based on endoscopic findings and clinical symptoms at the time of treatment and 1 week, 1 month, and 2 months after treatment.

Statistical analysis

Quantitative variables are presented as the median and range, and qualitative variables are presented as frequencies and percentages.

Ethical statements

This study conformed to the provisions of the Declaration of Helsinki in 1995 and was approved by the ethics committee of Yamaguchi University Hospital (No: H30-111-2). Informed consent was obtained from all the patients prior to ESD.

RESULTS

Twenty-seven patients underwent intralesional steroid infusion with a spray tube after *en bloc* resection by ESD for superficial esophageal cancer. Twenty-six patients underwent sub-circumferential resection, and one patient underwent circumferential resection. **Table 1** shows the clinicopathological characteristics of the patients. The intralesional steroid infusion required an

average time of 4.0±0.7 minutes.

Table 2 shows the posttreatment course of each patient. Among the 27 patients, 22 (81.5%) had a favorable outcome without stenosis. Stenosis was identified in five patients (18.5%), and EBD was performed. After a maximum of four EBD procedures, the scope could be passed, and the dysphagia symptoms improved in all patients. Only one patient had post-ESD bleeding, and no complications related to intralesional steroid infusion were observed.

DISCUSSION

Intralesional steroid injection is an effective method for preventing stenosis after extensive resection via esophageal ESD. Hashimoto et al.³ reported that when triamcinolone acetonide was injected locally for 3 days for resections involving more than three-quarters of the lumen, the rate of stenosis was 19%. Hanaoka et al.⁴ reported that when 100 mg of triamcinolone acetonide was injected only once immediately after ESD for resection involving more than three-quarters but less than the entire circumference of the lumen, the rate of stenosis was 10%. The rate of stenosis was 18.5% (5/27) with our intralesional steroid infusion method, which was not inferior to that reported in previous studies. None of the patients suffered refractory stenosis. The symptoms of stenosis in the five patients with stenosis were relieved and did not recur after a maximum of four EBD procedures.

Serious complications associated with steroid injections have been reported. In animal models, when triamcinolone acetonide was injected into the muscle layer of a post-ESD artificial ulcer, healing was prolonged, and perforations and abscess formation involving the lungs and aorta were reported.¹¹ Delayed perforation and abscess formation after steroid injection have also been reported in patients.⁷ These injection methods require needle insertion into the very thin, remaining submucosal layer after ESD. It takes great care to avoid penetrating the muscular layers, and the mental stress on the endoscopist is enormous. In contrast, with the spray tube method, intralesional steroid infusion can be performed by lightly pressing the spray tube on the ulcer bed. Because a white, cloudy bulge can be recognized when triamcinolone acetonide solution is infused into the remaining submucosal layer, our method may be effective in infusing sufficient triamcinolone acetonide into this layer. The risk of injection into the muscle layer is low; thus, no complications related to this technique were recognized in this study.

Table 1. Clinicopathological characteristics of the patients

Characteristic	Value
Age (yr)	72.3 (55–86)
Sex (male:female)	20:7
Tumor location	
Upper thoracic	2 (7.4)
Middle thoracic	19 (70.4)
Lower thoracic	6 (22.2)
Tumor diameter (mm)	35.8 (18–60)
<i>En bloc</i> resection	27 (100)
Circumference	
Sub-circumferential	26 (96.3)
Circumferential	1 (3.7)
Depth of tumor invasion	
Epithelium/lamina propria mucosa	16 (59.3)
Muscularis mucosa/SM1	8 (29.6)
SM2	3 (11.1)

Values are presenter as mean (range) or number (%). SM, submucosa.

Table 2. Posttreatment course of the patients

No.	Age (yr)	Sex	Location	Tumor diameter (mm)	Resection type	Amount of TA (mg)	Procedure time for steroid infusion (min)	Worsening of dysphagia score	Scope passability	Stenosis	EBD (time)
1	86	F	Mid	60	Sub-circumferential	80	4	-	Possible	-	0
2	78	M	Lower	60	Sub-circumferential	80	5	-	Possible	-	0
3	76	F	Mid	48	Sub-circumferential	80	4	+	Impossible	+	1
4	71	M	Mid	45	Sub-circumferential	80	3.5	-	Possible	-	0
5	58	M	Mid	45	Sub-circumferential	80	4	-	Possible	-	0
6	78	M	Lower	45	Sub-circumferential	80	3.5	-	Possible	-	0
7	70	M	Mid	44	Sub-circumferential	80	3.5	+	Impossible	+	1
8	82	M	Lower	42	Sub-circumferential	80	4	+	Impossible	+	4
9	60	M	Mid	42	Sub-circumferential	80	4	-	Possible	-	0
10	75	M	Mid	40	Sub-circumferential	80	3	-	Possible	-	0
11	55	M	Lower	35	Circumferential	80	4	-	Impossible	+	4
12	84	F	Mid	35	Sub-circumferential	80	3.5	-	Impossible	+	4
13	65	M	Mid	35	Sub-circumferential	80	5	-	Possible	-	0
14	78	M	Mid	35	Sub-circumferential	80	4.5	-	Possible	-	0
15	72	M	Mid	35	Sub-circumferential	80	5	-	Possible	-	0
16	71	F	Mid	34	Sub-circumferential	80	5	-	Possible	-	0
17	80	M	Lower	33	Sub-circumferential	80	5	-	Possible	-	0
18	72	M	Mid	32	Sub-circumferential	80	4.5	-	Possible	-	0
19	65	F	Mid	30	Sub-circumferential	80	4	-	Possible	-	0
20	78	M	Mid	30	Sub-circumferential	80	5	-	Possible	-	0
21	69	M	Mid	29	Sub-circumferential	40	3	-	Possible	-	0
22	61	F	Upper	28	Sub-circumferential	80	3.5	-	Possible	-	0
23	61	M	Mid	25	Sub-circumferential	40	3	-	Possible	-	0
24	74	F	Mid	23	Sub-circumferential	80	4.5	-	Possible	-	0
25	78	M	Upper	20	Sub-circumferential	40	3.5	-	Possible	-	0
26	75	M	Lower	18	Sub-circumferential	40	3	-	Possible	-	0
27	81	M	Mid	18	Sub-circumferential	40	4.5	-	Possible	-	0

TA, triamcinolone acetonide; EBD, endoscopic balloon dilation.

We believe that intralesional steroid infusion is easier and safer than direct injection.

Pathological diagnosis after ESD showed that 11 patients had an invasion depth deeper than the muscularis mucosa, which should be considered for additional treatment. Ten patients did not want to undergo additional treatment because of old age or comorbidities. One patient was treated with chemoradiation after the postoperative stenosis resolved.

The mean tumor diameter in patients with and without stenosis was 40.8 ± 5.7 mm and 34.6 ± 11.6 mm, respectively. Although the difference was not statistically significant, the tumor size tended to be larger in patients with stenosis. We excluded patients with a tumor diameter >5 cm in whom the entire circumference was resected; however, tumors with a diameter

close to 5 cm also require attention.

In this study, we performed intralesional steroid infusion only once after ESD, and the average duration of the procedure was 4 minutes, making our technique a time-saving procedure. Another non-needle method, which involves filling the esophagus with a steroid solution, has been reported to have a prophylactic effect on stenosis.¹² However, this procedure had to be performed at least twice. Moreover, stenosis developed in 45.5% of patients and required one to 13 repeat procedures.

The limitation of this study is that it was a single-center study that did not compare the present technique with conventional needle-based methods. Future randomized studies comparing these two methods are needed. Moreover, this study evaluated patients only treated with steroid infusion, and the effect on pa-

tients requiring combination therapy with oral steroids was not evaluated.

In conclusion, intralesional steroid infusion using a spray tube is a simple and safe technique and may have a comparable effect to that of the conventional injection method for preventing stenosis.

Supplementary Material

Supplementary Video 1. Intralesional steroid infusion procedure using a spray tube (patient no. 5 in Table 2) (<https://doi.org/10.5946/ce.2021.262.v001>).

Supplementary materials related to this article can be found online at <https://doi.org/10.5946/ce.2021.262>.

Conflicts of Interest

The authors have no potential conflicts of interest.

Funding

None.

Author Contributions

Conceptualization: AG, TO; Data curation: KH, SH; Formal analysis: RO; Supervision: TT; Writing-original draft: all authors.

ORCID

Atsushi Goto	https://orcid.org/0000-0002-4227-2720
Takeshi Okamoto	https://orcid.org/0000-0003-2676-4167
Ryo Ogawa	https://orcid.org/0000-0002-6882-9769
Kouichi Hamabe	https://orcid.org/0000-0003-2684-5477
Shinichi Hashimoto	https://orcid.org/0000-0001-5763-2920
Jun Nishikawa	https://orcid.org/0000-0002-6695-9754
Taro Takami	https://orcid.org/0000-0002-6689-4989

REFERENCES

1. Katada C, Muto M, Manabe T, et al. Esophageal stenosis after endoscopic mucosal resection of superficial esophageal lesions. *Gastrointest Endosc* 2003;57:165–169.
2. Hagel AF, Naegel A, Dauth W, et al. Perforation during esophageal dilatation: a 10-year experience. *J Gastrointest Liver Dis* 2013;22:385–389.
3. Hashimoto S, Kobayashi M, Takeuchi M, et al. The efficacy of endoscopic triamcinolone injection for the prevention of esophageal stricture after endoscopic submucosal dissection. *Gastrointest Endosc* 2011;74:1389–1393.
4. Hanaoka N, Ishihara R, Takeuchi Y, et al. Intralesional steroid injection to prevent stricture after endoscopic submucosal dissection for esophageal cancer: a controlled prospective study. *Endoscopy* 2012;44:1007–1011.
5. Yamaguchi N, Isomoto H, Nakayama T, et al. Usefulness of oral prednisolone in the treatment of esophageal stricture after endoscopic submucosal dissection for superficial esophageal squamous cell carcinoma. *Gastrointest Endosc* 2011;73:1115–1121.
6. Ishida T, Morita Y, Hoshi N, et al. Disseminated nocardiosis during systemic steroid therapy for the prevention of esophageal stricture after endoscopic submucosal dissection. *Dig Endosc* 2015;27:388–391.
7. Yamashina T, Uedo N, Fujii M, et al. Delayed perforation after intralesional triamcinolone injection for esophageal stricture following endoscopic submucosal dissection. *Endoscopy* 2013;45 Suppl 2 UCTN:E92.
8. Rajan E, Gostout C, Feitoza A, et al. Widespread endoscopic mucosal resection of the esophagus with strategies for stricture prevention: a preclinical study. *Endoscopy* 2005;37:1111–1115.
9. Kadota T, Yoda Y, Hori K, et al. Prophylactic steroid administration against strictures is not enough for mucosal defects involving the entire circumference of the esophageal lumen after esophageal endoscopic submucosal dissection (ESD). *Esophagus* 2020;17:440–447.
10. Knyrim K, Wagner HJ, Bethge N, et al. A controlled trial of an expansile metal stent for palliation of esophageal obstruction due to inoperable cancer. *N Engl J Med* 1993;329:1302–1307.
11. Yamashita S, Kato M, Fujimoto A, et al. Inadequate steroid injection after esophageal ESD might cause mural necrosis. *Endosc Int Open* 2019;7:E115–E121.
12. Shibagaki K, Ishimura N, Oshima N, et al. Esophageal triamcinolone acetone-filling method: a novel procedure to prevent stenosis after extensive esophageal endoscopic submucosal dissection (with videos). *Gastrointest Endosc* 2018;87:380–389.