



Open Access

Confocal Laser Endomicroscopy in the Diagnosis of Biliary and Pancreatic Disorders: A Systematic Analysis

Do Han Kim¹, Somashekar G. Krishna², Emmanuel Coronel³, Paul T. Kröner⁴, Herbert C. Wolfsen⁴, Michael B. Wallace⁴, and Juan E. Corral⁵

¹Universidad Francisco Marroquin, School of Medicine, Guatemala City, Guatemala, ²Division of Gastroenterology, Hepatology, and Nutrition, The Ohio State University Wexner Medical Center, Columbus, Ohio, ³Division of Gastroenterology and Hepatology, MD Anderson Cancer Center, Houston, Texas, ⁴Division of Gastroenterology and Hepatology, Mayo Clinic, Jacksonville, Florida, ⁵Division of Gastroenterology and Hepatology, Presbyterian Health Services, Albuquerque, New Mexico, USA.

Background/Aims: Endoscopic visualization of the microscopic anatomy can facilitate the real-time diagnosis of pancreatobiliary disorders and provide guidance for treatment. This study aimed to review the technique, image classification, and diagnostic performance of confocal laser endomicroscopy (CLE).

Methods: We conducted a systematic review of CLE in pancreatic and biliary ducts of humans, and have provided a narrative of the technique, image classification, diagnostic performance, ongoing research, and limitations.

Results: Probe-based CLE differentiates malignant from benign biliary strictures (sensitivity, $\geq 89\%$; specificity, $\geq 61\%$). Needle-based CLE differentiates mucinous from non-mucinous pancreatic cysts (sensitivity, 59%; specificity, $\geq 94\%$) and identifies dysplasia. Pancreatitis may develop in 2-7% of pancreatic cyst cases. Needle-based CLE has potential applications in adenocarcinoma, neuroendocrine tumors, and pancreatitis (chronic or autoimmune). Costs, catheter lifespan, endoscopist training, and interobserver variability are challenges for routine utilization.

Conclusions: CLE reveals microscopic pancreatobiliary system anatomy with adequate specificity and sensitivity. Reducing costs and simplifying image interpretation will promote utilization by advanced endoscopists. **Clin Endosc 2022;55:197-207**

Key Words: Biliary stricture; Cholangiocarcinoma; Confocal microscopy; Endoscopy; Pancreatic cyst

INTRODUCTION

Endomicroscopy refers to the use of different imaging technologies to microscopically evaluate the epithelium in real time. Electronic spectral enhancement and topical dyes are used to evaluate mucosal changes and identify superficial gastrointestinal neoplasia. Technologies such as narrow band imaging (Olympus Medical Systems Corp., Tokyo, Japan), iScan

(Pentax Inc., Tokyo, Japan), and blue light/blue laser imaging (Fujinon Intelligent Chromo Endoscopy, Fujinon, Saitama, Japan) help separate the areas of metaplasia, dysplasia, and early neoplasia from normal mucosa in the gastroesophageal junction, stomach, and colon.¹ With a higher magnification power, optical coherence tomography and volumetric laser endomicroscopy provide images of different histologic layers and cellular changes of the gastrointestinal epithelium and are useful for evaluating Barrett's esophagus.² The diameters of the biliary and pancreatic ducts in normal conditions are significantly smaller than the rest of the gastrointestinal tract, making the evaluation of the biliary epithelium and pancreatic parenchyma particularly challenging using conventional optical devices.

Confocal laser endomicroscopy (CLE) uses intravenous fluorophore, fluorescein, and a fiber-optic confocal laser to achieve higher magnification and reveal cellular and subcellular structures in the epithelium (Fig. 1). Multiple applications

Received: February 22, 2021 Revised: April 15, 2021

Accepted: May 10, 2021

Correspondence: Juan E. Corral

Division of Gastroenterology and Hepatology, Presbyterian Healthcare Services, 1100 Lead Avenue SE, Albuquerque, NM 87106, USA

Tel: +1-505-224-7000, Fax: +1-505-224-7292, E-mail: jcorralhu@pchs.org

ORCID: <https://orcid.org/0000-0002-8821-4534>

© This is an Open Access article distributed under the terms of the Creative Commons Attribution Non-Commercial License (<http://creativecommons.org/licenses/by-nc/3.0>) which permits unrestricted non-commercial use, distribution, and reproduction in any medium, provided the original work is properly cited.

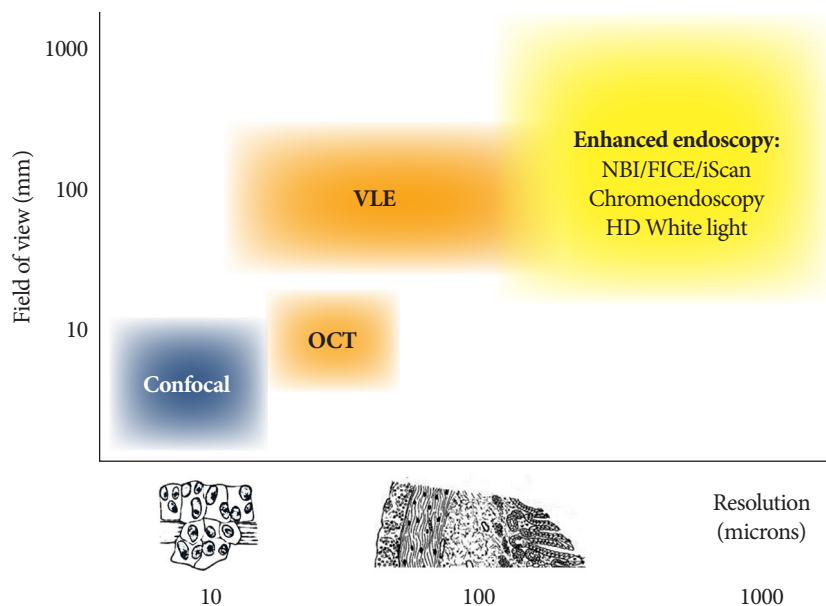


Fig. 1. Comparison of available endomicroscopy imaging technologies. FICE, Fujinon Intelligent Chromo Endoscopy (Fujinon, Saitama, Japan); HD, high definition; iScan (Pentax Inc., Tokyo, Japan); NBI, narrow band imaging (Olympus Medical Systems Corp., Tokyo, Japan); OCT, optical coherence tomography; VLE, volumetric laser endomicroscopy. Courtesy of Dr. Wallace MB.

of CLE have been described across gastrointestinal luminal neoplasia, including increasing the detection of dysplasia in Barrett's esophagus, categorizing early gastric cancer, identifying dysplasia associated with inflammatory bowel disease, and revealing early cancer in colon polyps or surgical margins.³⁻⁶ CLE has also been evaluated in benign conditions, including identifying mucosal atrophy in gastritis, measuring vascular integrity in celiac disease, determining mucosal permeability in inflammatory bowel disease, and visualizing inflammation in irritable bowel syndrome.⁷⁻¹¹

Small-caliber CLE catheters are introduced into the biliary and pancreatic structures through endoscopic retrograde cholangiopancreatography (ERCP) or endoscopic ultrasonography (EUS). Malignant biliary strictures are traditionally evaluated using a combination of cross-sectional imaging, cytology brushings, and biopsies with micro forceps. Pancreatic cysts are characterized using a combination of cross-sectional imaging, EUS, and fluid analysis. However, this approach has some limitations, particularly in chronic inflammatory conditions such as primary sclerosing cholangitis.^{12,13} Over the last 20 years, interest has grown in using CLE imaging during endoscopy to facilitate evaluation of the biliary and pancreatic structures. This structured review aims to provide a clinical assessment of current applications of CLE in biliary and pancreatic disorders, summarize diagnostic performance in both areas, and present the most recent criteria for image interpretation.

METHODS

The literature databases PubMed (US National Library of Medicine), Cochrane (The Cochrane Collaboration), and ClinicalTrials.gov (US National Institutes of Health) were reviewed. The search was performed in PubMed using two queries: Confocal microscopy (Medical Subject Headings [MeSH] term) OR Confocal laser scanning microscopy (MeSH) AND Endoscopy (non-MeSH) AND Pancreas (non-MeSH); and Confocal microscopy (MeSH) OR Confocal laser scanning microscopy (MeSH) AND Endoscopy (non-MeSH) and Biliary (non-MeSH). The selected studies were limited to those including humans and those in the English language published through March 15, 2021. Analogous strategies were used to search the other two databases.

Two investigators, Do Han Kim and Paul T. Kröner, independently reviewed the titles and abstracts of the retrieved articles. For journal manuscripts, full-text articles were retrieved for further review. Titles that could not be associated with an abstract were excluded from review. All studies and case reports that addressed the CLE technique, image interpretation or classification, accuracy estimations (i.e., specificity and sensitivity), interobserver agreement, and consensus meetings were retrieved and reviewed individually. Studies that used biomarkers or imaging tests other than CLE (e.g., EUS, cytology) as the main diagnostic tool were removed. If two or more manuscripts studied the same patient population, the one pub-

lished most recently or with the largest sample was selected. If two manuscripts provided complementary information (e.g., different years), both were included. If there was any discrepancy about whether a study should be included, a third investigator (Juan E. Corral) determined adequacy. When needed, the corresponding authors of the studies were contacted for additional information.

The following information was abstracted from each article: year of publication, first author, sample size, comparison groups, diagnostic accuracy, and adverse events (e.g., pancreatitis). Using the available information, we analyzed sensitivity, specificity, and diagnostic accuracy using conventional 2×2 tables.

We provide individual estimates of accuracy and opted not to perform a meta-analysis to illustrate the diversity of applications across different pathologies and patient subgroups. Furthermore, six meta-analyses have already been published on this topic, and their relevant results are included here.^{14–19}

RESULTS

The initial literature search retrieved 47 publications in the biliary group and 25 publications in the pancreas group. A Cochrane search retrieved CLE applications in dermatology (i.e., evaluation of melanoma and basal cell carcinoma) and ophthalmology (i.e., evaluation of the optic nerve and glaucoma) but no applications in gastroenterology. A review of ClinicalTrials.gov identified 20 trials using CLE in the biliary ducts and 10 trials using CLE in the pancreas.

After the exclusion of 14 irrelevant publications and three duplicate publications (overlapping pancreatic and biliary duct evaluation), 55 full-text articles were subjected to further evaluation. Numbers in Fig. 2, may differ considering that review articles covered both pancreatic and biliary, studies found in Clinical trials.gov not included. No studies were excluded for having a small sample size (Fig. 2).

CLE technique

Thin confocal laser probes feature a small enough diameter

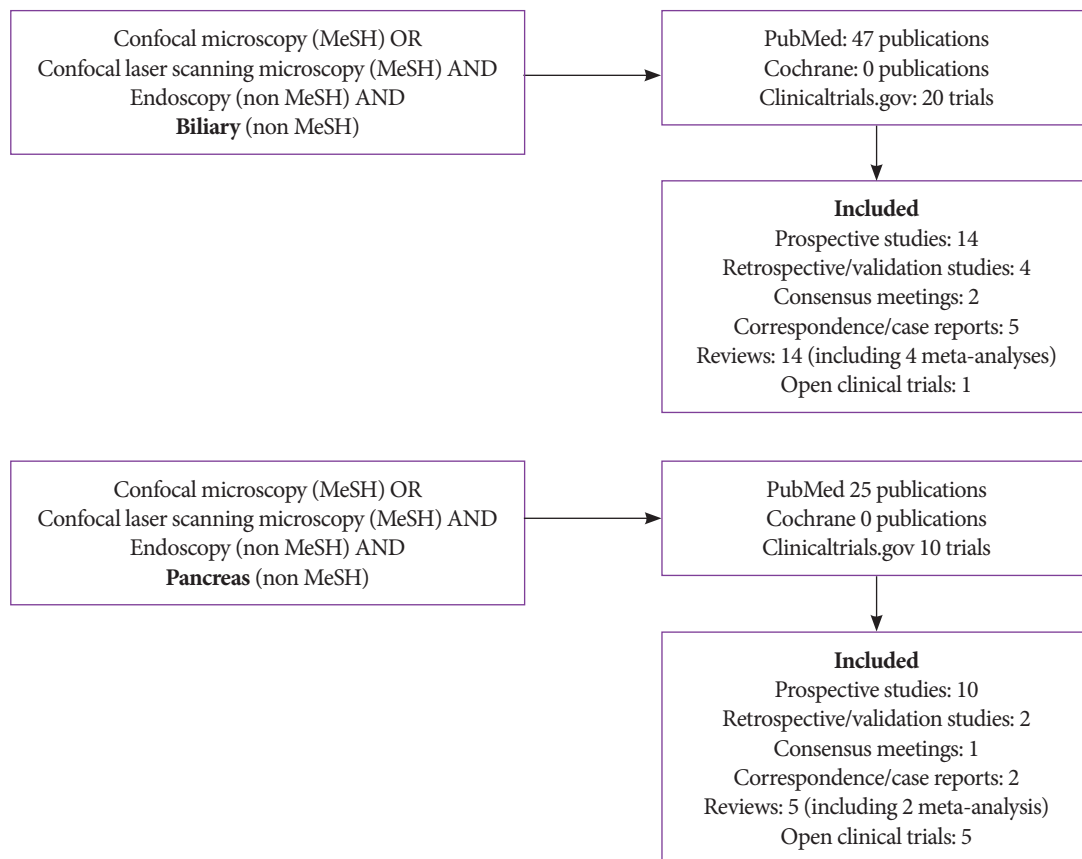


Fig. 2. Literature review flowchart. MeSH, medical subject headings used by the National Library of Medicine.

to allow their insertion through the working channel of conventional endoscopes and advancement through endoscopy needles. These techniques allow navigation into the biliary and pancreatic ducts and evaluation of pancreatic cystic lesions. Imaging depth can be carefully controlled with fluoroscopy by a single operator.

Two commercial probes are now available, one of which has been cleared by the United States Food and Drug Administration for patient care (Cellvizio, Mauna Kea Technologies, Paris, France).¹¹ Similar to other confocal applications, fluorescein (2–5 mL; 10% fluorescein sodium) is injected intravenously 2–3 minutes before imaging. Images are obtained placing the probe directly against the mucosa. The probe-based confocal laser endomicroscopy (pCLE) probe or “miniprobe” works through a 1-mm compatible operating channel. It was designed to be inserted through a side-viewing endoscope into the biliary ducts. The needle-based confocal laser endomicroscopy (nCLE) probe is slightly thinner and works through a compatible 0.95-mm operating channel. It was designed to be advanced through a 19-gauge EUS needle into pancreatic cysts.

According to the manufacturer’s instructions, both probes can be used up to 10 times. The probe tip is radio-opaque, allowing guidance and probe positioning under fluoroscopy. The optical penetration of the confocal plane provides superficial subsurface information without interference from bile or solid residues. Images feature high resolution at the cellular level. For both pCLE and nCLE, the manufacturer reports a field of view of 325 µm, resolution of 3.5 µm, and confocal depth of 40–70 µm. Changes in the tissue micro-architecture are used to visually differentiate between malignant and benign disorders (Fig. 1). Training for image recognition and interpretation takes approximately 6 hours for pCLE and 5 hours for nCLE.^{20,21} Three main applications were identified in our systematic review: indeterminate biliary strictures, pan-

creatic cysts, and pancreatic parenchyma.

Indeterminate biliary strictures

Malignant biliary strictures (caused by cholangiocarcinoma, hepatocellular carcinoma, or metastatic cancer to the liver) can be difficult to differentiate from benign strictures (caused by inflammation, surgical scarring, or extrinsic compression). Up to 15% of patients who undergo surgical resection for suspected malignancy end up having a benign condition.²²

When a biliary stricture is identified, the conventional approach is ERCP with bile duct brushings for cytology, fluorescence in-situ hybridization analysis for trisomy/polysomy, and cholangioscopy with targeted biopsies for histology. This triple approach has a sensitivity of 89% and a specificity of 96% for identifying cancer.²³ In these patients, pCLE is an adjunct tool for differentiating benign from malignant biliary strictures. Once the biliary stricture is located by the injection of radiopaque contrast, the pCLE catheter is passed through the narrow area while a black and white histology video is recorded. Images can be interpreted in real time or reviewed later by freezing frames for better interpretation. After pCLE videos are collected, the conventional brushings and biopsies can be performed.

Diagnostic criteria and performance

Image interpretation of pCLE is based on bands, shadows, and background colors that reflect changes in vascular patterns and epithelial cells. White bands correspond to lymphatic or blood vessels, while dark bands correspond to collagen fibrils that clump into tumoral glands.²⁴ An expert meeting proposed the initial criteria for the interpretation of CLE biliary images in 2011 (Miami classification).²⁵ Two years later, a second meeting refined the criteria and increased their specificity and accuracy (Paris classification; Table 1).²⁶ In this system, the bile ducts are classified as normal, inflammatory strictures, or ma-

Table 1. Paris Classification of Probe-Based Confocal Laser Endomicroscopy Patterns in Biliary Ducts

	Healthy bile duct	Inflammatory stricture	Malignant stricture
Collagen fibrils	Reticular network of thin dark branching bands (<20 µm)	Dark granular pattern in scales Thickened reticular structures	Thick dark bands (>40 µm)
Background	Light grey	Roughness aspect	Dark clumps
Vessels	Thin white bands (<20 µm)	Vascular congestion	Thick white bands (>20 µm)
Epithelium		Enlarged space between scales Increased inter-glandular space	Epithelium visualized (villi, glands)
Additional features ^{a)}			Fluorescein leakage

^{a)}Suggested in the Miami classification but not included in the Paris classification.^{24, 25}

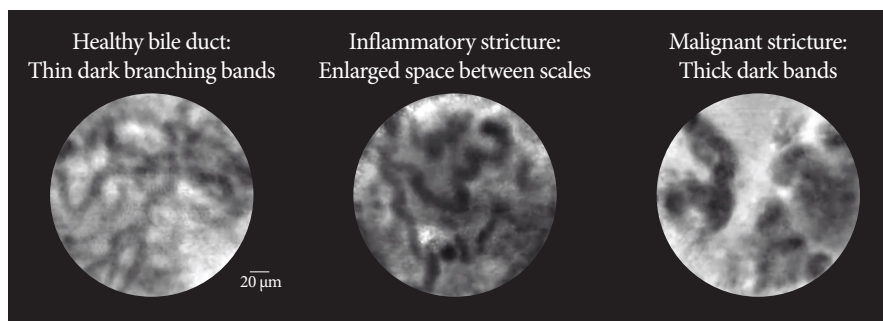


Fig. 3. Representative patterns of probe-based confocal laser endomicroscopy in biliary ducts conditions. Courtesy of Mauna Kea Technologies, Inc.

lignant strictures (Fig. 3).

An international consensus in 2015 reported that pCLE is more accurate than ERCP with brush cytology and/or forceps biopsy for discriminating malignant from benign strictures using established criteria (87% agreement).²⁷ ERCP-guided pCLE is now mentioned as an adjunct tool by the American Society of Gastrointestinal Endoscopy for management of

patients with indeterminate biliary strictures.²⁸ A technical review from the European Society of Gastrointestinal Endoscopy recognized that pCLE is currently difficult and expensive but has the potential to become an important diagnostic tool for indeterminate biliary strictures.²⁹

The diagnostic performance of pCLE in indeterminate biliary strictures is demonstrated in Table 2. Among the 46

Table 2. Landmark Studies Evaluating Probe-based Confocal Laser Endomicroscopy in Biliary Strictures

Study	Aim	Study design	Biliary strictures				Pancreatitis	Comments
			Sensitivity	Specificity	Accuracy			
Meining et al. (2011), ²⁴ n=86 ^{a)}	Diagnosis of cholangiocarcinoma.	Prospective multicenter	98%	67%	81%	0%	3 pancreatic strictures included	
Heif et al. (2013) ³⁰ , n=15	Dominant stricture in PSC.	Case series single center	100%	61%	66%	0%	PSC only	
Caillol et al. (2013), ²⁶ n=60	Standardize image interpretation	Retrospective image review	96%	76%	85%	NA	Focused on image standardization	
EMID (2015), ³¹ n=61 ^{a)}	Malignant vs. benign strictures	Prospective single center	100%	71%	93%	NA	Added EUS-guided biopsies	
FOCUS (2015), ³² n=112	Malignant vs. benign strictures	Prospective multicenter	89%	71%	82%	0%	Excluded patients with PSC	
Fugazza et al. (2016), ¹⁸ 10 studies, n=494	Malignant vs. benign strictures	Systematic review and meta-analysis	Pooled 90%	Pooled 72%	Pooled 81%	NA	Also reviewed Barrett's, gastric and colorectal cancer	
Liu et al. (2016), ¹⁷ 8 studies, n=280	Malignant vs. benign strictures	Systematic review and meta-analysis	Pooled 90%	Pooled 75%	Pooled 82%	NA		
Dubow et al. (2018), ³³ n=97	Malignant vs. benign strictures	Retrospective single center	83%	93%	90%	NA	Prior ERCP sampling and imaging negative	
Koda et al. (2021), ³⁴ n=7	Malignant vs. benign strictures	Case series single center	GastroFlex™ 100% CholangioFlex™ 75% AlveoFlex™ 75%	0% (0/3) 66.7% 33.3%	57.1% 71.4% 57.1%	NA		

^{a)}In cases of multiple manuscripts published by the same group, we selected the most recent publication or the one with the largest sample. ERCP, endoscopic retrograde cholangiopancreatography; EUS, endoscopic ultrasonography; NA, not available; nCLE, needle-based confocal laser endomicroscopy; pCLE, probe-based confocal laser endomicroscopy; PSC, primary sclerosing cholangitis.

Table 3. Landmark Studies Evaluating Needle-based Confocal Endomicroscopy in Pancreatic Cysts and Solid Lesions

Pancreatic cysts							
Study	Aim	Study design	Sensitivity	Specificity	Accuracy	Pancreatitis	Comments
INSPECT (2013), ³⁵ n=57	SCA and pseudo-cyst vs. other cysts	Prospective multicenter	59%	100%	71%	3%	Early phase defining diagnostic criteria
DETECT (2015), ³⁶ n=29	Mucinous vs. other cysts	Prospective single center	80%	100%	89%	7%	Combination with cystoscopy yields 100% accuracy
Fugazza et al. (2016), ¹⁸ 5 studies, n=163	Malignancy in pancreatic cysts	Systematic review and meta-analysis	Pooled 68%	Pooled 90%	Pooled 79%	NA	Also reviewed Barrett's, gastric and colorectal cancer
CONTACT (2015), ³⁷ n=43 (included 31)	SCA vs. other cysts	Prospective multicenter	SCA 95% Indeterminate mucinous 95% NET 100% Premalignant cyst 96%	100% 100% 95% 95%	99% 97% 96% 96%	2%	Superior than combination of CEA and cytology analysis
INDEX (2019), ³⁸ n=144	Mucinous vs. non mucinous pancreatic cysts	Prospective single center	98%	94%	97%	3%	Superior than combination of CEA and cytology analysis
CONCYST (2019), ³⁹ n=67 (included 56)	Indeterminate pancreatic cyst	Prospective multicenter	All indeterminate cysts 80% IPMN 90% Ductal adenocarcinoma 100% SCA 56% Pseudocysts 67%	NA	77% 87% 100% 38% 67%	0%	Correlation with pathology and experts was good. Image acquisition took <10 min
Krishna et al. (2020), ^{38,40} n=26	Identify dysplasia in IPMN	INDEX post-hoc analysis	Papillary epithelial width 88% Papillary epithelial darkness 88%	100% 100%	85% 84%	3%	Allow risk stratification of IPMN
Hao et al. (2020), ⁴¹ n=122	Solid and cystic pancreatic lesions	Prospective single center	All cysts 94% SCA 89% MCN 87% IPMN 97%	98% 100% 98% 100%	97% 97% 94% 99%	5%	
Facciorusso et al. (2020), ¹⁵ 10 studies, n=536	Pancreatic cystic lesions	Systematic review and meta-analysis	Pooled 82%	Pooled 97%	89%	0%	Mean procedure duration of 6 mins
Konjeti et al. (2020), ¹⁹ 7 studies, n=324	Pancreatic cystic lesions	Systematic review and meta-analysis	Pooled 85%	99%	99%	1%	High heterogeneity among studies
Chin et al. (2021), ⁴² 42 studies, n=519	Pancreatic cystic lesions	Systematic review				2.6%	No meta-analysis performed
Pancreatic parenchyma and solid lesions							
Giovannini et al. (2016), ⁴³ n=40	Solid pancreatic lesions, compared to pathology	Prospective multicenter. Part of CONTACT	Ductal adenocarcinoma 77% Chronic pancreatitis 50% NET 100%	100% 100% 97%	85% 91% 97%	NA	First description of adenocarcinoma, NET and chronic pancreatitis
Hao et al. (2020), ⁴¹ n=50	Solid and cystic pancreatic lesions	Prospective single center	Ductal adenocarcinoma 90%	89%	90%	5%	First description of AIP and tuberculosis

AIP, autoimmune pancreatitis; CEA, carcinoembryonic antigen; IPMN, intraductal papillary mucinous neoplasm; NA, not available; nCLE, needle-based confocal laser endomicroscopy; NET, neuroendocrine tumor; pCLE, probe-based confocal laser endomicroscopy; SCA, serous cystadenoma.

publications identified in the literature, nine were considered relevant. Sensitivity ranged from 75% to 100% and specificity ranged from 0% (one small study with three participants) to 93%. Overall, pCLE has a great negative predictive value for cancer in indeterminate biliary strictures. The negative predictive value of pCLE was estimated to be 94%, those of biliary biopsies (78%), biliary brushings (77%), and ERCP overall (98%).³³ In fact, pCLE has additional value for patients with primary sclerosing cholangitis (PSC), who experience progressive inflammation of the bile ducts and develop cholangiocarcinoma at high rates (1.5% incidence per year). Distinguishing cholangiocarcinoma from other inflammatory strictures in PSC remains challenging. Compared to other indications, the sensitivity of the traditional triple approach (fluorescence in-situ hybridization, cytology brushings, and biopsies) in PSC is only 54%, but it increases to 61% after the addition of pCLE (specificity and accuracy remain >80%, while the negative predictive value is 100 [95% confidence interval, 71.3–100]).³⁰

Pancreatic cysts

Pancreatic cysts are easily visualized with EUS, and special needles are introduced into them to collect fluid for tumor marker and cytology testing. Once a 19-gauge needle is inserted into a pancreatic cyst, an nCLE probe is advanced under EUS guidance into the pancreatic cyst. An intracystic endomicroscopic video is captured with permissive angulation of the needle facilitated by the elevator of the ecoendoscope using axial rotation of the endoscopist or the gentle application of torque. After the image collection, the nCLE probe is withdrawn and the cyst can be aspirated. The cystic fluid is evaluated for cytology, amylase, and carcinoembryonic antigen levels, mutations in tumor suppressor genes (loss of heterozygosity), and oncogene point mutations. If desired, a small-caliber biopsy forceps (Moray micro forceps, US Endoscopy, Mentor, Ohio, USA) can also be advanced through the needle channel

to enable additional biopsies of the cyst wall.⁴⁴ At the end of the procedure, intravenous antibiotic prophylaxis is administered to prevent cyst infection.

Of note, using the same technique as for bile duct evaluation, a pCLE probe can be introduced into the pancreatic duct for the evaluation of malignant pancreatic strictures or main duct–intraductal mucinous neoplasms (IPMN).²⁴

Diagnostic criteria and performance

It is noteworthy that nCLE was not reviewed at the consensus meeting in 2015 or the most recent European Society of Gastrointestinal Endoscopy technology review.^{27,29} The 2016 American Society of Gastrointestinal Endoscopy guideline for managing cystic pancreatic neoplasms acknowledged that the addition of nCLE increases the diagnostic yield of serous cystic neoplasms with high interobserver agreement.⁴⁵ Landmark studies evaluating nCLE in pancreatic cysts and solid lesions are shown in Table 3.

Comprehensive diagnostic criteria for nCLE in the evaluation of pancreatic cysts were established in the CONTACT and the INDEX studies.^{37,38,40} Its diagnostic features are divided into epithelial patterns and vascular patterns (Table 4^{36,38}). Specific patterns for different types of pancreatic cysts are shown in Fig. 4. The addition of nCLE can enable the classification of pancreatic cysts into mucinous cysts (IPMN or mucinous cystic neoplasms) and non-mucinous cysts (serous cystadenoma, pseudocyst, or solid tumors with a cystic component [e.g. neuroendocrine tumors]). A clear application of nCLE is identifying benign serous cystadenomas and thereby preventing unnecessary surgery in these patients. A recent study showed that nCLE can be used to identify dysplasia and localized cancer in cases of IPMN. After the implementation of the INDEX criteria, papillary width and darkness should be measured (Table 4).⁴⁰

Studies initially raised concerns that the addition of nCLE

Table 4. Needle-based Confocal Endomicroscopy

Epithelial patterns		Vascular patterns		
Papillae or epithelial bands	Dark background with bright particles	Trabecular pattern	Branched or rope-ladder pattern	Fern pattern (in the absence of any epithelial features)
IPMN, MCN Accuracy 96%	Pseudocyst Accuracy 98%	Cystic-NET, SPT Accuracy 97%	IPMN, MCN Accuracy 75%	SCA Accuracy 99%
Papillae: IPMN	Epithelial bands, chronic inflammation: MCN			
High-grade dysplasia: Papillary width ≥50 μm Papillary darkness ≤90 pixel intensity				

IPMN, intraductal mucinous papillary neoplasm; MCN, mucinous cystic neoplasm; Ncle, needle-based confocal laser endomicroscopy; NET, neuroendocrine tumor; SCA, serous cystadenoma; SPT, solid pseudopapillary tumor.

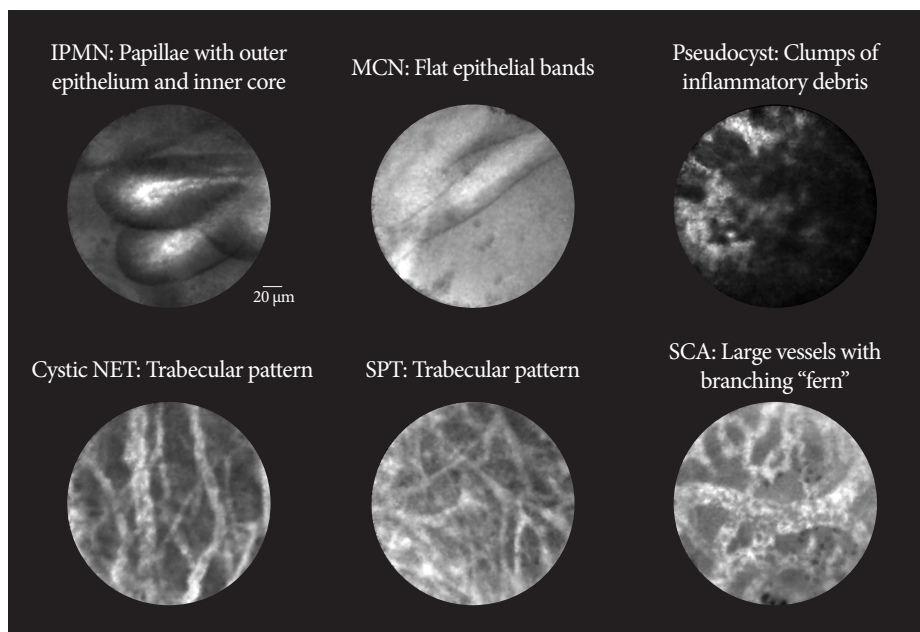


Fig. 4. Representative patterns of needle-based confocal laser endomicroscopy in pancreatic cysts. Pseudocyst can have a dark or light background. Cystic NET and SPT can only be differentiated using immunostaining. IPMN, intraductal mucinous papillary neoplasm; MCN, mucinous cystic neoplasm; NET, neuroendocrine tumor; SCA, serous cystadenoma; SPT, solid pseudopapillary tumor. Courtesy of Krishna SG.

to the traditional EUS aspiration of pancreatic cysts would increase the rate of adverse events (reported in 7–9% of all cases).⁴⁶ However, larger studies published over the last 10 years show reduced rates of pancreatitis similar to those seen for ERCP (Table 2). Other adverse events include bleeding into the cyst (1%), pruritus (1.5%), pseudocyst infection (1.5%; one case reported resolved with antibiotics), and peri-pancreatic fluid collection (2%).^{41,47}

Pancreatic parenchyma

Two studies have evaluated the use of nCLE for the pancreatic parenchyma and solid tumors.^{41,43} Researchers in China and France described the general characteristics of pancreatic adenocarcinoma, neuroendocrine tumors, chronic pancreati-

tis, autoimmune pancreatitis, solid pseudopapillary tumors, and one case of pancreatic tuberculosis (Table 5^{40,42}). The reported performance and pancreatitis incidence was similar to that reported for nCLE for pancreatic cysts (Table 3). In the authors' experience, without the liquid interface of the cyst, images are static and image interpretation is challenging.

DISCUSSION

Implementation costs, catheter lifespan, sampling errors, interobserver variability, and added procedure time have limited the broader utilization of CLE in clinical practice.⁴⁸ While CLE technology is being refined, alternative devices for tissue

Table 5. Initial Characteristics of Needle-Based Confocal Laser Endomicroscopy Patterns in Solid Pancreatic Tumors

	Findings
Adenocarcinoma	Dark cell aggregates Irregular vessels with fluorescein leakage
Chronic and autoimmune pancreatitis	Residual regular glandular pancreatic structures Massive fibrous areas
Neuroendocrine tumor	Black cell aggregates surrounded by vessels and fibrotic areas
Solid pseudopapillary tumor	Black columnar protrusions near the vascular area
Tuberculosis	Black huge cells (may correspond to macrophages) mixing with vesicular adipocytes

acquisition have been developed.⁴⁹ For pancreatic cysts, micro forceps allow tissue sampling under direct EUS visualization. The risk of developing pancreatitis from an nCLE evaluation is similar to or lower than that of biopsies performed using micro forceps (2.1%).⁴⁹ The most cited limitation of both pCLE and nCLE is disagreement among expert endoscopists on image interpretation. Agreement was rated “poor” to “good” in three studies.^{20,50,51} Artificial intelligence systems have significant potential to resolve this issue.

Our review of ClinicalTrials.gov identified five clinical trials recruiting patients to receive CLE: three in China, one in Brazil, and one multicenter study in the United States. Two trials will evaluate patients with pancreatic cysts, two with patients requiring surgery (or percutaneous drainage) after pancreatic trauma, and one will utilize CLE for the early detection of different gastrointestinal tumors (Barrett’s esophagus, partial gastric antrectomy, biliary duct strictures, pancreatic duct strictures, colorectal polyps, esophageal neoplasms, pancreatic head, and neck tumors). Significant limitations were found in studies evaluating its use for the pancreatic parenchyma or solid lesions.

Finally, early studies show that implementing deep learning algorithms into image recognition can facilitate CLE interpretation and expedite the clinical diagnosis.^{52,53} Despite the advances identified in our review, few studies have demonstrated that the use of CLE can change clinical decisions (e.g. prevent surgery) or improve direct patient care (e.g. shorten time to surgery or chemotherapy).³⁷ Prospective trials able to prove such benefits will be instrumental in justifying the added cost of implementing CLE in regular clinical practice.

In conclusion, pCLE and nCLE enable the microscopic evaluation of the bile ducts and pancreas in vivo and in real time, enhancing the imaging arsenal of gastroenterologists. Integrating CLE into the endoscopy room along with conventional cytology, histology, and molecular testing improves cancer detection. Although our understanding of CLE microscopy continues to increase, patient outcomes data remain limited. CLE images remain subject to significant inter-reader reliability and sampling errors. Despite those limitations, most experts agree on the potential of CLE imaging and support its integration into future diagnostic algorithms.^{26,32}

Conflicts of Interest

Juan E. Corral: Travel grant from AbbVie, Inc.; Minor food and beverage from Boston Scientific and Cook Medical.

Emmanuel Coronel: Consulting for Boston Scientific.

Michael B. Wallace: Consulting for Virgo Inc, Cosmo/Aries Pharmaceuticals, Anx Robotica (2019), Covidien, and GI Supply; Research grants from Fujifilm, Boston Scientific, Olympus, Medtronic, Ninepoint Medical, Cosmo/ Aries Pharmaceuticals; Stock options from Virgo Inc; Consulting on behalf of Mayo Clinic, GI Supply (2018), Endokey, Endostart,

Boston Scientific, and Microtek; General payments/minor food and beverage from Synergy Pharmaceuticals, Boston Scientific, and Cook Medical.

The authors have no potential conflicts of interest.

Funding

None.

Author Contributions

Conceptualization: Juan E. Corral

Data curation: Do Han Kim, Emmanuel Coronel, Paul T. Kröner

Formal analysis: DHK, EC, PTK

Funding acquisition

Investigation: DHK, EC, PTK

Methodology: JEC

Project administration: JEC

Resources: JEC

Supervision: JEC

Validation: Herbert C. Wolfsen, Michael B. Wallace

Visualization: Somashekar G Krishna, MBW

Writing-original draft: JEC

Writing-review & editing: DHK, HCW, MBW

ORCID

Do Han Kim <https://orcid.org/0000-0002-2815-1105>

Somashekar G. Krishna <https://orcid.org/0000-0001-5748-7890>

Emmanuel Coronel <https://orcid.org/0000-0001-8806-6765>

Paul T. Kröner <https://orcid.org/0000-0002-7361-7883>

Herbert C. Wolfsen <https://orcid.org/0000-0002-6957-522X>

Michael B. Wallace <https://orcid.org/0000-0002-6446-5785>

Juan E. Corral <https://orcid.org/0000-0002-8821-4534>

REFERENCES

- Kochhar G, Wallace MB. Virtual histology in everyday gastrointestinal endoscopy. *Clin Gastroenterol Hepatol* 2018;16:1556-1561.
- Trindade AJ, Leggett CL, Chang KJ. Volumetric laser endomicroscopy in the management of Barrett’s esophagus. *Curr Opin Gastroenterol* 2017;33:254-260.
- Al-Mansour MR, Caycedo-Marulanda A, Davis BR, et al. SAGES TAV-AC safety and efficacy analysis confocal laser endomicroscopy. *Surg Endosc* 2021;35:2091-2103.
- Glover B, Teare J, Patel N. The status of advanced imaging techniques for optical biopsy of colonic polyps. *Clin Transl Gastroenterol* 2020;11:e00130.
- Ruff S, Curtin B, Quezado M, et al. Evaluation of confocal endoscopic microscopy for detection of early-stage gastric cancer in hereditary diffuse gastric cancer (HDGC) syndrome. *J Gastrointest Oncol* 2019;10:407-411.
- Su P, Liu Y, Lin S, et al. Efficacy of confocal laser endomicroscopy for discriminating colorectal neoplasms from non-neoplasms: a systematic review and meta-analysis. *Colorectal Dis* 2013;15:e1-e12.
- Yu X, Chen J, Zheng L, Song J, Lin R, Hou X. Quantitative diagnosis of atrophic gastritis by probe-based confocal laser endomicroscopy. *Biomed Res Int* 2020;2020:9847591.
- Buchner AM. Confocal laser endomicroscopy in the evaluation of inflammatory bowel disease. *Inflamm Bowel Dis* 2019;25:1302-1312.
- Zhang MM, Zhong N, Wang X, et al. Endoscopic ultrasound-guided needle-based confocal laser endomicroscopy for diagnosis of gastric subepithelial tumors: a pilot study. *Endoscopy* 2019;51:560-565.

10. Pohl H, Tanczos BT, Rudolph B, et al. Probe-based confocal laser microscopy identifies criteria predictive of active celiac sprue. *Dig Dis Sci* 2012;57:451-457.
11. Cellvizio® Gastrointestinal Brochure - International [Internet]. Paris: Mauna Kea Technologies; c2016 [cited 2021 June 25]. Available from: <https://www.maunaakeatech.com/en/researchers/32-brochure>.
12. Saadi M, Yu C, Othman MO. A review of the challenges associated with the diagnosis and therapy of primary sclerosing cholangitis. *J Clin Transl Hepatol* 2014;2:45-52.
13. Hutchins GF, Draganov PV. Cystic neoplasms of the pancreas: a diagnostic challenge. *World J Gastroenterol* 2009;15:48-54.
14. Gao YD, Qu YW, Liu HF. Comparison of diagnostic efficacy between CLE, tissue sampling, and CLE combined with tissue sampling for undetermined pancreaticobiliary strictures: a meta-analysis. *Scand J Gastroenterol* 2018;53:482-489.
15. Facciorusso A, Buccino VR, Sacco R. Needle-based confocal laser endomicroscopy in pancreatic cysts: a meta-analysis. *Eur J Gastroenterol Hepatol* 2020;32:1084-1090.
16. Njei B, McCarty TR, Varadarajulu S, Navaneethan U. Systematic review with meta-analysis: endoscopic retrograde cholangiopancreatography-based modalities for the diagnosis of cholangiocarcinoma in primary sclerosing cholangitis. *Aliment Pharmacol Ther* 2016;44:1139-1151.
17. Liu Y, Lu Y, Sun B, et al. Probe-based confocal laser endomicroscopy for the diagnosis of undetermined biliary stenoses: a meta-analysis. *Clin Res Hepatol Gastroenterol* 2016;40:666-673.
18. Fugazza A, Gaiani F, Carra MC, et al. Confocal laser endomicroscopy in gastrointestinal and pancreatobiliary diseases: a systematic review and meta-analysis. *Biomed Res Int* 2016;2016:4638683.
19. Konjeti VR, McCarty TR, Rustagi T. Needle-based confocal laser endomicroscopy (nCLE) for evaluation of pancreatic cystic lesions: a systematic review and meta-analysis. *J Clin Gastroenterol* 2022;56:72-80.
20. Peter S, Council L, Bang JY, et al. Poor agreement between endoscopists and gastrointestinal pathologists for the interpretation of probe-based confocal laser endomicroscopy findings. *World J Gastroenterol* 2014;20:17993-18000.
21. Luthra AK, Pusateri AJ, Pfeil SA, et al. Confocal laser endomicroscopy interpretation and differentiation of pancreatic cysts: a randomized trial of teaching modalities. *Techniques and Innovations in Gastrointestinal Endoscopy* 2021;23:8-17.
22. Gerhards MF, Vos P, van Gulik TM, Rauws EA, Bosma A, Gouma DJ. Incidence of benign lesions in patients resected for suspicious hilar obstruction. *Br J Surg* 2001;88:48-51.
23. Shah RJ, Langer DA, Antillon MR, Chen YK. Cholangioscopy and cholangioscopic forceps biopsy in patients with indeterminate pancreaticobiliary pathology. *Clin Gastroenterol Hepatol* 2006;4:219-225.
24. Meining A, Chen YK, Pleskow D, et al. Direct visualization of indeterminate pancreaticobiliary strictures with probe-based confocal laser endomicroscopy: a multicenter experience. *Gastrointest Endosc* 2011;74:961-968.
25. Wallace M, Lauwers GY, Chen Y, et al. Miami classification for probe-based confocal laser endomicroscopy. *Endoscopy* 2011;43:882-891.
26. Caillol F, Filoche B, Gaidhane M, Kahaleh M. Refined probe-based confocal laser endomicroscopy classification for biliary strictures: the Paris Classification. *Dig Dis Sci* 2013;58:1784-1789.
27. Wang KK, Carr-Locke DL, Singh SK, et al. Use of probe-based confocal laser endomicroscopy (pCLE) in gastrointestinal applications. A consensus report based on clinical evidence. *United European Gastroenterol J* 2015;3:230-254.
28. ASGE Standards of Practice Committee, Chathadi KV, Chandrasekhara V, et al. The role of ERCP in benign diseases of the biliary tract. *Gastrointest Endosc* 2015;81:795-803.
29. Tringali A, Lemmers A, Meves V, et al. Intraductal biliopancreatic imaging: european society of gastrointestinal endoscopy (ESGE) technology review. *Endoscopy* 2015;47:739-753.
30. Heif M, Yen RD, Shah RJ. ERCP with probe-based confocal laser endomicroscopy for the evaluation of dominant biliary stenoses in primary sclerosing cholangitis patients. *Dig Dis Sci* 2013;58:2068-2074.
31. Caillol F, Bories E, Autret A, et al. Evaluation of pCLE in the bile duct: final results of EMID study : pCLE: impact in the management of bile duct strictures. *Surg Endosc* 2015;29:2661-2668.
32. Slivka A, Gan I, Jamidar P, et al. Validation of the diagnostic accuracy of probe-based confocal laser endomicroscopy for the characterization of indeterminate biliary strictures: results of a prospective multicenter international study. *Gastrointest Endosc* 2015;81:282-290.
33. Dubow M, Tatman PD, Shah RJ. Individual probe based confocal laser endomicroscopy criteria in the analysis of indeterminate biliary strictures. *Scand J Gastroenterol* 2018;53:1358-1363.
34. Koda H, Hara K, Nozomi O, et al. High-resolution probe-based confocal laser endomicroscopy for diagnosing biliary diseases. *Clin Endosc* 2021;54:924-929.
35. Konda VJA, Meining A, Jamil LH, et al. A pilot study of in vivo identification of pancreatic cystic neoplasms with needle-based confocal laser endomicroscopy under endosonographic guidance. *Endoscopy* 2013;45:1006-1013.
36. Nakai Y, Iwashita T, Park DH, Samarasena JB, Lee JG, Chang KJ. Diagnosis of pancreatic cysts: EUS-guided, through-the-needle confocal laser-induced endomicroscopy and cystoscopy trial: DETECT study. *Gastrointest Endosc* 2015;81:1204-1214.
37. Napoléon B, Lemaistre A-I, Pujol B, et al. A novel approach to the diagnosis of pancreatic serous cystadenoma: needle-based confocal laser endomicroscopy. *Endoscopy* 2015;47:26-32.
38. Krishna SG, Hart PA, Malli A, et al. Endoscopic ultrasound-guided confocal laser endomicroscopy increases accuracy of differentiation of pancreatic cystic lesions. *Clin Gastroenterol Hepatol* 2020;18:432-440.e6.
39. Keane MG, Wehnert N, Perez-Machado M, et al. A prospective trial of CONFocal endomicroscopy in CYSTic lesions of the pancreas: CON-CYST-01. *Endosc Int Open* 2019;7:E1117-E1122.
40. Krishna SG, Hart PA, DeWitt JM, et al. EUS-guided confocal laser endomicroscopy: prediction of dysplasia in intraductal papillary mucinous neoplasms (with video). *Gastrointest Endosc* 2020;91:551-563.e5.
41. Hao S, Ding W, Jin Y, et al. Appraisal of EUS-guided needle-based confocal laser endomicroscopy in the diagnosis of pancreatic lesions: a single Chinese center experience. *Endosc Ultrasound* 2020;9:180-186.
42. Chin YK, Wu CCH, Tan DMY. The role of needle-based confocal laser endomicroscopy in the evaluation of pancreatic cystic lesions: a systematic review. *Clin Endosc* 2021;54:38-47.
43. Giovannini M, Caillol F, Monges G, et al. Endoscopic ultrasound-guided needle-based confocal laser endomicroscopy in solid pancreatic masses. *Endoscopy* 2016;48:892-898.
44. Orr J, Lockwood R, Roberts J, Shi C, Yachimski P. EUS and confocal endomicroscopic diagnosis of pancreatic acinar cell cystadenoma. *Gastrointest Endosc* 2018;88:769-770.
45. ASGE Standards of Practice Committee, Muthusamy VR, Chandrasekhara V, et al. The role of endoscopy in the diagnosis and treatment of cystic pancreatic neoplasms. *Gastrointest Endosc* 2016;84:1-9.
46. European Study Group on Cystic Tumours of the Pancreas. European evidence-based guidelines on pancreatic cystic neoplasms. *Gut* 2018;67:789-804.
47. Larghi A, Crinò SF, Napoléon B. Pancreatic cystic lesions: time to move to 19-gauge needle with EUS-guided microforceps biopsy or needle-based confocal laser endomicroscopy. *Gastrointest Endosc* 2020;92:222.
48. Bhutani MS, Koduru P, Joshi V, et al. EUS-guided needle-based confocal laser endomicroscopy: a novel technique with emerging applications. *Gastroenterol Hepatol (NY)* 2015;11:235-240.
49. Yang D, Samarasena JB, Jamil LH, et al. Endoscopic ultrasound-guided through-the-needle microforceps biopsy in the evaluation of pancreatic cystic lesions: a multicenter study. *Endosc Int Open* 2018;6:E1423-E1430.

50. Karia K, Waxman I, Konda VJ, et al. Needle-based confocal endomicroscopy for pancreatic cysts: the current agreement in interpretation. *Gastrointest Endosc* 2016;83:924-927.
51. Talreja JP, Sethi A, Jamidar PA, et al. Interpretation of probe-based confocal laser endomicroscopy of indeterminate biliary strictures: is there any interobserver agreement? *Dig Dis Sci* 2012;57:3299-3302.
52. Aubreville M, Stoeve M, Oetter N, et al. Deep learning-based detection of motion artifacts in probe-based confocal laser endomicroscopy images. *Int J Comput Assist Radiol Surg* 2019;14:31-42.
53. Rasti P, Wolf C, Dorez H, et al. Machine learning-based classification of the health state of mice colon in cancer study from confocal laser endomicroscopy. *Sci Rep* 2019;9:20010.