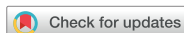

Letter to the Editor



Progressive Cognitive and Behavioral Changes With Leukodystrophy due to *ABCD1* Gene Mutation

Jinseok Park ,¹ Sanggon Lee ,¹ Heerah Lee ,² Jee Soo Lee ,²
Moon-Woo Seong ,² Hee-Jin Kim ¹

¹Department of Neurology, Hanyang University Hospital, Hanyang University College of Medicine, Seoul, Korea

²Department of Laboratory Medicine, Seoul National University Hospital, Seoul National University College of Medicine, Seoul, Korea



Received: Oct 21, 2022

Revised: Oct 27, 2022

Accepted: Oct 28, 2022

Published online: Oct 31, 2022

Correspondence to

Hee-Jin Kim

Department of Neurology, Hanyang University Hospital, Hanyang University College of Medicine, 222-1 Wangsimni-ro, Seongdong-gu, Seoul 04763, Korea.
Email: hyumcbrain@hanyang.ac.kr

© 2022 Korean Dementia Association

This is an Open Access article distributed under the terms of the Creative Commons Attribution Non-Commercial License (<https://creativecommons.org/licenses/by-nc/4.0/>) which permits unrestricted non-commercial use, distribution, and reproduction in any medium, provided the original work is properly cited.

ORCID iDs

Jinseok Park

<https://orcid.org/0000-0001-6581-5831>

Sanggon Lee

<https://orcid.org/0000-0003-0622-1210>

Heerah Lee

<https://orcid.org/0000-0002-9830-4859>

Jee Soo Lee

<https://orcid.org/0000-0002-6633-4631>

Moon-Woo Seong

<https://orcid.org/0000-0003-2954-3677>

Hee-Jin Kim

<https://orcid.org/0000-0001-7880-690X>

Conflict of Interest

The authors have no financial conflicts of interest.

Dear Editor,

Adrenoleukodystrophy (ALD) is caused by a mutation in the *ABCD1* gene, which is located on the X-chromosome (Xq28).¹ Peroxisomal dysfunction leads to accumulation of very long-chain fatty acids (VLCFA) in adrenal glands and peripheral white matter of the central nervous system.² In contrast to childhood-onset ALD, adult-onset ALD is relatively rare and asymptomatic until the 4th decade of life.¹ Since ALD has X-linked inheritance, it is difficult to prioritize genetic testing when there are only a few family members. In addition, if there are extensive white matter changes without a definitive family history, early diagnosis is difficult because other etiologies such as demyelinating disease should be given priority consideration. Herein, we report a sporadic case of adult-onset ALD caused by *ABCD1* mutation. The condition was originally thought to be a demyelinating disease. Therefore, the ALD diagnosis was delayed.

A 39-year-old man was admitted to our hospital with a history of progressive cognitive decline. He had begun to show behavioral abnormalities such as abusive language 2 years ago and his personal hygiene had been deteriorating for 3 months prior to admission. Two weeks prior, he had gone missing. However, he was found wandering the streets by the police and subsequently admitted to a psychiatric hospital under suspicion of schizophrenia. Neurological examination revealed frontal lobe dysfunctions such as abulia, preservation, and disinhibition. The Korean version of the Mini-Mental State Examination score was 4 out of 30 and his clinical dementia rating was 4 out of 5. No motor or sensory abnormalities were found. His reflexes were nonspecific. His family had a history of neurodegenerative disease. His grandmother had dementia. Two of his aunts had Parkinson's disease. His uncle had childhood-onset mental retardation and gait disturbance (**Fig. 1A**). Initial laboratory findings revealed rhabdomyolysis (creatinine phosphokinase: 37,634 U/L), elevated liver function test (aspartate aminotransferase: 1,584 U/L, alanine transaminase: 370 U/L), hypokalemia (2.8 mEq/L), and hyperammonemia (96 ug/dL). His cerebrospinal fluid protein levels were elevated (72.2 mg/dL) without pleocytosis. No epileptic discharges were observed on the electroencephalogram. Diffuse leukomalacia involving frontal and temporal lobes of the corpus callosum with perilesional enhancement was observed on brain magnetic resonance image (**Fig. 1B**). Demyelinating disease was initially considered because of widespread white matter changes. Despite high-dose methylprednisolone administration for 5 days to treat possible demyelinating disease, there was no change in his cognitive function.

Author Contributions

Conceptualization: Lee S, Kim HJ; Data curation: Lee H, Lee JS, Seong MW; Formal analysis: Lee H, Lee JS, Seong MW; Investigation: Park J, Lee S, Kim HJ; Methodology: Park J; Resources: Park J; Supervision: Park J, Kim HJ; Writing - original draft: Park J, Lee S; Writing - review & editing: Park J, Kim HJ.

A VLCFA test performed to evaluate capacious leukodystrophy revealed elevated C26:0 (3.61 umol/L), C24:0/C22:0 (1.42 umol/L), and C26:0/C22:0 (0.119 umol/L). Additional hormonal analysis showed decreased renin activity (0.30 ng/mL/hr), aldosterone (< 1.4 mg/dL), cortisol (0.4 ug/dL), and ACTH (0.4 ug/dL), which indicated adrenal insufficiency. A genetic test confirmed suspicion of adult-onset ALD and a *ABCD1* hemizygous variant (c.1866-10G>A) (Fig. 1C).

Adult-onset white matter disorders should be considered in the differential diagnosis of curable dementia with neuroinflammatory diseases (such as multiple sclerosis, neuromyelitis optica, acute disseminated demyelinating encephalitis), small vessel disease, and metabolic or inherited disorders.³ For differential diagnosis, empirical anti-inflammatory therapy such as high doses of intravenous steroids can be used. If they are not effective, diagnosis remains uncertain.

Leukodystrophy can be a lifelong condition. It occurs due to problems with metabolic products such as lipids, proteins, and organic acids.⁴ ALD is the most common type of leukodystrophy. It can be easily detected through a VLCFA test.⁵ However, in most cases of leukodystrophies reported in the pediatric literature, physicians are not familiar with the VLCFA test for cognitive impairment in adult patients. In this case, because of atypical behavioral changes, the patient was admitted for schizophrenia. Thus, a precise diagnosis was delayed. The most interesting finding of this patient was that his mother's sister (aunt) had neurodegenerative disease. In spinobulbar muscular atrophy, X-linked inherited disease, some female carriers might also have a mild form of the disease.⁶ Although we did not have any genetic data for other family

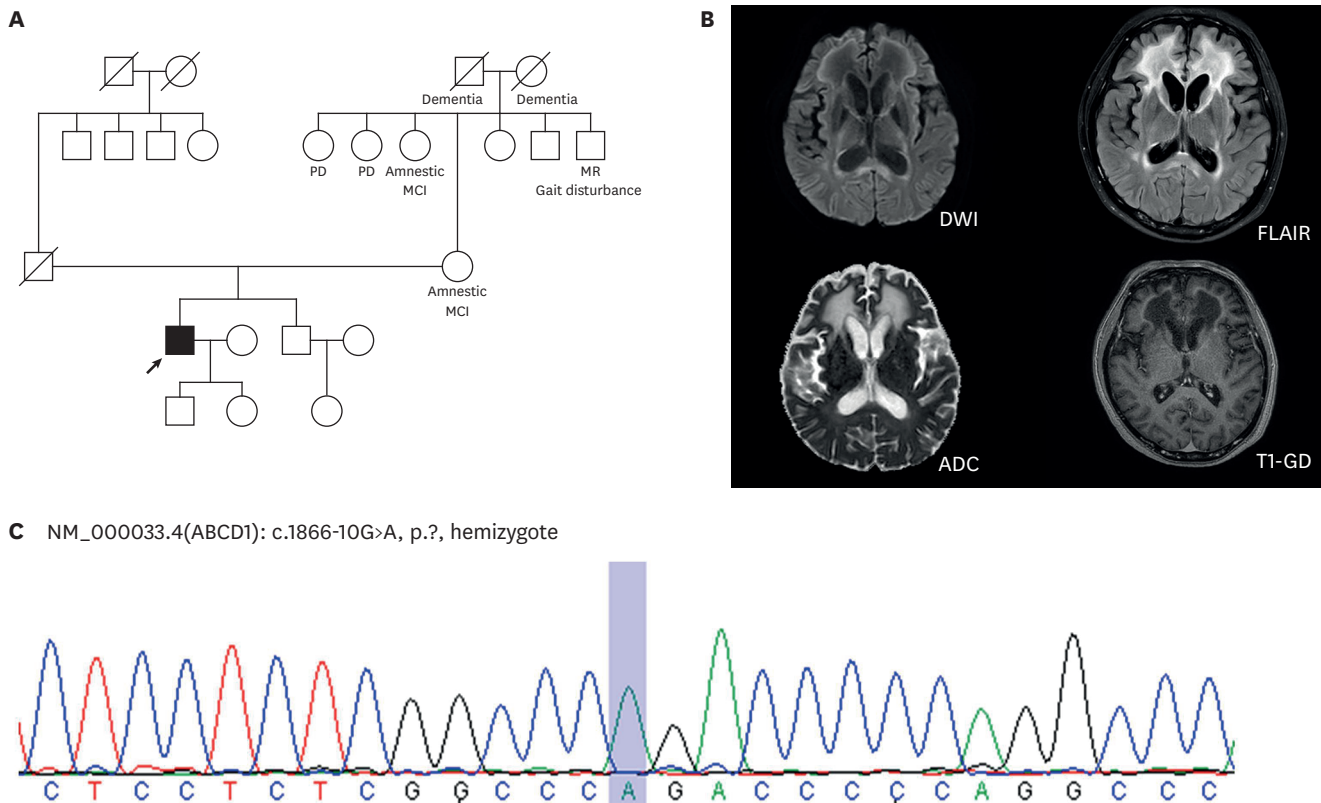


Fig. 1. Pedigree and brain MRI of a 39-year-old male patient. (A) Proband (black arrow) with an *ABCD1* variant. His family members had neurodegenerative disease. (B) Brain MRI showing symmetric confluent white matter changes. (C) Sequencing chromatograms of the proband. The blue box indicates the c.1866-10G>A hemizygous variant. MRI: magnetic resonance imaging, PD: Parkinson's disease, MR: mental retardation, MCI: mild cognitive impairment, DWI: diffusion-weighted imaging, FLAIR: fluid-attenuated inversion recovery, ADC: apparent diffusion coefficient, T1-GD: T1-gadolinium enhancement.

members, the possibility of mild form of ALD in hemizygous carrier should be analyzed. Although the final diagnosis was confirmed by *ABCD1* gene sequencing, a VLCFA test should be performed first as part of a differential diagnosis for patients with adult-onset leukodystrophy along with progressive cognitive and behavioral changes.

REFERENCES

1. Mohn A, Polidori N, Aiello C, Rizzo C, Giannini C, Chiarelli F, et al. *ABCD1* gene mutation in an Italian family with X-linked adrenoleukodystrophy: case series. *Endocrinol Diabetes Metab Case Rep* 2021;2021:20-0125.
[PUBMED](#) | [CROSSREF](#)
2. Kemp S, Berger J, Aubourg P. X-linked adrenoleukodystrophy: clinical, metabolic, genetic and pathophysiological aspects. *Biochim Biophys Acta* 2012;1822:1465-1474.
[PUBMED](#) | [CROSSREF](#)
3. Köhler W, Curiel J, Vanderver A. Adulthood leukodystrophies. *Nat Rev Neurol* 2018;14:94-105.
[PUBMED](#) | [CROSSREF](#)
4. Tsuji S. 4. Leukodystrophies. In: Gilman S, editor. *Neurobiology of Disease*. Cambridge: Academic Press, 2007;43-49.
5. Volmrich AM, Cuénant LM, Forghani I, Hsieh SL, Shapiro LT. *ABCD1* gene mutations: mechanisms and management of adrenomyeloneuropathy. *Appl Clin Genet* 2022;15:111-123.
[PUBMED](#) | [CROSSREF](#)
6. Schmidt BJ, Greenberg CR, Allingham-Hawkins DJ, Spriggs EL. Expression of X-linked bulbospinal muscular atrophy (Kennedy disease) in two homozygous women. *Neurology* 2002;59:770-772.
[PUBMED](#) | [CROSSREF](#)