

Traumatic abdominal wall hernia with hemoperitoneum caused by blunt injury: laparoscopic exploration with mini-laparotomy repair. A case report

Euisung Jeong, MD , Hyunseok Jang, MD , Younggoun Jo, MD, PhD , Yunchul Park, MD , Naa Lee, MD ,
Jungchul Kim, MD, PhD 

Division of Trauma, Department of Surgery, Chonnam National University Hospital, Chonnam National University Medical School, Gwangju, Korea

Received: August 10, 2021
Revised: September 7, 2021
Accepted: September 13, 2021

Correspondence to

Hyunseok Jang, MD
Division of Trauma, Department of
Surgery, Chonnam National University
Hospital, Chonnam National University
Medical School, 42 Jebong-ro, Dong-
gu, Gwangju 61469, Korea
Tel: +82-62-220-5442
E-mail: bluetholic@naver.com

Traumatic abdominal wall hernia is a very rare clinical entity. Herein, we report the case of a patient who was transferred from a local clinic to the emergency department because of left lower abdominal pain. Initially, an intra-abdominal hematoma was observed on computed tomography and no extravasation was noted. Conservative treatment was initiated, and the patient's symptoms were slightly relieved. However, though abdominal pain was relieved during the hospital stay, bowel herniation was suspected in the left periumbilical area. Follow-up computed tomography showed traumatic abdominal wall hernia with hemoperitoneum in the abdomen. We performed a laparoscopic exploration of the injury site and hernia lesion. The anterior abdominal wall hernia was successfully closed.

Keywords: Nonpenetrating wounds; Abdominal injuries; Contusions; Traumatic diaphragmatic hernia

INTRODUCTION

Traumatic abdominal wall hernia (TAWH) is a very rare clinical entity. The defect is caused by the blunt injury of the abdominal wall, and intestinal prolapse occurs through this site. In such a situation, TAWH is often difficult to evaluate through a bedside physical examination because intra-abdominal muscle rupture occurs without skin penetration, and bruising and abdominal tenderness are often found when examining the area near the injury.

In patients with TAWH, the presence of other accompanying intra-abdominal injuries should be evaluated, and if any injury is

suspected, either conservative or surgical treatment should be considered. However, decision-making might be challenging.

Herein, we report the case of a patient with a traumatic abdominal wall hernia with hemoperitoneum caused by a blunt injury. Initially, an intra-abdominal hematoma was observed on computed tomography (CT). On re-examination by interventional angiography, no extravasation was observed. Conservative treatment was initiated, the patient's symptoms were slightly relieved, and the results of laboratory investigations showed improvement. However, although the abdominal pain was relieved during the hospital stay, bowel herniation was suspected in the left periumbilical area. On follow-up CT, a TAWH with slight he-

moperitoneum was seen in the abdomen. We performed laparoscopic exploration of the injury site and the anterior abdominal wall hernia was successfully closed. This case demonstrated the feasibility of a laparoscopic approach and intervention in cases of TAWH to detect suspected injuries.

CASE REPORT

A 64-year-old male patient was transferred from a local clinic to the emergency department because of left lower quadrant abdominal pain. The patient had been struck on the abdomen with rebar 5 hours ago. His initial vital signs were stable. On physical examination, there was pain in the left lower quadrant and mild rigidity throughout the abdomen. He had underlying hypertension and diabetes mellitus, and was not on any anticoagulant medications. The laboratory findings were as follows: white blood cell count $17.7 \times 10^3/\mu\text{L}$ (normal reference range, $4.8\text{--}10.8 \times 10^3/\mu\text{L}$); hemoglobin, 12.2 g/dL; aspartate aminotransferase, 23 IU/L; alanine aminotransferase, 14 IU/L; total bilirubin level, 0.59 mg/dL; and C-reactive protein, 0.6 mg/dL (normal reference range, 0.0–0.3 mg/dL). An abdominal CT scan showed suspected mesenteric injury with a small amount of hemoperitoneum in the descending portion of the aorta and lateral aspect of the left common iliac artery with a contusion injury on the anterior abdominal wall (Fig. 1).

Abdominal aortography was initially performed in the emer-

gency department. The left common iliac artery and both lumbar arteries were also examined through abdominal angiography, and no evidence of active bleeding was found.

The patient was admitted and received conservative treatment. On day 4 of admission, slight abdominal tenderness persisted in the left lower quadrant, but the rigidity of the abdomen and the results of laboratory tests showed improvement. The white blood cell count was $7.2 \times 10^3/\mu\text{L}$ (normal reference range, $4.8\text{--}10.8 \times 10^3/\mu\text{L}$) and the C-reactive protein level was <0.6 mg/dL (normal reference range, 0.0–0.3 mg/dL). However, although the symptoms had subsided, a reducible bowel herniation lesion was palpable near the area of contusion over the left lower part of the abdomen when the patient was in an upright position. When herniation occurred, the patient had severe splanchnic pain; hence, a CT examination was performed again. A slight focal defect was found in the left anterior abdominal wall, and a small amount of hemoperitoneum persisted in the intra-abdominal cavity without evidence of active bleeding (Fig. 2).

Due to the recurrence of symptoms of herniation and intra-abdominal fluid collection, immediate repair of the abdominal hernia was planned. As the CT scan showed hemoperitoneum, we decided to perform a laparoscopic exploration of the intra-abdominal cavity and herniation site. The laparoscopic examination showed a small amount of hemoperitoneum throughout the entire abdominal cavity without injuries to the other intra-abdominal organs.

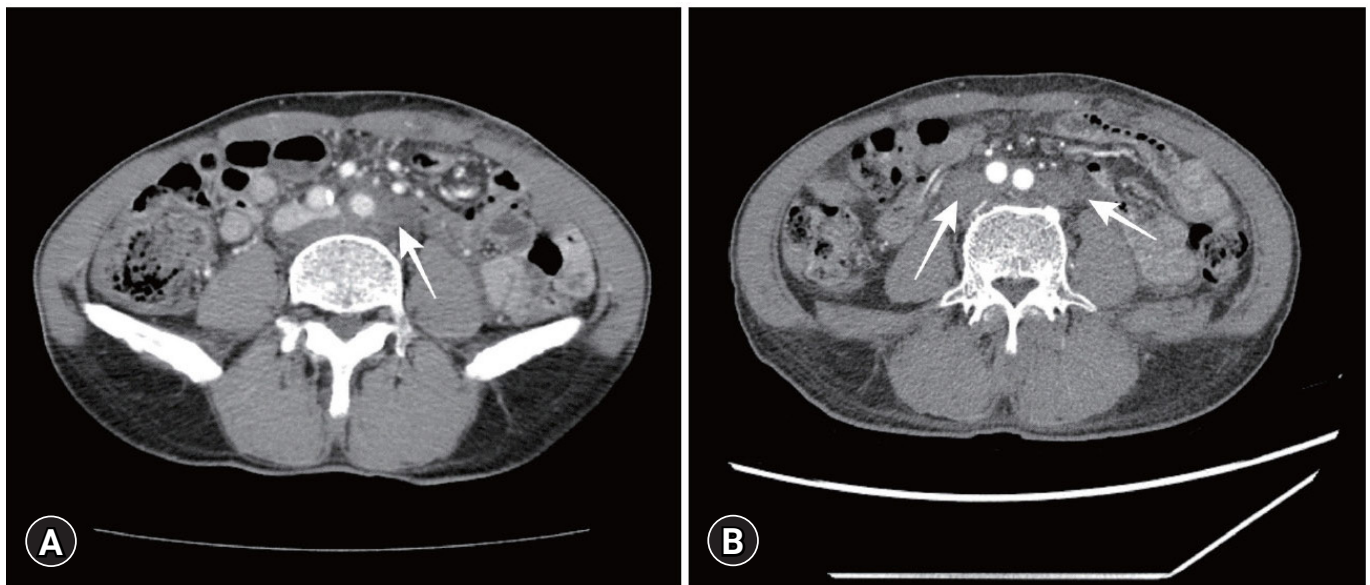


Fig. 1. (A) Hematoma (white arrow) is seen on the initial computed tomographic scan. (B) The Hounsfield unit values of the hematoma lesions, ranging from 27 to 35, suspected mesenteric injury (white arrows) with a small amount of hemoperitoneum in the descending part of the aorta and lateral aspect of the left common iliac artery. Written informed consent for the publication of the images was obtained from the patient.

On the left side of the umbilicus, a 5 × 4 cm defect in the abdominal wall was found. The defect showed loss of fascia and peritoneum, and muscle was exposed (Fig. 3). After locating and marking the abdominal wall defect externally, closure was performed layer-by-layer with non-absorbable suture material (Fig. 4). The patient was discharged 8 days after surgery with no other complications. Abdominal CT follow-up was performed 1 month after discharge and showed an improvement of hemoperitoneum at the herniation site.

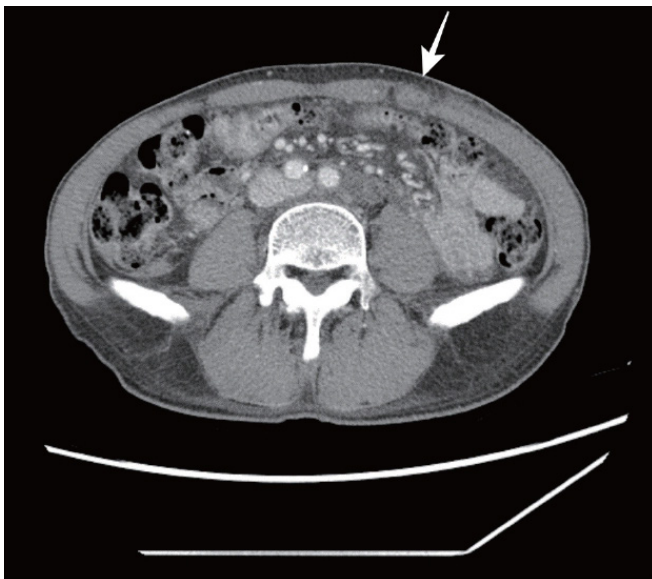


Fig. 2. A focal defect (white arrow) was found in the left anterior abdominal wall on the follow-up computed tomographic scan. Written informed consent for the publication of the image was obtained from the patient.

DISCUSSION

TAWH is a rare occurrence in patients with trauma, although some cases caused by bicycle or motorcycle handlebar injuries have been reported. Reports have indicated that it accounts for fewer than 1% of blunt trauma injuries [1,2].

In events with blunt trauma, injuries often result in bruising of the skin and bulging of the abdominal wall with hematoma. The surrounding muscles, tendons, and bones are often involved. This might lead to a delay in diagnosing the wall defects or other organ injuries due to masking of the symptoms [3,4].

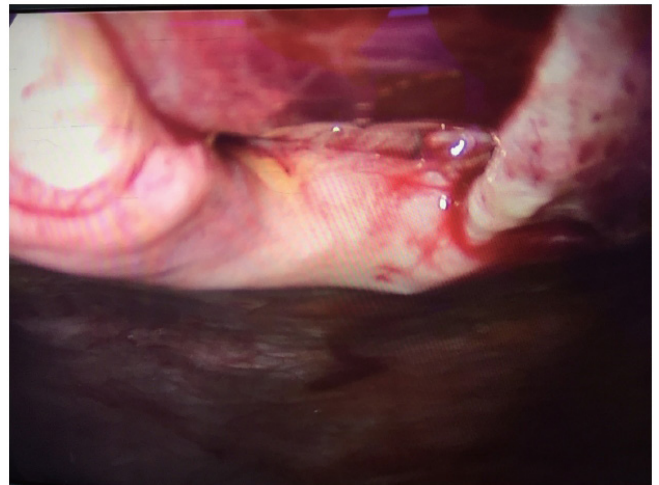


Fig. 3. Laparoscopic finding of the hernia sac in the anterior abdominal wall. Written informed consent for the publication of the image was obtained from the patient.

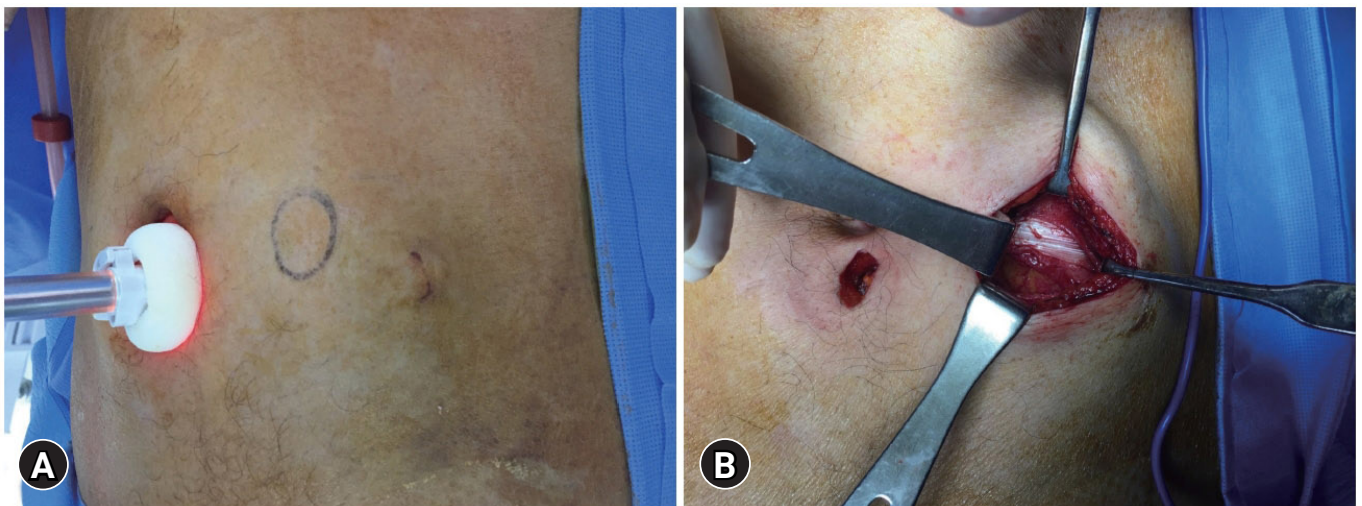


Fig. 4. (A) After locating the defect internally, the area was marked externally. (B) A minimal laparotomy incision was made for the herniation site and closure was performed. Written informed consent for the publication of the images was obtained from the patient.

Patients with anterior TAWH on clinical examination are more likely to have an associated intra-abdominal injury requiring surgical intervention. Hence, patients with abdominal wall hernias following trauma should receive a CT scan to rule out intra-abdominal injury [2,5]. Most TAWHs on the anterior abdominal wall do not show skin defects due to the elastic features of the skin, and the herniation defects occur on the rectus abdominus sheaths [6,7].

However, in our case, anterior TAWH was not clearly identified on the initial examination. Conservative treatment was administered following abdominal angiography. Upon the later onset of TAWH symptoms, CT was performed again, and it showed persistent hemoperitoneum in the abdominal cavity and a clear anterior abdominal wall defect. Based on these findings, it was decided to check for other accompanying intra-abdominal injuries.

There have been debates regarding local wound exploration versus midline exploratory laparotomy to rule out intraabdominal injuries, and Yegane et al. [6] insisted on the need for exploratory laparotomy.

In this patient, because a mesenteric injury with a small amount of hemoperitoneum was suspected, exploration of the injury site by local wound exploration might have been difficult, so midline exploratory laparotomy might have been considered to rule out intraabdominal injuries. Instead of midline laparotomy, we decided to perform laparoscopic exploration with mini-laparotomy repair

In the laparoscopic view, the defect at the TAWH site was well visualized. After locating the entire hernial sac through an intra-abdominal view, a minimal incision was made. Due to the large size of the hernia sac and defect itself, we approached it by minimal incision in case mesh insertion would be necessary. However, the fascia was fairly firm, and TAWH was successfully repaired by primary repair without mesh insertion.

Several reports of TAWH have raised questions about whether urgent laparotomy is necessary; instead, the possibility of delayed repair of herniation or non-surgical treatment has been discussed. It is difficult to consider urgent laparotomy as a standard treatment method because of its invasiveness and the possibility of recurrence of the hernia [8,9]. However, in some cases, the defect can grow and muscle atrophy might progress, making direct repair difficult.

Standard methods of laparotomy directly approach the herniation site through incisions directly in the weak layers where herniation has occurred; this direct approach might aggravate the hernia. Furthermore, several cases have been reported suggesting

that direct access and immediate hernia repair may increase the rate of surgical site infection and recurrence. Some clinicians recommend delaying hernia repair, as delayed closure allows the tissue and hematoma of the surrounding injury site to resolve, after which the margins of the muscle can be easily located and the developed hernia sac can be easily found [10,11].

In situations where an intra-abdominal injury cannot be completely excluded, such as in this case, it may be insufficient to check the intra-abdominal cavity by open laparotomy, and a diagnosis could be missed through a direct approach due to a limited view and cavity.

With recent technical improvements, herniation lesions can be repaired and intra-abdominal examinations can also be easily performed through a laparoscopic approach. Therefore, exploration and laparoscopic interventions, such as repair, can be considered. Even in cases of delayed hernia, minimally invasive laparoscopic surgery could be an alternative treatment option. The conventional treatment for hernia repair has mostly focused on the repair of the hernia itself [12]. However, in traumatic blunt injuries, it is often difficult to rule out a hollow viscus organ injury.

Since there may be cases in which detection of an accompanying injury is also necessary, intraperitoneal identification should be considered [13–15]. In such situations, if the patient's vital signs are stable, a minimally invasive intervention using the laparoscopic approach is required.

Laparoscopic treatment must be selected cautiously. Depending on the location of the blunt injury, the degree of herniation, and the hernia's content and symptoms, conservative treatment is often feasible and safe. Since there have been several cases of observation without repair, the range of indications should be maintained at an appropriate level [6]. In conclusion, in cases of TAWH, a laparoscopic approach can be helpful for herniation repair site visualization and further exploration of other injuries.

NOTES

Ethical statement

Informed consent was obtained from the patient.

Conflicts of interest

The authors have no conflicts of interest to declare.

Funding

None.

Author contributions

Project administration: EJ; Investigation: HJ; Methodology: HJ; Supervision: JK; Conceptualization: YJ, YP; Data curation: NL; Visualization: EJ; Writing—original draft: EJ; Writing—review & editing: HJ.

All authors read and approved the final copy of the manuscript.

REFERENCES

1. Honaker D, Green J. Blunt traumatic abdominal wall hernias: associated injuries and optimal timing and method of repair. *J Trauma Acute Care Surg* 2014;77:701–4.
2. Netto FA, Hamilton P, Rizoli SB, et al. Traumatic abdominal wall hernia: epidemiology and clinical implications. *J Trauma* 2006;61:1058–61.
3. Belgers HJ, Hulsewe KW, Heeren PA, Hoofwijk AG. Traumatic abdominal wall hernia: delayed presentation in two cases and a review of the literature. *Hernia* 2005;9:388–91.
4. Hernandez Cervantes BY, Martinez Lopez D, Guzman Lambert R, Rodriguez Gonzalez M, Meah M. Acute traumatic abdominal wall hernia—value of the physical examination: case report. *J Surg Case Rep* 2021;2021:rjab314.
5. Coleman JJ, Fitz EK, Zarzaur BL, et al. Traumatic abdominal wall hernias: location matters. *J Trauma Acute Care Surg* 2016;80:390–6.
6. Yegane RA, Peyvandi H, Nowrouzi S, Mosavian SA. Handlebar hernia: a rare type of abdominal wall hernia. *Acta Med Iran* 2010;48:351–2.
7. Decker S, Engelmann C, Krettek C, Muller CW. Traumatic abdominal wall hernia after blunt abdominal trauma caused by a handlebar in children: a well-visualized case report. *Surgery* 2012;151:899–900.
8. Bender JS, Dennis RW, Albrecht RM. Traumatic flank hernias: acute and chronic management. *Am J Surg* 2008;195:414–7.
9. Yadav S, Jain SK, Arora JK, et al. Traumatic abdominal wall hernia: delayed repair: advantageous or taxing. *Int J Surg Case Rep* 2013;4:36–9.
10. Rosen MJ, Krpata DM, Ermlich B, Blatnik JA. A 5-year clinical experience with single-staged repairs of infected and contaminated abdominal wall defects utilizing biologic mesh. *Ann Surg* 2013;257:991–6.
11. Damschen DD, Landercasper J, Cogbill TH, Stolee RT. Acute traumatic abdominal hernia: case reports. *J Trauma* 1994;36:273–6.
12. Wilson KL, Davis MK, Rosser JC Jr. A traumatic abdominal wall hernia repair: a laparoscopic approach. *JLS* 2012;16:287–91.
13. Suhardja TS, Atalla MA, Rozen WM. Complete abdominal wall disruption with herniation following blunt injury: case report and review of the literature. *Int Surg* 2015;100:531–9.
14. D'Elia MA, Grant RI, Kolozsvari NO, Matar MM. Motor vehicle collision with seatbelt sign and traumatic abdominal wall hernia should raise suspicion for hollow viscus injury. *Trauma Case Rep* 2019;22:100206.
15. Omar A, Laurent G, Antoinette L, Olivier M. Traumatic abdominal wall hernia—a series of 12 patients and a review of the literature. *World J Surg* 2021;45:2742–6.