



# Dissociative Identity Disorder in an Adolescent With Nine Alternate Personality Traits: A Case Study

Sang-Hun Lee<sup>1</sup>, Na Ri Kang<sup>1,2</sup>, and Duk-Soo Moon<sup>1,2</sup>

<sup>1</sup>Department of Psychiatry, Jeju National University Hospital, Jeju, Korea

<sup>2</sup>Department of Psychiatry, Jeju National University College of Medicine, Jeju, Korea

Since dissociative identity disorder (DID) has symptoms similar to schizophrenia, such as auditory hallucinations and delusional thoughts of being controlled, there are difficulties in its differential diagnosis. A 16-year-old adolescent male patient who was previously diagnosed with schizophrenia from a different hospital was admitted to our inpatient psychiatric unit for the evaluation of auditory hallucinations and suicide attempts. Through psychiatric evaluations, it was determined that the patient suffered from identity alternation, dissociation, and amnesia. As for the diagnostic evaluations, the following measures were implemented: a psychiatric interview regarding the diagnostic criteria, mental status examination, laboratory tests, brain imaging studies, electroencephalography, and full psychological test for adolescents, and the self-reported measure of the Adolescent Dissociative Experiences Scale. The patient was diagnosed with DID, and the following treatments were administered: pharmacotherapy, ego state therapy, psychoeducation regarding emotions, trauma-focused psychotherapy including stabilization, and family therapy. Following treatment, in the internal dimensions, the patient was able to recognize the nine alternate identities in charge of his emotions, which established a basis for the potential integration of identities. In the external dimensions, he showed improvements in the aspects of family conflicts and issue of school refusal. This is the first reported case of DID in an adolescent in Korea; it emphasizes the consideration of DID in the differential diagnosis of other mental illnesses such as schizophrenia, bipolar disorder, and posttraumatic stress disorder and expands the treatment opportunities for DID by sharing the procedures of ego state therapy.

**Keywords:** Dissociative identity disorder; Dissociation; Adolescents; Ego state therapy; Differential diagnosis; Trauma.

Received: March 10, 2022 / Revision: May 24, 2022 / Accepted: May 24, 2022

Address for correspondence: Duk-Soo Moon, Department of Psychiatry, Jeju National University Hospital, 15 Aran 13-gil, Jeju 63241, Korea  
Tel: +82-64-717-1850, Fax: +82-64-717-1849, E-mail: dr.moon@daum.net

## INTRODUCTION

Dissociative identity disorder (DID) is characterized by the existence of dissociative identities, disruption of identity and identity alteration, amnesia, depersonalization, and derealization [1]. Over 80% of patients with DID experience auditory hallucinations, and identity alteration is sometimes similar to the symptoms of other mental illnesses, such as delusional thoughts of being controlled. Since DID shares many of its symptoms with schizophrenia, there are difficulties associated with differential diagnosis, with errors in diagnosis leading to inappropriate treatment [2]. The patient in this case study had been diagnosed with schizophrenia and depression at a different hospital, with symptoms of auditory hallucinations and suicide attempts and a medical history that included pharmacotherapy and an inpatient treatment program. Afterwards, he was diagnosed with DID with nine

alternate personality states (alternate identities, “alter/alters”) at our clinic, underwent two hospitalization at the department of psychiatry’s closed ward, and has significantly improved symptoms through continuous outpatient treatment. This case study is the first reported case of adolescent DID in Korea and is being introduced to emphasize the importance of differential diagnosis between DID and other mental disorders, such as schizophrenia, and to share the specific treatment approach of ego state therapy that had been applied to this case.

## CASE REPORT

### Patient information

A 16-year-old male patient visited our outpatient clinic for the evaluation of auditory hallucinations and impulsive behavior of stabbing his mother’s forehead with a knife. The patient was born from a planned pregnancy with no reported medical history during the perinatal or postnatal period. The patient experienced numerous traumatic events starting

This is an Open Access article distributed under the terms of the Creative Commons Attribution Non-Commercial License (<https://creativecommons.org/licenses/by-nc/4.0>) which permits unrestricted non-commercial use, distribution, and reproduction in any medium, provided the original work is properly cited.

from his childhood, with both parents engaging in severe conflicts that resulted in a two-way domestic assault over the course of their marriage. The patient recalls his parents fighting before his eyes when he was approximately 5 years old, when his father threw an electric fan at his mother, which knocked her unconscious as it struck her head. He remembers heading to the hospital with his mother in an ambulance, trembling with fear of the possibility of his mother dying from the injury. His parents had divorced when he was about 8 years of age; for a few months following the divorce, the patient kept his eyes closed at all times, except when he was walking on the road or eating his meals. He has been bullied at school since the 1st grade, with most of his school life being spent in solitude. When he was approximately 11 years of age, the patient had witnessed his alcohol-intoxicated mother stabbing herself in the abdomen with a knife in their house. When he was about 13 years of age, the patient spent most of his time playing mobile games at home, excluding the time when he was at school. He had gotten into conflict with his mother regarding this issue, with verbal arguments escalating to the point of his mother throwing and breaking his phone repeatedly on multiple occasions. As the patient quarreled with his mother over his phone, the situation sometimes escalated to the point of his mother strangling the patient's throat or beating his mother until she had black eyes. When he was about 15 years of age (1 year prior to visiting our clinic), the patient started experiencing auditory hallucinations of three beings talking to him: someone who tells the patient to kill, another who tells the patient to kill himself, and a third one who tries to stop these two beings. The patient killed his pet turtle by chopping it with a knife, and he also caught wild pigeons from the roadside to stab them to death. Reacting to the auditory hallucinations, the patient engaged in self-harm by injuring his thighs with a knife and attempted to commit suicide by jumping from the roof of his school. Subsequently, he visited a different psychiatric clinic and started pharmacotherapy with antipsychotics and antidepressants, from the impressions of schizophrenia and depression. Although the patient faithfully followed the medication regimen, the symptoms of auditory hallucinations did not improve. Six months prior to visiting our clinic, he reacted to a voice that told him to kill a person and tried to stab his friend—who was next to him at the time—with a pen. Due to this incident, he was admitted to a closed ward of a different psychiatric clinic to receive a 2-week inpatient treatment. While the auditory hallucinations seemed to have improved since hospitalization, the patient started hearing auditory hallucinations again, starting from 3 months prior to visiting our clinic. The auditory hallucinations tended to occur when the patient was at crowded places, where the three beings—one male, one fe-

male, and one unidentified being—would start talking to him with words such as “Kill. If you do not want to, die.” Despite having increased the dosage of his medication, his auditory hallucinations did not improve to the point where the patient started to leave early from school on more frequent occasions, being unable to eat even a single bite of his school lunch. Two weeks prior to visiting our clinic, the patient's mother handed the patient a knife as she said, “If you are going to make me suffer so, why don't you rather just kill me,” while she was intoxicated with alcohol. As they were quarreling with each other, the patient stabbed his mother's forehead by accident. The patient was given recommendations for receiving treatment at an advanced hospital. The patient visited our outpatient clinic for evaluation and treatment and he was admitted to our inpatient psychiatric unit.

Written informed consent was obtained from the patient and his mother for the publication of data and images included in this article. This case study was reviewed and approved by the Institutional Review Board of the Jeju National University Hospital (IRB no. 2022-03-006).

### Clinical findings and diagnostic assessment

At the time of hospitalization at our inpatient psychiatric unit, the patient was a 174 cm-tall male adolescent weighing 88 kg, with greasy hair and poor hygiene, and had no facial expressions and spoke with a dry and monotonous voice. He said that there were three beings inside himself, and that those voices sometimes command him to stab his mother. He also reported that it was not him who stabbed his mother, but the ‘crow monster’ inside himself. He continued by saying that he was a child who could not feel any emotions. For a thorough evaluation of the patient, a psychiatric interview regarding the diagnostic criteria outlined in the Diagnostic and Statistical Manual of Mental Disorders, fifth edition (DSM-5), mental status examination, laboratory tests, brain imaging studies, electroencephalography, and full psychological test for adolescents were administered. Other than hyperprolactinemia (prolactin 67.08 µg/L), there were no noteworthy medical opinions from the laboratory test results. There were also no noteworthy medical opinions based on the brain imaging studies and electroencephalography. Results of the full psychological test for adolescents indicated a Full Scale Intelligence Quotient of 92, and the results of the projective tests suggested no cognitive distortions. In addition, there were no indications of noteworthy aspects from the results of the Minnesota Multiphasic Personality Inventory.

Regarding the ‘three beings within himself’ reported by the patient, it was necessary to have a differential diagnosis for DID. To evaluate for dissociations, the Adolescent Dissociative Experiences Scale (A-DES), which is the adolescent

version of the most commonly used measure of dissociation in clinical settings called the Dissociative Experiences Scale (DES), was administered. The DES consists of 28 items measured on the scale of 0–100, each of which is categorized into one of the following four subdimensions: identity confusion/alteration, absorption, depersonalization/derealization, and amnesia [3,4]. The A-DES consists of 30 items, each measured on a 10-point Likert-type scale; a mean total score of 3.7 in the A-DES was previously found as the standard for ‘significant dissociation’ [5]. In a study of the A-DES of Turkish adolescents, the mean total score of the A-DES was reported to be 6.2 points for the ‘dissociative disorder’ group, 3.9 points for the ‘posttraumatic stress disorder (PTSD)’ group, and approximately 2.4 points in the ‘non-clinical,’ ‘mood disorders,’ ‘attention deficit hyperactivity disorder,’ and ‘anxiety disorders’ groups [6]. A study on the validity of the A-DES in Korea reported a mean total score of 2.05 points in the ‘traumatized’ group, which was significantly higher than the score of 0.75 points in the ‘normative’ group [7].

The patient in this case study had high levels of dissociation based on a mean total score of 6.77 points on the A-DES administered during hospitalization. Regarding the item scores in the patient’s A-DES response, items such as “I have strong feelings that don’t seem like they are mine,” “Something inside of me seems to make me do things that I don’t want to do,” and “I feel like there are different people inside of me” in the identity confusion/alteration subdimension had the highest scores, all of them with 10 points. Items such as “I get confused about whether I have done something or only thought about doing it” and “I can’t figure out if things really happened or if I only dreamed or thought about them” in the amnesia subdimension also had high scores (8–10 points). However, items such as “I find myself standing outside of my body, watching myself as if I were another person” in the depersonalization/derealization subdimension were scored very low at 0 points.

Although the patient reported suffering from auditory hallucinations for almost 1 year, there were no clear observations of disorganized speech or behavior, or the negative symptoms of schizophrenia. The patient experienced disruption of identity characterized by three or more distinct personality states. He had gaps in his recall of specific past memories; childhood trauma experiences were discovered and understood thoroughly during the treatment process. In addition, the patient had multiple occasions when he failed to remember the activities that he had done in person, or was surprised when he discovered evidence of such activities after the fact. The combination of such testing results and clinical features suggests that the patient’s diagnostic impression was closer to that of DID than schizophrenia, which was his

previous diagnosis from a different clinic.

### **Therapeutic intervention**

Regarding the treatment for DID, various methods are being implemented, including pharmacotherapy, cognitive behavior therapy, and eye movement desensitization and reprocessing (EMDR) [8]. One of these methods is ego state therapy, where the clinician comes face-to-face with various ego states within the patient [9]. Ego state therapy also uses hypnosis as a treatment method and has been combined with trauma processing therapy methods (e.g., EMDR) to be developed into a therapeutic intervention for patients with symptoms of trauma and dissociation [10]. Ego state therapy aims to promote the proper functioning of a patient’s internal system, which is composed of multiple ego states, by connecting the memory of each state with those of the others, while accepting the differences that exist between the states and respecting the values of reciprocity and cooperativity [9–11]. During the course of two hospitalizations for treatment, the following were administered: psychoeducation regarding emotions, trauma-focused psychotherapy that includes stabilization, and family therapy. In addition, since the patient lacked awareness of his alters and experienced a loss of control, the clinician also utilized ego state therapy to identify and approach the patient’s alters. Pharmacotherapy was administered as an accompanying treatment to control the patient’s underlying symptoms of depression, anxiety, impulsiveness, and aggression (first hospitalization: 200 mg sertraline and 300 mg quetiapine; second hospitalization: 100 mg sertraline and 5 mg aripiprazole).

### **Follow-up and outcomes**

#### **Nine types of alternate identities**

In ego state therapy, the patient was allowed to explore the space of his mind through hypnosis with his eyes closed; the clinician and the patient have named that space the ‘Mind’s Room.’ Inside the Mind’s Room, as described by the patient, was a table, a sofa, three dogs, and 15 trees; on the ceiling, there was a large eye that could observe the inside of the room. There were four doors, each leading to either the ‘Computer Room,’ ‘Jungle,’ ‘Desert,’ or ‘Basement.’ The three alters reported by the patient could be met in the Mind’s Room; as ego state therapy progressed, the other spaces connected to the main room by the four doors were explored, resulting in the discovery of nine total alters (Table 1). Each time a new alter was discovered, the clinician could recognize the identity alteration, as the patient’s facial expression, manner and content of speech, and posture would also be changed simultaneously. There were alters that were aware of each other,

**Table 1.** Summary of the nine alternate identities

Name of alternate identity	Emotion(s) expressed by the alternate identity	Characteristics revealed through ego state therapy and the patient's drawings
Agate	Void	The patient's main state; it has become the leader of the other alters through the treatment process and is capable of controlling the other alters. Presence or absence of the horns (Fig. 1) can be an indicator of whether the patient is feeling void, or in a state where he is better at feeling emotions.
Ri_te	Sorrow	Good at feeling sorrow; when agitated, makes verbal slip-ups that include expletives. When engaging in violent and cruel behavior, it occasionally encourages such behavior from the side.
Xandra	Rage	A cynical character, who can be quite fierce at times. In the past, it was always in the shape of a monster resembling a crow; following admission, it became less fierce, and it was discovered that it had a human form.
Obsidian	Guilt (sin, fault)	This alter does not feel guilty but makes other alters feel guilty. In this process, its influence grows, which increases the probability of committing a crime. The feeling of guilt was too difficult for this alter; to become numb to guilt, it would repeatedly engage in behaviors that would induce guilt.
Tourmaline	Knowledge, disgust	The director who is in charge of the space within the Mind's Room; has almost all of the information regarding the things that have occurred within the mind.
Rose Quartz	Happiness, despair	It had been isolated and exhausted in the desert of Mind's room; since the beginning of the treatment, it has a good relationship with the others and sits straight.
Alex	Love, fear	This alter had thought that the patient was so lonely that it pushed the patient into a love relationship inappropriately with sexual jokes.
Emerald	Pure, insanity	Came into existence when the patient was 4 years old and stayed mainly in the basement of the Mind's Room; although it could leave or enter the space freely, it was completely shut-in when the patient was 10 years old and could no longer leave the Basement. Has a child-like appearance; the facial expression has become brighter since the beginning of the treatment, as the door to the basement had been opened.
The Emerald (Emma)	Insanity	The most impulsive and aggressive alter that was hidden inside the pure alter of Emerald. Takes turns with Emerald to change personality within the Mind's Room. Agate is controlling it since it has insanity and anger for people.

but there were also those who had no knowledge of the other until the clinician introduced them to each other. Among these alters, some had been perceived by the patient, whereas others were affecting the patient without the patient knowing their existence. For each of the nine alters, the patient gave names derived from birthstones. According to the patient's report, excluding 'Emerald' who came into existence when he was 4 years old, all alters were created when he was about 15 years old. Centered around 'Agate,' who served as the leader, there were dynamic relationships between the alters, with each alter playing a role related to the major emotions of the patient.

**Therapeutic process inside**

At the time of hospitalization, while the patient had some awareness of the beings inside himself, he had lost his sense of control over the auditory hallucinations and the timing of

amnesia and/or identity alteration. Through ego state therapy, the patient experienced a detailed inspection and understanding of his own ego states. In a safe treatment space that could be controlled by the clinician, the patient explored the Mind's Room together with the clinician; when the patient experienced anxiety, stabilization (such as grounding and containment) was used to control the patient's sense of anxiety. Through this process, the patient increased his awareness of his own states and had more control over himself. Since the patient was fond of drawing, he depicted the Mind's Room and each of the alters with pictures. Through the treatment process, he organized the changes in his mind by making drawings that captured the characteristics of each alter (Figs. 1 and 2).

Prior to treatment, the patient's alters increased the patient's sense of confusion by being activated separately, or by confronting each other in the patient's mind. Through the



Fig. 1. Self-portraits of the nine alternate identities, drawn by the patient.

treatment process, these alters gained awareness of each other's existence in the patient's psychic world, understood each other's positions, and acknowledged the existence of each other. When the patient was faced with difficult decisions, he occasionally found an appropriate measure by having a meeting between the alters; this was different from the past, where the alters would intemperately expose their emotions uncontrollably. As a result, the alters who were alone and isolated in the past became capable of living with each other and started to show signs of communication and understanding between them. The relationship between the alters, which have become intimate and comfortable with each other, has been depicted in the patient's drawing (Fig. 3).

Since the process of building expertise on 'acknowledging and making decisions regarding one's emotions' is accompanied by heavy responsibilities for the patient, there were moments when the patient wanted to give up his pursuit of the process. During the hospitalization period, a different female patient asked the current patient if they could meet outside the clinic. As the patient was not attracted by the female patient, he wanted to refuse the offer; however, it was difficult for the patient to behave in a manner that matched his emotions. The patient wanted to escape from the burden of such

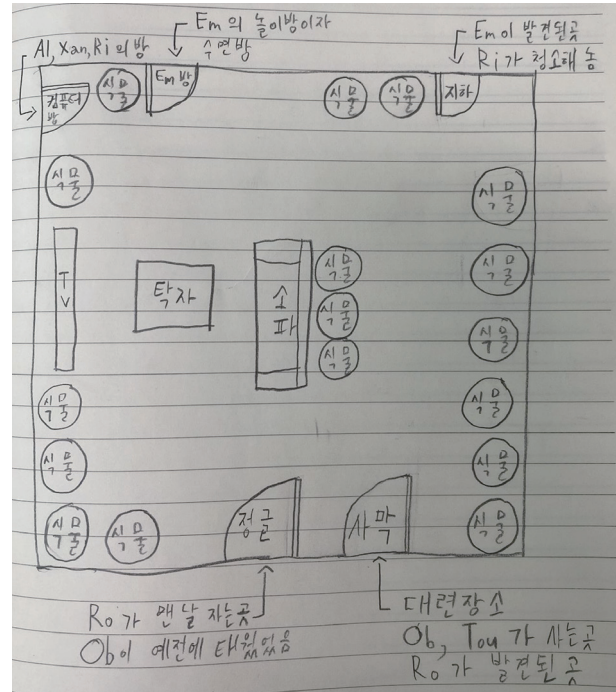



Fig. 2. The Mind's Room and its structure, as depicted by the patient. When exploring the Mind's Room for the first time through ego state therapy—together with the patient, who was in a state of hypnosis—the space had a structure similar to a living room, with actual objects such as a sofa, table, and TV; the alters Alex, Xandra, and Ri-te were in this room. The living room had three doors, each leading to either the Desert, the Jungle, or Computer Room. In the Desert, the alters Tourmaline, Obsidian, and Rose Quartz were discovered in order. As treatment progressed, the door to the basement, where the alter Emerald had been locked in, was newly discovered, freeing Emerald from the basement. When Emerald emerged from the basement, all other alters trembled with fear. The clinician believed it was necessary for Emerald—which had been locked away in the basement for a long period of time, as the alter of a young child—to get some rest and care and to be temporarily separated until the other alters' fear of Emerald had abated. Through hypnotic suggestion, a playroom was created for Emerald.

decisions and wished some other alters in his mind to take his place and make the tough decision for him. The patient retreated in his psychic world, telling the clinician that this was unbearable for him. In the absence of the controlling entity, other alters took turns appearing in front of the clinician. The clinician could associate this moment with the formation process of the patient's alters: when the patient decided that he wanted to escape from difficult emotions, the alters were created to bear the emotions in his place. However, during the treatment process, the patient realized that he cannot delegate all of his decisions to the other alters within his mind and recognized the need to behave autonomously based on the emotions he felt himself. He then communicated his polite yet honest refusal to the female patient. The patient was starting to develop his own capability, so that he no longer had to rely on the alters. The patient, who had let go of his



**Fig. 3.** Patient's drawing depicting the relationships between the alters in the latter half of the treatment, with their conflicts resolved. Early in the treatment, the alters kept each other in check, quibbling over what was right and wrong in their relationships. The alters' appearances also had an exclusive and threatening atmosphere, depicted with mostly dark colors, harsh eyes, and sharp lines (Fig. 1). As treatment progressed, the alters understood the position and reason for being of each other and began to be depicted in appearances that were freer and more comfortable within the patient's control. According to the patient's explanation, this drawing in Fig. 3 depicts the alter Obsidian, who was always living in seclusion at the Desert, starting to have a good relationship with the other alters. Here, Obsidian is being mischievous with the alter Ri\_te, suggesting that male Ri\_te is trying to wear feminine clothing. If this were a dangerous situation, Agate, which is represented as the patient himself, would have intervened to control the situation; Agate stands by and watches the mischievous situation. The patient's drawing depicts the playful communication between the alters, who used to be isolated in their own situations in the past, gathered in a single room. This describes the relationship between the alters in the latter half of the treatment, with sharp conflicts between them having been resolved.

control over emotion regulation since he was afraid of sensing his emotions, has acknowledged through the treatment process the fact that he needs emotions, as well as the ability to control them.

For the patient, whose emotions had been divided into the alters, controlling his emotions meant the same as being able to control his alters. Throughout the treatment process, the

patient's control gradually grew until he had the most influence; over time, the alters could no longer expose themselves at their will and could surface only if the patient allowed them to, in cases of necessity. In this process, the frequency of appearance of the alters decreased over time, and the patients' sense of confusion was also reduced. At the time of hospitalization, the patient reported that he could not sense emotions, and his emotions were represented by alters. For the patient who had difficulty recognizing his own emotions, it was even more difficult to empathize with the emotions of others. During treatment, the patient had experienced having his emotions understood by the hospital medical staff in a stable relationship and had received education on perceiving and expressing his emotions. Gradually, the patient was able to express his emotions with verbal terms (e.g., anger, depression, and anxiety) rather than expressing them through the activation of his alters. This is considered to be the result of the patient being less afraid of his own emotions due to the novel experience of 'a sense of security' in the treatment environment, something that he could not experience in his previous relationships.

#### Therapeutic process outside

After discharge from the first hospitalization, the patient showed a remarkable decrease in impulsive and aggressive behavior, with a decrease in the frequency of appearance of the alters; however, it was difficult for him to adapt to reality. Sensing the emotions that had been delegating to the alters on his own and determining his behavior accordingly can be considered more difficult for the patient, in a certain sense. The patient's family members have difficulty empathizing with the patient, who still finds it difficult to adapt to reality, which then worsened the conflict. In this process, a second hospitalization was performed to help the patient with emotional difficulties and adaptation.

If the first hospitalization focused on treating the patient's internal dimensions, the second admission focused on external dimensions, such as family conflicts and school refusal. By providing psychoeducation on DID to the family, the clinician attempted to help the family understand that symptoms such as dissociation and amnesia were the best means of survival for the patient in his circumstances, rather than an escape mechanism or intentional malingering from the patient. Likewise, through psychoeducation, the patient understood that it was difficult for laypersons, such as the patient's mother, to understand an illness like DID and that this process could take some time. He realized that his mother's inability to understand him was, in reality, the consequence of the difficulty she had in understanding the illness. The clinician intervened in the impulsive and hurtful speech be-

tween both parties, communicating the presence of sincere worries and love contained within such words and disentangled misunderstandings that had been left unresolved, which had occurred in multiple occasions.

Through family therapy, the family members tried to understand each other's positions; thus, the conflict between the patient and his mother decreased markedly compared to that in the past. The patient had time to self-reflect on the consequences of his immature behavior and showed a decrease in problematic behaviors. In turn, he was able to return to school and became capable of living in his daily life since his life pattern had been restored. Since he started receiving treatment at our clinic, he had better access to treatment resources, which enabled him to receive financial support for his studies. Despite such improvements, reality remains a series of difficult experiences for the patient, and there are times when he faces surges of anger, depression, and voidness. Through interventions for the patient's disruption of identity, provided through the two hospitalizations and outpatient treatment, the patient no longer suffered from the external symptoms of abrupt identity disturbance. However, the patient's inner conflict persisted, along with the feeling of depression caused by the conflict. Nevertheless, the patient chooses to sense such emotions and make judgments himself, rather than delegating the task to the alters in his mind. In a sense, this is even more difficult for the patient, but he is still living his life as he deals with such challenges. The patient is deprived of developmental experiences, has a weak ego function, and is still in his adolescence, that is, he is still immature compared to an adult. In future treatment processes, long-term procedures of 'working through' will be even more necessary to promote the continuous growth of the patient's developmental level and ego functions.

## DISCUSSION

### Dissociative identity disorder in Asian culture

There have been four cases of DID reported in Korea, all of which have been adults [12-14]. In Korea, this case study is the first reported case of DID in an adolescent. The prevalence rate of DID is reported to be significantly lower in Asian nations (0%–0.5%), compared to that reported in Western countries of North America and Europe (1%–5%) [12]. This is considered to be the consequence of previously diagnosing DID mainly as a possession disorder in Asian nations [15] and the fact that Korean clinicians are not accustomed to the diagnosis of DID [16]. Specifically, it is important to pay attention to this matter, since undiagnosed DID in Asian nations can be understood as a 'possession state' by the patient's acquaintances, leading the patient to rely on shaman-

istic interventions rather than appropriate treatment methods, in which the patient may even experience adverse effects.

### Trauma and dissociative identity disorder

In systematic ecological research, it has been observed that most DID patients have a history of severe and chronic child abuse [17]. A high proportion of patients with pathological DID also have a history of childhood trauma [18]. It has been observed that there is a statistically significant association between trauma, including physical abuse, and symptoms of dissociation [19]. Insecure attachment relationships also affect the relationship between childhood trauma and symptoms of dissociation in adulthood. This leads to imperfections in the function of resilience (i.e., vulnerability in the functionality of autonomous emotion regulation), which increases the likelihood of dissociative reactions, potentially resulting in the dissociation of identity such as identity alteration [20].

As such, repeated exposure to trauma, including childhood abuse, are painful experiences that cannot be integrated within the patient [18]. In this case, where there were many traumatic experiences, dissociation was used as a defense mechanism to protect oneself from painful experiences; by being incapable of sensing emotions, the patient could avoid the agony of such experiences. However, since emotion is an essential component of life, entities were created within the patient's psychic world to sense the patient's emotions in his place; therefore, the patient's alters acquired their characteristic emotions, each being in charge of a major one. During ego state therapy, the alters have voluntarily reported to the clinician that, "We are like vigilantes who had no choice but to mobilize, in order to protect ourselves in a state of anarchy."

### Amnesic barrier in dissociation

Through an amnesic barrier, dissociation can prevent the patient from recognizing major experiences [21]. The Mind's Room of this case was separated into different spaces by the four doors found in it. During the ego state therapy, treatment procedures conducted in a specific space were not recognized by the alters that were located in the other spaces. It seems that a dissociative barrier had been embodied in the patient's psychic world, which prevents the alters from recognizing the existence of each other depending on the characteristic or role of each alter; this is also associated with the symptoms of amnesia commonly observed in patients with dissociation. Depictions in the drawings of the patient in this case study (e.g., his alters and the structure of the Mind's Room; Figs. 1-3) are considered a useful resource for clinicians who wish to understand the internal dimensions of DID patients.

### Differential diagnosis of dissociative identity disorder

Through this case study, the authors emphasize the importance of DID diagnosis, as well as its differential diagnosis from other illnesses. Symptom patterns of DID, which are generally subtle and covert, differ from those portrayed in the media, which are more dramatic or histrionic [22]. Across studies, patients with DID spend an average of 5–12.4 years in the mental health system before correct diagnosis, receiving an average of 3–4 incorrect diagnosis [22]. For adolescents with symptoms of mental illness, such as auditory hallucinations, especially those with a history of exposure to traumatic experiences, the differential diagnosis of DID is necessary prior to the diagnosis of schizophrenia. Over 80% of patients with DID report auditory hallucinations [2], and research also suggests that patients with DID report auditory hallucinations more often than patients with schizophrenia, with both groups being younger than 18 years of age [23]. Unlike schizophrenia, DID does not have prominent symptoms of formal thought disorders or any negative symptoms [24]. For an accurate differential diagnosis, it is necessary to check whether the patient has a history of childhood trauma and whether the patient is experiencing symptoms such as amnesia, identity alteration, and dissociative experiences. For the evaluation of dissociative experiences in adolescents, measures such as the A-DES can be helpful.

Patients with DID are sometimes misdiagnosed as bipolar disorder, most commonly as bipolar II disorder. Patients with bipolar disorder are episodic and show slower mood changes; in contrast, patients with DID show rapid and subjective shifts in mood across their dissociative states [25]. Dissociation can also occur in patients with bipolar disorder; symptoms of dissociation can appear prior to the onset of bipolar disorder and are associated with a worse prognosis and larger numbers of mood swings for patients with bipolar disorder [26]. In a patient with DID and comorbid bipolar disorder, the bipolar disorder responded to pharmacotherapy, and it was only possible for psychotherapy as treatment for DID to demonstrate its efficacy after the symptoms of bipolar disorder had been controlled; thus, it can be hypothesized that the effectiveness of pharmacotherapy can be used to differentiate the two illnesses [27].

Since identity alteration observed in DID can be considered to be elaborate displays of trauma-related symptoms (e.g., intrusion and avoidance) that appear in PTSD, the two illnesses have similarities. However, since DID has distinct identities that can be identified at the conscious level (multiple “I” selves), it is different from PTSD [1].

This case had severe behavioral problems when he lost his sense of control and clearly displayed alterations between different identities during hospitalization. With high scores

of dissociation indicated on the A-DES results and reports of ‘relationships with other people being changed without the patient’s knowledge’ during the psychiatric interviews based on the diagnostic criteria of the DSM-5, the patient also reported recurring gaps in the recall of everyday events. The patient reported amnesia for the following: major accidents in the past, parental abuse, and verbal assault toward his parents. Through such evaluative and treatment procedures, the patient was diagnosed with DID, and the influence of other medical conditions, substances, or mental illnesses was ruled out by reviewing the results of the psychiatric evaluation, laboratory tests, brain imaging studies, electroencephalography, and full psychological tests for adolescents. Through such diagnostic procedures, the patient was somewhat relieved, as he started to gain an understanding of his symptoms, which had been causing him a lot of confusion.

### Conclusion

DID is occasionally misdiagnosed, making it difficult for patients to receive appropriate treatment. When childhood and adolescent traumatic experiences (e.g., school bullying, chronic abuse and neglect) are present in a patient, similar to that of this case study, the clinician need to be ready to evaluate and treat dissociative disorders. Specifically, for adolescent patients starting to develop symptoms of nonspecific psychotic symptoms including hallucination, it is necessary to have detailed evaluations of their traumatic experiences and dissociation.

### Availability of Data and Material

The datasets generated or analyzed during the study are not publicly available due to the copyright and privacy restriction, but are available from the corresponding author on reasonable request.

### Conflicts of Interest

The authors have no potential conflicts of interest to disclose.

### Author Contributions

Conceptualization: Sang-Hun Lee, Duk-Soo Moon. Data curation: Sang-Hun Lee. Formal analysis: all authors. Investigation: Sang-Hun Lee, Duk-Soo Moon. Methodology: all authors. Project administration: Sang-Hun Lee. Supervision: Na Ri Kang, Duk-Soo Moon. Writing—original draft: Sang-Hun Lee. Writing—review & editing: Duk-Soo Moon.

### ORCID iDs

Sang-Hun Lee <https://orcid.org/0000-0003-4410-9270>  
Na Ri Kang <https://orcid.org/0000-0002-2086-0927>  
Duk-Soo Moon <https://orcid.org/0000-0001-7878-3410>

### Funding Statement

None

## REFERENCES

- 1) Şar V, Dorahy MJ, Krüger C. Revisiting the etiological aspects of



- dissociative identity disorder: a biopsychosocial perspective. *Psychol Res Behav Manag* 2017;10:137-146.
- 2) **Foote B, Park J.** Dissociative identity disorder and schizophrenia: differential diagnosis and theoretical issues. *Curr Psychiatry Rep* 2008;10:217-222.
  - 3) **Bernstein EM, Putnam FW.** Development, reliability, and validity of a dissociation scale. *J Nerv Ment Dis* 1986;174:727-735.
  - 4) **Hariri AG, Gulec MY, Orengul FF, Sumbul EA, Elbay RY, Gulec H.** Dissociation in bipolar disorder: relationships between clinical variables and childhood trauma. *J Affect Disord* 2015;184:104-110.
  - 5) **Armstrong JG, Putnam FW, Carlson EB, Libero DZ, Smith SR.** Development and validation of a measure of adolescent dissociation: the Adolescent Dissociative Experiences Scale. *J Nerv Ment Dis* 1997;185:491-497.
  - 6) **Zoroglu SS, Sar V, Tuzun U, Tutkun H, Savas HA.** Reliability and validity of the Turkish version of the adolescent dissociative experiences scale. *Psychiatry Clin Neurosci* 2002;56:551-556.
  - 7) **Shin JU, Jeong SH, Chung US.** The Korean version of the adolescent dissociative experience scale: psychometric properties and the connection to trauma among Korean adolescents. *Psychiatry Investig* 2009;6:163-172.
  - 8) **Brand BL, Classen CC, McNary SW, Zaveri P.** A review of dissociative disorders treatment studies. *J Nerv Ment Dis* 2009;197:646-654.
  - 9) **Watkins HH.** Ego-state therapy: an overview. *Am J Clin Hypn* 1993;35:232-240.
  - 10) **Forgash C, Knipe J.** Integrating EMDR and ego state treatment for clients with trauma disorders. *J EMDR Pract Res* 2012;6:120-128.
  - 11) **Sugiyama T.** Ego-state therapy: psychotherapy for multiple personality disorders. *Nihon Eiseigaku Zasshi* 2018;73:62-66.
  - 12) **Kim I, Kim D, Jung HJ.** Dissociative identity disorders in Korea: two recent cases. *Psychiatry Investig* 2016;13:250-252.
  - 13) **Choe BM, Kim SH, Hahn HM, Yang CK, Eom YK.** A case of dissociative identity disorder. *J Korean Neuropsychiatr Assoc* 1996;35:1487-1491.
  - 14) **Lee JS, Nam JH.** A case of multiple personality disorder. *Ment Health Res* 1995;14:163-171.
  - 15) **Varma VK, Bouri M, Wig NN.** Multiple personality in India: comparison with hysterical possession state. *Am J Psychother* 1981;35:113-120.
  - 16) **Jung HJ.** Clinical characteristics of inpatients who were diagnosed as possession disorder [dissertation]. Seoul: Hanyang Univ.;2013.
  - 17) **Dorahy MJ, Brand BL, Sar V, Krüger C, Stavropoulos P, Martínez-Taboas A, et al.** Dissociative identity disorder: an empirical overview. *Aust N Z J Psychiatry* 2014;48:402-417.
  - 18) **Foote B, Smolin Y, Kaplan M, Legatt ME, Lipschitz D.** Prevalence of dissociative disorders in psychiatric outpatients. *Am J Psychiatry* 2006;163:623-629.
  - 19) **Brand BL, Lanius R, Vermetten E, Loewenstein RJ, Spiegel D.** Where are we going? An update on assessment, treatment, and neurobiological research in dissociative disorders as we move toward the DSM-5. *J Trauma Dissociation* 2012;13:9-31.
  - 20) **Kong SS, Kang DR, Oh MJ, Kim NH.** Attachment insecurity as a mediator of the relationship between childhood trauma and adult dissociation. *J Trauma Dissociation* 2018;19:214-231.
  - 21) **Dorahy MJ.** Dissociative identity disorder and memory dysfunction: the current state of experimental research and its future directions. *Clin Psychol Rev* 2001;21:771-795.
  - 22) **Loewenstein RJ.** Dissociation debates: everything you know is wrong. *Dialogues Clin Neurosci* 2018;20:229-242.
  - 23) **Dorahy MJ, Shannon C, Seagar L, Corr M, Stewart K, Hanna D, et al.** Auditory hallucinations in dissociative identity disorder and schizophrenia with and without a childhood trauma history: similarities and differences. *J Nerv Ment Dis* 2009;197:892-898.
  - 24) **Regier DA, Kuhl EA, Kupfer DJ.** The DSM-5: classification and criteria changes. *World Psychiatry* 2013;12:92-98.
  - 25) **American Psychiatric Association.** Diagnostic and Statistical Manual of Mental Disorders, Fifth Edition. Arlington: American Psychiatric Association; 2013.
  - 26) **Steardo L Jr, Carbone EA, Ventura E, de Filippis R, Luciano M, Segura-García C, et al.** Dissociative symptoms in bipolar disorder: impact on clinical course and treatment response. *Front Psychiatry* 2021;12:732843.
  - 27) **Lakshmanan MN, Meier SL, Meier RS, Lakshmanan R.** An archetype of the collaborative efforts of psychotherapy and psychopharmacology in successfully treating dissociative identity disorder with comorbid bipolar disorder. *Psychiatry (Edgmont)* 2010;7:33-37.