



Detection of herpesviral hematopoietic necrosis virus (Cyprinid herpesvirus 2, CyHV-2) from goldfish, *Carassius auratus* (L.) in Korea

Myung-Hwa Jung¹, Je-Won Ryu², Chamilani Nikapitiya³, Sung-Ju Jung^{2,*}

¹ Department of Marine Bio and Medical Sciences, Hanseo University, Seosan 31962, Korea

² Department of Aqualife Medicine, Chonnam National University, Yeosu 59626, Korea

³ College of Veterinary Medicine and Research Institute of Veterinary Medicine, Chungnam National University, Daejeon 34134, Korea

Abstract

In April and June 2014, mortalities of goldfish occurred at Korea. The principal signs included pale gills, severely enlarged and softened spleen and kidney and red liver. Moreover, the histopathological characteristics observed mainly in hematopoietic tissues of kidney, gill lamellae and intestine. The predominant histopathological changes were severe necrosis of hematopoietic tissue. In addition, nucleus exhibiting peripherally displaced chromatin were particularly abundant in the kidney of affected fish. The histological examination led to hypothesize the implication of a virus in the mortality. The hematopoietic necrosis herpesvirus (Cyprinid herpesvirus 2, CyHV-2) DNA polymerase gene successfully detected in DNA extracted from kidney and spleen of affected fish using PCR assay and showed 100% identity with already deposited CyHV-2 DNA polymerase gene in NCBI. Artificial infection trials using affected tissues filtrates gave cumulative mortalities of 30% for virus injected goldfish. In the present study, CyHV-2 was detected and identified as the causative pathogen of the epizootic in goldfish in Korea.

Keywords: Herpesviral hematopoietic necrosis, Cyprinid herpesvirus 2, CyHV-2, Goldfish

Introduction

Goldfish (*Carassius auratus* L.) is a freshwater fish belonging to family Cyprinidae of order Cypriniformes. Goldfish generally has strong vitality. However, several diseases can cause mortality of goldfish (Groff et al., 1998; Iqbal et al., 1999; Jung & Miyazaki, 1995). Members of the cyprinid herpesviridae family are divided into carp pox herpesvirus (Cyprinid herpesvirus 1, CyHV-

1), goldfish hematopoietic necrosis herpesvirus (Cyprinid herpesvirus 2, CyHV-2) and koi herpesvirus (Cyprinid herpesvirus 3, CyHV-3) (Davison et al., 2013; Waltzek et al., 2005). CyHV-2 causes hematopoietic necrosis, resulting in herpesviral hematopoietic necrosis. This disease first occurred in Japan (1992 and 1993), causing severe mortality (up to 100%) of goldfish (Jung & Miyazaki, 1995). Since then, CyHV-2 outbreaks in goldfish have been reported in many countries, including Australia, India,

Received: Mar 6, 2022 Revised: Jun 5, 2022 Accepted: Jun 30, 2022

*Corresponding author: Sung-Ju Jung

Department of Aqualife Medicine, Chonnam National University, Yeosu 59626, Korea

Tel: +61-659-7175, E-mail: sungju@chonnam.ac.kr

This is an Open Access article distributed under the terms of the Creative Commons Attribution Non-Commercial License (<http://creativecommons.org/licenses/by-nc/4.0/>) which permits unrestricted non-commercial use, distribution, and reproduction in any medium, provided the original work is properly cited.

Copyright © 2022 The Korean Society of Fisheries and Aquatic Science

France, Taiwan, UK, and USA (Boitard et al., 2016; Chang et al., 1999; Goodwin et al., 2006; Groff et al., 1998; Jeffery et al., 2007; Sahoo et al., 2016; Stephens et al., 2004). Moreover, CyHV-2 has been detected in prussian carp (*Carassius giberio* B.) and crucian carp (*Carassius carassius* L.) from Czech, China, Hungary, and Italy, causing massive mortality in recent years (Daněk et al., 2012; Doszpoly et al., 2011; Fichi et al., 2013; Luo et al., 2013; Wang et al., 2012). The tendency of CyHV-2 spreading globally is significant.

This study describes two cases of CyHV-2 detection in Korea. Additionally, artificial infection experiment of CyHV-2 was carried out to confirm that the cause of goldfish mortality was CyHV-2.

Materials and Methods

Two cases of Cyprinid herpesvirus 2 (CyHV-2) detection

Case I : In April 2014, mortalities of goldfish (9.9 ± 0.4 cm, 17 ± 0.7 g) occurred at a local aquarium in Korea. Fish were maintained in a 4,000 L tank with recirculating water system. Water temperature, pH and dissolved oxygen in the tank were 21°C – 22°C , 7.57 and 7.11, respectively. The estimated mortality was about 33% (230 out of 700 fish) in this incident. Affected fish showed reduced feed intake, lethargy and atypical swimming at edges of tank. Diseased fish showed pale gills, severely enlarged and softened spleen and kidney and red liver (Fig. 1A). After confirming CyHV-2 infection, all survived goldfish were sacrificed. The facility was then disinfected.

Case II : In June 2014, goldfish (3.6 ± 0.4 cm, 4.6 ± 1.1 g) were purchased from an online market. Fish started to die from 7 days after arrival. Fish showed lethargy without clinical signs. Internal organs showed gill pallor and enlarged spleen and kidney. Thinned intestinal wall was filled with transparent fluid (Fig. 1B).

Parasite and bacteriology

Goldfish gills were examined directly under microscope to identify possible parasite infections. Aseptically collected kidney from affected fish were inoculated in brain heart infusion agar (BHIA, 0.5%) (BD Difco, Sparks, MD, USA), thiosulfate citrate bile sucrose agar and salmonella shigella agar and incubated at 23°C for 2 days to identify pathogenic bacteria.

Virus inoculum preparation

The virus was prepared from kidney and spleens of affected goldfish which obtained from the above described online local

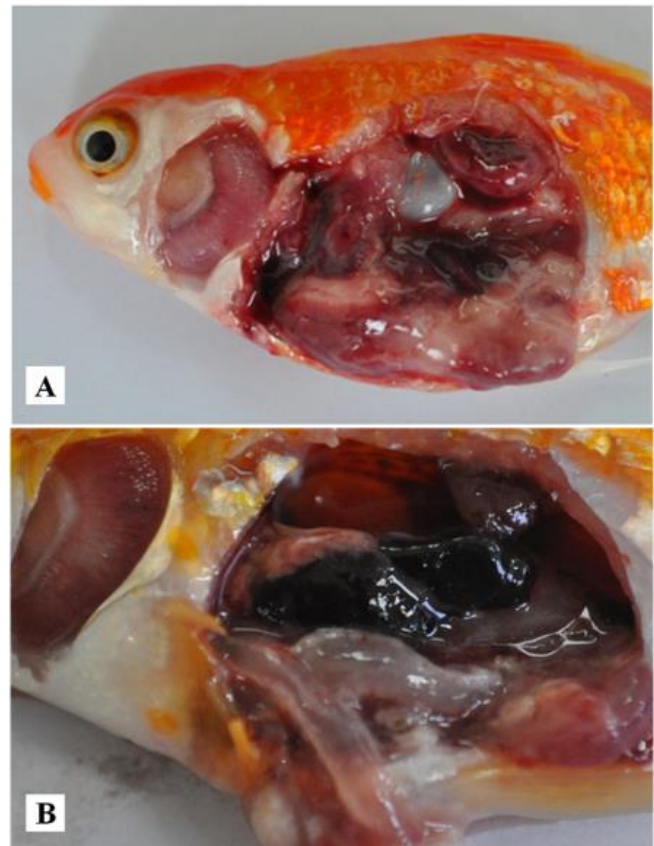


Fig. 1. Goldfish showing the gill pallor, enlarged internal organs including spleen and kidney in natural outbreak of Case I (A) and Case II (B).

fish market. The organs were added to 50-fold volumes of Dulbecco's Minimum Essential Medium (DMEM) (Gibco, Grand Island, NY, USA) and homogenized using Polytron PT 1200 E homogenizer (Kinematica, Littau, Switzerland) on ice until dissolved completely. Homogenate was centrifuged at $737\times g$ for 30 min at 4°C . Supernatant was filtered through a $0.45\text{-}\mu\text{m}$ Acrodisc[®] syringe filter (Pall, Ann Arbor, MI, USA) and considered as original virus dose and stored at -80°C until use.

Histopathological examination

For histopathological observations, dissected tissues of infected goldfish gills, heart, intestine, kidney, liver and spleen were fixed in 10% phosphate-buffered formalin solution and rinsed in tap water. Fixed tissues were serially dehydrated using ethanol and were embedded in paraffin wax using standard protocols. Sections were cut at $4\ \mu\text{m}$ using Shandon AS 325 manual microtome (Shandon, Runcorn, UK), mounted on glass slides, and

air dried overnight before staining with hematoxylin and eosin (H&E). Sections were analyzed under light microscopy and digital images were captured using NIS-Elements F software (version 3.22).

Virus identification by PCR and sequence analysis

To confirm the CyHV-2 infection, PCR was conducted by amplifying DNA polymerase gene of CyHV-2 using a primer set (F 5' CGGAATCTAGAYTTYGCNWSNYTNTAYCC 3' Y = C, T; N = ACGT; W = AT; S = CG; R = AG and R 5' CCCGAATTCAGATCTCNGTRTCNCCRTA 3') (Goodwin et al., 2006). The genomic DNA was isolated from the kidney and spleen from goldfish using an AccuPrep[®] Genomic DNA extraction kit (Bioneer, Daejeon, Korea) according to the manufacturer's instructions. Extracted genomic DNA was dissolved in 100 µL of diethyl pyrocarbonate (DEPC)-treated water and stored at -20°C until use. The PCR reactions were performed using AccuPower[®] PCR PreMix (Bioneer) in a final reaction volume of 20 µL, containing 1 µL of each primer (10 µM), 13 µL of DEPC-treated water and 5 µL of the template (genomic DNA) by MyGenie 32 Thermal Block (Bioneer). PCR amplification conditions were as follows: 94°C for 1 min, followed by 30 cycles of 94°C for 30 s, 45°C for 30 s and 72°C for 3 min (Goodwin et al., 2006).

The amplified PCR products of virus were analyzed in 1.5% agarose gels containing ethidium bromide and visualized under UV light. The PCR products were resolved from the agarose gel, and purified using AccuPrep[®] Gel purification kit (Bioneer) and cloned into pGEM[®]-T easy vector for sequencing (Bioneer) according to manufacturer's protocol. The resulted sequence was used to search for similarity using BLASTN of NCBI.

Virus infection experiment

For experimental infections, a total number of 60 healthy goldfish (10.4 ± 1.1 cm, 16.9 ± 0.5 g) were obtained from local fish farm in Suncheon, Jeollanam-do, Korea. Five randomly selected fish were confirmed to be free from pathogens (the absence of parasites under microscopic observation, absence of bacteria on BHIA and no amplified CyHV-2 DNA polymerase gene product by PCR). Fish were maintained 2 weeks in quarantine room before challenge test.

Fish were intra-peritoneally (i.p.) injected with kidney and spleen filtrate (100 µL/fish) at the original concentration (1:50 w/v diluted with DMEM) and at 10-, 100-, and 1,000- fold dilutions. Phosphate buffered saline (100 µL/fish) was i.p. injected into control fish. Each group (10 fish per group) was maintained

at 21°C for 30 days in the aquaria containing 30 L of fresh water. All dead fish in the CyHV-2 infection group were collected for the PCR assay of the pathogen and histological observation of the infected tissues.

Results and Discussion

In April 2014 sample (Case I), a few *Dactylogyrus* sp. in affected gills were observed. In addition, a bacterium was isolated from two out of three fish examined shared high homology with 16S rRNA sequences of *Aeromonas* spp.: 97.1% with *Aeromonas* sp. (accession number: HQ436040.1), 96.6% with *Aeromonas hydrophilia* (accession number: HQ731685.1) and 96.1% with *Aeromonas veronii* (accession number: FJ940850.1). Lethal dose 50 from the infection experiment using the isolated bacterium was calculated to be 5×10^5 CFU/fish (data not shown). No bacterium was grown from 'Case II' of the June 2014 sample.

In both natural disease cases in this study, clinical signs of gill pallor and enlargement of spleen and kidney were similar to those reported previously (Groff et al., 1998; Jeffery et al., 2007; Jung & Miyazaki, 1995). Red liver was shown only in 'Case I'. It might be due to mixed infection by *Aeromonas* sp. Several *Aeromonas* spp. can cause goldfish mortality (Iqbal et al., 1999; Wiklund & Dalsgaard, 1998). Moreover, CyHV-2 detection associated with *A. hydrophila* or *Aeromona sobria*, similar to 'Case I', has been reported in crucian carp in Italy and goldfish in India (Claudio et al., 2017; Fichi et al., 2013; Sahoo et al., 2016). Further characterization, identification and the effect of mixed infection of isolated bacteria with CyHV-2 on goldfish mortality are necessary.

To confirm CyHV-2 infection, CyHV-2 polymerase gene (expected size, 520 bp) was amplified from kidney and spleen pools of all naturally infected fish (3 fish from 'Case I' and 5 fish from 'Case II'). Nucleotide sequences of PCR products shared 100% similarities with seven sequences deposited at GenBank (accession numbers: DQ085626.1, DQ085627.1, DQ085628.1, HM014349.1, JQ740764.1, JQ740765.1, and AB709903.1). They also shared 99% sequence homologies with another two sequences (AY939863.1 and KC841411.1), indicating that these goldfish were infected by CyHV-2.

For experimental infections, a total of 60 healthy goldfish were i.p. injected with kidney and spleen filtrate (100 µL/fish) at the original concentration and at 10-, 100-, and 1,000- fold dilutions. Original concentration group began to die from 10 days post infection and cumulative mortality reached 30% for 30

days. Mortalities in the 10-, 100-, and 1,000-fold diluted groups were 30%, 20%, and 0%, respectively. However, the control group did not show any mortality (Fig. 2). CyHV-2 infection was confirmed by amplification of CyHV-2 polymerase gene product from kidney of dead goldfish.

Naturally infected fish in 'Case I' showed extensive necrosis in the splenic pulp and hematopoietic tissue of the kidney. Some enlarged nucleus with peripherally displaced chromatin, which is characteristic of CyHV-2 infection, was shown in the spleen and kidney (Fig. 3A and 3B). Only in 'Case I', bacterial colonies were existed in the macrophage-like cells in the spleen and kidney (Fig. 2A). Fusion of secondary gill lamella by abnormal hyperplasia of gill epithelial cells was found but there was no necrotic change. Liver parenchymal cells were not damaged but had many cellular debris in expanded central veins. Cellular debris might be necrotised cells entering the central vein from other organs. In the intestine, the mucus epithelium was sloughed to the lumen with severe necrosis of epithelial cells. Natural infection in 'Case II' showed severe necrosis in the spleen and hematopoietic tissue of the kidney, including nuclei

with karyopyknosis and karyorrhesis with some peripherally displaced chromatin in the nucleus (Fig. 3C). There was no specific change in other tissues. Histopathological change of dead goldfish from experimental infection exhibited extensive necrosis in the kidney and spleen (Fig. 3D). However, other tissues such as liver, heart, and intestine were normal. In the gills, the fusion of secondary gill lamella showed abnormal hyperplasia of gill epithelial cells, but at similar level to those in the non-infected control.

In other reports, necrosis by CyHV-2 infection has been shown in hematopoietic tissues of kidney and spleen with enlarged nucleus and peripherally displaced chromatin (Goodwin et al., 2006; Jung & Miyazaki, 1995; Stephens et al., 2004). Histopathological changes of 'Case II' and 'experimentally infected fish' were having similarly severe necrosis of hematopoietic tissue and splenic pulp. Peripherally displaced chromatin was also observed as previous reports. Histopathology of 'Case I' also exhibited characteristic histopathological changes of CyHV-2. However, it had additional alterations such as necrotic cells in blood vessels and sloughed intestinal epithelial layer into the

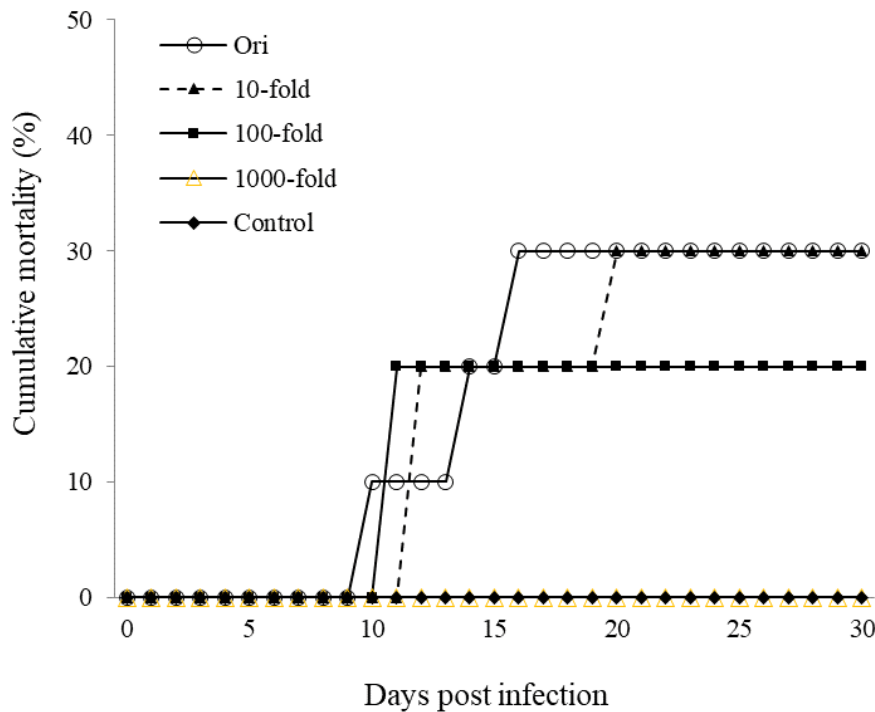


Fig. 2. Cumulative mortality of goldfish (10.4 ± 1.1 cm, 16.9 ± 0.5 g) intra-peritoneally infected with different doses of Cyprinid herpesvirus 2 at 21°C (serial dilution 10-fold steps). ○, Original concentration; ▲, 10-fold diluted; ■, 100-fold diluted; ◆, 1,000-fold diluted; △, Control (phosphate buffered saline; 100 µL/fish).

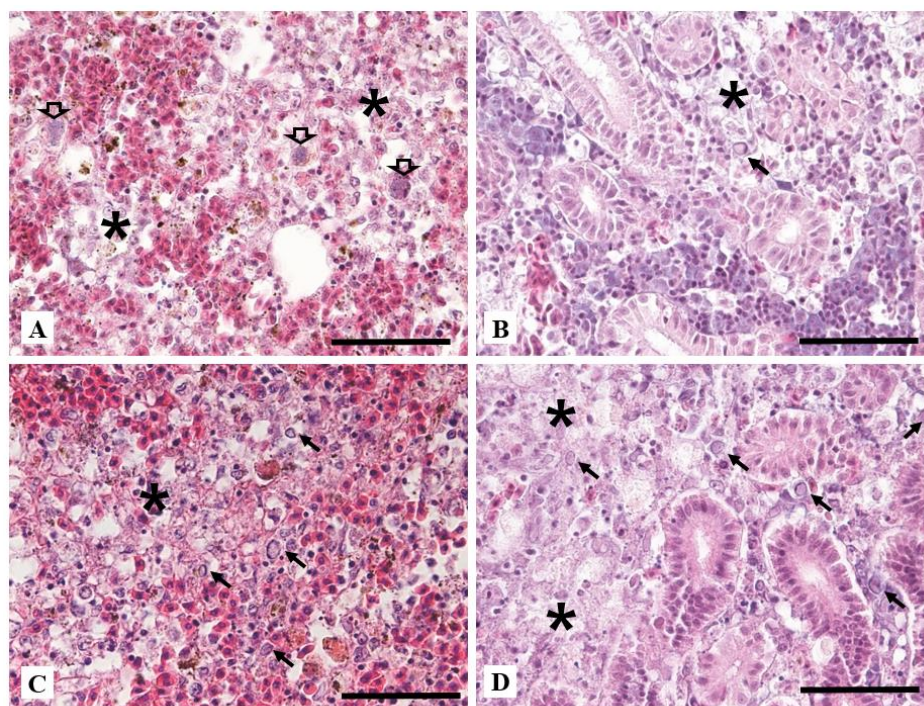


Fig. 3. Histopathological changes from naturally infected (A and B: 'Case I' was co-infected with *Aeromonas* sp., C: 'Case II') and artificially infected (D) goldfish. (A) Extensive necrosis (*) of spleen with bacteria, probably *Aeromonas* sp., engulfed by macrophage-like cells (arrows) (H&E staining, bar = 50 μ m). (B) Necrosis of hematopoietic tissue (*) with enlarged nucleus having peripherally displaced chromatin (arrow) (H&E staining, bar = 50 μ m). (C) Severe necrosis (*) of splenic pulp exhibiting karyopyknosis, karyorrhexis and enlarged nucleus with peripherally displaced chromatin (arrows) (H&E staining, bar = 50 μ m). (D) Diffuse necrosis (*) with peripherally displaced chromatin (arrows) in hematopoietic tissue of the kidney with normal appearance of tubules (H&E staining, bar = 50 μ m).

lumen. These might be due to co-infection by *Aeromonas* sp.

Most ornamental fish including goldfish in South Korea are imported from the countries such as China, Singapore, and Japan. Generally, they are distributed to various places through online or local wholesale markets. Their disease status is mostly unknown. Goldfish died at aquarium in April 2014 in this study were bought from a local wholesaler collecting goldfish from various sources. Song et al. (2008) detected CyHV-2 by PCR from December 2016 to November 2017 then showed 33.3% of pearlscale goldfish *C. auratus* imported from Singapore were positive for CyHV-2. Surprisingly, similar percentage, 27.8%, of domestic goldfish were also CyHV-2 positive means the virus has already been widespread throughout Korea at the year 2016 and 2017. Not much attention has been paid to disease diagnosis or disease etiology of ornamental fish because of lower economic value. More attention is needed for ornamental fish to prevent foreign pathogens become indigenous.

Competing interests

No potential conflict of interest relevant to this article was reported.

Funding sources

Not applicable.

Acknowledgements

Not applicable.

Availability of data and materials

Upon reasonable request, the datasets of this study can be available from the corresponding author.

Ethics approval and consent to participate

This study was carried out in accordance with the guidelines and permission by Institutional Animal Care and Use Com-

mittee of Chonnam National University (permit number: CNU IACUC-YS-2016-3).

ORCID

Myung-Hwa Jung <https://orcid.org/0000-0002-9521-3804>
 Je-Won Ryu <https://orcid.org/0000-0002-6958-3289>
 Chamilani Nikapitiya <https://orcid.org/0000-0001-6273-9271>
 Sung-Ju Jung <https://orcid.org/0000-0002-9171-6543>

References

- Boitard PM, Baud M, Labrut S, de Boisséson C, Jamin M, Bigarré L. First detection of Cyprinid herpesvirus 2 (CyHV-2) in goldfish (*Carassius auratus*) in France. *J Fish Dis*. 2016;39:673-80.
- Chang PH, Lee SH, Chiang HC, Jong MH. Epizootic of herpes-like virus infection in goldfish, *Carassius Auratus* in Taiwan. *Fish Pathol*. 1999;34:209-10.
- Claudio C, Pastorino P, Prato R, Burioli EAV, Peletto S, Righetti M, et al. CyHV-2 outbreak associated with *Aeromonas* spp. in crucian carp (*Carassius carassius*) in Piedmont (Italy). In: Berillis P, editor. *Trends in fisheries and aquatic animal health*. Sharjah: Bentham Science; 2017. p. 307-14.
- Daněk T, Kalous L, Veselý T, Krásová E, Reschová S, Rylková K, et al. Massive mortality of Prussian carp *Carassius gibelio* in the upper Elbe basin associated with herpesviral hematopoietic necrosis (CyHV-2). *Dis Aquat Organ*. 2012;102:87-95.
- Davison AJ, Kurobe T, Gatherer D, Cunningham C, Korf I, Fukuda H, et al. Comparative genomics of carp herpesviruses. *J Virol*. 2013;87:2908-22.
- Doszpoly A, Benko M, Csaba G, Dan Á, Lang M, Harrach B. Introduction of the family *Alloherpesviridae*: the first molecular detection of herpesviruses of cyprinid fish in Hungary. *Magy Allatorvosok Lapja*. 2011;133:174-81.
- Fichi G, Cardeti G, Cocumelli C, Vendramin N, Toffan A, Eleni C, et al. Detection of Cyprinid herpesvirus 2 in association with an *Aeromonas sobria* infection of *Carassius carassius* (L.), in Italy. *J Fish Dis*. 2013;36:823-30.
- Goodwin AE, Khoo L, LaPatra SE, Bonar C, Key DW, Garner M, et al. Goldfish hematopoietic necrosis herpesvirus (Cyprinid herpesvirus 2) in the USA: molecular confirmation of isolates from diseased fish. *J Aquat Anim Health*. 2006;18:11-8.
- Groff JM, LaPatra SE, Munn RJ, Zinkl JG. A viral epizootic in cultured populations of juvenile goldfish due to a putative herpesvirus etiology. *J Vet Diagn Invest*. 1998;10:375-8.
- Iqbal MM, Tajima K, Ezura Y. Pathogenicity of motile *Aeromonas* species isolated from fishes with epizootic ulcerative syndrome (EUS) in Southeast Asian countries. *Bull Fish Sci Hokkaido Univ*. 1999;50:93-100.
- Jeffery KR, Bateman K, Bayley A, Feist SW, Hulland J, Longshaw C, et al. Isolation of a Cyprinid herpesvirus 2 from goldfish, *Carassius auratus* (L.), in the UK. *J Fish Dis*. 2007;30:649-56.
- Jung SJ, Miyazaki T. Herpesviral haematopoietic necrosis of goldfish, *Carassius auratus* (L.). *J Fish Dis*. 1995;18:211-20.
- Luo YZ, Lin L, Liu Y, Wu ZX, Gu ZM, Li LJ, et al. Haematopoietic necrosis of cultured Prussian carp, *Carassius gibelio* (Bloch), associated with Cyprinid herpesvirus 2. *J Fish Dis*. 2013;36:1035-9.
- Sahoo PK, Swaminathan TR, Abraham TJ, Kumar R, Pattanayak S, Mohapatra A, et al. Detection of goldfish hematopoietic necrosis herpes virus (Cyprinid herpesvirus-2) with multi-drug resistant *Aeromonas hydrophila* infection in goldfish: first evidence of any viral disease outbreak in ornamental freshwater aquaculture farms in India. *Acta Trop*. 2016;161:8-17.
- Song HD, Park JS, Kwon SR. Molecular evidence of Cyprinid herpesvirus 2 (CyHV-2) in domestic goldfish *Carassius auratus* and imported pearlscale goldfish *Carassius auratus*. *Korean J Fish Aquat Sci*. 2018;51:383-8.
- Stephens FJ, Raidal SR, Jones B. Haematopoietic necrosis in a goldfish (*Carassius auratus*) associated with an agent morphologically similar to herpesvirus. *Aust Vet J*. 2004;82:167-9.
- Waltzek TB, Kelley GO, Stone DM, Way K, Hanson L, Fukuda H, et al. Koi herpesvirus represents a third cyprinid herpesvirus (CyHV-3) in the family *Herpesviridae*. *J Gen Virol*. 2005;86:1659-67.
- Wang L, He J, Liang L, Zheng X, Jia P, Shi X, et al. Mass mortality caused by Cyprinid herpesvirus 2 (CyHV-2) in Prussian carp (*Carassius gibelio*) in China. *Bull Eur Assoc Fish Pathol*. 2012;32:164-73.
- Wiklund T, Dalsgaard I. Occurrence and significance of atypical *Aeromonas salmonicida* in non-salmonid and salmonid fish species: a review. *Dis Aquat Organ*. 1998;32:49-69.