



Reconstruction of Pharyngolaryngeal Defects with the Ileocolon Free Flap: A Comprehensive Review and How to Optimize Outcomes

Joseph M. Escandón, MD¹ Eric Santamaría, MD² Peter A. Prieto, MD, MPH³
 Daniela Duarte-Bateman, MD⁴ Pedro Ciudad, MD, PhD^{5,6} Megan Pencek, MD¹
 Howard N. Langstein, MD¹ Hung-Chi Chen, MD, PhD, FACS⁶ Oscar J. Manrique, MD, FACS¹

¹Division of Plastic and Reconstructive Surgery, Strong Memorial Hospital, University of Rochester Medical Center, Rochester, New York

²Department of Plastic and Reconstructive Surgery, Hospital General Dr. Manuel Gea Gonzalez, National Cancer Institute, Mexico City, Mexico

³Surgery Department, University of Rochester Medical Center, New York; Wilmot Cancer Institute, University of Rochester Medical Center, New York

⁴Division of Plastic and Reconstructive Surgery, Cleveland Clinic, Ohio

⁵Department of Plastic, Reconstructive and Burn Surgery, Arzobispo Loayza National Hospital, Lima, Peru

⁶Department of Plastic Surgery, China Medical University Hospital, Taichung, Taiwan

Address for correspondence Oscar J. Manrique, MD, FACS, Division of Plastic and Reconstructive Surgery, Strong Memorial Hospital, University of Rochester Medical Center, Rochester, NY 14642 (e-mail: oscarj.manrique@gmail.com).

Arch Plast Surg 2022;49:378–396.

Abstract

Several reconstructive methods have been reported to restore the continuity of the aerodigestive tract following resection of pharyngeal and hypopharyngeal cancers. However, high complication rates have been reported after voice prosthesis insertion. In this setting, the ileocolon free flap (ICFF) offers a tubularized flap for reconstruction of the hypopharynx while providing a natural phonation tube. Herein, we systematically reviewed the current evidence on the use of the ICFF for reconstruction of the aerodigestive tract. A systematic literature search was conducted across PubMed MEDLINE, Web of Science, ScienceDirect, Scopus, and Ovid MEDLINE(R). Data on the technical considerations and surgical and functional outcomes were extracted. Twenty-one studies were included. The mean age and follow-up were 54.65 years and 24.72 months, respectively. An isoperistaltic or antiperistaltic standard ICFF, patch flap, or chimeric seromuscular-ICFF can be used depending on the patients' needs. The seromuscular chimeric flap is useful to augment the closure of the distal anastomotic site. The maximum phonation time, frequency, and sound pressure level (dB) were higher with ileal segments of 7 to 15 cm. The incidence of postoperative leakage ranged from 0 to 13.3%, and the majority was occurring at the coloesophageal junction. The revision rate of the microanastomosis ranged from 0 to 16.6%. The

Keywords

- ▶ ileum
- ▶ colon
- ▶ hypopharyngeal neoplasms
- ▶ reconstructive surgical procedures
- ▶ free tissue flaps
- ▶ laryngectomy

DOI <https://doi.org/10.1055/s-0042-1748652>.
 ISSN 2234-6163.

© 2022. The Korean Society of Plastic and Reconstructive Surgeons. All rights reserved.

This is an open access article published by Thieme under the terms of the Creative Commons Attribution-NonDerivative-NonCommercial-License, permitting copying and reproduction so long as the original work is given appropriate credit. Contents may not be used for commercial purposes, or adapted, remixed, transformed or built upon. (<https://creativecommons.org/licenses/by-nc-nd/4.0/>)

Thieme Medical Publishers, Inc., 333 Seventh Avenue, 18th Floor, New York, NY 10001, USA

ICFF provides a reliable and versatile alternative for reconstruction of middle-size defects of the aerodigestive tract. Its three-dimensional configuration and functional anatomy encourage early speech and deglutition without a prosthetic valve and minimal donor-site morbidity.

Head and neck cancers are the sixth most common type of malignancies worldwide with a high mortality rate, reaching approximately 375,000 deaths per year.¹ Local and regional recurrence rates have been reported similar with radiotherapy in comparison to surgical resection; therefore, radiation has become the standard of care for early-stage hypopharyngeal and laryngeal cancer.² In advanced-stage disease, free-margin surgical resections are required. In these cases, as primary closure is impractical and there is an associated risk of fistulas, free tissue transfer (FTT) becomes necessary.^{2,3} In fact, with the implementation of organ preservation protocols in the treatment of laryngeal and hypopharyngeal cancer, surgery is often performed in a salvage setting in which extensive defects and significant local toxicity can cause a higher complication rate when comparing primary closure versus FTT.⁴

Different speech rehabilitation techniques have been reported following pharyngolaryngectomy including esophageal speech, the use of electrolarynx, or tracheoesophageal puncture (TEP) with voice prosthesis insertion.⁵ In this context, the most common reconstructive alternatives used to restore the continuity of the aerodigestive tract for subsequent voice prosthesis insertion are the jejunal free flap or fasciocutaneous flaps.^{2,6,7} These methods have achieved reasonable results in swallowing and voice function but are not without disadvantages as a high incidence of leakage has been recognized at the anastomosis sites or following TEP. To avoid the insertion of a prosthetic valve, some institutions have advocated to use an extra portion of fasciocutaneous flaps to form a skin tube, recreating a voice shunt between the airway and esophagus.⁸ Nonetheless, this method does not provide a valve between the trachea and digestive tract, and sebaceous material from the skin or food impaction can obstruct the shunt.^{6,8} Therefore, the only flap that provides a natural voice tube with an inherent unidirectional valve that assists in the passage of air from the trachea to the pharynx and prevents regurgitation of food or saliva into the airway with a self-cleansing capacity is the ileocolon free flap (ICFF). Herein, we performed a review with a systematic search of the current evidence on the use of the ICFF for reconstruction of defects following pharyngolaryngectomy, and we provide several technical considerations to optimize the surgical and clinical outcomes.

Methods

A systematic search was conducted across PubMed Medline, Web of Science, ScienceDirect, Scopus, and Ovid MEDLINE(R) using the following search terms: ((ileocolon) OR (ileocolic)

OR (Ileocolonic) OR (Ileocecal)) AND ((Free flap) OR (Free tissue transfer) OR (Free tissue flaps) OR (Microsurgical reconstruction) OR (microvascular anastomosis) OR (autologous reconstruction) OR (autologous reconstructive) OR (autograft) OR (Free graft)) (► **Supplementary Table S1**, available in the online version). The inclusion and exclusion criteria are displayed in ► **Table 1**.

The level of evidence was evaluated using the Oxford Centre for Evidence-Based Medicine (OCEBM).⁹ The risk of bias was evaluated using the Newcastle–Ottawa Scale (NOS) for observational cohort studies and case-control studies, while the Methodological Quality Assessment Tool (MQAT) was used for case reports and case series (► **Supplementary Table S2**, available in the online version).^{10,11}

Flap Design and Surgical Technique

The standard isoperistaltic ICFF was initially described by Kawahara and colleagues. After positioning the bowel segment in the recipient bed, the cecum was anastomosed end to side to the pharynx proximally and the ascending colon was anastomosed end to end to the remaining esophagus. For the phonation shunt, a tracheostoma was opened in the anterior wall of the trachea, leaving at least three tracheal rings between the tracheal stump and the new tracheostoma. Subsequently, while a 28-F tube was inserted through the ileum, the anterior and posterior aspects of the cecum were wrapped around the terminal ileum and sutured as a cecal plication.¹² Then, the ileum was anastomosed in an end-to-end fashion to the tracheal stump (► **Fig. 1**).¹²

In patients who underwent an extensive pharyngolaryngectomy with resection of the rhinopharyngeal mucosa, soft palate, and both tonsillar fossae, an antiperistaltic ICFF was

Table 1 Inclusion and exclusion criteria

| Inclusion criteria |
|-----------------------------------------------------------------------------------------|
| • Patient-based studies |
| • Reconstructive procedures of the aerodigestive tract using an ileocolon free flap |
| • Clinical studies reporting surgical outcomes |
| • Studies written in English |
| Exclusion criteria |
| • Review articles |
| • Studies including pedicled ileocolon flaps |
| • Studies including pedicled ileocolon flaps with microvascular blood flow augmentation |
| • Preclinical studies or animal studies |

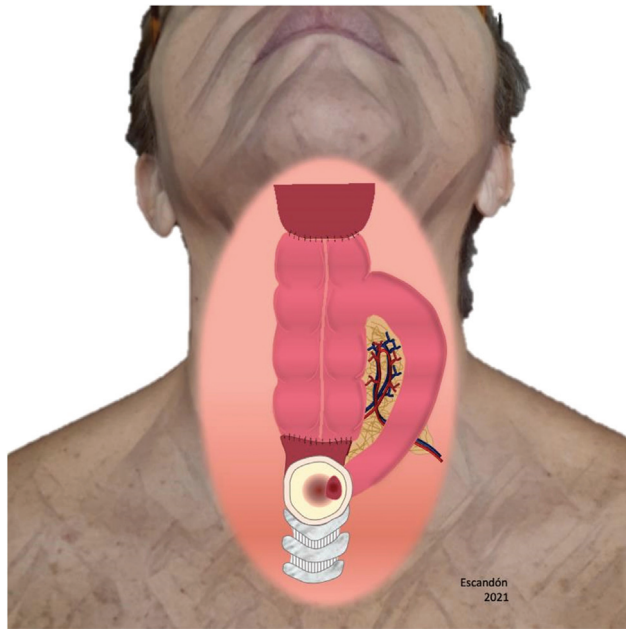


Fig. 1 Standard isoperistaltic ileocolon free flap (indication: total pharyngolaryngectomy).

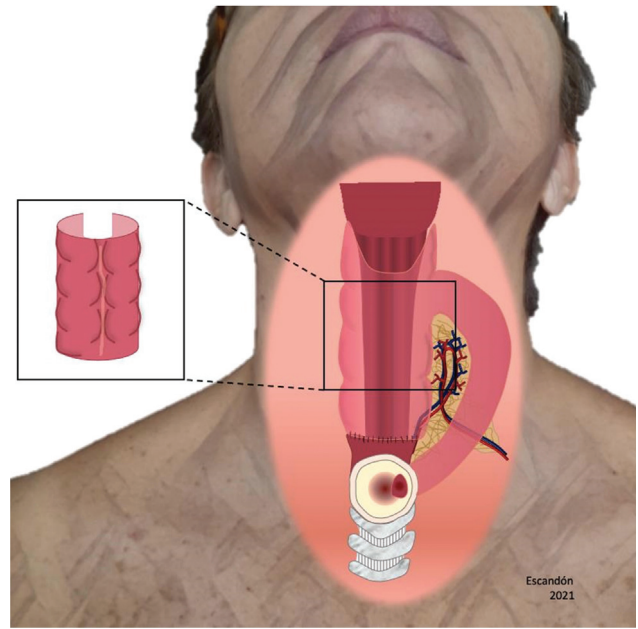


Fig. 2 Detubularized ileocolon free flap (indication: anterior pharyngolaryngectomy).

versatile due to the wide diameter of the ascending colon. In these cases, the ascending colon was sutured above to the rhinopharynx and below to the isthmus faucium, while the cecum was sutured to the esophageal stump using an end-to-side anastomosis.¹³ Sartoris et al strengthened the ileocecal valve continence by performing a single or double row of Lembert's suture along the ileal tract instead of performing the cecal plication described by Kawahara et al¹²⁻¹⁴

The detubularized ICFF was resourceful when the posterior pharynx was spared during anterior pharyngolaryngectomies.¹⁵ Succo et al developed this technique with the same technical considerations aforementioned. However, the colon segment was sectioned along the antimesenteric tenia.¹⁵ These borders were then sutured to the posterior hypopharyngeal wall, and the proximal and distal anastomosis were performed ordinarily (► **Fig. 2**).¹⁵ The ileocolon patch flap was reported by Kobayashi et al using a partially resected cecum in conjunction with the terminal ileum.¹⁶ This reconstructive option was practical in patients who have undergone only a laryngectomy. The patch flap was sutured to the anterior hypopharyngeal wall using a layer-to-layer closure. Phonation was reestablished by anastomosing the ileum to the proximal end of the trachea. Similarly, the diameter of the terminal ileum was tightened down by placing three or four additional sutures in the intestinal serosa (► **Fig. 3**).¹⁶

Mardini et al reported the reverse ileocolon free "Funnel Flap" for high pharyngeal and esophageal defects to avoid potential size mismatch at the proximal and distal ends which was habitually encountered when free jejunal and colon flaps were used.¹⁷ The flap was inset in an antiperistaltic manner. The ascending colon was anastomosed to the pharyngeal end and the ileum was anastomosed to the esophageal stump, both in an end-to-end fashion.¹⁷ A valvuloplasty of the ileocecal valve was required to overcome the one-way nature of the ileocecal valve and was performed

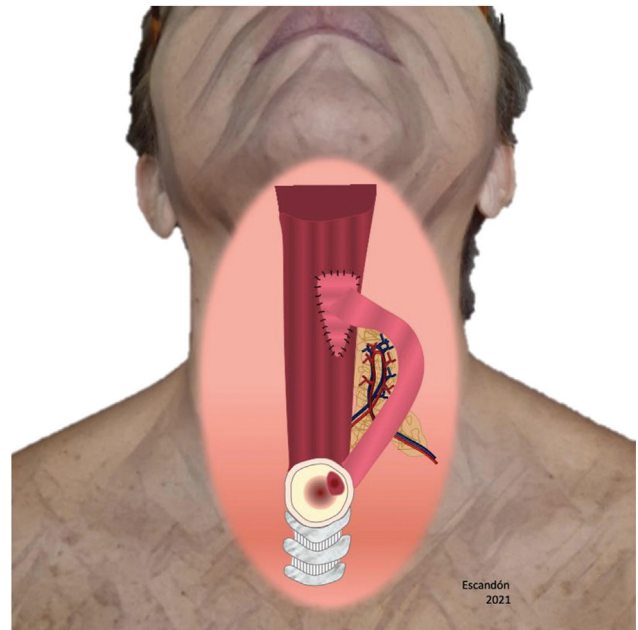


Fig. 3 Ileocolon patch flap (indication: laryngectomy).

by means of full thickness longitudinal incision along the distal 3-cm of the ileum and the proximal 3-cm of the cecum. The valvuloplasty was finalized with closure of the full thickness incision in the opposite direction (► **Fig. 4**).¹⁷

The chimeric seromuscular ICFF (CS-ICFF) was a reconstructive alternative, specifically designed to prevent leakage around the distal anastomosis. The ICFF was raised routinely; however, an additional 7 cm × 3 cm × 0.5 cm segment of the ileal loop was isolated from the border of the ileum. The mesenteric vascular arcades connecting the ileal segment to the main flap were consecutively ligated until sufficient mobility was attained. After the mucosa was removed, the

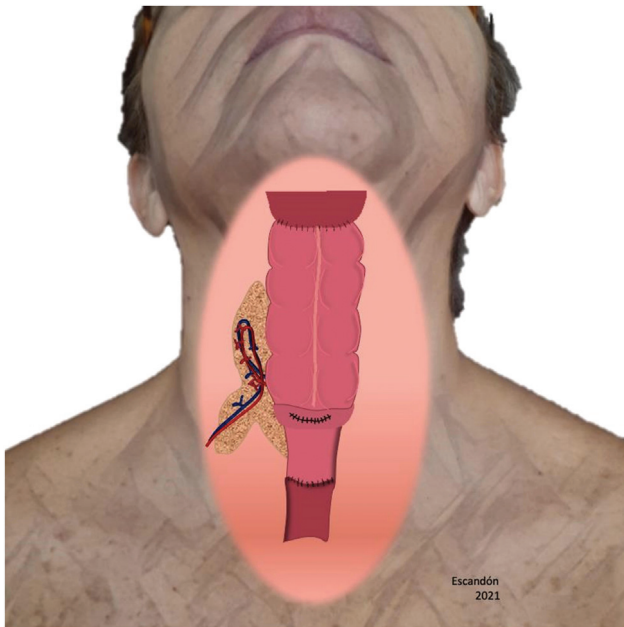


Fig. 4 Antiperistaltic inset of an ileocolon funnel flap with ileocecal valvuloplasty (indication: high pharyngeal and low esophageal defects).

ileal segment was positioned in the recipient bed, and the proximal and distal anastomoses were performed. Then, the additional seromuscular ileal segment was sutured with interrupted absorbable sutures to the anterolateral walls of the colo-esophageal anastomosis, with the mesenteric axis parallel to the colo-esophageal suture line (►Fig. 5).^{6,18}

To achieve a better ileocecal valve continence, Hsiao et al performed a wedge resection of the subserosal tissue of the ileocecal valve; and the resected site was closed using absorbable sutures to tighten the sphincter.¹⁹ Rampazzo

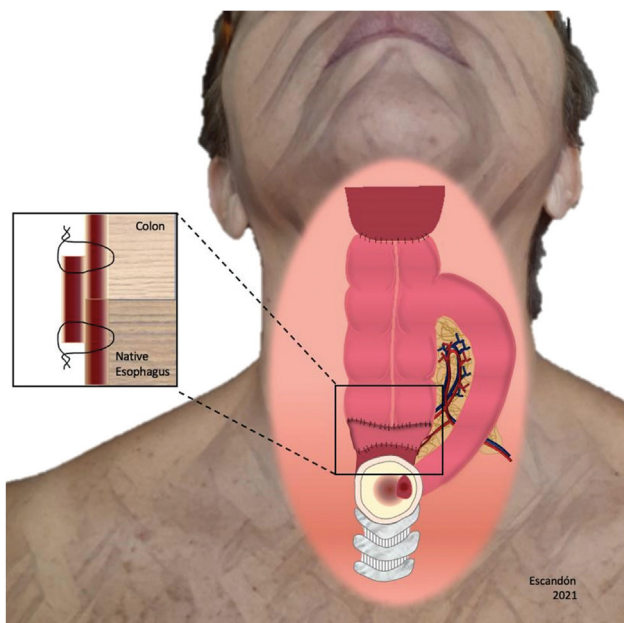


Fig. 5 Chimaeric seromuscular flap (indication: prevent anastomotic leakage).

et al redefined the method that is used nowadays by the microsurgical team at our institution. This method included an external plication in which subserosal sutures are placed between the ileum and cecum to decrease the ileocecal angle to 30 degrees. Additionally, an internal plication of the ileocecal valve with interrupted 3-0 absorbable sutures is performed to achieve a 0.5-cm valve aperture.²⁰

Results

Twenty-one studies met the inclusion criteria and were included in the final synthesis (►Fig. 6).^{6,12,13,15-36} The male-to-female ratio was 8:1. Overall, the mean age was 54.65 years (range: 20-80 years) while the average follow-up was 24.72 months (range: 1-72 months). The most common indications for reconstruction with an ICFF were hypopharyngeal and laryngeal carcinoma followed by thyroid carcinoma, esophageal cancer, failed reconstruction with previous fasciocutaneous flaps, radiotherapy induced necrosis, pharyngolaryngeal stricture, and pharyngocutaneous fistulas (►Table 2).

Six studies reported prior radiotherapy or chemotherapy (►Table 3).^{12,15,16,26,28,34} Oncologic staging was reported in 10 studies. Most of these studies included patients with advanced stage disease, stages III and IV. Only one article reported patients with neoplastic disease stage II.¹⁹ The most common ablative procedure was either a pharyngolaryngectomy or laryngectomy with or without unilateral or bilateral neck dissection. In some cases, extensive resections were required in which the soft palate and tonsillar fossae were resected, a total or subtotal thyroidectomy was required, and/or a glossectomy was performed. Fifteen studies reported the use of postoperative chemotherapy or radiotherapy (►Table 3).^{12,13,15,17-20,24-29,33,35-39}

Primary and secondary reconstructions were performed in 24.6 ($n = 134$) and in 19.1% ($n = 104$) of the cases, respectively (►Table 4). The surgical time ranged from 8 to 14.5 hours reported in four studies.^{13,15,34,37} An isolated case report stated an intraoperative time of 6 hours in which the ICFF was laparoscopically harvested.³¹ The mean hospital stay was 23.09 days (range: 12-62 days), as reported in six studies.^{17,23,26,31,35,40} A summary of the type of flaps used, the recipient vessels, the surgical time, and the mean hospital stay is exhibited in ►Table 4.

Flap Failure Rate

Overall, most series reported an excellent flap success rate (>91-100%; ►Table 4). Buck et al. reported a flap loss in a patient with squamous cell carcinoma of the esophagus requiring the microanastomosis to the internal mammary vessels.³⁹ Yang et al reported another flap failure in a patient with a previous failed reconstruction using an anterolateral thigh (ALT) flap, a gastric pull-up, and past medical history of cirrhosis.³² In another series, a complete flap loss was reported in an overweight patient with past medical history of chronic obstructive pulmonary disease, diabetes mellitus, and chronic use of alcohol and tobacco.³⁴ A 91% flap success rate was reported in the biggest series which comprised 191

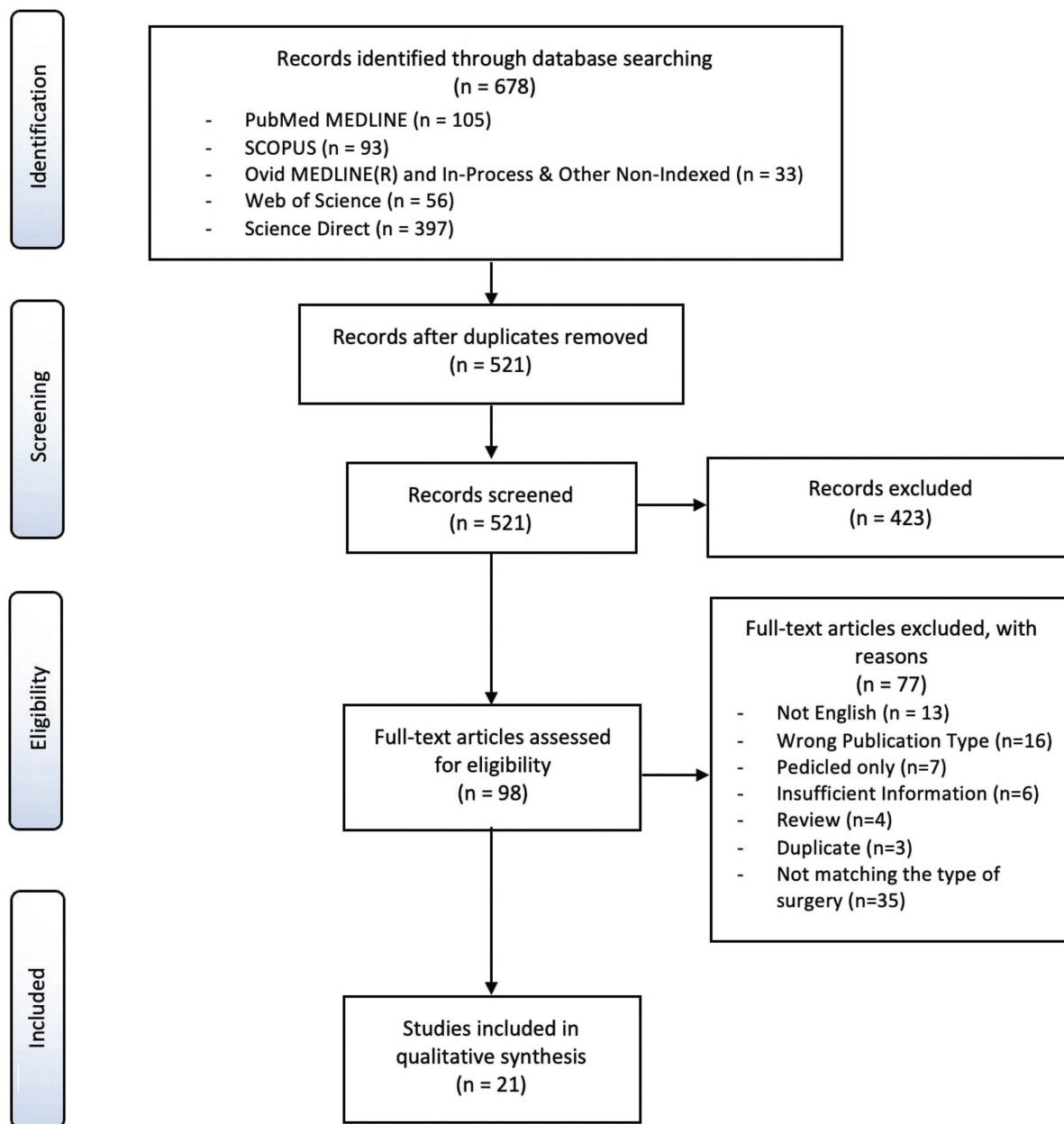


Fig. 6 Systematic search flow diagram.

flaps.⁶ The incidence of partial flap loss was 5.88%, reported in two articles.^{26,34}

Complications

An overview of all the reported postoperative complications is exhibited in **Table 5**. Following reconstruction, the revision rate of the microanastomosis ranged from 0 to 16.6%, reported in five studies.^{12,26,28,35,39} Revision rate due to bleeding or hematoma was reported in two articles and ranged from 0 to 16%.^{12,34} The incidence of postoperative leakage ranged from 0 to 13.3%, the majority occurring at the coloesophageal junction.^{6,28} Only two studies reported a single patient with pharyngocutaneous leakage in the upper anastomosis site.^{19,41} Reinterventions directed to close leak-

age were reported in eight studies.^{19,20} Leakage was closed with local skin flaps,⁶ pectoralis major flaps,^{18,28,35,41} deltopectoral flaps,^{18,26,28,35} or additional CS-ICFF.^{18,28} The incidence of stricture ranged from 0 to 10% in series with a sample size greater than 30.^{6,26,28,35} Reconstructive procedures to address stricture using additional flaps were reported in two studies.^{28,35}

Before Tsou et al published the results in which optimal functional outcomes were attained using an ileal segment of 7 to 15 cm, the percentage of patients requiring additional procedures to treat redundancy of the ileal conduit ranged from 0 to 35.7%. Afterward, the rate decreased to 7.3%.^{6,26-28} Delayed ileotracheal anastomosis was reported in two studies.^{6,26} Also, the size of the tracheal stoma was

Table 2 Overview, general characteristics of patients, and quality assessment of included studies

| Author, year | OCEBM | NOS | Observation period (years) | Patients (n) | M | F | Age (y) | Flaps (n) | Indication | Follow-up (mo) |
|--------------------------------------|-------|----------------|----------------------------|--------------|----|---|----------------------|-----------|----------------------------------------------------------------------------------------------------------------------|---------------------|
| Kawahara et al (1992) ¹² | 4 | 5 ^a | 1987–1992 | 6 | 4 | 2 | 63.5 (range: 50–78) | 6 | Neoplastic disease | 11.66 (range: 6–23) |
| Sartoris et al (1999) ¹³ | 4 | 5 ^a | 1998–1999 | 6 | 3 | 3 | Range: 45–65 | 6 | Squamous cell carcinoma | Range: 8–12 |
| Succo et al (2000) ¹⁵ | 4 | 5 ^a | 1998–2000 | 8 | 5 | 3 | 58.25 (range: 45–68) | 8 | Squamous cell carcinoma | 13.5 (range: 9–24) |
| Kobayashi et al (2003) ¹⁶ | 4 | 5 ^a | 1998–2000 | 7 | 5 | 2 | 58.85 (range: 20–71) | 7 | Thyroid carcinoma Tongue carcinoma Laryngeal carcinoma | 29.8 (range: 23–48) |
| Mardini et al (2004) ⁴¹ | 4 | 5 ^a | 2001–2002 | 9 | 9 | 0 | 58 (range: 46–73) | 9 | Hypopharyngeal cancer Corrosive injury | 7 |
| Leu et al (2005) ³⁶ | 4 | 5 ^a | 2002–2003 | 12 | 12 | 0 | 48.2 (range: 33–61) | 12 | Hypopharyngeal squamous cell carcinoma (n = 11) Laryngeal squamous cell carcinomas (n = 1) | 16.5 (range: 12–20) |
| Chen et al (2006) ²¹ | 4 | 5 | 2002–2004 | 12 | 11 | 1 | 62.8 ± 11.4 | 6 | Laryngeal cancer (n = 4) Hypopharyngeal cancer (n = 7) Vocal tumor (n = 1) | 7 (range: 1.5–24) |
| Rampazzo et al (2008) ²³ | 4 | 5 | 2003–2007 | 34 | 32 | 2 | NR | 34 | Hypopharyngeal cancer (n = 24) Laryngeal cancer (n = 9) Thyroid cancer (n = 1) | 19 (range: 4–56) |
| Leu et al (2008) ²⁴ | 4 | 4 ^a | 2002–2004 | 15 | 15 | 0 | 49.8 (range: 33–61) | 15 | Hypopharyngeal squamous cell carcinoma (n = 14) Laryngeal squamous cell carcinomas (n = 1) | 24 |
| Hsiao et al (2009) ¹⁹ | 4 | 5 ^a | 2001–2005 | 16 | 16 | 0 | 51.9 (range: 33–69) | 16 | Squamous cell carcinoma: Hypopharyngeal cancer (n = 13) Epiglottic cancer (n = 1) Pharyngeal cancer (n = 2) | 15.6 (range: 4–36) |
| Tai et al (2009) ²⁵ | 4 | 4 | 2003–2006 | 13 | 13 | 0 | 54.3 (range: 44–63) | 13 | Hypopharyngeal squamous cell carcinoma (n = 13) | 33 |
| Karri et al (2011) ²⁶ | 4 | 7 | 2004–2009 | 17 | 15 | 2 | 49 (range: 35–69) | 17 | Hypopharyngeal cancer (n = 12) Laryngeal cancer (n = 3) Thyroid (n = 2) | 22 (range: 6–72) |
| Rampazzo et al (2011) ²⁰ | 4 | 5 | 2004–2008 | 35 | 33 | 2 | 57 (range: 38–80) | 35 | Hypopharyngeal cancer (n = 25) Laryngeal cancer (n = 9) Thyroid cancer (n = 1) | 34.2 |
| Perrone et al (2012) ¹⁸ | 4 | 7 | 2004–2009 | 29 | 26 | 3 | 55.5 (range: 41–79) | 29 | Hypopharyngeal cancer (n = 21) Thyroid cancer (n = 2) Esophageal cancer (n = 1) Laryngeal cancer (n = 5) | 51 |

(Continued)

Table 2 (Continued)

| Author, year | OCEBM | NOS | Observation period (years) | Patients (n) | M | F | Age (y) | Flaps (n) | Indication | Follow-up (mo) |
|-------------------------------------|-------|----------------|----------------------------|--------------|----|----|----------------------|-----------|-------------------------------------------------------------------------------------------------------------------------------------------------------|----------------------|
| Gharb et al (2013) ²⁷ | 4 | 6 | 1995–2009 | 14 | 13 | 1 | 59.14 (range: 45–73) | 14 | Hypopharyngeal cancer (n = 7) Laryngeal cancer (n = 7) | 28.07 (range: 12–40) |
| Tsou et al (2016) ²⁸ | 4 | 6 | 2011–2012 | 30 | NR | NR | NR | 30 | Hypopharyngeal cancer (n = 21) Laryngeal cancer (n = 9) | >3 |
| Chen et al (2018) ⁶ | 4 | 5 | 1988–2017 | 205 | NR | NR | NR | 191 | Pharynx or larynx cancer (n = 187) Thyroid cancer invasion (n = 2) Corrosive injury with destruction of pharynx, larynx, and epiglottis (n = 2) | NR |
| Yang et al (2019) ³² | 4 | 5 ^a | 2013–2015 | 14 | 14 | 0 | 51 (range: 39–72) | 14 | Cervical esophagus defects following oncological resection + failed free ALT flap reconstruction (n = 14) | 13.8 (range: 6–27) |
| Lo Torto et al (2020) ³⁵ | 4 | 6 | 2010–2015 | 37 | 35 | 2 | 54.1 (range: 38–78) | 37 | Hypopharyngeal (n = 32) Laryngeal cancer (n = 3) Post-radiotherapy damage (n = 2): • Thyroid cancer • Nasopharynx cancer | 20 (range: 12–48) |
| Manrique et al (2020) ³⁴ | 4 | 6 | 2010–2015 | 34 | 29 | 5 | 54.4 (range: 44–60) | 34 | Squamous cell carcinoma (n = 30) Lymphoepithelial (n = 1) CA canaliculatum (n = 1) Adeno-squamous (n = 1) Spindle cell carcinoma (n = 1) | NR |
| Yegin et al (2020) ³³ | 4 | 5 ^a | 1983–2017 | 12 | 5 | 7 | 52 (range: 28–78) | 12 | Pharyngolaryngeal stricture (n = 5) Hypopharyngeal cancer (n = 7) | 28.1 (range: 19–48) |

Abbreviations: BMI, body mass index; F, female; NOS, Newcastle–Ottawa Scale; M, male; NR, not reported; OCEBM, Oxford Centre for Evidence-Based Medicine; Levels of Evidence.
^aRisk of bias evaluated with the methodological quality assessment tool (MQAT) proposed by Murad et al.¹¹ for case reports and case series.

Table 3 Oncologic treatment reported in included studies

| Study (year) | Flaps (n) | Cancer surgery | Stage ^a | Prior chemo/radiotherapy | Adjuvant RT | Adjuvant ChT |
|--------------------------------------|-----------|---------------------------------------------------------------------------------------------------------------------------------------------------------------------------------------------------------------------------|-----------------------------------------|----------------------------------------------|-------------|--------------|
| Kawahara et al (1992) ¹² | 6 | PLE + B/L ND (n = 2) PLE + B/L ND + mediastinal LND (n = 2) | NR | Chemotherapy (n = 3) Radiotherapy (n = 1) | (n = 2) | (n = 3) |
| Sartoris et al (1999) ¹³ | 6 | PLE + B/L ND ± HemiTh/subtotal Th (n = 5) PLE + soft palate and tonsillar fossae resection + B/L ND ± HemTh/subtotal Th (n = 1) | Advanced stage | NR | (n = 3) | NR |
| Succo et al (2000) ¹⁵ | 8 | PLE + B/L ND (n = 4) PL + B/L ND (n = 1) anterior PL + B/L ND (n = 3) | IV | Chemotherapy (n = 5) Radiotherapy (n = 5) | (n = 3) | (n = 1) |
| Kobayashi et al (2003) ¹⁶ | 7 | L + B/L ND + Th (n = 3) L + B/L ND (n = 3) G + L + B/L ND (n = 1) | NR | Chemotherapy (n = 3) Radiotherapy (n = 4) | NR | NR |
| Mardini et al (2004) ⁴¹ | 9 | PLE | NR | NR | NR | NR |
| Leu et al (2005) ³⁶ | 12 | PL (n = 4) PL + B/L ND (n = 3) PL + U/L ND (n = 5) | III (n = 3) IV (n = 9) | NR | (n = 11) | (n = 11) |
| Chen et al (2006) ²¹ | 6 | L (n = 12) | NR | NR | NR | NR |
| Rampazzo et al (2008) ²³ | 34 | L (n = 11) PL (n = 23) | NR | NR | NR | (n = 7) |
| Leu et al (2008) ²⁴ | 15 | PLE (n = 15) | III (n = 5) IV (n = 10) | NR | (n = 15) | (n = 15) |
| Hsiao et al (2009) ¹⁹ | 16 | PL (n = 5) PL + radical ND (n = 11) | II (n = 4) III (n = 7) IV (n = 5) | NR | (n = 16) | (n = 16) |
| Tai et al (2009) ²⁵ | 13 | NR | III (n = 3) IV (n = 9) | NR | (n = 13) | (n = 13) |
| Karri et al (2011) ²⁶ | 17 | Radiation (n = 2) PL + B/L ND (n = 2) PL + B/L ND + subtotal Th (n = 2) PL + B/L ND + HemiTh (n = 3) PL + U/L ND (n = 2) PL + U/L ND + HemiTh (n = 3) Partial L (n = 2) Th + larynx necrosis (n = 1) | III and IV | (n = 7) | (n = 8) | (n = 4) |
| Rampazzo et al (2011) ²⁰ | 35 | L PL | NR | NR | (n = 15) | (n = 10) |
| Perrone et al (2012) ¹⁸ | 29 | NR | NR | NR | (n = 24) | NR |
| Gharb et al (2013) ²⁷ | 14 | PL | NR | NR | (n = 2) | NR |
| Tsou et al (2016) ²⁸ | 30 | PL (n = 30) | NR | (n = 11) | (n = 19) | NR |
| Chen et al (2018) ⁶ | 191 | PL | NR | NR | NR | NR |
| Yang et al (2019) ³² | 14 | PL (n = 14) | NR | NR | NR | NR |
| Lo Torto et al (2020) ³⁵ | 37 | PL (n = 37) | NR | NR | (n = 22) | (n = 21) |
| Manrique et al (2020) ³⁴ | 34 | PL | III (n = 20) IV (n = 14) | (n = 10) | NR | NR |
| Yegin et al (2020) ³³ | 12 | NR | NR | NR | (n = 11) | NR |

Abbreviations: B/L, bilateral; ChT, chemotherapy; G, glossectomy; HemiTh/HemTh, hemithyroidectomy; L, laryngectomy; ND, neck dissection; NR, not reported; PL, pharyngolaryngectomy; PLE, pharyngolaryngoesophagectomy; RT, radiotherapy; TELND, tracheoesophageal lymph node dissection; Th, thyroidectomy; U/L, unilateral.

^aCancer staging using the tumor, node, metastasis (TNM) system for classification.

revised in the studies reported by Karri et al and Chen et al to improve the clearance of sputum and speech, particularly following radiation.^{6,26} In series with a sample size of more than 30 patients, revision procedures to strengthen the ileocecal valve competence ranged from 0 to 8.5%.^{6,19,20,26–28,35} In fact, reinset of the ileum was per-

formed to achieve easier entry of air in 11 out of 191 patients in the series described with the greatest number of patients.⁶

The most common complication reported in several series was self-limited diarrhea with a duration of 4 days to 4 weeks.^{6,23,26,35} Eventration was reported in two studies

Table 4 Overview of the type of flaps, surgical technique, and flap success rate of included studies

| Study (year) | Flaps (n) | Primary or secondary reconstruction | Type of flap | Supplementary surgical considerations | Recipient vessels | Surgical time (h) | Mean hospital stay (d) | Flap success (%) |
|-------------------------------------|-----------|----------------------------------------|------------------------------------------------------------------|---------------------------------------------------------------------------------------------------------------------------------------------------------------|----------------------------------------------------------------------------------------------------------------------------|-------------------|------------------------|------------------|
| Kawahara et al (1992) ¹² | 6 | Primary (n = 6) | Standard ISO | Cecal plication using the anterior and posterior wall of the cecum. Ileum is anastomosed to the trachea (E-E, 4-0 Vicryl) (n = 2) or ileostoma + tube (n = 4) | IJV (E-S, 9-0) TCA (E-E, 9-0) | NR | NR | 100 |
| Santonis et al (1999) ¹³ | 6 | Primary (n = 6) | Standard ISO (n = 5) Standard ANTI (n = 1) | Lembert's stitches along the ileal tract | ECA or branch of ECA (9-0) Thyrolinguofacial Venous Trunk/IJV (9-0) | 10-12 | NR | 100 |
| Succo et al (2000) ¹⁵ | 8 | Primary (n = 4) | Standard ISO (n = 5) DeTUBE (n = 3) | Ileotracheal anastomosis (E-E) Lembert's stitches along the ileal tract | ECA Thyrolinguofacial Venous Trunk/IJV | 9-12 | NR | 100 |
| Kobayashi et al (2003) | 7 | Primary (n = 6) Secondary (n = 1) | Patch (n = 7) | Patch to the hypopharyngeal defect (same size) Ileotracheal anastomosis (E-E, n = 5; S-S, n = 1) Stitches along the ileal serosa | IJV (E-S) SCA or STA (E-E) | NR | NR | 100 |
| Mardini et al (2004) ⁴¹ | 9 | NR | Standard | Biologic dressing (Biobrane, Dow Hickam Pharmaceuticals, Inc., Sugar Land, Texas) | IJV (E-E) TCA (E-E) | NR | NR | 100 |
| Leu et al (2005) ³⁶ | 12 | Primary (n = 12) | Standard | Ileotracheal anastomosis (E-E) | NR | NR | NR | 100 |
| Chen et al (2006) ²¹ | 6 | Secondary (n = 6) | Standard or Patch | NR | NR | NR | NR | 100 |
| Rampazzo et al (2008) ²³ | 34 | Primary (n = 9) Secondary (n = 25) | Standard ISO/ANTI (n = 23) Patch (n = 11) | NR | NR | NR | 42 ± 20 | 100 |
| Leu et al (2008) ²⁴ | 15 | Primary (n = 15) | Standard | Ileotracheal anastomosis (E-E) | NR | NR | NR | 100 |
| Hsiao et al (2009) ¹⁹ | 16 | Primary (n = 16) | Standard ISO | Ileotracheal anastomosis (E-E) | STA STV/EJV | NR | NR | 100 |
| Tai et al (2009) ²⁵ | 13 | NR | NR | NR | NR | NR | NR | 100 |
| Karri et al (2011) ²⁶ | 17 | Primary (n = 12) Secondary (n = 5) | Standard ISO (n = 13) Standard ANTI (n = 3) DeTUBE (n = 1) | Ileotracheal anastomosis (E-E) (n = 17) Ileocaecal valve plicated to narrow the opening to 5 mm | TCA (n = 11), STA (n = 1), APA (n = 2), TAA (n = 1)/ thyrocervical trunk (n = 2) EJV (n = 15)/TAV (n = 1) / IJV (n = 1) | NR | 23.8(Range 21-37) | 100 |
| Rampazzo et al (2011) ²⁰ | 35 | Primary (n = 10) Secondary (n = 25) | Standard ISO (n = 24) Patch (n = 11) | Ileotracheal anastomosis (E-E) | NR | NR | NR | 100 |
| Perrone et al (2012) ¹⁸ | 29 | Primary (n = 15) | Ch-SM (n = 14) Standard (n = 15) | A seromuscular flap (A 3-cm segment of the ileal loop) was sutured to the antero-lateral walls | NR | NR | NR | 100% |

Table 4 (Continued)

| Study (year) | Flaps (n) | Primary or secondary reconstruction | Type of flap | Supplementary surgical considerations | Recipient vessels | Surgical time (h) | Mean hospital stay (d) | Flap success (%) |
|-------------------------------------|-----------|-------------------------------------|-----------------------------------|------------------------------------------------------------------------------------------------------------------------------------------|-----------------------------|----------------------|------------------------|------------------|
| Gharb et al (2013) ²⁷ | 14 | Primary (n=2) Secondary (n=12) | Standard ISO (n=7) Patch (n=7) | of the colooesophageal anastomosis. NR | NR | NR | NR | 100 |
| Tsou et al (2016) ²⁸ | 30 | NR | Standard ISO (n=31) | Ileum segment: <7 cm (n=6) Ileum segment: 7–15 cm (n=13) Ileum segment: >15 cm (n=11) | TCA EJV | NR | NR | 100 |
| Chen et al (2018) ⁶ | 191 | NR | Standard ISO Ch-SM | NR | NR | NR | NR | 97 |
| Yang et al (2019) ³² | 14 | Secondary (n=14) | Standard | NR | TCA EJV or cephalic vein | NR | NR | 92.85 |
| Lo Torto et al (2020) ³⁵ | 37 | Primary (n=21) Secondary (n=16) | Standard ANTI | NR | NR | NR | 24.8 ± 12 | 100 |
| Mamrique et al (2020) ³⁴ | 34 | NR | Standard | NR | NR | 11.5 (range: 8–14.5) | NR | 97 |
| Yegin et al (2020) ³³ | 12 | Revision (n=12) | NR | Revision of the Free ileocolon flap with pedicle transection (n=11) Revision of the free ileocolon free flap + vein graft, 5 cm (n=1) | NR | NR | NR | 100 |

Abbreviations: ANTI, anti-peristaltic ileocolon free flap; APA, ascending pharyngeal artery; Ch-SM, chimeric seromuscular flap; DeTUBE, detubularized ileocolon free flap; ECA, external carotid artery; E-E, end to end; EJV, external jugular vein; E-S, end to side; IJV, internal jugular vein; ISO, iso-peristaltic ileocolon free flap; NR, not reported; rTCA, retrograde transverse cervical artery; TAA, thoracoacromial artery; TAV, thoracoacromial vein; SCA, superficial cervical artery; SMA, superior mesenteric artery; STA, superior thyroid artery; STV, superior thyroid vein.

Table 5 Recipient and donor site complications, and additional surgical procedures reported in included studies

| Study (year) | Flaps (n) | Complications recipient site | Complications donor site | Additional surgeries |
|--------------------------------------|-----------|---------------------------------------------------------------------------------------------------------------------------------------------------------------------------------------------------------------------------------------------------------------------------------------------|----------------------------------------------------------------------------------------------------------------------------------------------------------------------------------------------------------------------------------------------------------------------------------------------------------------|----------------------------------------------------------------------------------------------------------------------------------------------------------------------------------------------------------------------------------------------------------------------------------------------------------------------------------------------------------|
| Kawahara et al (1992) ¹² | 6 | Death (hepatic failure, preexisting cirrhosis; <i>n</i> = 1) Venous congestion (<i>n</i> = 1) Bleeding (<i>n</i> = 1) | No abdominal complications | Revision of venous congestion (<i>n</i> = 1) Revision due to bleeding (<i>n</i> = 1) |
| Sartoris et al (1999) ¹³ | 6 | Erosive gastric hemorrhage (<i>n</i> = 1) Skin flap necrosis (<i>n</i> = 1) | Eventration POD 17 (<i>n</i> = 1) (violent coughing) | None |
| Succo et al (2000) ¹⁵ | 8 | Erosive gastric hemorrhage (<i>n</i> = 1) Skin flap necrosis (<i>n</i> = 1) Salivary fistula (<i>n</i> = 1) Hemorrhage (<i>n</i> = 1) | Eventration POD 17 (<i>n</i> = 1) (violent coughing) | NR |
| Kobayashi et al (2003) ¹⁶ | 7 | Death (rupture of carotid artery) (<i>n</i> = 1) | NR | NR |
| Mardini et al (2004) ⁴¹ | 9 | Pharyngocutaneous fistula (<i>n</i> = 1) • Upper colon anastomosis | Superficial abdominal wound infection (<i>n</i> = 1) Abdominal wall dehiscence (<i>n</i> = 1) | Pectoralis major muscle flap for fistula (<i>n</i> = 1) Abdominal wall closure (<i>n</i> = 1) |
| Leu et al (2005) ³⁶ | 12 | Suicide (<i>n</i> = 1) | No abdominal complications | NR |
| Chen et al (2006) ²¹ | 6 | NR | NR | NR |
| Rampazzo et al (2008) ²³ | 34 | Hypocalcemia (<i>n</i> = 1) | Pseudomembranous colitis (<i>n</i> = 1) Gastroduodenal ulcers (<i>n</i> = 1) Erosive gastritis with minimal bleeding (<i>n</i> = 4) Skin wound dehiscence (<i>n</i> = 1) Lower abdominal hernia (<i>n</i> = 1) Intestinal anastomosis leakage (<i>n</i> = 1) Diarrhea (<i>n</i> = 19) | None |
| Leu et al (2008) ²⁴ | 15 | NR | NR | NR |
| Hsiao et al (2009) ¹⁹ | 16 | Late flap necrosis (pedicle damaged in another operation) (<i>n</i> = 1) Pharyngocutaneous fistula (<i>n</i> = 1) Narrowing (<i>n</i> = 3) Ileocecal valve dysfunction (<i>n</i> = 1) Tracheal leak (<i>n</i> = 2) Avascular necrosis of cartilage ring (<i>n</i> = 1) | No abdominal complications | Pharyngocutaneous fistula closure (<i>n</i> = 1) Ileocecal valve closure (<i>n</i> = 1) |
| Tai et al (2009) ²⁵ | 13 | NR | NR | NR |
| Karri et al (2011) ²⁶ | 17 | Partial flap necrosis (<i>n</i> = 1) Pedicle thrombosis (<i>n</i> = 2) Neck-wound dehiscence (<i>n</i> = 1) Stricture at colo-esophageal anastomosis (<i>n</i> = 1) Unable ileotracheal anastomosis for voice (<i>n</i> = 1) | Self-limited diarrhea (a few) | Release of stricture (<i>n</i> = 3) Shortening of ileal loop (<i>n</i> = 2) Tracheostomy revision (<i>n</i> = 7) Buccal Ca resection (<i>n</i> = 1) Deltapectoral flap (<i>n</i> = 2) Plication of the ileocecal valve (<i>n</i> = 1) Microsurgical revision (<i>n</i> = 2) Delayed ileotracheal anastomosis (<i>n</i> = 1) |
| Rampazzo et al (2011) ²⁰ | 35 | Incompetence of the ileocecal valve (<i>n</i> = 5) Tracheoesophageal fistula (<i>n</i> = 1) Pneumonia (<i>n</i> = 4) | NR | Closure of the pathologic tracheoesophageal fistula (<i>n</i> = 1) Internal plication of the ileocecal valve (<i>n</i> = 3) |
| Perrone et al (2012) ¹⁸ | 29 | Anastomotic leakage (<i>n</i> = 5) • Isoperistaltic (<i>n</i> = 4) • Chimaeric seromuscular flap with free ileocolon flap (<i>n</i> = 1) Recurrent cough (<i>n</i> = 5) | NR | DP flap or PMMC flap for fistula Normal flap (<i>n</i> = 3) Additional seromuscular flap (<i>n</i> = 1) in a previous standard flap (<i>n</i> = 1) |
| Gharb et al (2013) ²⁷ | 14 | Incontinence of the ileocecal valve (<i>n</i> = 5) Redundancy of the ileal conduit (<i>n</i> = 5) | NR | Correct incontinence of ileocecal valve (<i>n</i> = 5) |

Table 5 (Continued)

| Study (year) | Flaps (n) | Complications recipient site | Complications donor site | Additional surgeries |
|-------------------------------------|-----------|---------------------------------------------------------------------------------------------------------------------------------------------------------------------------------------------------------------------------------------------------------------------------------------------|----------------------------------------------------------------------------------------------------|-------------------------------------------------------------------------------------------------------------------------------------------------------------------------------------------------------------------------------------------------------------------------------------------------------------|
| | | Stricture formation at pharyngocolic junction (n = 4) | | Redundancy of the ileal conduit (n = 5) Enterolysis (n = 4) |
| Tsou et al (2016) ²⁸ | 30 | Vascular compromise (n = 2) Incompetence of the ileocecal valve (n = 5) Leakage and fistula (n = 4) Stricture (n = 3) | NR | Vascular compromise (n = 2) Transcolic plication of the ileocecal valve (n = 5) Deltopectoral flap (n = 2) PMMC flap (n = 1) Seromuscular flap (n = 1) Reconstruction for stricture (n = 3) |
| Chen et al (2018) ⁶ | 191 | Death pneumonia POD 13 (n = 1) Leak at the junction of colon (n = 6) Voice tube was too long (n = 14) Stricture (n = 2) Ileocecal valve incompetence (n = 8) Small ileotracheal junction (n = 11) Tracheal stoma was narrowed (n = 14) Coloesophageal stenosis (n = 5) | Intestinal adhesion (n = 3) Abdominal wound dehiscence (n = 1) Self-limited diarrhea (n = 5) | Local skin flaps (n = 6) for leaks Enterolysis and relief of obstruction (n = 2) Abdominal wound dehiscence repair (n = 1) Ileum segment shortening (n = 14) Ileocecal valve narrowing (n = 8) Ileum was reinserted to increase the orifice (n = 11) Tracheal stoma was narrowed (n = 14) |
| Yang et al (2019) ³² | 14 | Flap failure (n = 1) Sepsis (n = 1) Skin defect (n = 1) Unable ileotracheal anastomosis for voice (n = 1) | Ventral hernia (n = 1) | PM flap: flap failure (n = 1) STSG: skin defect (n = 1) |
| Lo Torto et al (2020) ³⁵ | 37 | Surgical revision due to arterial thrombosis (n = 1) Aspiration (n = 3) Death POD 13 (n = 1; aspiration) Neoesophagocutaneous fistula (n = 2) stricture at the neoesophagus (n = 1) | Ileus (n = 1) Self-limited diarrhea (n = 7) Secondary abdominal procedures (n = 0) | Microsurgical revision (n = 1) Narrowing for the ileocecal valve for aspiration (n = 2) PM flap for fistula (n = 1) DP flap for fistula (n = 1) PM for stricture (n = 1) |
| Manrique et al (2020) ³⁴ | 34 | Hypotension >requiring vasopressors (n = 3) Nonplanned/attempt-self extubation (n = 2) Postoperative bleeding/hematoma (n = 2) Pneumonia (n = 1) Partial flap loss (n = 2) Complete flap loss (n = 1) | NR | Partial flap loss revision (n = 2) Complete flap loss (n = 1) Hematoma evacuation (n = 1) |
| Yegin et al (2020) ³³ | 12 | Immediate paleness and loss of peristalsis in the two cases of arterial pedicle division (n = 2) | NR/NA | Anterior wall reconstruction (n = 1) |

Abbreviations: DP, deltopectoral flap; NA, not applicable; NR, not reported; PM, pectoralis major flap; PMMC, pectoralis major myocutaneous flap; POD, postoperative day; SSTG, split-thickness skin graft.

only in one patient, secondary to violent coughing.^{13,15} Other donor site complications included surgical site infection and symptoms related to intestinal ileus due to surgery-induced adhesions.^{6,23,26,35,41}

Rampazzo et al specifically investigated the donor-site morbidity in 34 patients undergoing reconstruction with ICFF. The most common complications experienced were self-limited diarrhea (n = 19), erosive gastritis with minimal bleeding (n = 4), pseudomembranous colitis (n = 1), gastroduodenal ulcers (n = 1), skin wound dehiscence (n = 1), lower abdominal hernia (n = 1), and intestinal anastomosis leakage (n = 1). Postoperative chemotherapy was significantly associated with diarrhea ($p < 0.01$).²³

Yegin et al reported a series of 12 ICFFs that required revision procedure to shorten the flap for functional improvement, performed at an average of 3 months postoperatively. In these cases, nine venous and two arterial pedicle divisions were necessary. No venous pedicle divisions re-

quired reanastomosis. However, all arterial pedicle division cases required immediate restoration due to instantaneous ischemic intestinal changes.³³

Quality of Life and Functional Outcomes

An overview of the outcomes related to quality of life (QoL), speech, and deglutition is exhibited in ► **Table 6**. Using the QLQ-C30 in a group of 17 patients, a score of 55.9 was reported for global QoL/general health, and the average score for the five functional subscales ranged from 59.8 to 83.3 which suggested an overall average-to-good postoperative functionality.^{6,26} Also, when compared with the pneumatic artificial larynx (PAL), the ICFF yielded better outcomes regarding the severity of depression ($p = 0.72$) and anxiety ($p = 0.311$), and better intelligibility ($p = 0.004$), loudness ($p = 0.065$), and fluency of speech ($p = 0.004$).²¹

In recent series using a 7-point Likert's scale to evaluate deglutition after reconstruction in which 1 represented

Table 6 Overview of functional outcomes following reconstruction of the aerodigestive tract with an ileocolon free flap

| Study (year) | Flaps (n) | QoL | Swallowing | Speech |
|--------------------------------------|-----------|-----------------------------------------------------------------------------------------------------------------------------------------------------------------------------------------------------------------------------------------------------------------------------------------------------------------------------------------------------------------------------------------------------------------|---------------------------------------------------------------------------------------------------------------------------------------------------------------------------------------------------------------------------------------|---------------------------------------------------------------------------------------------------------------------------------------------------------------------------------------|
| Kawahara et al (1992) ¹² | 6 | NR | Swallow without aspiration (n = 5) Mild regurgitation (n = 2) Regular diet (n = 4) | Fundamental frequency: 83 ± 23.2 to 138 ± 55.8 Hz Mean duration: 2.7 ± 1.3 seg 12.4 ± 3.6 seg Phonation pressure: 20–30 mm Hg Vibration of the Bauhin's valve (endoscopy) |
| Sartoris et al (1999) ¹³ | 6 | NR | Swallowing without aspiration (n = 6) (100%) Solid and semisolid diet (n = 6) (100%) Slight, transitory dysphagia for bulky food (n = 2) | Voice characteristics were not altered after radiotherapy Fairly good level of intelligibility |
| Succo et al (2000) ¹⁵ | 8 | NR | Deterioration of swallowing after RT (n = 2) Swallow video fluoroscopy using fluid, semisolid, and solid foods. | Fairly good level of intelligibility (n = 8) |
| Kobayashi et al (2003) ¹⁶ | 7 | NR | Swallow without aspiration No regurgitation or aspiration | Speak naturally by practicing themselves Excellent intelligibility >8/10 points (n = 6) |
| Mardini et al (2004) ⁴¹ | 9 | NR | Solid and semisolid diet (n = 9) | NR |
| Leu et al (2005) ³⁶ | 12 | NR | Swallow meals without aspiration (n = 12): mild regurgitation (n = 1), solid diet (n = 6), semisolid diet (n = 5), Only a liquid diet (n = 1) | Evaluation 6 months after surgery: speech efficacy 55% (range 10–80%) |
| Chen et al (2006) ²¹ | 6 | <ul style="list-style-type: none"> • HADS-anxiety: VTS, 5.50 ± 6.03; PAL, 8.83 ± 4.71 • HADS-depression: VTS, 7.67 ± 5.01; PAL, 8.67 ± 4.3 • Self-esteem: VTS, 1.65 ± 0.61; PAL: 2.70 ± 0.44 • Frequency of use: VTS, 4.0 ± 1.2; PAL, 3.5 ± 1.7 • Motivation for use: VTS, 5; PAL, 3.0 ± 1.4 • Overall satisfaction: VTS, 2.3 ± 1.6; PAL, 2.0 ± 0.9 | Swallowing function: VTS, 5.83 ± 1.17; PAL, 5.17 ± 1.72 | Intelligibility: VTS, 4.67 ± 0.82; PAL, 2.00 ± 1.55. Loudness: VTS, 5.00; PAL, 3.62 ± 1.63 Fluency: VTS, 5.83 ± 1.17; PAL, 2.33 ± 1.03 |
| Rampazzo et al (2008) ²³ | 34 | NR | Satisfactory swallowing (n = 32) | NR |
| Leu et al (2008) ²⁴ | 15 | NR | <ul style="list-style-type: none"> • 6 months postoperatively (n = 15): solid diet (n = 7), semisolid (n = 6), liquid diet (n = 2) • 18 months postoperatively (n = 8): solid diet (n = 6), semisolid (n = 2) | NR |

Table 6 (Continued)

| Study (year) | Flaps (n) | QoL | Swallowing | Speech |
|-------------------------------------|-----------|--------------------------------------------------------------------------------------------------------------------------------|---------------------------------------------------------------------------------------------------------------------------------------------------------------------------------------------------------------------------------------------------------------------------------------------------------------------------------------------------------------------------------------------------------------------------------------------------------------------------|---------------------------------------------------------------------------------------------------------------------------------------------------------------------------------------------------------------------------------------------------------------|
| Hsiao et al (2009) ¹⁹ | 16 | NR | <ul style="list-style-type: none"> 24-months postoperatively (n = 8): solid diet (n = 5), semisolid (n = 2), liquid diet (n = 1) Feeding pattern 3 month after CCRT: liquid diet (n = 5), soft diet (n = 5), full diet (n = 4), NG tube (n = 1). | Phonation efficacy 3 months after CCRT (%): 48% Phonation during counting 3 months after CCRT (fluency of counting in one breath, ranging from 0 to 10): 4.73 |
| Tai et al (2009) ²⁵ | 13 | NR | The 5 patients treated with IMRT appeared to have better restoration of phonation and swallowing ability as well as less severe acute dermatitis and mucositis than did the 8 who had treated with 2DRT | NR |
| Karri et al (2011) ²⁶ | 17 | EORTC QLQ-C30 and H&N35 (n = 17): Mean score for global QoL/ general health (55.9) Five functional subscales (Range 59.8–83.3) | Soft-diet oral feeding by 4 weeks (n = 16) Dysphagia (n = 1): > bougination > liquids or pureed food | Speech (n = 13); no speak (n = 4) Voice analysis at 16.8 (range, 1–59) months: excellent (n = 4), moderate (n = 8) MPT (n = 10), 9s (range, 3–28); F0 (n = 10): 124.6 Hz (range, 89.5–177.4); mean of dynamic range (n = 10), 62.1 dB (range 47.8–74.2) |
| Rampazzo et al (2011) ²⁰ | 35 | NR | Aspiration: (n = 6) <ul style="list-style-type: none"> External plication of the ileocecal junction (n = 1): 100% incompetence of the ileocecal valve External and internal plication of the ileocecal junction with residual aperture of 1 cm: 100% incompetence of the ileocecal valve. External and internal plication of the ileocecal junction with residual aperture of 0.5 cm (n = 30): 3.33% incompetence of the ileocecal valve | NR |
| Perrone et al (2012) ¹⁸ | 29 | NR | 7-point Likert's scale (1, severe complaints and an inability to swallow; 7, swallowing without complaints); median swallowing score, 5; 50% had only minimal complaints and had dry swallowing at the last follow-up. | 5-point Likert's scale (1, no voice; 5, very good outcome): median speech score, 4; 50% spoke long sentences with an intelligible voice and moderate loudness. |
| Tsou et al (2016) ²⁸ | 30 | NR | 7-point Likert's scale (1, severe complaints and an inability to swallow; 7, swallowing without any complaints); <7 cm: 4.3 (± 0.5) | 5-point Likert's scale (1, no voice; 5, very good outcome) Loudness (p = 0.03): <7 cm: 1.3; 7–15 cm, 3.6; >15 cm, 2.2. |

(Continued)

Table 6 (Continued)

| Study (year) | Flaps (n) | QoL | Swallowing | Speech |
|-------------------------------------|-----------|-------------------------------------------------------------------------------------------------------------------------------------------------------------------------------------------------------------------------------------------------------------------|-----------------------------------------------------------------------------------------------------------------------------------------------|------------------------------------------------------------------------------------------------------------------------------------------------------------------------------------------------------------------------------------------------------------------------------------------------------------------------------------------------------------------------------------------------------------------------------------------------------------------------------------------------------------------------------------------------------------------------------------------------------------------------------------------------------------------------------------------|
| Chen et al (2018) ⁶ | 191 | EORTC QLQ-C30 (n = 17). At 4 weeks, 16 patients (94%) achieved swallowing function, while twelve (71%) demonstrated moderate-to-excellent speech intelligibility. QLQ-C30: Global QoL/general health, (55.9); five functional subscales ranged from 59.8 to 83.3. | 7-point Likert's scale (1, severe complaints and an inability to swallow; 7, swallowing without complaints; n = 27): 5-7: 78%, ≤4: 22% | Intelligibility score (p = 0.1): <7 cm, 1.6; 7-15 cm, 3.8; >15 cm, 3.1. Fluency score (p = 0.1): <7 cm, 1.4; 7-15 cm, 3.5; >15 cm, 3.3. MPT (sec) (p = 0.10): <7 cm, 2.2; 7-15 cm, 4.7; >15 cm, 3.1 F0 (Hz) (p = 0.3): <7 cm, 160.4; 7-15 cm, 154.6; >15 cm, 113. Sound pressure level (dB) (p = 0.01): <7 cm, 22.8; 7-15 cm, 70.12; >15 cm, 38.31. 5-point Likert's scale (1, no voice; 5, very good outcome): good result (score >12), 64%; moderate result (score 9-11), 21%; unsatisfactory (<9), 6%. MPT, 11 (3-27); frequency (Hz), 105 (94-176); loudness (dB), 56 (46-75); jitter percent (%), 3.2%; shimmer percent (%), 11.4%; noise/harmony (dB), 0.3; s/z ratio, 10/12 |
| Yang et al (2019) ³² | 14 | NR | Time before restoration of swallowing: 1.35 months Swallow porridge at 6 months of follow-up (n = 14) | |
| Lo Torto et al (2020) ³⁵ | 37 | NR | 7-point Likert's scale (1, severe complaints and an inability to swallow; 7, swallowing without complaints; n = 27): 5-7 (n = 21); ≤4 (n = 6) | Voice analysis (n = 12): MPT: 10.75 seconds (range 3-27); frequency, 131 Hz (range 93.8-176.4); dynamic range, 56 dB (range 56-74.9). 5-point Likert's scale (1, no voice; 5, very good outcome): excellent results (score >12) (n = 20); moderate results (score 9-11) (n = 7) |
| Yegin et al (2020) ³³ | 12 | NR | Oral intake and swallowing rehabilitation at 1 month postoperatively (n = 12) Solid intake at 3 months postoperatively (n = 12) | NR |

Abbreviations: CCRT, concurrent chemoradiotherapy; EORT QLQ-C30, the EORTC core quality of life questionnaire; F0, frequency; H&N35, European Organization for Research and Treatment of Cancer Quality of Life Questionnaire Head and Neck Module; HADS, Hospital Anxiety and Depression Scale; IMRT, intensity-modulated radiation therapy; MPT, mean phonation time; NR, not reported; PAL, Pneumatic artificial larynx; QoL, quality of life; RT, radiotherapy; VTS, voice tube shunt; 2DRT, conventional radiotherapy.

severe complaints and inability to swallow, and 7 represented swallowing without complaints, 78% of the patients had a score between 5 and 7, while 22% had a score of 4 or less.^{6,35} Perrone et al reported a median swallowing score of 5 while 50% of patients had minimal complaints or dry swallowing at the last follow-up.¹⁸ Using the same 7-point scale, Tsou et al reported scores of 4.3 (± 0.5), 4.6 (± 0.7), and 4.3 (± 0.4) when the ileum length was of <7, 7–15, and >15 cm, respectively.²⁸

Three series reported consistent outcomes regarding the mean phonation time (MPT), frequency, and dynamic range.^{6,26,35} The average phonation time was 10.25 seconds (range: 3–28 seconds), the mean frequency was 120 Hz (range: 89.5–177.4 Hz), and the dynamic range was 59 dB (range: 47.8–74.9 dB). Tsou et al reported the same parameters comparing different ileum lengths. The maximum phonation time, frequency, and sound pressure level (dB) were higher with ileal segments of 7 to 15 cm in comparison to segments of <7 or >15 cm.²⁸ However, only sound pressure was statistically significant ($p = 0.01$).

Using a 5-point Likert's scale in which 1 represents no voice and 5 represented a very good outcome, good results (score >12) were reported in 64% of patients, moderate results (score 9–11) in 21%, and substandard results (score <9) in 6% of patients (**Supplementary Table S3**, available in the online version).⁶ Using a simplified 5-point Likert's scale, ICFFs with an ileum length between 7 and 15 cm yielded higher scores for loudness (3.6 ± 0.6), intelligibility (3.8 ± 0.3), and fluency (3.5 ± 1.2) in comparison to segments of <7 or >15 cm.²⁸ Nevertheless, only loudness was statistically significant ($p = 0.03$).²⁸ Perrone et al reported that at least 50% of patients spoke long sentences with an intelligible voice and moderate loudness.¹⁸

Discussion

Currently, several techniques exist for the reconstruction of postlaryngectomy defects. Nonetheless, due to its biological structure, the ICFF has the unique capacity to restore the continuity of the upper digestive system while offering functional tissue for voice rehabilitation and an intrinsic mechanism to avert aspiration without foreign prosthetic material.⁶ Moreover, the unconstrained peristalsis and the biologic secretions supply intestinal flaps with a natural self-cleansing machinery that prevents obstruction of the reconstructed phonation tube.^{6,20,26} In contrast to the ICFF, fasciocutaneous and jejunal free flaps require a trachea-esophageal prosthesis to generate voice which ultimately results in increased morbidity. In fact, the incidence of leakage around a speech prosthetic valve following TEP enlargement is acknowledged to be between 1 and 29% with a 3-fold increased risk of aspiration pneumonia, a 20 to 30% mortality rate, and 14% long-lasting requirements of nutritional support via percutaneous gastrostomy.^{42–44} Therefore, for young patients with better prognosis, no comorbidities, and long life expectancy, the ICFF is a fair alternative. For older patients or patients with poor prognosis, a skin flap with voice prosthesis can be considered as in initial choice.

Multiple techniques have been conveyed to strengthen the competence of the ileocecal valve following ICFF transfer. For instance, a cecal plication around the terminal ileum, the application of Lemberg's sutures along the longitudinal axis of the ileum, or a combined approach with a wedge excision and reinforcement with sutures of the terminal ileum have been described.^{15,16,19,20} Nevertheless, optimal outcomes are usually encountered with a multimodal internal and external valve plication to attain a residual aperture of 0.5 cm, yielding a minimal incompetent valve rate of 3.33%.²⁰ On the other hand, with solely external plication, or external and internal plication but a residual aperture of 1 cm, incompetence of the ileocecal valve is seen in 100% of patients.²⁰

Frequently, small and proximal fistulas have a higher spontaneous resolution rate with conservative techniques. Yet, a proper surgical management may be required with larger and distally located fistulas, especially following radiotherapy.^{18,45,46} Since first described by Kawahara et al in 1992, the use of the ICFF has been undertaken due to its versatility. However, early postoperative fistulas at the level of the distal anastomosis signified a challenging complication, ultimately contributing to postoperative morbidity, further surgical revisions, extended hospital stay, delayed adjuvant therapy, and worst functional outcomes.^{18,45} Local flaps are usually the first alternative for fistula closure due to their location and feasibility, but their use can be restricted when local radiation, infections, or bilateral neck dissections have been performed.^{18,45} In response to this phenomenon, the use of the CS-ICFF to augment the distal anastomotic site closure in contemporary series has been deemed to provide a lower distal anastomosis leakage rate (7%), in comparison to the standard ICFF (27%).^{6,18}

In contrast with several fasciocutaneous flaps which do not present significant complications after 4 to 5 hours of ischemia, the ICFF has activated intestinal enzyme in the lumen, a high concentration of bacterial flora, and a relatively high metabolic rate which causes significant microstructural changes (autolysis) notable even after 30 minutes of ischemia.^{6,27} Therefore, ischemia time is a crucial determinant not only of flap survival but also for optimal functional outcomes; as even after an ideal microvascular anastomosis, the bowel segment will not survive if the ischemia time was extensive (>1 hour).⁶ Therefore, an adequate pre- and intra-operative recipient vessel selection is paramount to reduce ischemia.

Several authors have reported that fibrosis of recipient vessels can be the utmost adverse prognostic element in head and neck reconstruction with FTT when preceding surgery or radiotherapy has been performed.^{30,47} Therefore, for a safe anastomosis, several authors have reported the transverse cervical artery (TCA) and external jugular vein as the preferred recipient vessels.^{6,48–50} The TCA is usually uninjured by former ablative surgical procedures or radiation, has an exceptional size match for pedicles of intestinal flaps, and the risk of kinking is minimal.^{6,48,50} Alternatively, recipient vessels that have been suggested when the ipsilateral TCA is unsuitable include the retrograde flow TCA, the

superficial temporal artery (STA), thoracoacromial branches, the internal mammary artery with/without an interposing vein graft, contralateral neck vessels, and even branches of previous or simultaneous flaps.^{30,39,51} Regarding the venous drainage, the external jugular vein is idyllically situated to permit inset without kinking with an outstanding size match.⁶ Nonetheless, if the recipient veins are small following radiotherapy, the cephalic vein can be selected promptly. Finally, an extended dissection proximal from the region of the oncologic procedure helps avoid potential injured areas that may not be clearly identified macroscopically.⁶

Longer ICFF may negatively impact voice production as they can be bulky, leading to compression and augmented airflow resistance. Conversely, shorter flaps may decrease the external tension to the ileocecal valve which causes air to leak and aphonia, as the valve is not able to close in a natural position.^{28,52} Therefore, loudness, MPT, and sound pressure levels are best when ileum segments measure from 7 to 15 cm.^{28,52} With these modifications, the ICFF has comparable functional outcomes with other flaps. For instance, the MPT for the radial forearm free flap and the anterolateral free flap has been reported to be 9.3 (± 3.6) and 9.9 (± 3.9) seconds in other studies, respectively, in comparison to 10.25 seconds of the ICFF.⁵³ Additionally, an overall dynamic range of 59 dB was obtained with the ICFF which was equivalent to primary closure (56.36 ± 4.76 dB), the radial forearm free flap (54.55 ± 3.83 dB), and the jejunal free flap (56.09 ± 5.96 dB) when used for the reconstruction of the aerodigestive tract.

Regarding the ileotracheal anastomosis, when feasible, an end-to-end ileotracheal anastomosis is preferred as it allows for optimal airflow.⁵⁴ However, most patients have a very short residual tracheal stump. In these cases, an end-to-side ileotracheal anastomosis with a tracheal opening of >1 cm can be employed.^{54,55} When the previous methods are impracticable, the inlet of the tracheal stump can also be partially sutured to the inlet of the voice tube with an additional reconstructed voice hood over the ileum inlet to aid phonation with finger occlusion of the tracheostome.^{54,55}

Fasciocutaneous free flaps are considered the gold standard in many institutions mainly because of the low donor site morbidity in comparison with abdominal surgery.^{35,56} Nevertheless, during tubularization an extra vertical suture is required, possibly contributing to a fistula rate of 13 to 24% and a stricture rate of 16.3 to 26% when using fasciocutaneous or myocutaneous flaps.^{35,57-59} Moreover, the incompatible skin-mucosa interface at the junction of fasciocutaneous flaps and the remnant of the esophagus, in addition to the hypovascularized and vulnerable T junction of tubular fasciocutaneous flaps, may explain the high incidence of fistulas occurring both proximally and distally.^{18,35,57} Additionally, even after appropriate wound healing, narrowing at the junction of skin tube and the thoracic esophagus may still occur in the long-term as the skin is more susceptible to contracture after long-standing exposure to saliva, regurgitated food, and gastric acid.

Fistulas usually occur at the pharyngoesophageal junction when using the free jejunal flap due to the anastomosis size mismatch between the jejunal segment and the pharyngeal

remnants.^{18,45,60,61} Conversely, the greater caliber of the cecum allows for a facile anastomosis proximally; however, the ascending colon has a significant size mismatch compared with the esophagus which may account for most of the leakages found at the colo-esophageal junction using the ICFF.^{6,18} In this setting, the CS flap offers additional vascularized tissue to the anterior wall which decreases the anastomotic leakage rate without affecting outcomes regarding swallowing and speech function or increasing donor site morbidity.^{6,18} Additionally, the senior authors (H.-C.C. and O.J.M.) also recommend a longitudinal cut at the upper end of thoracic esophagus before finishing the colo-esophageal anastomosis, as it has shown to widen the circumference, decrease the risk of stricture, and lessen the size mismatch.

Despite not homogeneously reported, diarrhea was a commonly encountered complication related with the ICFF.^{35,62} Nevertheless, this complication was usually self-limited and rarely required pharmacological treatment.^{26,35} While Rampazzo et al found a significant association between postoperative chemotherapy and the incidence of diarrhea ($p < 0.01$), this phenomenon is also believed to be secondary to the resection of the ileocecal valve and a postoperative period of bowel adaptation.^{26,35}

Besides postoperative diarrhea, the incidence of major donor site complications was relatively low, suggesting flap harvest is a safe procedure. Some relevant aspects to be considered for flap harvest is a multidisciplinary team in which an experienced surgeon harvest the ileocolon flap. Additionally, as harvesting this flap in theory is a controlled procedure, which means there is not an underlying intra-abdominal pathologic or inflammatory process, the donor site morbidity is usually low. In fact, the rate of postoperative intestinal adhesion is overall low, ranging from 1.6 to 2.7% in comparison to other laparotomy procedures (7.3–23%).⁶³ Furthermore, the intestinal anastomosis leak and the incidence of abdominal hernia has been reported to be 0 to 2.9% in series with more than 30 patients.^{6,23,30,32}

Conclusion

The different designs of the ICFF provide a versatile and reliable alternative for reconstruction of middle-sized defects involving the hypopharynx, larynx, and proximal esophagus. Its three-dimensional configuration and functional anatomy encourages early speech and deglutition which, in turn, allows for early adjuvant therapy within an optimal time frame coupled with minimal donor-site morbidity.

Author Contributions

Conceptualization: J.M.E. and O.J.M. Data curation: J.M.E. and D.D.-B. Formal Analysis: J.M.E. and O.J.M. Funding Acquisition: J.M.E. Investigation: J.M.E. and D.D.B. Methodology: J.M.E. and O.J.M. Project administration: O.J.M. and H.C.C. Resources: O.J.M. Software: J.M.E. Supervision: O.J.M., H.-C.C., P.C. Validation: All authors; Visualization: All authors; Writing-original draft: All authors; Writing-review and editing: All authors.

Ethical Approval

Statement of Institutional Review Board Approval and/or Statement of Conforming to the Declaration of Helsinki: The present manuscript did not require Institutional Review Board approval.

Funding

None.

Conflict of Interest

E.S. and P.C. are editorial board members of the journal but were not involved in the peer reviewer selection, evaluation, or decision process of this article. No other potential conflicts of interest relevant to this article were reported.

References

- Bradley PJ. Epidemiology of hypopharyngeal cancer. *Adv Otorhinolaryngol* 2019;83:1–14
- Yu P, Hanasono MM, Skoracki RJ, et al. Pharyngoesophageal reconstruction with the anterolateral thigh flap after total laryngopharyngectomy. *Cancer* 2010;116(07):1718–1724
- Genden EM, Ferlito A, Silver CE, et al. Evolution of the management of laryngeal cancer. *Oral Oncol* 2007;43(05):431–439
- Withrow KP, Rosenthal EL, Gourin CG, et al. Free tissue transfer to manage salvage laryngectomy defects after organ preservation failure. *Laryngoscope* 2007;117(05):781–784
- Mahalingam S, Srinivasan R, Spielmann P. Quality-of-life and functional outcomes following pharyngolaryngectomy: a systematic review of literature. *Clin Otolaryngol* 2016;41(01):25–43
- Chen HC, Ciudad P, Chen SH, Agko M. Thirty-five years of single surgeon experience in the reconstruction of esophagus and voice with free ileocolon flap following total pharyngolaryngectomy. *J Surg Oncol* 2018;117(03):459–468
- Selber JC, Xue A, Liu J, et al. Pharyngoesophageal reconstruction outcomes following 349 cases. *J Reconstr Microsurg* 2014;30(09):641–654
- Hsieh YH, Fang TJ, Huang SF, et al. Synchronous reconstruction of esophageal defect and voice with J-flap after laryngopharyngectomy: Indications and outcomes. *Oral Oncol* 2020;110:104947
- OCEBM Levels of Evidence Working Group. The Oxford 2011 Levels of Evidence. Accessed April 11, 2022 at: <https://www.cebm.ox.ac.uk/resources/levels-of-evidence/ocebml-levels-of-evidence>
- Wells G, Shea B, O'Connell D, et al. The Newcastle-Ottawa Scale (NOS) for assessing the quality if nonrandomized studies in meta-analyses. Accessed April 11, 2022 at: http://www.ohri.ca/programs/clinical_epidemiology/oxford.asp
- Murad MH, Sultan S, Haffar S, Bazerbachi F. Methodological quality and synthesis of case series and case reports. *BMJ Evid Based Med* 2018;23(02):60–63
- Kawahara H, Shiraishi T, Yasugawa H, Okamura K, Shirakusa T. A new surgical technique for voice restoration after laryngopharyngoesophagectomy with a free ileocolic graft: preliminary report. *Surgery* 1992;111(05):569–575
- Sartoris A, Succo G, Mioli P, Merlino G. Reconstruction of the pharynx and cervical esophagus using ileocolic free autograft. *Am J Surg* 1999;178(04):316–322
- Rowland RG, Mitchell ME, Bihrlle R. Alternative techniques for a continent urinary reservoir. *Urol Clin North Am* 1987;14(04):797–804
- Succo G, Mioli P, Merlino G, Sartoris A. New options for aerodigestive tract replacement after extended pharyngolaryngectomy. *Laryngoscope* 2000;110(10 pt. 1):1750–1755
- Kobayashi M, Onozuka N, Fukuda A, Matsubara A, Kobayashi W. New surgical technique for primary and secondary voice restoration using a free ileocecal patch graft after total laryngectomy. *Surg Today* 2003;33(11):817–822
- Mardini S, Chen HC, Salgado CJ, Özkan O, Cigna E, Chung TT. Free microvascular transfer of the reverse ileo-colon flap with ileo-caecal valve valvuloplasty for reconstruction of a pharyngoesophageal defect: indication and usage of the 'funnel flap'. *J Plast Reconstr Aesthet Surg* 2006;59(11):1241–1246
- Perrone F, Gharb BB, Rampazzo A, Ngo QD, Chen HC. The use of a chimaeric sero-muscular flap to prevent anastomotic leakage in head and neck reconstruction with free ileocolon flap. *J Plast Reconstr Aesthet Surg* 2012;65(06):752–756
- Hsiao HT, Leu YS, Chang YC, Yang JC, Tung KY. Voice and swallowing after laryngopharyngectomy and free ileocolic flap reconstruction for hypopharyngeal cancer. *Ann Plast Surg* 2009;62(04):390–394
- Rampazzo A, Gharb BB, di Spilimbergo SS, Chung KP, Chen HC. Voice reconstruction with free ileocolon flap transfer: implications for the lower respiratory tract. *Plast Reconstr Surg* 2011;127(05):1916–1924
- Chen HC, Mardini S, Yang CW. Voice reconstruction using the free ileocolon flap versus the pneumatic artificial larynx: a comparison of patients' preference and experience following laryngectomy. *J Plast Reconstr Aesthet Surg* 2006;59(12):1269–1275
- Kobayashi M, Meguro E, Hayakawa Y, Irinoda T, Noda Y. A new technique using free ileocecal patch transplantation for secondary voice restoration after total laryngectomy. *J Plast Reconstr Aesthet Surg* 2008;61(09):e5–e9
- Rampazzo A, Salgado CJ, Gharb BB, Mardini S, di Spilimbergo SS, Chen HC. Donor-site morbidity after free ileocolon flap transfer for esophageal and voice reconstruction. *Plast Reconstr Surg* 2008;122(06):186e–194e
- Leu YS, Huang CM, Yang CC, Hsiao HT, Chang YC. Functional outcome following free ileocolic flap in total pharyngolaryngectomy. *Acta Otolaryngol* 2008;128(06):702–705
- Tai HC, Hsieh CH, Chao KS, et al. Comparison of radiotherapy strategies for locally advanced hypopharyngeal cancer after resection and ileocolic flap reconstruction. *Acta Otolaryngol* 2009;129(03):311–317
- Karri V, Yang MC, Chung KP, Chen SH, Mardini S, Chen HC. Total pharyngolaryngectomy and voice reconstruction with ileocolon free flap: functional outcome and quality of life. *J Plast Reconstr Aesthet Surg* 2011;64(07):911–920
- Gharb BB, Rampazzo A, Hsu CT, Bassetto F, Spanio di Spilimbergo S, Chen HC. Histological changes of the voice tube and possible clinical consequences after voice reconstruction with free ileocolon flap. *Ann Plast Surg* 2013;71(01):109–113
- Tsou YA, Li TS, Tsai MH, Chen HC, Belafsky P. Optimal ileocolic flap length for a reconstructed voice tube after laryngopharyngectomy. *J Laryngol Otol* 2016;130(02):190–193
- Lo Torto F, Manrique OJ, Ciudad P, Agko M, Chung JCK, Chen HC. Pearls and pitfalls of voice reconstruction after pharyngolaryngectomy using the ileocolon free flap. *Microsurgery* 2017;37(05):453–454
- Ciudad P, Agko M, Manrique OJ, et al. The retrograde transverse cervical artery as a recipient vessel for free tissue transfer in complex head and neck reconstruction with a vessel-depleted neck. *Microsurgery* 2017;37(08):902–909
- Lo Torto F, Tzu-Liang Chen W, Agko M, et al. Laparoscopic harvest of ileocolon flap in pharyngoesophageal reconstruction. *Microsurgery* 2017;37(06):737–738
- Yang SC, Loh CYY, Tang YB, Chen HC. Using intestinal segments during secondary salvage procedures after failed reconstructions of the cervical oesophagus. *Eur J Cardiothorac Surg* 2019;55(02):286–291

- 33 Yegin ME, Chen SH, Chen HC. Vascular pedicle division during free flap re-inset in pharyngoesophageal reconstruction. *Microsurgery* 2020;40(02):154–159
- 34 Manrique OJ, Sabbagh MD, Kapoor T, Ciudad P, Chen HC. Postoperative management after total pharyngolaryngectomy using the free ileocolon flap: a 5-year surgical intensive care unit experience. *Ann Plast Surg* 2020;84(01):68–72
- 35 Lo Torto F, Ribuffo D, Manrique OJ, et al. Simultaneous restoration of swallowing and voice function with ileocolon free flap. *J Craniofac Surg* 2020;31(04):916–918
- 36 Leu YS, Hsiao HT, Chang YC, et al. Ileocolic free flap reconstruction, concomitant chemotherapy and radiotherapy and assessment of speech and swallowing function during management of advanced cancer of the larynx and hypopharynx: preliminary report. *Acta Otolaryngol* 2005;125(06):642–646
- 37 Merlini G, Bergamin F, Borsetti G. Ileocolic free flap for voice and swallowing rehabilitation after pharyngolaryngo-esophagectomy: a preliminary report. *Eur J Plast Surg* 2000;23(05):251–255
- 38 Chen HC, Gharb BB, Rampazzo A, Perrone F, Chen SH, Trignano E. Simultaneous restoration of voice function and digestive tract continuity in patients with synchronous primaries of hypopharynx and thoracic esophagus with pedicled ileocolon flap. *Surgery* 2011;149(05):662–671
- 39 Buck PM, Wax MK, Petrisor DI. Internal mammary vessels: alternate recipient vessels in microvascular head and neck reconstruction. *J Oral Maxillofac Surg* 2016;74(09):1896.e1–1896.e6
- 40 Rossmiller SR, Ghanem TA, Gross ND, Wax MK. Modified ileocolic free flap: viable choice for reconstruction of total laryngopharyngectomy with total glossectomy. *Head Neck* 2009;31(09):1215–1219
- 41 Mardini S, Chen HC, Salgado CJ, Hsu CM, Chen KT, Feng GM. Bowel preparation before microvascular free colon transfer for head and neck reconstruction: is it necessary? *Plast Reconstr Surg* 2004;113(07):1916–1922
- 42 Hutcheson KA, Lewin JS, Sturgis EM, Risser J. Outcomes and adverse events of enlarged tracheoesophageal puncture after total laryngectomy. *Laryngoscope* 2011;121(07):1455–1461
- 43 Dwivedi RC, Sattar R, Tsiropoulos G, Repanos C. Fascia lata graft closure of an enlarged tracheoesophageal puncture (TEP) after laryngectomy/laryngopharyngectomy. *Eur Arch Otorhinolaryngol* 2019;276(08):2355–2359
- 44 Gozen ED, Tevetoglu F, Eker C, Yener HM, Karaman E. A simple and effective method for closure of enlarged tracheoesophageal puncture in seven patients. *Clin Otolaryngol* 2019;44(06):1224–1227
- 45 Chang DW, Hussussian C, Lewin JS, Youssef AA, Robb GL, Reece GP. Analysis of pharyngocutaneous fistula following free jejunal transfer for total laryngopharyngectomy. *Plast Reconstr Surg* 2002;109(05):1522–1527
- 46 Disa JJ, Cordeiro PG. Reconstruction of the hypopharynx and cervical esophagus. *Clin Plast Surg* 2001;28(02):349–360
- 47 Head C, Sercarz JA, Abemayor E, Calcaterra TC, Rawnsley JD, Blackwell KE. Microvascular reconstruction after previous neck dissection. *Arch Otolaryngol Head Neck Surg* 2002;128(03):328–331
- 48 Urken ML, Vickery C, Weinberg H, Buchbinder D, Biller HF. The internal oblique-iliac crest osseomyocutaneous microvascular free flap in head and neck reconstruction. *J Reconstr Microsurg* 1989;5(03):203–214
- 49 Orfaniotis G, Sacak B, Nicoli F, et al. Absence of the ileocolic artery: Microsurgical implications in reconstruction of the esophagus with the free ileocolon flap. *Microsurgery* 2016;36(02):173–174
- 50 Kushida-Contreras BH, Manrique OJ, Gaxiola-García MA. Head and neck reconstruction of the vessel-depleted neck: a systematic review of the literature. *Ann Surg Oncol* 2021;28(05):2882–2895
- 51 Hanasono MM, Barnea Y, Skoracki RJ. Microvascular surgery in the previously operated and irradiated neck. *Microsurgery* 2009;29(01):1–7
- 52 Plant RL, Freed GL, Plant RE. Direct measurement of onset and offset phonation threshold pressure in normal subjects. *J Acoust Soc Am* 2004;116(06):3640–3646
- 53 Revenaugh PC, Knott PD, Alam DS, Kmiecik J, Fritz MA. Voice outcomes following reconstruction of laryngopharyngectomy defects using the radial forearm free flap and the anterolateral thigh free flap. *Laryngoscope* 2014;124(02):397–400
- 54 Perrone F, Gharb BB, Rampazzo A, Ngo QD, Chen SH, Chen HC. Evaluation and management of complications or functional problems at the recipient site after esophageal and voice reconstruction with free ileocolon flap. *Surgery* 2013;153(03):373–382.e2
- 55 Deschler DG, Herr MW, Kmiecik JR, Sethi R, Bunting G. Tracheoesophageal voice after total laryngopharyngectomy reconstruction: jejunum versus radial forearm free flap. *Laryngoscope* 2015;125(12):2715–2721
- 56 Carlson GW, Schusterman MA, Guillaumondegui OM. Total reconstruction of the hypopharynx and cervical esophagus: a 20-year experience. *Ann Plast Surg* 1992;29(05):408–412
- 57 Murray DJ, Novak CB, Neligan PC. Fasciocutaneous free flaps in pharyngolaryngo-oesophageal reconstruction: a critical review of the literature. *J Plast Reconstr Aesthet Surg* 2008;61(10):1148–1156
- 58 Denewer A, Khater A, Hafez MT, et al. Pharyngoesophageal reconstruction after resection of hypopharyngeal carcinoma: a new algorithm after analysis of 142 cases. *World J Surg Oncol* 2014;12(182):182
- 59 Spyropoulou GC, Lin PY, Chien CY, Kuo YR, Jeng SF. Reconstruction of the hypopharynx with the anterolateral thigh flap: defect classification, method, tips, and outcomes. *Plast Reconstr Surg* 2011;127(01):161–172
- 60 Moradi P, Glass GE, Atherton DD, et al. Reconstruction of pharyngolaryngectomy defects using the jejunal free flap: a 10-year experience from a single reconstructive center. *Plast Reconstr Surg* 2010;126(06):1960–1966
- 61 Reece GP, Schusterman MA, Miller MJ, et al. Morbidity and functional outcome of free jejunal transfer reconstruction for circumferential defects of the pharynx and cervical esophagus. *Plast Reconstr Surg* 1995;96(06):1307–1316
- 62 Sharp DA, Theile DR, Cook R, Coman WB. Long-term functional speech and swallowing outcomes following pharyngolaryngectomy with free jejunal flap reconstruction. *Ann Plast Surg* 2010;64(06):743–746
- 63 Barmparas G, Branco BC, Schnüriger B, Lam L, Inaba K, Deme-triades D. The incidence and risk factors of post-laparotomy adhesive small bowel obstruction. *J Gastrointest Surg* 2010;14(10):1619–1628