



# Gluteus Maximus Muscle Flap in Tongue in Groove and Wrap Around Pattern for Refractory CSF Leakage in Extradural Cyst Patient

Kyong Chan Park, MD<sup>1</sup> Jun Ho Lee, MD<sup>2</sup> Jae Jun Shim, MD, PhD<sup>3</sup> Hyun Ju Lee, MD, PhD<sup>4</sup>  
Hwan Jun Choi, MD, PhD<sup>2,5</sup>

<sup>1</sup> Department of Plastic and Reconstructive Surgery and College of Medicine, Soonchunhyang University, Bucheon, Korea

<sup>2</sup> Department of Plastic and Reconstructive Surgery and College of Medicine, Soonchunhyang University, Cheonan, Korea

<sup>3</sup> Department of Neurosurgery, College of Medicine, Soonchunhyang University, Cheonan, Korea

<sup>4</sup> Department of Pathology, College of Medicine, Soonchunhyang University, Cheonan, Korea

<sup>5</sup> Institute of Tissue Regeneration, Soonchunhyang University, Cheonan, Korea

**Address for correspondence** Hwan Jun Choi, MD, PhD, Department of Plastic and Reconstructive Surgery, Soonchunhyang University Cheonan Hospital, Soonchunhyang University College of Medicine, 23-20 Bongmyung-dong, Cheonan 330-721, Korea (e-mail: medi619@hanmail.net).

Arch Plast Surg 2022;49:365–368.

## Abstract

Spinal extradural arachnoid cyst (SEAC) is a rare disease and has surgical challenges because of the critical surrounding anatomy. We describe the rare case of a 58-year-old woman who underwent extradural cyst total excision with dural repair and presented with refractory cerebrospinal fluid (CSF) leakage even though two consecutive surgeries including dural defect re-repair and lumbar-peritoneal shunt were performed. The authors covered the sacral defect using bilateral gluteus maximus muscle flap in tongue in groove and wrap around pattern for protection of visible sacral nerve roots and blockage of CSF leakage point. With the flap coverage, the disappearance of cyst and fluid collection was confirmed in the postoperative radiological finding, and the clinical symptoms were significantly improved. By protecting the sacral nerve roots and covering the base of sacral defect, we can minimize the risk of complication and resolve the refractory fluid collection. Our results suggest that the gluteus muscle flap can be a safe and effective option for sacral defect and CSF leakage in extradural cyst or other conditions.

## Keywords

- ▶ tongue in groove and wrap around pattern
- ▶ gluteus maximus muscle flap
- ▶ extradural cyst
- ▶ cerebrospinal fluid
- ▶ sacral defect

Primary extradural tumors of the spine are rare and constitute approximately 4% of all spine tumors.<sup>1</sup> Despite their rarity, these tumors have surgical challenges because of the critical surrounding anatomy including the nerve roots and spinal cord. Spinal extradural arachnoid cyst (SEAC) is a

herniation of arachnoid membrane through a dural defect communicating to intradural subarachnoid space. Etiology of herniation is still unclear and can be either congenital or acquired including trauma, inflammation, and infection.<sup>2</sup> The standard treatment of SEACs remains controversial,

DOI <https://doi.org/10.1055/s-0042-1748650>.  
ISSN 2234-6163.

© 2022. The Korean Society of Plastic and Reconstructive Surgeons. All rights reserved.

This is an open access article published by Thieme under the terms of the Creative Commons Attribution-NonDerivative-NonCommercial-License, permitting copying and reproduction so long as the original work is given appropriate credit. Contents may not be used for commercial purposes, or adapted, remixed, transformed or built upon. (<https://creativecommons.org/licenses/by-nc-nd/4.0/>)

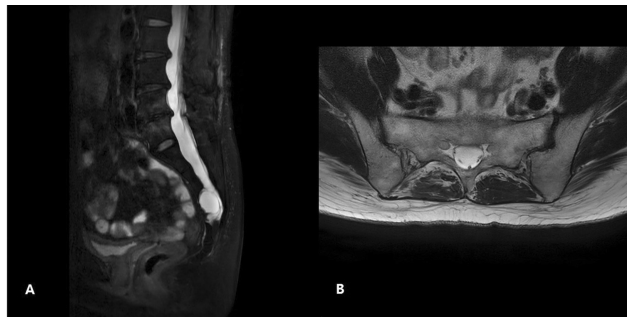Thieme Medical Publishers, Inc., 333 Seventh Avenue, 18th Floor, New York, NY 10001, USA

some insist that in case of symptomatic SEACs, a surgical procedure would be needed. The repair of dural defect is on consensus among surgeons to prevent for the cerebrospinal fluid (CSF) leakage.<sup>3</sup> Here we report our experience with case of refractory CSF leakage surgically cured by gluteus maximus muscle flap in tongue in groove and wrap around pattern.

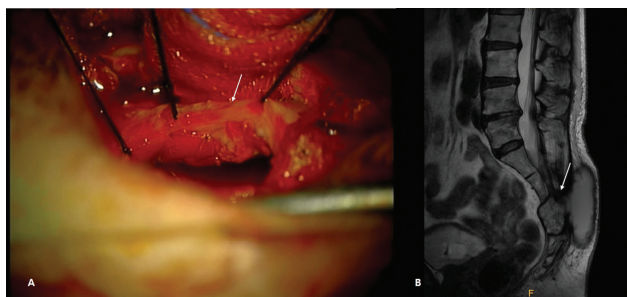
## Case Summary

A 58-year-old woman presented with radiating low back pain and voiding difficulty for 3 years. She underwent hysterectomy for adenomyosis 16 years ago, and sling operation for incontinence 8 months ago. Urinary symptom was improved with incontinence surgery, and other physical findings were not remarkable. Preoperative magnetic resonance imaging (MRI) showed 3-cm sized extradural cyst with a high T2 signal and a low T1 signal at S3 level without evident dural defect or subarachnoid communication (►Fig. 1A, B). And computed tomography (CT) revealed the bony erosion finding in adjacent posterior sacrum.

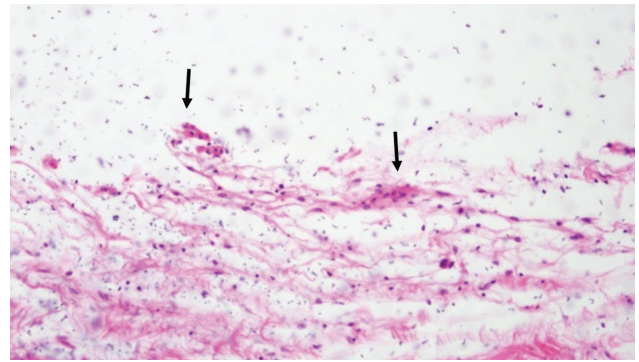
Sacral canal was opened through median sacral crest at the S3 level. The thecal sac was deviated to dorsal side due to cystic lesion and the cyst compressed sacral nerve.



**Fig. 1** Preoperative magnetic resonance imaging (MRI) images. Extradural cystic lesion is found at S3 level without evident dural defect or communication in MRI images. The cystic lesion is visible with a high signal intensity on a T2-weighted image, similar to cerebrospinal fluid (A and B).



**Fig. 2** Intraoperative photographic finding (A) and postoperative magnetic resonance image (MRI) finding (B). After sacral canal exposure, cyst removal and dural repair (white arrow) was performed using Lyodura, which is derived from dura mater of a human cadaver (A). MRI taken 4 months after the initial surgery show the fluid collection after primary repair of dural defect was identified in the cystectomy site (B). There seemed to be subarachnoid communication leading to the cerebrospinal fluid leakage (white arrow).



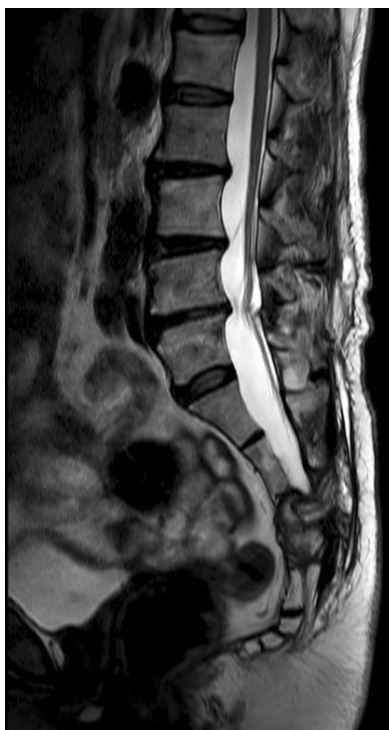**Fig. 3** Histologic finding. Histopathology showing the cyst wall lined by arachnoidal cells (arrow, hematoxylin and eosin [H&E] 200 ×). Arachnoidal cells and arachnoid cap cells were positive in epithelial membrane antigen.

removed, hole-like dural defect was found and repaired using Lyodura (B. Braun Melsungen AG, Germany), which is derived from dura mater of a human cadaver (►Fig. 2A). Microscopically, it is a benign cyst and consists of a thick fibrous wall, fibrinous fibrosis, and many hemosiderin-laden macrophages. Cyst wall was lined by arachnoidal cells and arachnoid cap cells (►Fig. 3). Histologic findings were compatible with the presence of an arachnoid cyst with fibrous cyst.

However, the patient's symptoms were constant after the surgery and fluid collection on cystectomy space was identified in MRI study 4 months after the initial surgery (►Fig. 2B). Palpable fluid collection on sacral area recurred after two consecutive surgeries of drainage with dural defect re-repair and the third operation was combined with general surgery department for lumbar-peritoneal shunt. In the reoperative field, the evidence of CSF leakage through the dural defect was absent. In the fourth operation, the department of plastic surgery was requested for coverage of bony defect and blockage of CSF leakage. After exposure of cystectomy site, the sacral defect was closed by bilateral gluteus maximus muscle flap. One is tongue in groove pattern and the other is wrap around for protection of visible sacral nerve roots and coverage of sacral defect simultaneously (►Fig. 4). The left side gluteus muscle was positioned on base of sacral defect and the right muscle flap covered the defect, so as to protect the sacral nerve roots and block the CSF leakage. Each muscle flap was approximately 6 × 4 cm in size. After closure of the wound, negative pressure wound therapy was applied on for 5 days. However, seroma formation was shown, so aspiration and compressive dressing was performed for 2 weeks. After 2 weeks, the lower back pain and palpable fluid collection disappeared. After 1 month after the flap surgery, follow-up MRI study was performed and complete disappearance of the fluid collection was shown with visualization of gluteus maximus muscle flap (►Fig. 5). And 1 year after surgery, she has not shown any symptoms.

## Discussion

SEAC is a rare disease and the prevalence of SEACs is most likely in the thoracic region for 65%, lumbar region for 25%,



**Fig. 4** Postoperative photographic finding after 1 month after the flap surgery. A complete disappearance of the fluid collection was shown with visualization of gluteus maximus muscle flap.

and sacral region in 6%.<sup>4,5</sup> SEACs are mostly asymptomatic and found among male patients in their 20s to 50s.<sup>6</sup> The presenting symptoms may include radiating pain, paresthesia, claudication, bowel or bladder dysfunction, and weakness.

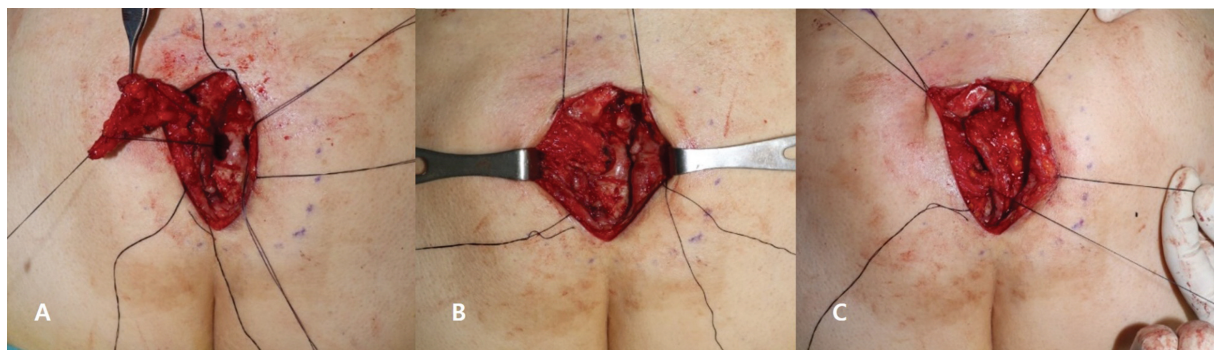
The pathogenesis of SEACs is not clear. It is assumed to be the result of dural defect and cause of dural defect can be congenital and acquired. Although there is still debate in determining the etiology of SEACs, the theory of congenital dural defect is widely accepted.<sup>7</sup> One hypothesis is that tension across the movable dural sac and fixed roots can be subject to dural tearing. In case of structural abnormality such as Marfan syndrome, the probability of dural tearing may be increased. However, there are cases of no dural defect identified. In that case, authors explained that the cyst occurred by pulsatile CSF dynamics through dural defect

and the communication had been gradually closed over time and then disappeared.<sup>8</sup>

The exact mechanism of cyst expansion affecting the spinal cord is also not yet identified, but several theories have been proposed. The first hypothesis is ball valve mechanism that the CSF pressure increases intermittently, which expands the cyst and creates tension in the cyst wall. When the CSF pressure decreases again, the tension applied to the cyst presses the pedicle to prevent the CSF outflow from the cyst. Another theory is hyperosmolar collection of fluid within the cyst causing free water to enter. The other theory is active fluid secretion from the cyst wall, expanding gradually due to lack of communication with the subarachnoid space. It is based on cases of recurred cyst after the dural defect repaired like our experience. Several cases reported in the literature have speculated that the valve-like mechanism with intermittent surges in CSF pressure. The exacerbation of symptoms during exercise and Valsalva maneuvers is related to inflation of cyst. CSF pressure increases temporarily and fluid enters the cyst on straining and coughing, causing some degree of spinal cord compression.<sup>9</sup>

Because the clinical symptoms of SEACs are similar to those of degenerative spine disease, SEACs are easy to misdiagnosis. An MRI is the most useful diagnostic tool.<sup>10</sup> CT myelography or CSF flow MRI study can identify the location of dural defective site between the subarachnoid and the cyst cavity.<sup>3</sup> Recently, the usefulness of other imaging study such as kinematic MRI or time-spatial labeling inversion pulse MRI have been reported for detection of the communicating hole.<sup>11</sup>

In our case, the patient had no history of trauma, arachnoiditis, previous spine operation, and no specific underlying disease. The dural defect was detected and repaired in initial surgery and the repaired state was confirmed in serial surgeries. Histological evaluation showed that the cyst wall in our case only contains hemorrhagic tissue and layered collagenous fibers, but not the glands or secreting tissues. We suggest the possibility of another communication such as dural defect between the subarachnoid space and the cystectomy site. And it is assumed that the muscle flap covered the leakage point. Although there was a probable communication hole identified in MRI taken 4 months after the initial surgery, but further evaluation such as CSF flow MRI study could be helpful.



**Fig. 5** Intraoperative photographic finding. Sacral defect was covered by bilateral gluteus maximus muscle flap in tongue in groove and wrap around pattern (A, B). The left gluteus maximus muscle flap was positioned on base of sacral defect to protect the sacral nerve roots. The right gluteus muscle flap was covered by the sacral defect above the sacral bone and the wound was closed (C).

The gluteus maximus muscle is one of the most frequently used flaps, because flap separation is technically easy, while it has an abundance of blood circulation and excellent elasticity due to a large volume of the muscle.<sup>12</sup> The muscle provides a straightforward option for this challenging spinal wound with minimal morbidity. Because of its bulk, it completely obliterates any dead space, and also acts as a biological barrier to the continuous leakage of the CSF. Further theoretical advantages of the muscle included drainage of the CSF back to the circulation through its rich capillary network.<sup>13</sup> Banerjee et al described a technique of lumbosacral pseudomeningocele repair involving a two-layer pants-over-vest closure of the pseudomeningocele coupled with mobilization of bilateral paraspinous musculature to create a Z-plasty, or a Z-shaped flap.<sup>14</sup> And this report including 10 patients demonstrated a high success rate without recurrence. Previous retrospective study reported that 19 patients of SEAC underwent complete or partial excision of cyst with dural repair and none of them showed recurrence or clinical deterioration.<sup>15</sup>

To the best of our knowledge, this is a first case of refractory CSF leakage after extradural cyst complete excision and dural repair, resolved by muscle flap coverage.

A SEAC is caused by the herniation of the arachnoid membrane. We experienced a rare case of refractory CSF leakage after extradural cyst complete excision, even though the serial dural repair and lumbar-peritoneal shunt were performed. With the flap coverage, the disappearance of cyst and fluid collection was confirmed in the postoperative radiological finding, and the clinical symptoms were significantly improved. By protecting the sacral nerve roots and covering the base of sacral defect, we can minimize the risk of complication and resolve the refractory fluid collection. Our muscle flap coverage in tongue in groove and wrap around pattern for sacral defect produced good clinical and radiological outcomes. This muscle flap is a useful reconstructive option for spine surgeon to manage these challenging spinal wounds presenting refractory CSF leakage.

#### Ethical Approval

The study was performed in accordance with the principles of the Declaration of Helsinki. Written informed consent was obtained.

#### Patient Consent

The patient provided written informed consent for the publication and the use of images.

#### Author Contributions

Conceptualization : H.J.C. Data curation : J.J. S. and J.H.L. Methodology : H.J.L. Project administration : H.J.C. Writing-original draft : K.C.P. Writing-review and editing : K.C.P.

#### Funding

This work was supported by grants from National Research Foundation of Korea (NRF), grants founded by the Korea government (MSIT) (No. 2020R1A2C110089), and was supported by Soonchunhyang University research fund.

#### Conflict of Interest

None declared.

#### References

- Kelley SP, Ashford RU, Rao AS, Dickson RA. Primary bone tumours of the spine: a 42-year survey from the Leeds Regional Bone Tumour Registry. *Eur Spine J* 2007;16(03):405-409
- Lee CH, Hyun SJ, Kim KJ, Jahng TA, Kim HJ. What is a reasonable surgical procedure for spinal extradural arachnoid cysts: is cyst removal mandatory? Eight consecutive cases and a review of the literature. *Acta Neurochir (Wien)* 2012;154(07):1219-1227
- Woo JB, Son DW, Kang KT, et al. Spinal extradural arachnoid cyst. *Korean J Neurotrauma* 2016;12(02):185-190
- Basaldella L, Orvieto E, Dei Tos AP, Della Barbera M, Valente M, Longatti P. Causes of arachnoid cyst development and expansion. *Neurosurg Focus* 2007;22(02):E4
- Samartzis D, Gillis CC, Shih P, O'Toole JE, Fessler RG. Intramedullary spinal cord tumors: part I-epidemiology, pathophysiology, and diagnosis. *Global Spine J* 2015;5(05):425-435
- Choi SW, Seong HY, Roh SW. Spinal extradural arachnoid cyst. *J Korean Neurosurg Soc* 2013;54(04):355-358
- Oh JK, Lee DY, Kim TY, et al. Thoracolumbar extradural arachnoid cysts: a study of 14 consecutive cases. *Acta Neurochir (Wien)* 2012;154(02):341-348
- Kim IS, Hong JT, Son BC, Lee SW. Noncommunicating spinal extradural meningeal cyst in thoracolumbar spine. *J Korean Neurosurg Soc* 2010;48(06):534-537
- Choi JY, Kim SH, Lee WS, Sung KH. Spinal extradural arachnoid cyst. *Acta Neurochir (Wien)* 2006;148(05):579-585
- Netra R, Min L, Shao Hui M, Wang JC, Bin Y, Ming Z. Spinal extradural meningeal cysts: an MRI evaluation of a case series and literature review. *J Spinal Disord Tech* 2011;24(02):132-136
- Ishibe T, Senzoku F, Ikeda N, Kamba Y, Mikawa Y. Detection of the communicating hole(s) of spinal extradural arachnoid cysts using time-spatial labeling inversion pulse magnetic resonance imaging. *Spine* 2014;39(23):E1394-E1397
- Bae SW, Lim TK, Kim HS, Song BY. Hatchet-type gluteus maximus musculocutaneous flap for reconstruction of sacral pressure sore. *Arch Hand Microsurg* 2014;23(01):25-28
- Wanjala NF, Stanley KO. Island latissimus dorsi muscle flap and a perforator flap in repairing post-gunshot thoracic spine CSF fistula: case presentation. *Case Rep Surg* 2015;2015:219535
- Banerjee C, Cross B, Rumley J, Devine J, Ritter E, Vender J. Multiple-layer lumbosacral pseudomeningocele repair with bilateral paraspinous muscle flaps and literature review. *World Neurosurg* 2020;144:e693-e700
- Singh S, Bhaisora KS, Sardhara J, et al. Symptomatic extradural spinal arachnoid cyst: more than a simple herniated sac. *J Craniovertebr Junction Spine* 2019;10(01):64-71