



Ultrasound Imaging/Guidance to Augment Musculoskeletal Interventions

Orhan Güvener¹, Vincenzo Ricci², Levent Özçakar³

¹Department of Physical and Rehabilitation Medicine, University of Mersin of Medical School, Mersin, Turkey; ²Unit of Physical and Rehabilitation Medicine, Luigi Sacco University Hospital, ASST Fatebenefratelli-Sacco, Milan, Italy; ³Department of Physical and Rehabilitation Medicine, University of Hacettepe of Medical School, Ankara, Turkey

We read with interest White et al. [1] pictorial review published in the journal. We agree that literature- and image-supported methodological efforts to improve the knowledge, confidence, and experience of physicians as regards ultrasound-guided musculoskeletal interventions are important for education and training, as well as for providing high-quality health care. Herewith, we also believe that maximum caution/diligence should be taken when preparing technical descriptions/images, as the readers will focus on these aspects when attempting application in daily clinical practice. To this end, we would like to note some minor points concerning ultrasound imaging/guidance.

For instance, in their Figure 6, the authors describe the common flexor tendon injection. However, although the probe is shown correctly placed on the medial side of the elbow, the corresponding ultrasound image shows the common extensor tendon. Of note, using short- and long-axis imaging, specific parts of the tendons (or adjacent soft tissues) can be targeted for different scenarios [2]. Another

Received: November 4, 2021 **Accepted:** November 29, 2021

Corresponding author: Orhan Güvener, MD, Department of Physical and Rehabilitation Medicine, University of Mersin of Medical School, Çiftlikköy, Yenişehir/Mersin 33110, Turkey.

• E-mail: dr.orhanguvener@gmail.com

This is an Open Access article distributed under the terms of the Creative Commons Attribution Non-Commercial License (<https://creativecommons.org/licenses/by-nc/4.0>) which permits unrestricted non-commercial use, distribution, and reproduction in any medium, provided the original work is properly cited.

point is related to paratenon stripping, which is described in non-insertional Achilles tendinosis. Although the authors, in their Figure 13, describe saline injections by targeting the ‘superficial’ and ‘deep’ paratenons, it is important to mention that a “deep” paratenon between the Achilles tendon and the fat pad has not been anatomically and histologically demonstrated in the human body (Fig. 1) [3].

Moreover, following the technical and conceptual developments in ultrasound imaging and guidance for musculoskeletal interventions, it is noteworthy that prompt/specific terminologies should necessarily replace old approaches. It is preferable to use an expression such as ‘intra-lesional platelet-rich plasma injection for an incomplete partial-thickness tear of the supraspinatus tendon on the bursal side,’ instead of a general/non-specific terminology such as ‘shoulder injection’ [4,5].

Conflicts of Interest

The authors have no potential conflicts of interest to disclose.

ORCID iDs

Orhan Güvener

<https://orcid.org/0000-0003-2771-7055>

Vincenzo Ricci

<https://orcid.org/0000-0003-2576-2039>

Levent Özçakar

<https://orcid.org/0000-0002-2713-4071>

Funding Statement

None

REFERENCES

1. White R, Croft M, Bird S, Sampson M. Ultrasonography-guided common musculoskeletal interventions from head to toe: procedural tips for general radiologists. *Korean J Radiol* 2021;22:2006-2016
2. Çarlı AB, Ricci V, Tekin L, Kumbhare D. *Periarticular and soft tissue injections – upper limb*. In: Ozcakar L, Chang KV, Gürçay E, Park G, Franchignomi F, Ricci V, eds. *Ultrasound imaging and guidance for musculoskeletal interventions in physical and rehabilitation medicine*, 1st ed. Milan: Edi Ermes, 2020:183-206
3. Stecco C, Cappellari A, Macchi V, Porzionato A, Morra A,

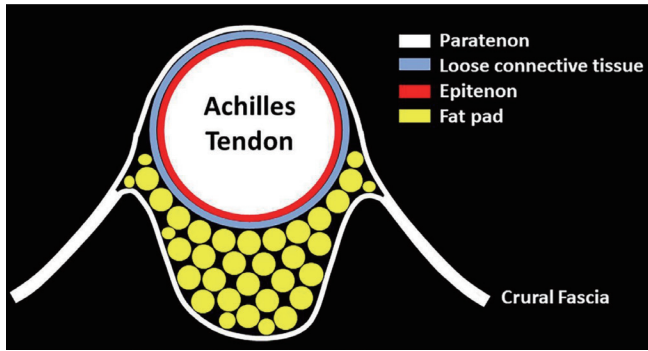


Fig. 1. Schematic diagram showing the histo-anatomical architecture of the paratendineous tissue of the Achilles tendon.

Berizzi A, et al. The paratendineous tissues: an anatomical study of their role in the pathogenesis of tendinopathy. *Surg Radiol Anat* 2014;36:561-572

4. Ricci V, Özçakar L. Life after ultrasound: are we speaking the same (or a new) language in physical and rehabilitation Medicine? *J Rehabil Med* 2019;51:234-235
5. Ricci V, Mezian K, Özçakar L. Contemporary/ultrasound guidance for musculoskeletal interventions: let bygones be bygones. *Am J Phys Med Rehabil* 2021;100:e134-e135