



Tracheal Membrane Rupture as the Cause of Pneumomediastinum in a Patient with COVID-19

Bao Fu, Jie Hu, Tao Chen, Xiaoyun Fu

All authors: Department of Critical Care Medicine, Affiliated Hospital of Zunyi Medical University, Zunyi, China

Recently, pneumomediastinum has been reported in patients with coronavirus disease 2019 (COVID-19) including cases published in the *Korean Journal of Radiology* [1-3]. Endotracheal intubation is commonly performed to treat COVID-19; tracheal membrane injury, a rare and potentially life-threatening complication associated with this procedure, can cause pneumomediastinum. The most common symptoms of tracheal injury are dyspnea, subcutaneous emphysema, and mediastinal emphysema. Diagnosis requires a high suspicion index and is thus often delayed; indeed, intubation, iatrogenic tracheal injuries were confirmed in nearly 15% of emergency intubations according to autopsy [4]. Herein, we report a case of tracheal membrane rupture after tracheal intubation and invasive mechanical ventilation in a patient with COVID-19.

An 80-year-old female was diagnosed with COVID-19 and admitted to the hospital. The physical examination findings were as follows: temperature, 36.7°C; heart rate, 86 beats/min; respiratory rate, 20 beats/min, oxygen saturation, 97% (in room air); and blood pressure, 116/95 mm Hg. Chest computed tomography (CT) on admission

revealed exudative lesions in both the upper and lower lobes of the left lung (Fig. 1A). As her condition worsened, she was transferred to the intensive care unit (ICU). She received awake prone position therapy and noninvasive mechanical ventilation. Two days after ICU admission, the patient underwent visual laryngoscope-guided tracheal intubation.

On the second day after tracheal intubation, she underwent a re-examination of chest CT, and the results showed extensive subcutaneous emphysema and mediastinal emphysema (Fig. 1B). Further, chest CT showed rupture of the tracheal membrane (Fig. 1C). She developed severe acute respiratory distress syndrome and subsequently received veno-venous extracorporeal membrane oxygenation (V-V ECMO) as treatment. After 5 days of ECMO treatment, bedside X-ray examination showed that the emphysema had been absorbed (Fig. 1D). At present, the patient's condition remains stable.

Tracheal membrane rupture is typically caused by mechanical injuries. The incidence of tracheobronchial injury in patients with chest and neck trauma, including death, is between 0.5% and 2.0% [5]. Iatrogenic causes of tracheal injury include percutaneous dilatation, tracheostomy, tracheal intubation, and hard bronchoscopy [6]. The patient was intubated a day before the development of a suspected tracheal injury. The intubation process was smooth and gentle; therefore, the possibility of tracheal membrane injury induced by intubation procedure was relatively low. A previous study reported the first case of tracheal stenosis due to viral tracheitis associated with COVID-19 [7]. A recent study also reported two cases of COVID-19-related laryngotracheitis [8]. Therefore, we speculate that tracheal membrane injury in this patient may be related to tracheal inflammation caused by COVID-19 rather than mechanical injury. If tracheal injury can be detected and treated in time, the outcome is generally good. Chest X-rays are the initial method to evaluate trauma patients and may show signs of tracheal injury, including symptoms of subcutaneous emphysema, mediastinal emphysema, or "fallen lung" [9]. CT imaging has been shown to have an accuracy rate of 94%–100% in diagnosing tracheal injuries, and bronchoscopy is the gold standard for detecting tracheal damage [9].

Once tracheal injury is determined, the first problem

Received: December 17, 2021 **Revised:** January 18, 2022

Accepted: January 28, 2022

Corresponding author: Xiaoyun Fu, MD, PhD, Department of Critical Care Medicine, Affiliated Hospital of Zunyi Medical University, 149 Dalian road, Zunyi, Guizhou Province 563000, China.

• E-mail: zyxyfy@163.com

This is an Open Access article distributed under the terms of the Creative Commons Attribution Non-Commercial License (<https://creativecommons.org/licenses/by-nc/4.0>) which permits unrestricted non-commercial use, distribution, and reproduction in any medium, provided the original work is properly cited.

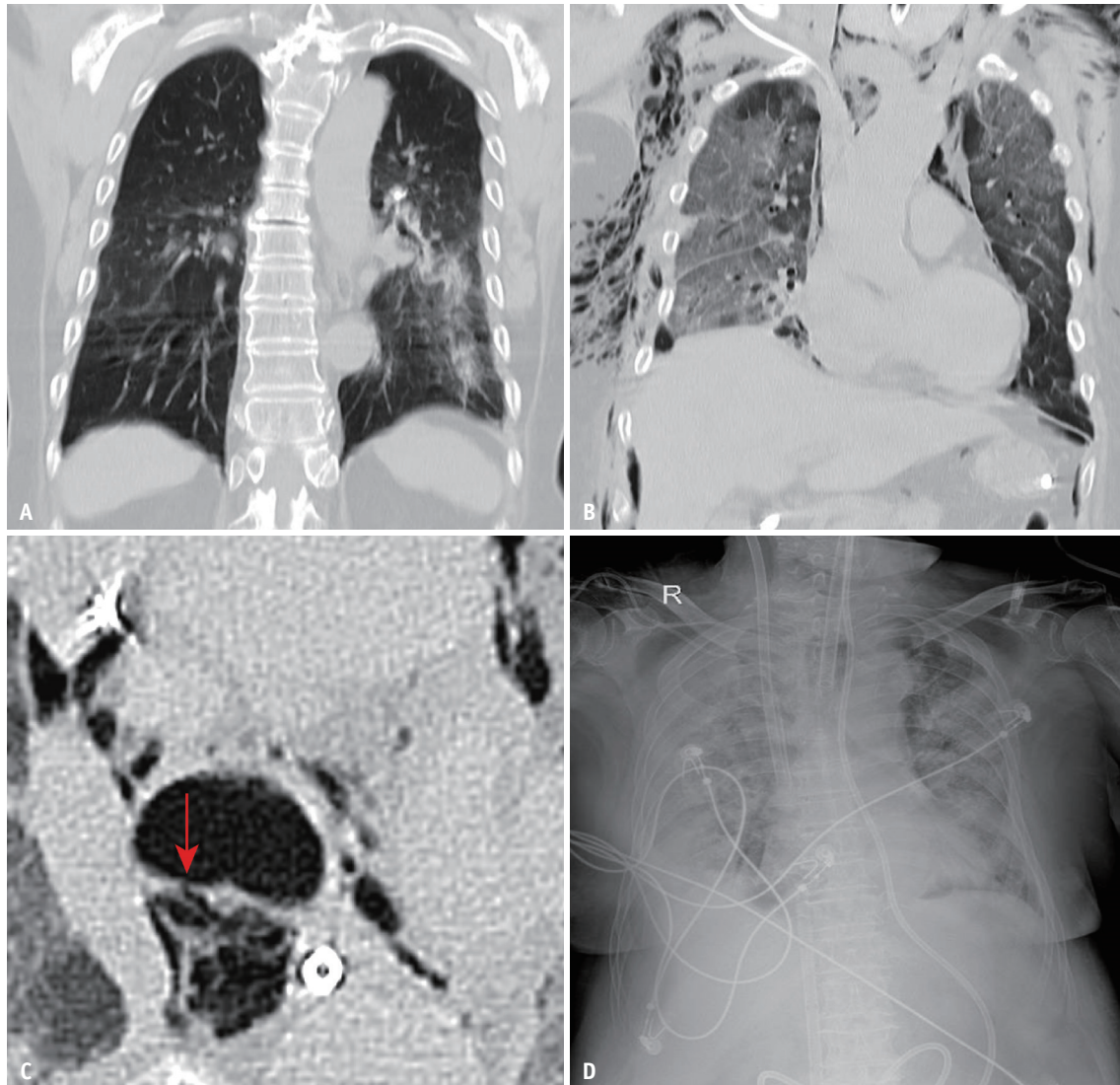


Fig. 1. Changes in the patient's chest imaging.

A. Chest CT image at the time of admission. **B.** Chest CT image the day after tracheal intubation. **C.** Rupture of the patient's tracheal membrane (arrow). The injury was 2 cm away from the tracheal carina and 0.5 cm above the tip of the endotracheal tube. **D.** Chest CT image on the fifth day after veno-venous extracorporeal membrane oxygenation.

that needs to be solved is how to deal with the patient's airway. Different oxygenation and ventilation methods can be used according to the location of the injury. A common method is to advance the endotracheal tube past the injury, allowing oxygenation and ventilation, while minimizing the risk of positive pressure. Owing to severe hypoxemia, this patient received V-V ECMO, which guarantees oxygenation. In this case, temporary use of ECMO allowed the trachea to heal while avoiding the sequelae of hypoxia. When the trachea is severely ruptured, a one-stage surgical repair with V-V ECMO support can be considered.

Conflicts of Interest

The authors have no potential conflicts of interest to disclose.

ORCID iDs

Bao Fu

<https://orcid.org/0000-0002-6836-229X>

Jie Hu

<https://orcid.org/0000-0001-8578-3478>

Tao Chen

<https://orcid.org/0000-0002-9974-0871>

Xiaoyun Fu

<https://orcid.org/0000-0003-1727-449X>

Funding Statement

None

Acknowledgments

Thanks the patient and her family.

REFERENCES

1. Sun R, Liu H, Wang X. Mediastinal emphysema, giant bulla, and pneumothorax developed during the course of COVID-19 pneumonia. *Korean J Radiol* 2020;21:541-544
2. Wang J, Su X, Zhang T, Zheng C. Spontaneous pneumomediastinum: a probable unusual complication of coronavirus disease 2019 (COVID-19) pneumonia. *Korean J Radiol* 2020;21:627-628
3. Lei P, Mao J, Wang P. Spontaneous pneumomediastinum in a patient with coronavirus disease 2019 pneumonia and the possible underlying mechanism. *Korean J Radiol* 2020;21:929-930
4. Richardson JD. Outcome of tracheobronchial injuries: a long-term perspective. *J Trauma* 2004;56:30-36
5. Prokakis C, Koletsis EN, Dedeilias P, Fligou F, Filos K, Dougenis D. Airway trauma: a review on epidemiology, mechanisms of injury, diagnosis and treatment. *J Cardiothorac Surg* 2014;9:117
6. Farley LS, Schlicksup KE. *Tracheal injury*. Treasure Island: StatPearls Publishing, 2021
7. Ershadi R, Rafieian S, Sarbazzadeh J, Vahedi M. Tracheal stenosis following mild-to-moderate COVID-19 infection without history of tracheal intubation: a case report. *Gen Thorac Cardiovasc Surg* 2022;70:303-307
8. Oliver CM, Campbell M, Dulan O, Hamilton N, Birchall M. Appearance and management of COVID-19 laryngo-tracheitis: two case reports. *F1000Res* 2020;9:310
9. Welter S. Repair of tracheobronchial injuries. *Thorac Surg Clin* 2014;24:41-50