



# MRI Findings in Trigeminal Neuralgia without Neurovascular Compression: Implications of Petrous Ridge and Trigeminal Nerve Angles

Hai Zhong<sup>1</sup>, Wenshuang Zhang<sup>2</sup>, Shicheng Sun<sup>3</sup>, Yifan Bie<sup>1</sup>

<sup>1</sup>Department of Radiology, The Second Hospital, Cheeloo College of Medicine, Shandong University, Jinan, China; Departments of <sup>2</sup>Radiology and <sup>3</sup>Neurosurgery, Shandong Provincial Hospital, Cheeloo College of Medicine, Shandong University, Jinan, China

**Objective:** To determine the anatomical characteristics of the petrous ridge and trigeminal nerve in trigeminal neuralgia (TN) without neurovascular compression (NVC).

**Materials and Methods:** From May 2017 to March 2021, 66 patients (49 female and 17 male; mean age  $\pm$  standard deviation [SD],  $56.8 \pm 13.3$  years) with TN without NVC and 57 controls (46 female and 11 male;  $52.0 \pm 15.6$  years) were enrolled. The angle of the petrous ridge (APR) and angle of the trigeminal nerve (ATN) were measured using magnetic resonance imaging with a high-resolution three-dimensional T2 sequence. Data on the symptomatic side were compared with those on the asymptomatic side in patients and with the mean measurements of the bilateral sides in controls. Receiver operating characteristic (ROC) analysis was conducted to evaluate the performance of APR and ATN in distinguishing TN patients from controls.

**Results:** In TN patients without NVC, the mean  $\pm$  standard deviation (SD) of APR on the symptomatic side ( $98.40^\circ \pm 19.75^\circ$ ) was significantly smaller than that of the asymptomatic side ( $105.59^\circ \pm 22.45^\circ$ ,  $p = 0.019$ ) and controls ( $108.44^\circ \pm 15.98^\circ$ ,  $p = 0.003$ ). The mean ATN  $\pm$  SD on the symptomatic side ( $144.41^\circ \pm 8.92^\circ$ ) was significantly smaller than that of the asymptomatic side ( $149.67^\circ \pm 8.09^\circ$ ,  $p = 0.003$ ) and controls ( $150.45^\circ \pm 8.48^\circ$ ,  $p = 0.001$ ). The area under the ROC curve for distinguishing TN patients from controls was 0.673 (95% confidence interval [CI]: 0.579–0.758) for APR and 0.700 (CI: 0.607–0.782) for ATN. The sensitivity and specificity using the diagnostic cutoff yielding the highest Youden index were 81.8% (54/66) and 49.1% (28/57), respectively, for APR (with a cutoff score of  $94.30^\circ$ ) and 65.2% (43/66) and 66.7% (38/57), respectively, for ATN (cutoff score,  $148.25^\circ$ ).

**Conclusion:** In patients with TN without NVC, APR and ATN were smaller than those in controls, which may explain the potential cause of TN and provide additional information for diagnosis.

**Keywords:** Neurovascular compression; Trigeminal neuralgia; Aangulation; Petrous ridge; Magnetic resonance imaging

## INTRODUCTION

Trigeminal neuralgia (TN) is clinically defined as paroxysmal, stereotyped attacks of intense, sharp, superficial, or stabbing pain in the distribution of one or

more branches of the trigeminal nerve [1]. Neurovascular compression (NVC) is considered to be the main cause of classical TN. Since microvascular decompression (MVD) was first used by Gardener in 1966 [2], it has been widely applied in the treatment of TN, with immediate satisfactory

**Received:** October 4, 2021 **Revised:** April 26, 2022 **Accepted:** April 27, 2022

**Corresponding author:** Yifan Bie, MD, Department of Radiology, The Second Hospital, Cheeloo College of Medicine, Shandong University, #247 Beiyuan Street, Jinan 250033, Shandong, China.

• E-mail: yizcatus@163.com; and

Shicheng Sun, MD, Department of Neurosurgery, Shandong Provincial Hospital, Cheeloo College of Medicine, Shandong University, #324 Jingwu Road, Jinan 250021, Shandong, China.

• E-mail: nn8191899@163.com

This is an Open Access article distributed under the terms of the Creative Commons Attribution Non-Commercial License (<https://creativecommons.org/licenses/by-nc/4.0>) which permits unrestricted non-commercial use, distribution, and reproduction in any medium, provided the original work is properly cited.

outcomes in most classical cases. As the incidence of recurrence has been reported to be 3%–30% [3–5], results of post-MVD imaging studies showed that most patients with recurrent TN did not have recurrent NVC after surgery [6]. It has also been reported that NVC might not be found during surgical explorations, with variable incidence from 3% to 89% [3,6–14]. Additionally, venous or arterial contact with the trigeminal nerve is observed even in healthy subjects [15–19]. Therefore, some studies have explored other potential causes. Some authors traced the trigeminal nerve and its relationship with the surrounding tissues and bony structures in the skull base to identify the likely locations of mechanical compression [20]. Other authors have reported that nerve branches may be tensioned or compressed by spurs or ossified ligaments near the bony foramen and ridges [21–24]. Some studies showed that the arachnoidal dissection along the entire length of the nerve has good efficacy in clinical practice for TN patients without NVC because it made the trigeminal nerve near the entrance of Meckel's cave straight and flaccid [3,5]. A previous study reported a small petrous ridge and accordingly affected the trigeminal nerve in TN patients with NVC [25], which showed that the bone edge might contribute to TN, at least as an indirect factor. We considered that the impact of the petrous bone on TN could be more directly explored if vessel interference was ruled out. Therefore, the present study aimed to compare the anatomical characteristics of the petrous ridge and trigeminal nerve in TN patients without NVC using high-resolution magnetic resonance imaging (MRI) and to determine the performance of the angle of the petrous ridge (APR) and angle of the trigeminal nerve (ATN) in distinguishing patients with TN from those without TN.

## MATERIALS AND METHODS

### Patients and Inclusion Criteria

This retrospective study enrolled patients from the outpatient department between May 2017 and March 2021 who were diagnosed with TN according to the International Classification of Headache Disorders (3rd edition) [1]. The patients had no NVC in the trigeminal root entry zone on MRI. Patients with prior intracranial surgery, known brain malformations, tumors, and secondary trigeminal neuropathy were excluded. Patients with TN presenting with bilateral symptoms were also excluded. Controls were selected for comparison, including patients with hemifacial spasm (HS) and normal subjects who had negative MRI

results in the prepontine cistern. All procedures performed in this study were in accordance with the ethical standards of the recommendations of the Institutional Review Board, and informed consent was obtained from all participants included in the study (IRB No. KYLL-2017P192).

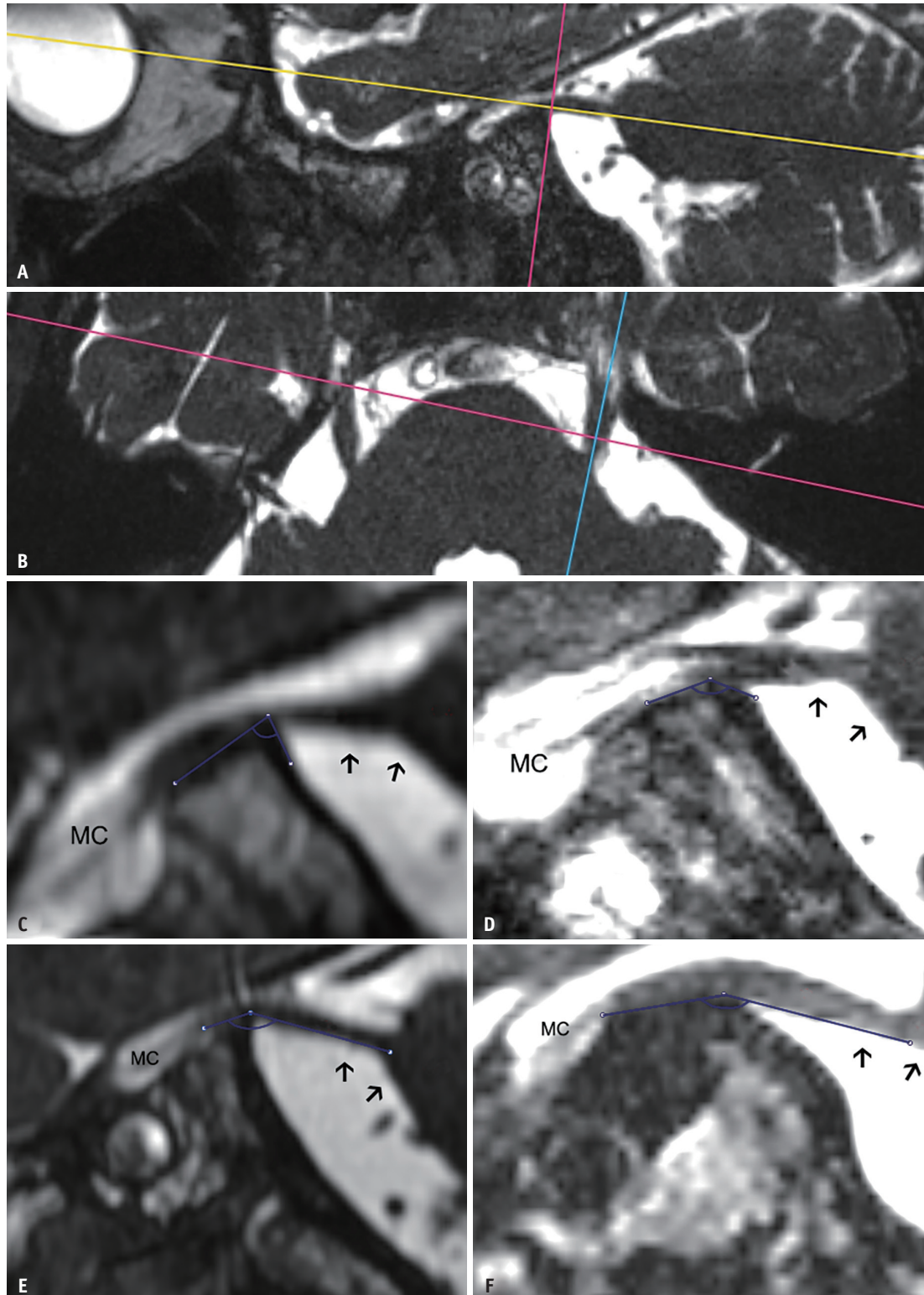
### Neuroimaging and Measurements

Neuroimaging was performed using 3T MRI scanners. MRI data were obtained using high-resolution three-dimensional T2 sequences (repetition time, 2000 ms; echo time, 207 ms; acquisition matrix, 400 × 278; acquisition voxel measurement/phase/slice, 0.40/0.57/1.00; reconstruction voxel measurement/phase/slice, 0.29/0.29/0.50; flip angle, 90°; number of signal average, 3; and 16-channel head coil) centered on the trigeminal nerve path and a standard protocol of conventional axial T1-weighted and T2-weighted images. All images were transferred to a personal workstation for post-processing and analysis using the RadiAnt DICOM Viewer (version 2020.2.3; Medixant) and Digimizer (version 4.2.6; MedCalc Software).

Axial images were oriented centering on the cisternal segment of the trigeminal nerve, and measurements in the oblique sagittal view on each side were performed separately following the axis of the cisternal segment of the trigeminal nerve (Fig. 1A, B). In the oblique sagittal view, the APR and that of the trigeminal nerve were measured bilaterally as follows: 1) APR was measured following the upper ridge of the petrous bone to define its bony sharpness (Fig. 1C, D), and 2) ATN was measured following the path from Meckel's cave to the upper petrous ridge and from the upper petrous ridge to the pons to identify the angulation of the trigeminal nerve over the petrous ridge (Fig. 1E, F). Measurements were performed by two neuroradiologists with 5 years of experience who were blinded to the clinical information, and one of them repeated the analysis. The average values of the two readers' measurements were used in the final analysis.

### Statistical Analysis

The characteristics of the study participants were compared between patients with TN and controls using the independent *t* test and chi-square test. APR and ATN are expressed as mean ± SD for all measurements. The Kolmogorov–Smirnov test was used to determine the normal distribution of quantitative variables. Data were compared between the two sides and between groups using Student's *t* test after the equality of variances was verified when data



**Fig. 1. Methodology and examples of comparison between patients and controls.**

**A.** Axial images are centered on the cisternal segment of the trigeminal nerve (yellow line). **B.** Oblique sagittal view of the measurements on each side is set following the axis of the cisternal segment of the trigeminal nerve (blue line). **C-F.** The angle of the petrous ridge is measured following the upper ridge of the petrous bone in a patient (**C**) and in a control subject (**D**). The angle of the trigeminal nerve is measured following the path from Meckel's cave to the upper petrous ridge and from the upper petrous ridge to the pons in a patient (**E**) and an example control subject (**F**). Arrows indicate the course from the cisternal segment of the trigeminal nerve to the ventral pons. MC = area of Meckel's cave

were normally distributed.

Intraclass correlation (ICC) analysis was used to assess inter- and intra-observer agreement. ICC values < 0.4, between 0.4 and 0.8, and > 0.8 indicate weak, moderate, and strong agreement, respectively. Receiver operating characteristic (ROC) analysis was conducted to determine the diagnostic performance of APR and ATN in differentiating between patients with TN and controls. Statistical tests were bilateral, and the associations were considered statistically significant at  $p < 0.05$ . SPSS software (version 20.0, IBM Corp.) and MedCalc (version 20.106, MedCalc Software) were used for the statistical analyses.

## RESULTS

### Patient Demographics

Between May 2017 and March 2021, 66 patients (49 female and 17 male) with unilateral TN (left side, 24 and right side, 42) and mean age  $56.8 \pm 13.3$  years were included in this study. Fifty-seven participants were included in the control group. A comparison of the measurement data between the HS group ( $n = 37$ ) and normal subjects ( $n = 21$ ) revealed no significant differences (Supplementary Table 1). The mean age of the 57 controls (46 female and 11 male) was  $52.0 \pm 15.6$  years. Patients and controls showed no differences in sex or age (Table 1).

### Measurements of the Petrous Ridge and Trigeminal Nerve

The mean APR in patients was  $98.40^\circ \pm 19.75^\circ$  on the symptomatic side and  $105.59^\circ \pm 22.45^\circ$  on the

**Table 1. Characteristics of Study Participants**

Characteristic	Patients (n = 66)	Controls (n = 57)	P
Age, year	$56.8 \pm 13.3$	$52.0 \pm 15.6$	0.075
Sex			0.394
Female	49 (74.2)	46 (80.7)	
Male	17 (25.8)	11 (19.3)	
Affected side			
Left	24 (36.4)	NA	
Right	42 (63.6)	NA	

Data are mean  $\pm$  standard deviation or patient number with % in parentheses. NA = not applicable

**Table 2. Measurements of the Petrous Bone and the Trigeminal Nerve Angles**

Value	Symptomatic (n = 66)	Asymptomatic (n = 66)	Controls (n = 57)	P (S-A)	P (S-C)
APR, °	$98.40 \pm 19.75$	$105.59 \pm 22.45$	$108.44 \pm 15.98$	0.019	0.003
ATN, °	$144.41 \pm 8.92$	$149.67 \pm 8.09$	$150.45 \pm 8.48$	0.003	< 0.001

Data are mean  $\pm$  standard deviation. APR = angle of the petrous ridge, ATN = angle of the trigeminal nerve, S-A = symptomatic-to-asymptomatic, S-C = symptomatic-to-control

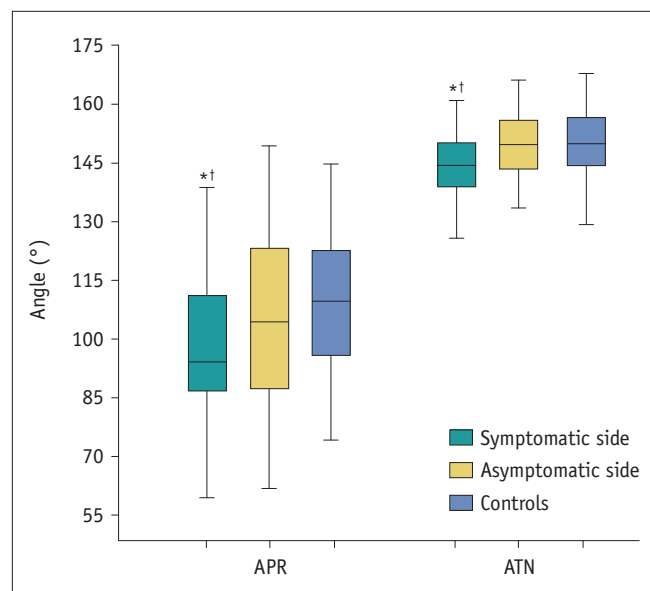
asymptomatic side, with significant differences between the two sides ( $p = 0.019$ ). In the controls, APR on both sides was measured, and the mean value was calculated. The mean APR on the symptomatic side in patients was significantly different from that in controls ( $108.44^\circ \pm 15.98^\circ$ ,  $p = 0.003$ ).

Compared with ATN on the asymptomatic side ( $149.67^\circ \pm 8.09^\circ$ ) in patients and controls ( $150.45^\circ \pm 8.48^\circ$ ), the mean ATN on the symptomatic side in patients was  $144.41^\circ \pm 8.92^\circ$  and significantly smaller ( $p = 0.003$  and  $p < 0.001$ , respectively) (Table 2, Fig. 2).

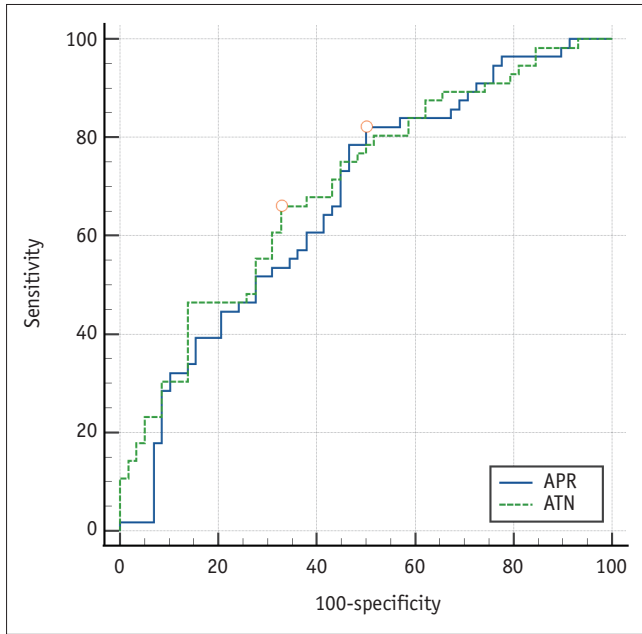
Intra- and inter-observer agreements of measurements were assessed (APR, ICC = 0.997 and 0.812,  $p < 0.001$ ; ATN, ICC = 0.911 and 0.786,  $p < 0.001$ , respectively).

### ROC Analysis

ROC curves and areas the under the ROC curve (AUCs) for APR and ATN are shown in Figure 3. AUC and 95%



**Fig. 2. Measurements of the petrous ridge and the trigeminal nerve.** Data for the bilateral sides of the controls are averaged for comparison. APR and ATN showed significant differences between the symptomatic and asymptomatic sides in patients ( $p = 0.019$  and  $p = 0.003$ , respectively) and between the symptomatic side of patients and controls ( $p = 0.003$  and  $p < 0.001$ , respectively). \* $p < 0.05$  compared to controls, † $p < 0.05$  compared to the asymptomatic side. APR = angle of the petrous ridge, ATN = angle of the trigeminal nerve



**Fig. 3. ROC analysis of the petrous ridge and the trigeminal nerve.** ROC curves of diagnostic performance for differentiating between trigeminal neuralgia patients without neurovascular compression and controls. Areas under the ROC curve and 95% confidence intervals for APR and ATN are 0.673 (0.579–0.758) and 0.700 (0.607–0.782), respectively. The points yielding the highest Youden indices are marked on the curves. APR = angle of the petrous ridge, ATN = angle of the trigeminal nerve, ROC = receiver operating characteristic

**Table 3. ROC Analysis of the Petrous Ridge and Trigeminal Nerve Angles for Diagnosing Trigeminal Neuralgia**

Parameter	AUC*	Sensitivity <sup>†</sup>	Specificity <sup>†</sup>
APR	0.673 (0.579–0.758)	0.818 (54/66)	0.491 (28/57)
ATN	0.700 (0.607–0.782)	0.652 (43/66)	0.667 (38/57)

\*The values in parentheses are 95% confidence interval, <sup>†</sup>Using cutoff scores yielding the highest Youden index, 94.30° for APR and 148.25° for ATN. APR = angle of the petrous ridge, ATN = angle of the trigeminal nerve, AUC = areas under the ROC curve, ROC = receiver operating characteristic

confidence intervals for APR and ATN were 0.673 (0.579–0.758) and 0.700 (0.607–0.782). Regarding the diagnostic performance for differentiating between TN patients without NVC and controls, the highest Youden index (sensitivity + specificity - 1) was 0.321 with an APR cutoff score of 94.30° (sensitivity, 81.8%, 54 of 66 patients; specificity, 49.1%, 28 of 57 controls) and 0.333 with an ATN cut-off score of 148.25° (sensitivity, 65.2%, 43 of 66 patients; specificity, 66.7%, 38 of 57 controls) (Table 3).

## DISCUSSION

Previous studies have shown that factors closely related

to TN are the volume of the prepontine cistern and cerebellopontine angle [17]. However, assessments of the petrous bone and the nerve around the porus trigeminus have not yet been conducted in patients with TN, especially in those without NVC.

In the present study, we focused on patients with TN but without NVC. Although NVC is regarded as the prevalent method to guide the interpretation and treatment of TN, patients with recurrent TN without specific NVC found on MRI have been reported [6]. This implies that there may be other pathogenic factors contributing to neuralgia. Considering previous reports on the influence of several bony structures on the transcranial segment of the trigeminal nerve [20,23], we presumed that the petrous ridge might be a factor of the skull base related to the underlying compression of the trigeminal nerve.

We selected TN patients with negative NVC results to rule out the interference of vessels that would lift or push the trigeminal nerve. ATN is directly correlated with the petrous bone. It seems plausible that patients with TN tend to have more severe compression of the petrous ridge, as was observed in our study. We measured the APR to evaluate the sharpness of the petrous bony ridge because it would provide a mechanical stimulus or cause injury to the trigeminal nerve at the upper ridge of the petrous bone. ATN was measured as a morphological value to reflect the latent compression of the trigeminal nerve when it passed through the porus trigeminus.

Procedures for TN without NVC, such as arachnoid dissection or isolation with thin Teflon fragments, are considered to protect the nerve from underlying compression or adhesion by surrounding structures [3,5]. In one study, 19 TN patients without NVC underwent 360° circumferential arachnoid dissection, and the main surgical strategy in these cases involved the dissection and exposure of the entire trigeminal nerve root, especially when a thickened arachnoid, angulation, or torsion of the trigeminal nerve root was noted intraoperatively [5].

A smaller APR was observed on the symptomatic side in these patients. Since it has been reported that the adhesion between the nerve and the surrounding structures could cause a tethering effect [14], we hypothesized that it would be much easier for the nerve to undergo a stretching force or mechanical irritation from the aggressively sharp petrous ridge.

ATN directly reflects the morphological changes occurring in the trigeminal nerve related to the sharpness of the

petrous bone. We showed that ATN was smaller on the symptomatic side in patients. Additionally, APR and ATN in patients on the symptomatic side were smaller than those on the asymptomatic side, which might result from the asymmetric morphologies of the bilateral petrous ridges. As the prevalence increases with age [26], we hypothesized that the asymmetry of hyperostosis with age on the bilateral petrous bone might contribute to TN.

In the present study, we aimed to depict the anatomy of the trigeminal nerve around the petrous ridge and use the obtained data to aid in the diagnosis and evaluation of TN without NVC preoperatively or postoperatively. MRI is usually included in routine clinical evaluation of patients with TN. Therefore, three-dimensional reconstruction and measurement could become part of clinical practice for comprehensive assessment of TN. Additionally, APR and ATN showed acceptable performances in ROC analysis, and thus, these parameters might be useful for predicting and evaluating patients with TN. The results of our study showed smaller APR and ATN in TN, which is consistent with the results of a previous study [25]. Nevertheless, regarding the inclusion of patients, we enrolled TN patients without NVC to rule out the interference of vessels, which made the impact of the petrous bone straighter and observation more convincing.

To preclude interference from vessel conflicts, we selected TN patients without NVC, and the total number of cases was limited because the overall proportion of TN patients with negative findings was small [14]. Controls that included subjects with HS and normal subjects had negative MRI results in the cisternal segment of the trigeminal nerve area. The comparison of the measurement data between the HS group and normal subjects showed no significant difference; therefore, we included all subjects in a single group to expand the control group. Additionally, our results could hardly prove that there were more obvious anatomical characteristics than previously thought in patients with TN. Although we expected confirmation of the angulation, routine medications were recommended for most patients with TN without NVC. Therefore, this observational study was devoid of surgical validation. A cause-and-effect relationship between the obtained results and TN could not be established in this cross-sectional study. We proposed cutoff values/angles to differentiate between normal and abnormal angulations. The results were not satisfactory because of the insufficient number of cases in the present study, and they need to be verified in the future to provide clinical references for TN without NVC. Further studies with larger sample sizes

and longitudinal follow-up are needed, and the anatomical characteristics of structures around the porus trigeminus deserve more attention during surgical exploration.

In conclusion, in TN patients without NVC, APR and ATN were significantly smaller than those in control subjects, which implied that smaller APR and ATN might be a potential cause of TN without NVC. These findings may provide additional information for the diagnosis of TN without NVC.

## Supplement

The Supplement is available with this article at <https://doi.org/10.3348/kjr.2021.0771>.

## Availability of Data and Material

The datasets generated or analyzed during the study are available from the corresponding author on reasonable request.

## Conflicts of Interest

The authors have no potential conflicts of interest to disclose.

## Author Contributions

Conceptualization: Hai Zhong, Yifan Bie, Shicheng Sun. Data curation: Hai Zhong, Wenshuang Zhang. Formal analysis: Wenshuang Zhang. Investigation: Shicheng Sun. Methodology: Yifan Bie. Project administration: Yifan Bie. Resources: Hai Zhong, Yifan Bie, Shicheng Sun. Software: Hai Zhong, Wenshuang Zhang. Supervision: Shicheng Sun. Validation: Yifan Bie. Visualization: Shicheng Sun. Writing—original draft: Hai Zhong, Yifan Bie. Writing—review & editing: Yifan Bie, Shicheng Sun.

## ORCID iDs

Hai Zhong

<https://orcid.org/0000-0001-7530-6862>

Wenshuang Zhang

<https://orcid.org/0000-0002-9291-2538>

Shicheng Sun

<https://orcid.org/0000-0001-9783-3081>

Yifan Bie

<https://orcid.org/0000-0001-9169-4287>

## Funding Statement

None

### Acknowledgments

We thank International Science Editing (<http://www.internationalscienceediting.com>) for editing this manuscript.

### REFERENCES

- Headache Classification Committee of the International Headache Society (IHS). The international classification of headache disorders, 3rd edition. *Cephalalgia* 2018;38:1-211
- Rand RW. Gardner neurovascular decompression of the trigeminal and facial nerves for tic douloureux and hemifacial spasm. *Surg Neurol* 1981;16:329-332
- Revuelta-Gutiérrez R, López-González MA, Soto-Hernández JL. Surgical treatment of trigeminal neuralgia without vascular compression: 20 years of experience. *Surg Neurol* 2006;66:32-36; discussion 36
- Lee SH, Levy EI, Scarrow AM, Kassam A, Jannetta PJ. Recurrent trigeminal neuralgia attributable to veins after microvascular decompression. *Neurosurgery* 2000;46:356-361; discussion 361-362
- Guo H, Song X, Wang X, Bao Y. Surgical treatment of trigeminal neuralgia with no neurovascular compression: a retrospective study and literature review. *J Clin Neurosci* 2018;58:42-48
- Kuncz A, Vörös E, Barzó P, Tajti J, Milassin P, Mucsi Z, et al. Comparison of clinical symptoms and magnetic resonance angiographic (MRA) results in patients with trigeminal neuralgia and persistent idiopathic facial pain. Medium-term outcome after microvascular decompression of cases with positive MRA findings. *Cephalalgia* 2006;26:266-276
- Jannetta PJ. Arterial compression of the trigeminal nerve at the pons in patients with trigeminal neuralgia. *J Neurosurg* 1967;26:159-162
- Klun B. Microvascular decompression and partial sensory rhizotomy in the treatment of trigeminal neuralgia: personal experience with 220 patients. *Neurosurgery* 1992;30:49-52
- Adams CB, Kaye AH, Teddy PJ. The treatment of trigeminal neuralgia by posterior fossa microsurgery. *J Neurol Neurosurg Psychiatry* 1982;45:1020-1026
- Patel NK, Aquilina K, Clarke Y, Renowden SA, Coakham HB. How accurate is magnetic resonance angiography in predicting neurovascular compression in patients with trigeminal neuralgia? A prospective, single-blinded comparative study. *Br J Neurosurg* 2003;17:60-64
- Rath SA, Klein HJ, Richter HP. Findings and long-term results of subsequent operations after failed microvascular decompression for trigeminal neuralgia. *Neurosurgery* 1996;39:933-938; discussion 938-940
- Zhao H, Zhang X, Tang D, Li S. Nerve combing for trigeminal neuralgia without vascular compression. *J Craniofac Surg* 2017;28:e15-e16
- Sindou MP, Chiha M, Mertens P. Anatomical findings observed during microsurgical approaches of the cerebellopontine angle for vascular decompression in trigeminal neuralgia (350 cases). *Stereotact Funct Neurosurg* 1994;63:203-207
- Ishikawa M, Nishi S, Aoki T, Takase T, Wada E, Ohwaki H, et al. Operative findings in cases of trigeminal neuralgia without vascular compression: proposal of a different mechanism. *J Clin Neurosci* 2002;9:200-204
- Ruiz-Juretschke F, González-Quarante LH, García-Leal R, Martínez de Vega V. Neurovascular relations of the trigeminal nerve in asymptomatic individuals studied with high-resolution three-dimensional magnetic resonance imaging. *Anat Rec (Hoboken)* 2019;302:639-645
- Peker S, Dinçer A, Necmettin Pamir M. Vascular compression of the trigeminal nerve is a frequent finding in asymptomatic individuals: 3-T MR imaging of 200 trigeminal nerves using 3D CISS sequences. *Acta Neurochir (Wien)* 2009;151:1081-1088
- Park SH, Hwang SK, Lee SH, Park J, Hwang JH, Hamm IS. Nerve atrophy and a small cerebellopontine angle cistern in patients with trigeminal neuralgia. *J Neurosurg* 2009;110:633-637
- Kakizawa Y, Seguchi T, Kodama K, Ogiwara T, Sasaki T, Goto T, et al. Anatomical study of the trigeminal and facial cranial nerves with the aid of 3.0-tesla magnetic resonance imaging. *J Neurosurg* 2008;108:483-490
- Magnaldi S, Cecconi P, Skrap M, Ricci C, Cova MA, Pozzi-Mucelli RS. Magnetic resonance in trigeminal neuralgia. *Radiol Med* 1992;83:700-705
- Liang L, Diao Y, Xu Q, Zhang M. Transcranial segment of the trigeminal nerve: macro-/microscopic anatomical study using sheet plastination. *Acta Neurochir (Wien)* 2014;156:605-612
- Krmpotić-Nemanić J, Vinter I, Hat J, Jalsovec D. Mandibular neuralgia due to anatomical variations. *Eur Arch Otorhinolaryngol* 1999;256:205-208
- Tubbs RS, May WR Jr, Apaydin N, Shoja MM, Shokouhi G, Loukas M, et al. Ossification of ligaments near the foramen ovale: an anatomic study with potential clinical significance regarding transcuteaneous approaches to the skull base. *Neurosurgery* 2009;65(6 Suppl):60-64; discussion 64
- Liu P, Zhong W, Liao C, Liu M, Zhang W. Narrow foramen ovale and rotundum: a role in the etiology of trigeminal neuralgia. *J Craniofac Surg* 2016;27:2168-2170
- Guo H, Wang X, Song C, Song Z, Liang J, Song G, et al. Trigeminal neuralgia secondary to osteoid osteoma of the petrous bone: report of 4 cases and brief review of literature. *World Neurosurg* 2018;114:e713-e718
- Brinzeu A, Dumot C, Sindou M. Role of the petrous ridge and angulation of the trigeminal nerve in the pathogenesis of trigeminal neuralgia, with implications for microvascular decompression. *Acta Neurochir (Wien)* 2018;160:971-976
- Araya EI, Claudino RF, Piovesan EJ, Chichorro JG. Trigeminal neuralgia: basic and clinical aspects. *Curr Neuropharmacol* 2020;18:109-119