

# Evaluation of ultrasonography as a diagnostic tool in the management of periapical cysts and granulomas: A clinical study

Fatma Avcı<sup>1,\*</sup>, Meryem Etöz<sup>1</sup>, Yakup Üstün<sup>2</sup>, Tuğrul Arslan<sup>2</sup>

<sup>1</sup>Department of Oral and Maxillofacial Radiology, Faculty of Dentistry, University of Erciyes, Melikgazi, Turkey

<sup>2</sup>Department of Endodontics, Faculty of Dentistry, University of Erciyes, Melikgazi, Turkey

## ABSTRACT

**Purpose:** The aim of this study was, firstly, to determine the concordance of ultrasonographic and histopathological diagnoses in patients in whom apical resection was already indicated. Secondly, this study aimed to determine whether lesions were periapical granulomas or cysts, and to compare them after root canal treatment using ultrasonography and periapical radiographs.

**Materials and Methods:** In the first stage of the study, ultrasonographic and histopathologic diagnoses of 10 lesions were compared. Secondly, the periapical radiographs and ultrasonographic images of 44 lesions were measured. The presence of internal vascularity was determined by ultrasonographic color and power Doppler modes. Follow-up examinations of healing after root canal treatment were performed using ultrasonography and periapical radiographs, and these modalities were compared.

**Results:** In the periapical granuloma and cyst groups, the measurement values decreased for all variables. There was no significant difference in the dimensional changes of lesions between the 2 groups, and ultrasonography and periapical radiographs were compatible. The pre-diagnoses were compared with histopathological diagnoses and were found to be compatible.

**Conclusion:** The ultrasonographic color and power Doppler techniques could be an effective method for diagnosing periapical lesions as cysts or granulomas. After root canal treatment of granulomas and cysts, the dimensional shrinkage and healing patterns appear to be similar. Ultrasonography and periapical radiographs were consistent in terms of dimensional comparisons, and ultrasonography may be an alternative method for follow-up of the healing of periapical lesions. (*Imaging Sci Dent* 2022; 52: 209-17)

**KEY WORDS:** Periapical Granuloma; Radicular Cyst; Ultrasonography; Radiography

## Introduction

Periapical radiolucencies caused by dental caries and trauma are often diagnosed as periapical granulomas or periapical cysts. Periapical cysts are 3-dimensional pathological cavities of endodontic origin, which are localized around the tooth apex, surrounded by a non-keratinized stratified squamous epithelium of varying size. Periapical granulomas are derived from a chronic defense reaction

of the alveolar bone to irritations through the apical foramen or through a side canal in the root canal.<sup>1</sup> Different points of view exist regarding endodontic treatment protocols with regard to periapical cysts and granulomas.<sup>2,3</sup> However, radiographs are insufficient for differentiating periapical cysts and granulomas.<sup>1</sup> They do not reliably show the size of bone lesions and do not allow a differential diagnosis between cystic and solid lesions.<sup>1,4</sup>

Ultrasonography (USG) is a minimally invasive imaging method that has been used in medicine for many years without causing any known biological damage. Not using ionizing radiation to obtain the image is one of the most important advantages of USG in the evaluation of diseases in the human body.<sup>5</sup> The color and power Doppler

Received September 22, 2021; Revised December 8, 2021; Accepted December 27, 2022  
Published online March 15, 2022

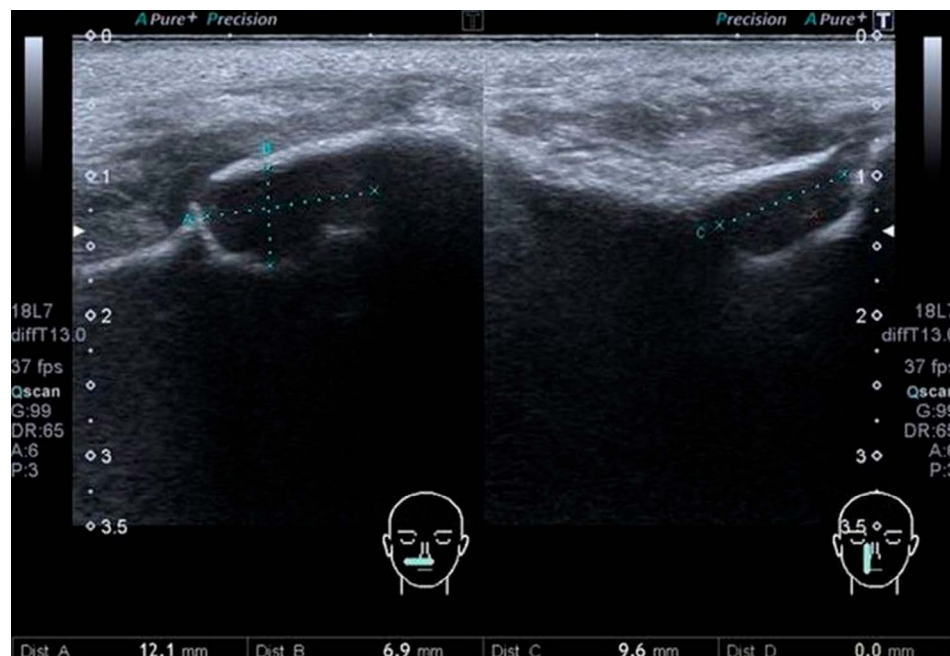
\*Correspondence to : Dr. Fatma Avcı

Department of Oral and Maxillofacial Radiology, Faculty of Dentistry, Erciyes University, Melikgazi, Kayseri 38039, Turkey  
Tel) 90-507-881-37-85, E-mail) fatmakocoglu77@gmail.com

Copyright © 2022 by Korean Academy of Oral and Maxillofacial Radiology

This is an Open Access article distributed under the terms of the Creative Commons Attribution Non-Commercial License (<http://creativecommons.org/licenses/by-nc/3.0>) which permits unrestricted non-commercial use, distribution, and reproduction in any medium, provided the original work is properly cited.

Imaging Science in Dentistry · pISSN 2233-7822 eISSN 2233-7830



**Fig. 1.** B-mode ultrasonography shows the mesio-distal and antero-posterior measurements of a periapical lesion with the transducer in the transverse position (left). B-mode ultrasonography shows the supero-inferior dimension of the periapical lesion with the transducer in the longitudinal position (right).

USG methods allow an evaluation of the presence, direction, and velocity of blood flow in the tissue under examination.<sup>6</sup>

Many studies have suggested that USG could be used for the differential diagnosis of periapical granulomas and cysts.<sup>5-9</sup> According to these studies, a periapical cyst is a hypoechoic cavity surrounded by reinforced bone walls, filled with fluid, and without evidence of internal vascularization on color and power Doppler examinations. A granuloma is defined as a well-circumscribed, hyperechoic/echogenic lesion with a rich vascular source on color and power Doppler examinations.<sup>7</sup>

The first purpose of this study was to determine the concordance of ultrasonographic evaluations and histopathological diagnoses in patients in whom apical resection was already indicated. The second purpose was to determine the cystic and solid characteristics of the lesions using color and power Doppler USG examinations in cases of periapical cysts and granulomas that could not be differentiated by clinical and radiographic data and to compare the follow-up of healing with USG and periapical radiographs after root canal treatment.

### Materials and Methods

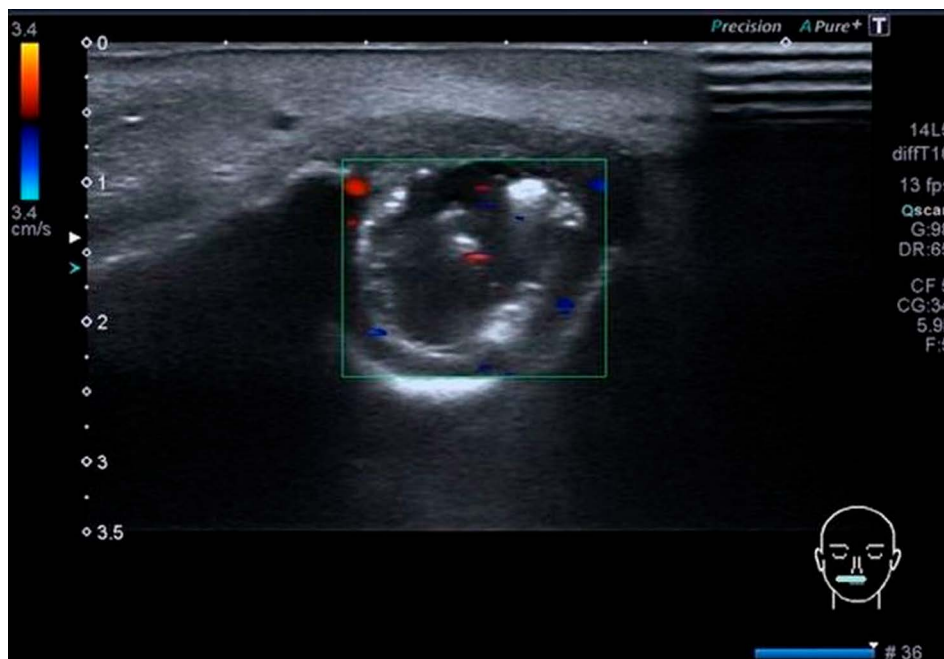
Ethical approval of the protocol 2018/570 was obtained from Erciyes University Clinical Research Ethics Committee in accordance with the Helsinki Declaration. All patients in the study were informed about the study and

their written consent was obtained.

The study was conducted in 2 stages. In the first stage, the presence of vascularity in lesions for which apical resection was already indicated in patients treated at the Department of Endodontics was determined by using the Doppler mode of USG. The lesions were classified as solid (periapical granulomas) or cystic (periapical cysts). The post-treatment histopathological diagnosis of the lesions was compared with the USG findings. In the second stage, the mesio-distal (M-D) and supero-inferior (S-I) sizes of 44 periapical lesions detected on panoramic radiographs were measured using periapical radiographs. In USG examinations of the same lesions, the limits were determined and dimensional measurements were performed. The color and power Doppler modes of the USG device were used to determine and record the vascularity of the lesions.

The lesion size was re-measured on periapical radiographs and USG examinations at 6 months following canal treatment in the same 44 cases, and the measurements were compared with those obtained before treatment (Fig. 1).

This study included 10 patients in whom apical resection was indicated at the Department of Endodontics and who were referred to the Maxillofacial Surgery Clinic, and 44 patients who were referred to the Department of Oral and Maxillofacial Radiology of Erciyes University Faculty of Dentistry for dental examinations between September 2018 and December 2018 and who had peri-



**Fig. 2.** Ultrasonographic color Doppler image shows a periapical granuloma. In this solid lesion, vascular foci are shown using color.

apical radiolucencies on their panoramic radiograms.

The inclusion criteria for volunteers were patients with periapical lesions of the lower and upper jaw anterior teeth detected on panoramic radiographs, and patients with periapical lesions after root canal treatment in whom apical resection was indicated. The exclusion criteria were patients with intra-bony lesions not directly related to the root apex in the maxillary and mandibular anterior region, patients who had radiolucencies in the periapical area but had vital teeth (e.g., cases of periapical cemental dysplasia), pediatric patients, patients with metabolic bone disease, patients with single- or double-sided cleft palate, and individuals who did not cooperate with treatment and follow-up.

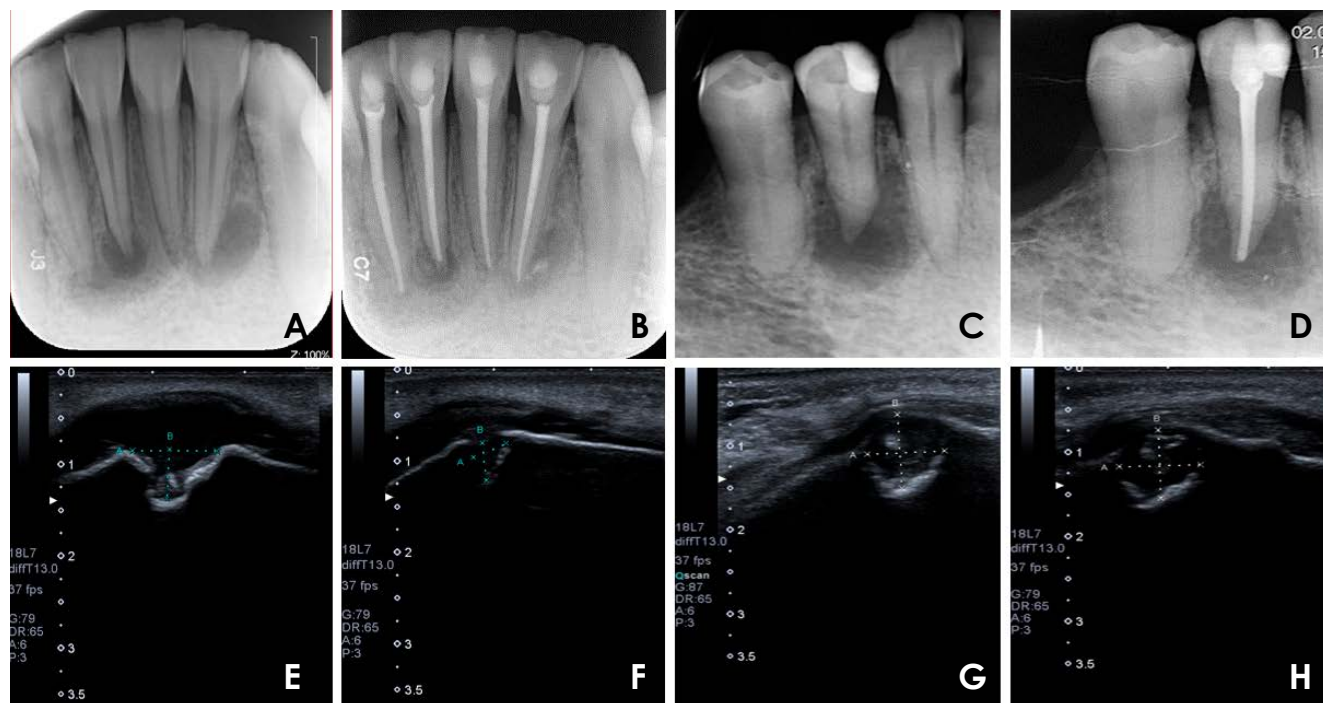
The USG examinations were performed by a single investigator (FA) using an ultrasound device (Aplio™ 500; Toshiba Medical Systems Corp, Otawara, Japan) using the B-mode and high frequency (7.2-14 MHz) linear scanning probe (PLT 1204BT). To prevent possible artifacts and oblique imaging, the probe was held perpendicular to the surface of the skin, and a water-based gel was applied to prevent the presence of air between the probe and the skin.

The M-D and antero-posterior (A-P) dimensions of periapical lesions were measured by positioning the probe in the transverse position; the S-I dimension of the lesion was measured and recorded by positioning it in the longitudinal position (Fig. 2). The presence of interior lesion vascularization was detected and recorded using the color

and power Doppler modes of the USG device (Figs. 3 and 4). With the use of the device's color and power Doppler modes, the vascularity and pulsation status of the intra-lesion tissue were determined and recorded. In determining the presence of vascularity with the color Doppler mode, checks were completed by lowering the blood flow velocity to 2 cm/s in order to detect low-flow currents after adjusting the area indicator according to the size of the lesion. In order to ensure the standardization of intra-lesion pulsations with the power Doppler mode, the angle correlation value of the device was determined as 60° and investigations were performed.

For radiographic measurements, periapical radiographs were obtained from patients with a Progeny X-ray unit (Preva, DK51267, Midmark Corp, Dayton, OH, USA), and using the parallel technique with phosphorous plates (No. 1 and No. 2) according to the lesions' localization and an automatic plate reader was applied according to the manufacturer's instructions. The M-D and S-I sizes of the lesions on periapical radiographs were measured with the MedData program (MedData Technologies, Georgetown, TX, USA) and recorded by the same investigator.

Root canal treatment was performed by 2 endodontists with at least 10 years of clinical experience in the Department of Endodontics of Erciyes University Faculty of Dentistry. All root canal treatment procedures were done using rubber dam isolation. The working length of each tooth was determined using an electronic apex locator (Propex Pixi Dentsply Maillefer, Ballaigues, Switzer-



**Fig. 3.** Comparative presentation of periapical radiography and ultrasonographic (USG) images of the two cases before and after treatment. A. Pre-treatment periapical radiography of a periapical cyst. B. Post-treatment periapical radiography of a periapical cyst. C. Pre-treatment periapical radiography of a periapical granuloma. D. Post-treatment periapical radiography of a periapical granuloma. E. Pre-treatment USG image of a periapical cyst. F. Post-treatment USG image of a periapical cyst. G. Pre-treatment USG image of a periapical granuloma. H. Post-treatment USG image of a periapical granuloma.

land). For the preparation of the root canals, C2 and C4 files of the EdgeFile X3 series (EdgeEndo, Albuquerque, NM, USA) were used with a torque-regulated endodontic motor (X Smart Plus, Dentsply Maillefer, Ballaigues, Switzerland) according to the manufacturer's instructions. Between the use of each file, the root canals were irrigated with 2 mL of 2.5% NaOCl (ImidentMed, Konya, Turkey). The final irrigation was performed with 3 mL of 17% EDTA for 1 minute and 3 mL of distilled water solution followed by 3 mL of 2% chlorhexidine. The canals were dried with paper points (Dentsply Maillefer, Ballaigues, Switzerland). The root canals were then filled with a premixed calcium hydroxide paste (DiaPaste; Diadent, Almere, The Netherlands), and the teeth were sealed with a temporary filling material (Cavit G; 3M ESPE, St Paul, MN, USA). After 1 week, the intracanal medicament was removed by irrigation with 5 mL NaOCl (ImidentMed, Konya, Turkey), 3 mL of EDTA, followed by 3 mL of distilled water and 3 mL of 2% chlorhexidine with the help of an Endoactivator device (Dentsply Maillefer, Ballaigues, Switzerland). The canals were dried with paper points (Dentsply Maillefer, Ballaigues, Switzerland) and filled with AH Plus Jet (Dentsply DeTrey, Konstanz, Ger-

many) and gutta-percha cones (Dentsply Maillefer, Ballaigues, Switzerland). The access cavities were restored with a composite resin material (Universal Restorative 200, 3M ESPE, St. Paul, MN, USA).

The periapical lesions were excised during apical resection. Tissue was cleaned with normal saline solution and kept in a 10% formalin solution. After obtaining the appropriate samples, they were kept in the tissue monitor for 12 hours. The samples were then embedded in paraffin and 5 µm sections were taken and placed on the slide. Hematoxylin-eosin staining was performed, and the samples were examined with a light microscope (Olympus BX51, Center Valley, PA, USA).

Statistical analyses were performed using SPSS version 22 (IBM Corp., Armonk, NY, USA) and Medcalc v.18.11.6. (Medcalc Software, Ostend, Belgium). The level of statistical significance was taken as  $P=0.05$ . The normality of the distribution of the data was tested using the Shapiro-Wilk test. If the data had a normal distribution, the t-test was used for comparisons between groups, and the paired t-test was used for intra-group comparisons; otherwise, the Mann-Whitney U test and the Wilcoxon test were used. The comparison of repeated measurements between groups

was made according to the percentage change values based on the initial value. Descriptive values were given as the arithmetic mean and standard deviation when parametric tests were used, and as median and minimum-maximum (min-max) values when non-parametric tests were used. The chi-square test, the Fisher exact chi-square test, and the Fisher-Freeman-Halton test were used to compare categorical data between the groups. Dependent categorical variables were compared using the McNemar test. Evaluator agreement was analyzed using the intra-class correlation coefficient (ICC). The concordance between the measured values was examined using the Bland-Altman method.

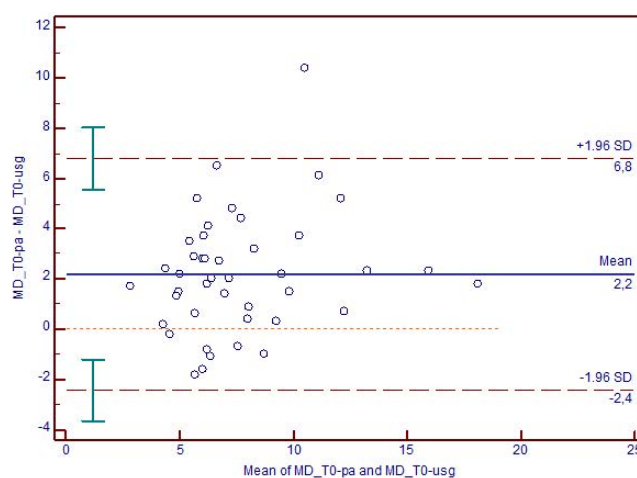
### Results

In the first stage of this study, pre-treatment USG examinations and post-treatment histopathological evaluations were done, and USG pre-diagnoses of cysts/granulomas were made before apical resection. The agreement of the USG and histopathological diagnoses was evaluated in patients in whom apical resection was indicated. Eight of the 10 cases (80%) had a USG pre-diagnosis a histopathological diagnosis of periapical cyst, indicating that the 2 methods were compatible. One case was pre-diagnosed as a periapical cyst on USG, while the histopathologic diagnosis was periapical granuloma. Another case was pre-diagnosed as periapical granuloma, while the histopathological diagnosis was a periapical cyst.

In the second stage of our study, the mean age of the

44 individuals (18 males and 26 females) was found to be 30.5 years. The age, sex, and localization distributions were even between the cyst and granuloma groups, and there was no statistically significant difference between the groups before and after root canal treatment.

In the USG findings in the periapical cyst group, there was a statistically significant decrease in the M-D and A-P measurements after treatment of the lesions. The median (min-max) values of the A-P size measurements, before and after treatment, were 7.95 mm (4.9-9.3 mm) and 4.05 mm (3.1-8 mm), respectively ( $P < 0.05$ ). The S-I measurements of the lesions decreased after treatment, but this re-



**Fig. 4.** Bland-Altman analysis of agreement of mesio-distal (MD) size measurements in periapical radiographic and ultrasonographic images.

**Table 1.** Pre- and post-treatment comparison of periapical cysts and granulomas on ultrasonographic images (mean and range, unit: mm)

Measurements	Periapical cysts (n = 8)		Periapical granulomas (n = 13)	
	Pre-treatment	Post-treatment	Pre-treatment	Post-treatment
Mesio-distal	8.15 (4.2-17.2)	3.7 (2.3-6.4)*	5.5 (3.2-14.8)	3.3 (1.7-7.6)*
Antero-posterior	7.95 (4.9-9.3)	4.05 (3.1-8.0)*	6.4 (3.3-9.8)	4.2 (2.3-9.0)*
Supero-inferior	6.65 (4.7-12.2)	3.45 (2.4-8.2)	5.2 (2.3-12.5)	3.4 (1.7-7.1)*

\*:  $P < 0.05$

**Table 2.** Pre- and post-treatment comparison of periapical cysts and granulomas on periapical radiographic images (mean and range, unit: mm)

Measurements	Periapical cysts (n = 8)		Periapical granulomas (n = 13)	
	Pre-treatment	Post-treatment	Pre-treatment	Post-treatment
Mesio-distal	8 (4.4 : 19)*	5.45 (3.3:11.6)*	8.13 ± 2.90*	5.34 ± 2.16*
Supero-inferior	9.38 ± 3.12*	6.11 ± 2.37*	9.80 ± 3.01*	6.06 ± 2.89*

\*:  $P < 0.05$

**Table 3.** Bland-Altman analysis of the agreement of mesio-distal and supero-inferior measurements on periapical and ultrasonographic images

	Mesio-distal	Supero-inferior
Number	44	44
Mean ± standard deviation	2.17 ± 2.36	3.60 ± 3.31
P value	<0.05	<0.05
Limits of agreement, number (%)	43 (98%)	42 (97%)

sult was not statistically significant ( $P > 0.05$ ) (Table 1).

In the USG findings in the periapical granuloma group, the M-D, A-P, and S-I measurements of the lesions showed statistically significant differences when comparing the pre- and post-treatment measurements. The median (min-max) values of the A-P measurements before and after treatment were 6.4 mm (3.3-9.8 mm) and 4.2 mm (2.3-9 mm), respectively ( $P < 0.05$ ) (Table 1).

When the pre- and post-treatment values of M-D and S-I measurements on periapical radiographs were compared in the cyst and granuloma groups, statistically significant differences were found ( $P < 0.05$ ). Similar decreases in size were observed in the cyst group and in the granuloma group after treatment (Table 2).

Bland-Altman concordance analyses were performed to compare the size measurements made by USG examinations with the size measurements using periapical radiographs, and to investigate the compatibility of the 2 techniques. Although there was no one-to-one agreement between the pre-treatment and post-treatment M-D and S-I measurements, consistent measurements (with agreement ranging from 97% to 100%) were obtained (Table 3, Fig. 4). The measurement data obtained to evaluate internal consistency were re-examined and recorded after 6 months. The results in terms of the ICC indicated a very high level of consistency ( $P < 0.05$ ).

### Discussion

Periapical lesions, which occur as a result of many physical, chemical, microbiological, and immunological irritants in the dental pulp stimulating the periapical region, are the most common pathological formation in the alveolar bone.<sup>10</sup> According to various epidemiological studies, apical periodontitis is a common disease that was reported to be observed in between 24.5% and 61% of the adult population.<sup>11</sup> Nobuhara and del Rio<sup>12</sup> stated that 59.3% of peri-radicular lesions were cases of chronic apical periodontitis (granulomas), 22% were cysts, 12% were apical

scars, and 6.7% were other pathologies. In the present study, the mean age of the groups was found to be 30.5 years, and there were no statistically significant differences between the groups in terms of age, sex, and lesion localization.

It has been stated that USG could differentiate between cystic and solid structures of jaw lesions and provide accurate information about the contents of intra-bony lesions in jaws prior to surgical intervention.<sup>13</sup> Firstly, Lauria et al.<sup>14</sup> reported positive findings related to the role of USG in the differential diagnosis of intra-bony lesions of the jaws. Studies on the differential diagnosis of apical granulomas and periapical cysts in teeth with periapical lesions using USG and the color Doppler technique have supported findings of high reliability, as confirmed by histopathologic diagnoses and conventional radiography.<sup>8,15,16</sup>

Raghav et al.<sup>1</sup> investigated the efficacy of conventional radiography, digital radiography, and USG in the diagnosis of lesions with periapical radiolucencies in the anterior teeth of the maxilla and mandible. Based on the histopathological examinations, the efficiency of conventional radiography was found to be 47.6%, that of digital radiography was 55.6%, and that of USG was 95.2%. In their study Cotti et al.<sup>7</sup> pre-diagnosed peri-radicular lesions of endodontic origin, and apical surgery was planned for these individuals. The results obtained in a study of histopathological sections were reported to be compatible with the preliminary diagnoses. In the first stage of the present study, using color and power Doppler USG techniques, 10 cases with apical lesions for which apical resection was indicated were evaluated pre-diagnosis, and the USG results were compared with the findings of the histopathological evaluation. Eight cases (80%) were diagnosed as cysts in the preliminary diagnosis and following the histopathological examination. The 20% discrepancy was attributed to the fact that USG is an operator-dependent technique, and the color Doppler USG could not detect very small vascularizations, the presence of dental landmarks in the region (e.g., roots), and inadequate thinning of the buccal cortical bone, making the passage of US waves difficult.

According to the literature, USG showed lesions in the jawbones that could cause thinning or perforation of the buccal cortical bone. USG is a useful imaging method in diagnosis and follow-up.<sup>5,7,13,14</sup> Some investigators have suggested that lesions could not be imaged in the absence of fenestration in the bone in the lesion area,<sup>8,9,17</sup> while many studies have reported that lesions can be imaged

with regard to the thinning of the cortical bone.<sup>18,19</sup> Adibi et al.<sup>18</sup> obtained 20 sections that mimicked bone thicknesses at different stages, and undertook USG imaging by creating artificial lesions with regard to the different sections. It was concluded that the capability of USG to detect intrabony lesions depends on the cortical bone thickness decreasing to  $\leq 1.1$  mm. In a similar study, Tikku et al. reported that lesions with a mean cortical bone thickness of less than 1.6 mm were correctly diagnosed by USG, but in diagnosing the lesions with a thicker cortical bone (greater than or equal to 1.6 mm), the diagnostic accuracy decreased to 65%.<sup>20</sup> In the present study, all 44 periapical lesions were able to be visualized on USG prior to treatment, but only 21 of them could be visualized after treatment due to shrinkage of the lesion in the periapical region and thickening of the buccal bone. This study revealed that USG was a useful technique for detecting and monitoring the healing of intra-bony lesions in case of thinning of bone or bone windows.

In the previous clinical studies, size measurements of peri-radicular lesions were compared with periapical radiographs and cone-beam computed tomographic (CBCT) images using USG.<sup>1,7,21-23</sup> Raghav et al.<sup>1</sup> stated that the M-D and S-I dimensions of the lesions were compared between measurements made using conventional and digital periapical radiographs or USG. They reported that the lesion dimensions measured using USG were smaller than those shown on conventional and digital radiographs. The reason for this was that the lesions caused acoustic shadowing of the lateral bone walls, and the measurement points could not be determined using the USG technique. Similar studies showed that the USG length measurements were smaller than length measurements obtained using periapical and CBCT images.<sup>5,24</sup> Sönmez et al.<sup>25</sup> obtained USG, periapical radiographs, and CBCT images before treatment and compared length measurements made using these 3 methods. They stated that there were no significant differences in all measurements, with the exception of the S-I measurement, and that these methods yielded compatible results in terms of dimension measurements. In our study, the M-D and S-I dimensions of the lesions measured on periapical radiographs and USG were consistent with each other, and this result was statistically significant. When all measurements were taken into consideration, the Bland-Altman analysis of the agreement between periapical radiograph and USG measurements demonstrated that there was no one-to-one agreement, but consistent measurements were obtained.

Some studies have used USG to evaluate periapical lesions; however, such an approach generally aimed to deter-

mine the characteristics and size of lesions<sup>7,21,26</sup> and there have been few studies on the follow-up of lesions with USG.<sup>6,19,25</sup>

In the studies where USG was used to perform follow-up of the healing of periapical lesions, the number of cases followed was very low compared to our study, and the lesions were not subjected to a preliminary diagnosis process. Sönmez et al.<sup>25</sup> argued that USG could be used as an imaging modality in endodontic treatment follow-up. Maity et al.<sup>19</sup> concluded that lesions on the anterior aspect of the jaws could be monitored by USG, and mentioned the need to develop better intraoral probes. Tikku et al.<sup>17</sup> reported that the best follow-up technique was color Doppler USG based on a comparison between color Doppler USG and periapical radiography.

Our study found that there was agreement with regard to the measurement of lesion sizes obtained from USG and periapical images, and this study revealed that USG could be used in follow-up examinations of lesion healing. With regard to pre-treatment measurements, the size of cysts noted in previous studies was larger than granulomas.<sup>27,28</sup> In light of the results obtained in this study, USG could be used to support periapical radiographs in the follow-up of teeth with periapical lesions. In addition, this study revealed that USG could be used as an alternative imaging method in pregnancy and for pediatric patients. There were statistically significant changes after treatment in terms of M-D, A-P, and S-I measurements in both the cyst and granuloma groups, with the exception of S-I measurements in the cyst group. Decreases in measured values and percentage changes were observed in all three variables.

Studies in the literature suggest that granulomas spontaneously heal after the elimination of causal factors, and that real apical cysts tend to be self-sustaining with respect to tissue dynamics when compared to apical pocket cysts and pocket cysts, which are more likely to heal as a result of non-surgical root canal treatment.<sup>29-31</sup> However, in our study, no statistically significant differences were found in the dimensional decreases in M-D, A-P and S-I measurements between the periapical cyst and granuloma study groups. According to the data obtained from the present study, overall size reduction was observed in all lesions, and in 26 patients, buccal bone thickness increased. When the follow-up periapical radiographs of these individuals were examined, it was noted that they all had significant shrinkage and the lack of bony defect findings on imaging was a sign of healing.

Options for the treatment of large periapical lesions

range from non-surgical root canal treatment, laser applications, and/or apical surgery to extraction.<sup>32,33</sup> Ramachandran Nair et al.<sup>31</sup> showed that between 85% and 90% of periapical lesions disappeared radiographically as a result of traditional root canal treatment, or a significant reduction in size was achieved. According to some reports on the presence and treatment of large, cyst-like periapical lesions, complete recovery could be achieved with root canal treatment combined with a local antibiotic, calcium hydroxide, and decompression.<sup>33</sup> Ricucci et al.<sup>34</sup> believed that apical true cysts should not be seen as a separate pathology from pocket cysts because both types of cysts are based on apical periodontitis lesions caused by root canal infection. In line with this view, Lin et al.<sup>2</sup> showed that the differentiation of these 2 cysts could not be understood before the initiation of root canal treatment (only magnetic resonance imaging has the capacity to differentiate pocket cysts from true cysts), implying that root canal treatment is appropriate for all cystic lesions. According to the data obtained in the present study, traditional root canal treatment involving adequate disinfection, appropriate treatment, and regular follow-up, regardless of size, yielded successful results without the need for surgical treatment in cases of large periapical lesions. For this purpose, traditional root canal treatment should be the first choice, instead of surgical procedures. In conclusion, USG showed a reasonable ability to differentiate between periapical cysts and granulomas, as the USG classification was compatible with the histopathological diagnosis in 80% of cases. In the cyst and granuloma groups, after root canal treatment, there was a reduction in lesion size. However, there were no statistically significant differences between the groups. USG and periapical radiographs were consistent in terms of dimensional comparisons. Follow-up of the healing periapical lesions could be performed by USG as long as buccal bone thickness permits, but follow-up could not be performed if bone thickness increases.

**Conflicts of Interest:** None

## References

1. Raghav N, Reddy SS, Giridhar AG, Murthy S, Yashodha Devi BK, Santana N, et al. Comparison of the efficacy of conventional radiography, digital radiography, and ultrasound in diagnosing periapical lesions. *Oral Surg Oral Med Oral Pathol Oral Radiol Endod* 2010; 110: 379-85.
2. Lin LM, Ricucci D, Lin J, Rosenberg PA. Nonsurgical root canal therapy of large cyst-like inflammatory periapical le-

- sions and inflammatory apical cysts. *J Endod* 2009; 35: 607-15.
3. Nair PN. New perspectives on radicular cysts: do they heal? *Int Endod J* 1998; 31: 155-60.
4. Musu D, Rossi-Fedele G, Campisi G, Cotti E. Ultrasonography in the diagnosis of bone lesions of the jaws: a systematic review. *Oral Surg Oral Med Oral Pathol Oral Radiol* 2016; 122: e19-29.
5. Shahidi S, Shakibafard A, Zamiri B, Mokhtare MR, Houshyar M, Mahdian S. The feasibility of ultrasonography in defining the size of jaw osseous lesions. *J Dent (Shiraz)* 2015; 16: 335-40.
6. Rajendran N, Sundaresan B. Efficacy of ultrasound and color power Doppler as a monitoring tool in the healing of endodontic periapical lesions. *J Endod* 2007; 33: 181-6.
7. Cotti E, Campisi G, Ambu R, Dettori C. Ultrasound real-time imaging in the differential diagnosis of periapical lesions. *Int Endod J* 2003; 36: 556-63.
8. Goel S, Nagendrareddy SG, Raju MS, Krishnoji Rao DR, Rastogi R, Mohan RP, et al. Ultrasonography with color Doppler and power Doppler in the diagnosis of periapical lesions. *Indian J Radiol Imaging* 2011; 21: 279-83.
9. Aggarwal V, Singla M. Use of computed tomography scans and ultrasound in differential diagnosis and evaluation of nonsurgical management of periapical lesions. *Oral Surg Oral Med Oral Pathol Oral Radiol Endod* 2010; 109: 917-23.
10. Torabinejad M, Fouad AF, Walton RE. *Endodontics: principles and practice*. St. Louis: Elsevier; 2015. p. 51-67.
11. Gulsahi A, Yüzügüllü B, Imirzalioglu P, Genç Y. Assessment of panoramic radiomorphometric indices in Turkish patients of different age groups, gender and dental status. *Dentomaxillofac Radiol* 2008; 37: 288-92.
12. Nobuhara WK, del Rio CE. Incidence of periradicular pathoses in endodontic treatment failures. *J Endod* 1993; 19: 315-8.
13. Ishii J, Nagasawa H, Wadamori T, Yamashiro M, Ishikawa H, Yamada T, et al. Ultrasonography in the diagnosis of palatal tumors. *Oral Surg Oral Med Oral Pathol Oral Radiol Endod* 1999; 87: 39-43.
14. Lauria L, Curi MM, Chammas MC, Pinto DS, Torloni H. Ultrasonography evaluation of bone lesions of the jaw. *Oral Surg Oral Med Oral Pathol Oral Radiol Endod* 1996; 82: 351-7.
15. Tiwari B, Krishnan M, Popli M, Iyer SR, Arora V. Ultrasonography and color Doppler in the differential diagnosis of periapical cyst and granuloma. *J Contemp Dent* 2014; 4: 17-21.
16. Sumer AP, Danaci M, Ozen Sandikçi E, Sumer M, Celenk P. Ultrasonography and Doppler ultrasonography in the evaluation of intraosseous lesions of the jaws. *Dentomaxillofac Radiol* 2009; 38: 23-7.
17. Tikku AP, Kumar S, Loomba K, Chandra A, Verma P, Aggarwal R. Use of ultrasound, color Doppler imaging and radiography to monitor periapical healing after endodontic surgery. *J Oral Sci* 2010; 52: 411-6.
18. Adibi S, Shakibafard A, Karimi Sarvestani Z, Saadat N, Khojastepour L. Effect of cortical bone thickness on detection of intraosseous lesions by ultrasonography. *Radiol Res Pract* 2015; 2015: 797593.
19. Maity I, Kumari A, Shukla AK, Usha H, Naveen D. Monitoring of healing by ultrasound with color power doppler after



- root canal treatment of maxillary anterior teeth with periapical lesions. *J Conserv Dent* 2011; 14: 252-7.
20. Tikku AP, Bharti R, Sharma N, Chandra A, Kumar A, Kumar S. Role of ultrasound and color doppler in diagnosis of periapical lesions of endodontic origin at varying bone thickness. *J Conserv Dent* 2016; 19: 147-51.
  21. Parvathy V, Kumar R, James EP, George S. Ultrasound imaging versus conventional histopathology in diagnosis of periapical lesions of endodontic origin: a comparative evaluation. *Indian J Dent Res* 2014; 25: 54-7.
  22. Cotti E, Campisi G, Garau V, Puddu G. A new technique for the study of periapical bone lesions: ultrasound real time imaging. *Int Endod J* 2002; 35: 148-52.
  23. Gundappa M, Ng SY, Whaites EJ. Comparison of ultrasound, digital and conventional radiography in differentiating periapical lesions. *Dentomaxillofac Radiol* 2006; 35: 326-33.
  24. Gad K, Ellabban M, Sciubba J. Utility of transfacial dental ultrasonography in evaluation of cystic jaw lesions. *J Ultrasound Med* 2018; 37: 635-44.
  25. Sönmez G, Kamburoğlu K, Yılmaz F, Koç C, Barış E, Tüzüner A. Versatility of high resolution ultrasonography in the assessment of granulomas and radicular cysts: a comparative in vivo study. *Dentomaxillofac Radiol* 2019; 48: 20190082.
  26. Prince CN, Annapurna CS, Sivaraj S, Ali IM. Ultrasound imaging in the diagnosis of periapical lesions. *J Pharm Bioallied Sci* 2012; 4 (Suppl 2): S369-72.
  27. Fernandes M, De Ataide I. Non-surgical management of a large periapical lesion using a simple aspiration technique: a case report. *Int Endod J* 2010; 43: 536-42.
  28. Özan Ü, Er K. Endodontic treatment of a large cyst-like paradicular lesion using a combination of antibiotic drugs: a case report. *J Endod* 2005; 31: 898-900.
  29. Çalışkan MK. Prognosis of large cyst-like periapical lesions following nonsurgical root canal treatment: a clinical review. *Int Endod J* 2004; 37: 408-16.
  30. Nair P, Sjögren U, Schumacher E, Sundqvist G. Radicular cyst affecting a root-filled human tooth: a long-term post-treatment follow-up. *Int Endod J* 1993; 26: 225-33.
  31. Ramachandran Nair PN, Pajarola G, Schroeder HE. Types and incidence of human periapical lesions obtained with extracted teeth. *Oral Surg Oral Med Oral Pathol Oral Radiol Endod* 1996; 81: 93-102.
  32. Soares JA, Brito-Júnior M, Silveira FF, Nunes E, Santos SM. Favorable response of an extensive periapical lesion to root canal treatment. *J Oral Sci* 2008; 50: 107-11.
  33. Franzen R, Gutknecht N, Falken S, Heussen N, Meister J. Bactericidal effect of a Nd: YAG laser on *Enterococcus faecalis* at pulse durations of 15 and 25 ms in dentine depths of 500 and 1,000 µm. *Lasers Med Sci* 2011; 26: 95-101.
  34. Ricucci D, Pascon EA, Ford TR, Langeland K. Epithelium and bacteria in periapical lesions. *Oral Surg Oral Med Oral Pathol Oral Radiol Endod* 2006; 101: 239-49.