










# Ectopic Adrenal Adenoma in Renal Sinus: A Case Report








## 신장의 이소성 부신 선종: 증례 보고

John Baek, MD<sup>1</sup> , See Hyung Kim, MD<sup>1\*</sup> , Seung Hyun Cho, MD<sup>2</sup> ,  
Won Hwa Kim, MD<sup>2</sup> , Hye Jung Kim, MD<sup>2</sup> ,  
Hun Kyu Ryeom, MD<sup>1</sup> , Ghilsuk Yoon, MD<sup>2†</sup> 

<sup>1</sup>Department of Radiology, School of Medicine, Kyungpook National University, Kyungpook National University Hospital, Daegu, Korea

<sup>2</sup>Department of Radiology, School of Medicine, Kyungpook National University, Kyungpook National University Chilgok Hospital, Daegu, Korea

### ORCID iDs

John Baek  <https://orcid.org/0000-0002-3249-2359>  
See Hyung Kim  <https://orcid.org/0000-0002-3268-3091>  
Seung Hyun Cho  <https://orcid.org/0000-0001-7617-7302>  
Won Hwa Kim  <https://orcid.org/0000-0001-7137-9968>  
Hye Jung Kim  <https://orcid.org/0000-0002-0263-0941>  
Hun Kyu Ryeom  <https://orcid.org/0000-0003-4327-8777>  
Ghilsuk Yoon  <https://orcid.org/0000-0002-9941-024X>

Received December 6, 2021

Revised February 7, 2022

Accepted March 8, 2022

### \*Corresponding author

See Hyung Kim, MD  
Department of Radiology,  
School of Medicine,  
Kyungpook National University,  
Kyungpook National University  
Hospital, 130 Dongdeok-ro,  
Jung-gu, Daegu 41944, Korea.

Tel 82-53-200-5390

Fax 82-53-422-2677

E-mail kimseehyung72@knu.ac.kr

This is an Open Access article distributed under the terms of the Creative Commons Attribution Non-Commercial License (<https://creativecommons.org/licenses/by-nc/4.0>) which permits unrestricted non-commercial use, distribution, and reproduction in any medium, provided the original work is properly cited.

<sup>†</sup>Department of Pathology,  
Kyungpook National University  
School of Medicine, Daegu, Korea.

The kidney is a rare site of ectopic adrenal adenoma. To the best of our knowledge, some cases of ectopic adrenal adenoma have been found in the kidney, but few of these cases explain the CT and MRI findings of the lesion. We reported a case of ectopic adrenal adenoma in the left renal sinus. A 47-year-old male patient underwent abdominal CT for routine health check-ups, which revealed a 1.2 cm enhancing mass in the left renal sinus. The MRI showed a signal drop of the mass in T1 weighted in- and opposed-phase, which indicates fat components. The mass was confirmed as an ectopic adrenal adenoma after surgery.

**Index terms** Kidney; Adrenal Glands; Adenoma; Computed Tomography, X-Ray; Magnetic Resonance Imaging

## INTRODUCTION

Ectopic adrenal tissue has been reported in various anatomical sites, including the celiac plexus, kidney, testis, epididymis, broad ligament, the canal of Nuck, hernial and hydrocele sacs, the mesoappendix, liver, lungs, intradural space and brain (1). Cortical tissue appears to be the only component of ectopic adrenal rests, as accompanying medullary tissue was not reported (2). Occasionally, ectopic rest undergoes marked proliferation and develops into ec-

topic adrenocortical adenomas and carcinomas (3-5). The clinical features of ectopic adrenocortical tumors depend on the hormone secretion status; thus, these tumors may be functional or nonfunctional. However, unlike their functional counterparts, nonfunctional ectopic adrenocortical tumors may go undetected because they are mostly asymptomatic (4).

The incidence of localized renal masses has been increasing, partly due to the increased use of abdominal imaging. The CT may show an intrarenal adenoma as a solid enhancing renal mass, leading to the presumptive diagnosis of renal cell carcinoma (5). Generally, such a case is not discovered as benign until pathologic analysis of the surgical specimen is conducted after partial or radical nephrectomy. On T1 weighted in- and opposed-phase MRI, a fat component assessment within the mass is possible. The biopsy of such a lesion poses important diagnostic challenges given both the possibility of an angiomyolipoma to simulate clear cell renal cell carcinoma and potentially interpret a sample of unexpected adenoma tissue as a nondiagnostic sample adjacent to a lesion (6).

Reported herein are CT and MRI findings of an ectopic adrenocortical adenoma located in the renal hilum, a rare site for this tumor occurrence, which can easily be misdiagnosed as renal angiomyolipoma.

## CASE REPORT

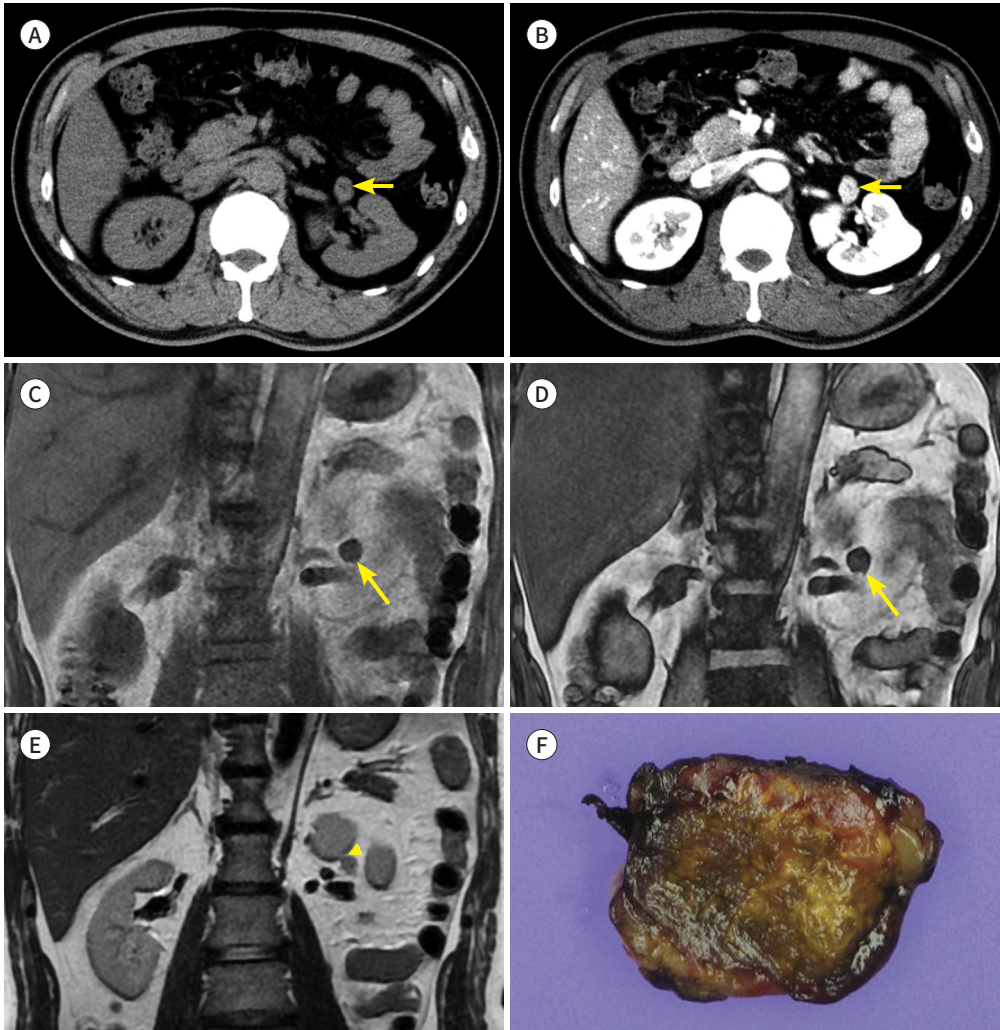
A 47-year-old male patient had abdominal CT during routine health check-up. No remarkable findings were found in the clinical history, physical examinations, or laboratory tests. The CT revealed a 12 mm well-defined round mass in the left renal sinus, abutting the left kidney. The mass showed mean density of 32 Hounsfield unit (HU) in the pre-contrast phase and heterogeneous enhancement (mean HU: 146) in the portal venous phase (Fig. 1A, B). The tentative diagnosis during the interpretation included renal cell carcinoma and angiomyolipoma with minimal fat. A kidney MRI was performed for further characterization of the mass. T2 weighted image showed mass with iso-signal intensity to the renal parenchyma. The in- and opposed-phase T1-weighted gradient images revealed a marked signal drop of the mass, which indicated fatty component within the mass (in-phase: 512, opposed-phase: 325, tumor to spleen ratio: 0.67, tumor signal intensity index: 36.5%) (Fig. 1C, D). A coronal multi-planar reformatted image depicted the mass separating from renal parenchyma (Fig. 1E). The mass showed a modest arterial enhancement in the arterial phase and washout in the delayed and equilibrium (3 minutes) phases. The diffusion-weighted image showed high signal intensity, and the apparent diffusion coefficient value was  $0.8 \times 10^{-3} \text{ mm}^2/\text{s}$ . These findings indicate the possibility of fat-poor angiomyolipoma.

The patient underwent robot-assisted laparoscopic partial nephrectomy of the left kidney. During the operation, an exophytic mass was found near the mid-kidney anteromedial aspect of the left kidney. The mass was originating from the renal sinus fat, and it was located in between kidney lobulation. The mass was not connected to the kidney. The mass in the renal sinus was completely resected.

On gross examination, the mass was yellow to brown in color and was a 17 mm  $\times$  15 mm oval with soft margins and a medium texture. The microscopic exam revealed tumor cells that were rich in cytoplasm and eosinophilic and numerous sinusoid capillaries. The cytoplasm

**Fig. 1.** Ectopic adrenal adenoma arising from renal sinus in a 47-year-old male.

- A.** An unenhanced CT image shows a low-density mass in the left renal sinus (arrow).  
**B.** The mass shows heterogeneous enhancement on portal venous phase image (arrow).  
**C, D.** On in-phase (**C**) and opposed-phase (**D**) T1-weighted gradient-echo MR images, the mass shows a marked signal drop, suggesting abundant fatty component (arrows).  
**E.** Coronal T2-weighted image shows separation of the mass and the kidney by the clear border (arrowhead).  
**F.** Gross specimen shows a 17 mm × 15 mm yellow to brown mass that contains renal sinus fat and is separated from the left kidney.



contained melanin, which was confirmed by decolorization. The tumor cells were arranged in cords or goblets with a low ratio of nucleus to cytoplasm, and rare mitotic figures. The immunohistochemical staining of the mass showed positive for vimentin, synaptophysin, CD56, and chromogranin. The pathologic diagnosis was of an ectopic adrenocortical adenoma in the renal sinus. The patient is alive with no tumor recurrence after 12 months of follow-up.

This study was approved by the Institutional Review Board of our hospital and the requirement for informed consent was waived (IRB No. KNUCH 2022-03-016).

## DISCUSSION

Adrenocortical primordium is formed by the invagination of the coelomic epithelium, adjacent to the region where the gonadal blastema arises, on approximately day 30 of gestation (7). During gonadal migration, fragments of adrenocortical tissue may be scattered along the descending pathway and form ectopic adrenal glands. Most of these ectopic adrenal tissues settle in the vicinity of the adrenal gland or along its migratory course. Ectopic adrenal adenoma can arise from these ectopic adrenal rests, albeit very rarely, and may mimic tumors in other organs (8). Radiologists should be aware of this potential occurrence to avoid unnecessary surgery. Our reported case is a rare case of ectopic adrenal adenoma in the renal hilum (4, 6).

An adrenal cortical adenoma is the most common benign neoplasm in the adrenal gland and treatment is usually not necessary unless it is symptomatic. Approximately 80% of adrenal adenomas measures less than 10 HU on a non-contrast CT and can be easily diagnosed as a lipid-rich adenoma without other dedicated examinations. Adrenal adenoma has little or no fatty component, also known as a lipid-poor adenoma; however, it is differentiated from non-adenoma lesions through the calculation of the percentage enhancement washout with high sensitivity and specificity (9). In our case, the patient underwent the single protocol CT, which contains pre-contrast and portal venous phases. Therefore, we could not calculate the washout rate of the tumor. Chemical shift imaging is the reliable technique for diagnosing adrenal adenoma. In- and opposed-phase T1-weighted-gradient image signal drop of more than 16.5% is diagnostic of adrenal adenoma (10). In our case, the mass showed iso signal intensity to renal parenchyma in T2-weighted image and signal drop of 36.5% in in-and opposed-phase MR image. Therefore, fat-containing renal origin pathologies such as angiomyolipoma or clear cell renal cell carcinoma could not be ruled out. However, the tumor separately abutted the left kidney on both the radiologic examination and the operative field. Both gross and microscopic examination revealed that the tumor was well encapsulated and completely separated by the renal parenchyma, which confirm its pure ectopic location. It is difficult to make the correct preoperative diagnosis of adenoma originating from an ectopic adrenal tissue. But correct preoperative diagnosis would have been possible if the location outside the renal parenchyma had been interpreted as more important finding.

In conclusion, our case provides a reminder to radiologists to be aware of atypical ectopic adrenal adenoma and to include an ectopic adrenal lesion in the differential diagnosis of tumors that involve the renal hilum.

### Author Contributions

Conceptualization, all authors; investigation, B.J., K.S.H.; project administration, B.J., K.S.H.; resources, B.J., K.S.H.; supervision, K.S.H.; visualization, B.J., K.S.H.; writing—original draft, B.J., K.S.H.; and writing—review & editing, B.J., K.S.H.

### Conflicts of Interest

The authors have no potential conflicts of interest to disclose.

### Funding

None

## REFERENCES

1. Liu Y, Jiang YF, Wang YL, Cao HY, Wang L, Xu HT, et al. Ectopic adrenocortical adenoma in the renal hilum: a case report and literature review. *Diagn Pathol* 2016;11:40
2. Tong A, Jia A, Yan S, Zhang Y, Xie Y, Liu G. Ectopic cortisol-producing adrenocortical adenoma in the renal hilum: histopathological features and steroidogenic enzyme profile. *Int J Clin Exp Pathol* 2014;7:4415-4421
3. Wang XL, Dou JT, Gao JP, Zhong WW, Jin D, Hui L, et al. Laparoscope resection of ectopic corticosteroid-secreting adrenal adenoma. *Neuro Endocrinol Lett* 2012;33:265-267
4. Zhang J, Liu B, Song N, Lv Q, Wang Z, Gu M. An ectopic adreocortical adenoma of the renal sinus: a case report and literature review. *BMC Urol* 2016;16:3
5. Ayala AR, Basaria S, Udelsman R, Westra WH, Wand GS. Corticotropin-independent Cushing's syndrome caused by an ectopic adrenal adenoma. *J Clin Endocrinol Metab* 2000;85:2903-2906
6. Sappal S, Sulek J, Smith SC, Hampton LJ. Intrarenal adrenocortical adenoma treated by robotic partial nephrectomy with adrenalectomy. *J Endourol Case Rep* 2016;2:41-43
7. Neville AM, O'Hare MJ. Chapter 3, Origin and development of the adrenal gland. In Neville AM, O'Hare MJ, eds. *The human adrenal cortex*. London: Springer 1982:11-15
8. Yoon JH, Kim SH, Kim MA, Han JK, Choi BI. MDCT and Gd-EOB-DTPA enhanced MRI findings of adrenal adenoma arising from an ectopic adrenal gland within the liver: radiologic-pathologic correlation. *Korean J Radiol* 2010;11:126-130
9. Ren PT, Fu H, He XW. Ectopic adrenal cortical adenoma in the gastric wall: case report. *World J Gastroenterol* 2013;19:778-780
10. Shetty AS, Sipe AL, Zulfiqar M, Tsai R, Raptis DA, Raptis CA, et al. In-phase and opposed-phase imaging: applications of chemical shift and magnetic susceptibility in the chest and abdomen. *Radiographics* 2019;39:115-135

## 신장의 이소성 부신 선종: 증례 보고

백요한<sup>1</sup> · 김시형<sup>1\*</sup> · 조승현<sup>2</sup> · 김원화<sup>2</sup> · 김혜정<sup>2</sup> · 염현규<sup>1</sup> · 윤길숙<sup>2</sup>

신장은 이소성 부신 선종의 드문 부위이다. 우리가 아는 한, 신장에서 발생한 이소성 부신 선종의 일부 증례가 보고되었지만, 이러한 증례들 중 병변의 컴퓨터단층촬영 및 자기공명영상 소견을 설명하는 경우는 거의 없다. 47세 남자 환자가 정기 건강검진을 위해 복부 컴퓨터단층촬영을 시행한 결과 왼쪽 신장동에 1.2 cm 크기의 조영 증강이 되는 종괴가 발견되었다. 추가적으로 시행한 자기공명영상에서 지방 성분을 의미하는 신호 강하 소견을 보였다. 종괴는 수술 후 이소성 부신 선종으로 확인되었다.

<sup>1</sup>경북대학교 의과대학 경북대학교병원 영상의학과,

<sup>2</sup>경북대학교 의과대학 칠곡경북대학교병원 영상의학과