



A Primary Neuroendocrine Tumor Mimicking a Thrombus in the Left Atrial Appendage

좌심방이에서 발생한 혈전을 모방한 심장의 일차성 신경 내분비 종양

Myoung Kyoung Kim, MD¹ , Sung Mok Kim, MD^{1,2*} ,
Eun Kyoung Kim, MD^{2,3} , Dong Seop Jeong, MD⁴ ,
Yeon Hyeon Choe, MD^{1,2}

Departments of ¹Radiology and ⁴Thoracic and Cardiovascular Surgery, Samsung Medical Center, Sungkyunkwan University School of Medicine, Seoul, Korea

²Imaging Center, Heart Vascular Stroke Institute, Samsung Medical Center, Sungkyunkwan University School of Medicine, Seoul, Korea

³Division of Cardiology, Department of Medicine, Samsung Medical Center, Sungkyunkwan University School of Medicine, Seoul, Korea

Most cardiac tumors are metastases, and primary cardiac tumors are rare; even among primary cardiac tumors, primary cardiac neuroendocrine tumors (NETs) are extremely rare. Herein, we report a case of a patient presenting a left atrial mass without past medical history. Because of the location and movement of the mass, as well as the patient's cerebral infarction episode, the mass was initially suspected to be a thrombus. However, the mass was surgically diagnosed as NET.

Index terms Neuroendocrine Tumor; Heart Neoplasm; Heart Atria

INTRODUCTION

Cardiac tumors are relatively rare and can either be primary or metastatic, with metastatic tumors being more common than primary tumors. Sarcomas are the most common primary cardiac tumors, followed by lymphoma and pericardial mesothelioma (1). In particular, primary cardiac neuroendocrine tumors (NETs) are extremely rare. NETs of the heart are usually observed as metastases from gastrointestinal or pulmonary tumors. Here, we report the case of a patient with primary NET mimicking a thrombus in the left atrial appendage (LAA).

Received January 11, 2021

Revised March 24, 2021

Accepted June 4, 2021

*Corresponding author

Sung Mok Kim, MD
Department of Radiology,
Imaging Center,
Heart Vascular Stroke Institute,
Samsung Medical Center,
Sungkyunkwan University
School of Medicine, 81 Irwon-ro,
Gangnam-gu, Seoul 06351, Korea.

Tel 82-2-3410-2548

Fax 82-2-3410-2559

E-mail sungmok_kim@hanmail.net

This is an Open Access article distributed under the terms of the Creative Commons Attribution Non-Commercial License (<https://creativecommons.org/licenses/by-nc/4.0>) which permits unrestricted non-commercial use, distribution, and reproduction in any medium, provided the original work is properly cited.

ORCID iDs

Myoung Kyoung Kim
[https://
orcid.org/0000-0001-9228-022X](https://orcid.org/0000-0001-9228-022X)
Sung Mok Kim
[https://
orcid.org/0000-0001-5190-2328](https://orcid.org/0000-0001-5190-2328)
Eun Kyoung Kim
[https://
orcid.org/0000-0002-7653-3503](https://orcid.org/0000-0002-7653-3503)
Dong Seop Jeong
[https://
orcid.org/0000-0002-6947-8403](https://orcid.org/0000-0002-6947-8403)
Yeon Hyeon Choe
[https://
orcid.org/0000-0002-9983-048X](https://orcid.org/0000-0002-9983-048X)

CASE REPORT

A 55-year-old female patient with a history of thyroid cancer successfully treated 6 years earlier with surgery presented to the emergency department with recurrent diarrhea and nausea. The patient had received symptomatic treatment for diarrhea, which was ineffective, and she began to complain of dyspnea. Echocardiography revealed an impending cardiac tamponade and a mobile mass suspected to be a thrombus in the LAA. In addition, pericardiocentesis showed exudate effusion without any higher atypical cells. Anticoagulation with enoxaparin was initially provided, and the patient's dyspnea improved. However, a week later, she returned to the emergency room due to dysarthria and right arm weakness. Brain MRI showed multiple embolic infarctions in the bilateral cerebral hemispheres. She was transferred to our hospital for further management. Transesophageal echocardiography showed an irregularly shaped echogenic mass which occupied the LAA and protruded into the left atrium (Fig 1A, Supplementary Video 1 in the online-only Data Supplement). Left atrial enlargement with paroxysmal atrial fibrillation was also observed. CT scans were performed using a 128-slice DSCT system (SOMATOM Definition Flash, Siemens Medical Solution, Forchheim, Germany). CT imaging protocol consisted of arterial phase for coronary evaluation using retrospective electrocardiography (ECG)-gated helical mode and delayed phase obtained 3 minutes later for thrombus evaluation using prospective ECG-gated sequence mode. Cardiac CT demonstrated a 3 cm-sized low-attenuated lesion in the LAA, which had a contour of a bulging mass with lobulated margin. On delayed enhancement images, the mass showed heterogeneous enhancement with 43.4 Hounsfield units (HU) (16 HU on precontrast scan) in the space-occupying lesion of the LAA and 88.7 HU (25 HU on precontrast scan) in the protruding part of the left atrium (Fig. 1B). Because the patient had experienced multiple cerebral infarctions and a mobile LAA thrombus was suspected, the lesion was surgically removed as the mobile LAA thrombus was likely to cause recurrent systemic embolism. Histopathology demonstrated a malignant neoplasm with neuroendocrine differentiation. Immunohistological analysis revealed diffuse positivity for neuroendocrine markers such as synaptophysin, CD56, anti-cytokeratin (AE1/AE3), and vimentin, as well as negative staining for melanoma markers, HMB45, and chromogranin. Despite further investigations (CT-chest/abdomen/pelvis, PET/CT), no other lesion was found. Based on the absence of other lesions, the suspicion of a primary lesion, and the immunohistochemical pattern, the NET of the heart was diagnosed as a primary tumor.

After surgery, the patient refused palliative chemotherapy, and two months later, she was hospitalized for a newly emergent embolic cerebral infarction. ECG-gated cardiac CT showed several low-density lesions in the left ventricular myocardium, and the possibility of metastasis was considered. The patient underwent chemotherapy once with carboplatin and etoposide. However, she was discharged after stopping chemotherapy due to repeated ventricular tachycardia and cardiac arrest episodes, and died 6 months after her first hospital visit.

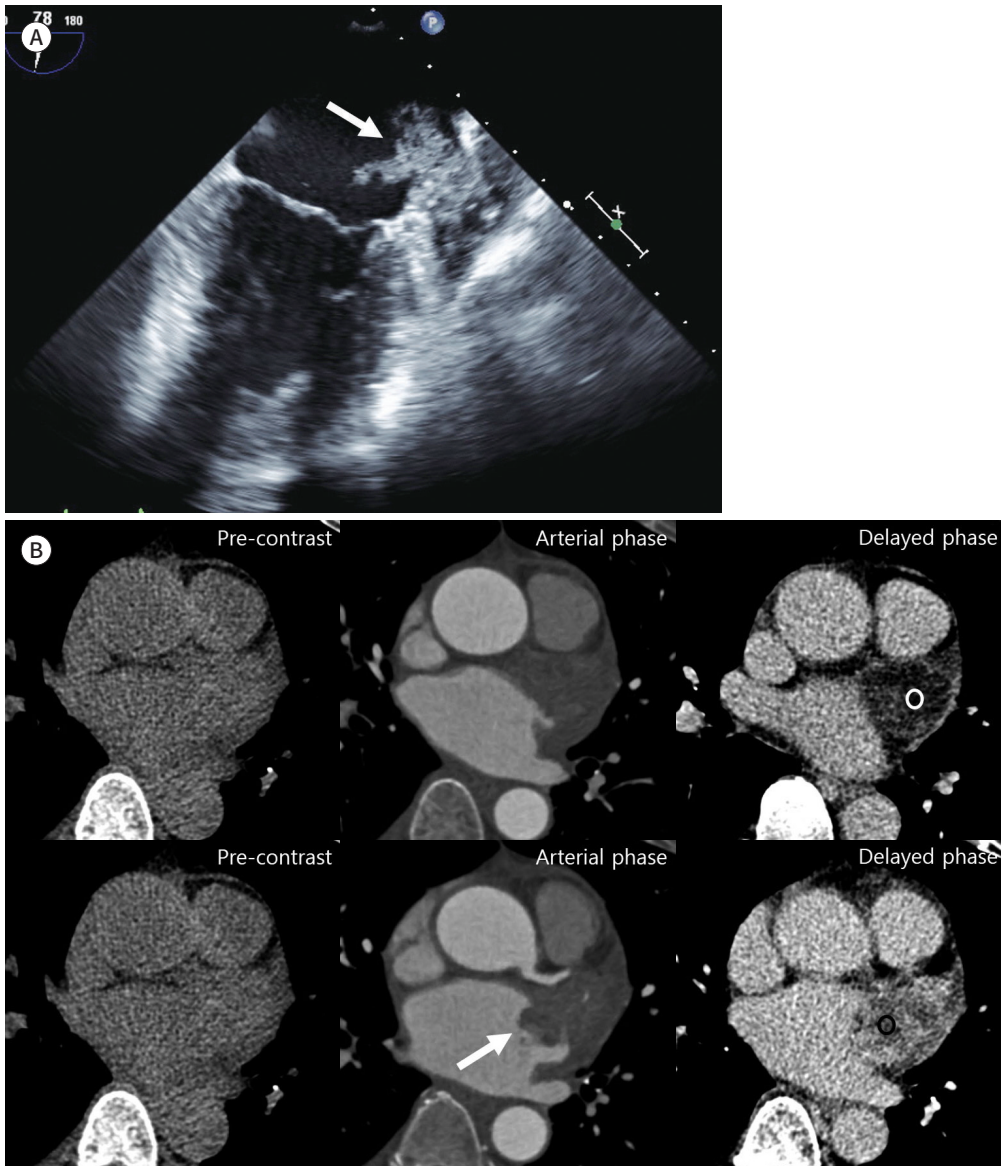
This retrospective study was approved by the Institutional Review Board of our hospital, and the requirement for informed consent was waived (IRB No. 2021-01-056).

Fig. 1. A primary neuroendocrine tumor mimicking a thrombus in the LAA in a 55-year-old female.

A. Transesophageal echocardiography shows an irregularly shaped echogenic mass occupying the LAA and protruding into the left atrium. Highly mobile thread-like materials are observed on the surface of the mass, including the head of Medusa (arrow).

B. Cardiac CT demonstrates a 3 cm-sized low-attenuated lesion in the LAA, which shows a bulging contour with a lobulated margin (arrow). On delayed enhancement images, the mass shows slightly heterogeneous enhancement with 43.4 HU in the occupied lesion of the LAA (white circle) and 88.7 HU in the protruding part of the left atrium (black circle).

HU = Hounsfield units, LAA = left atrial appendage



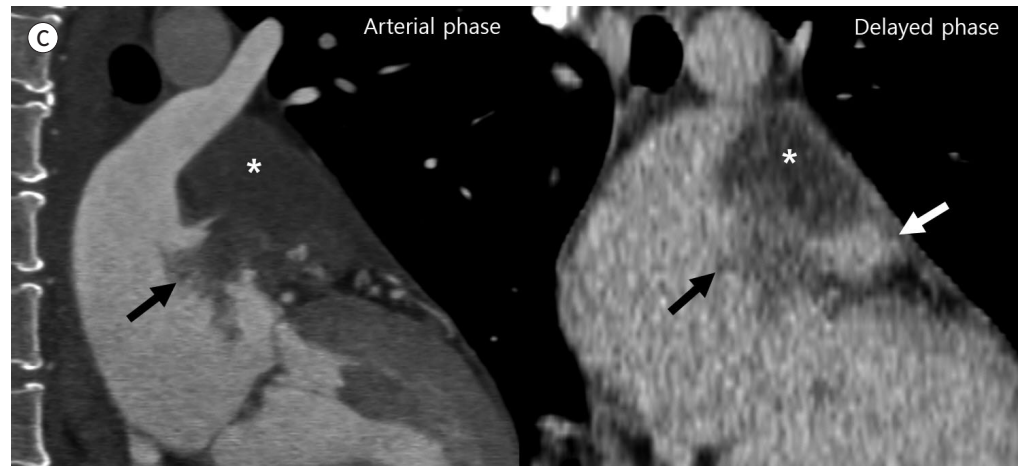DISCUSSION

NETs originate from nerve and endocrine cells. They are malignancies that are found in the gastrointestinal tract, lungs, pancreas, ovaries, and other organs. The clinical symptoms are non-specific and may vary by organ. NETs may also cause symptoms of carcinoid syndrome,

Fig. 1. A primary neuroendocrine tumor mimicking a thrombus in the LAA in a 55-year-old female.

C. The epicenter of the low-attenuated mass involving LAA appears to be located above the LAA (asterisks), and the extended mass protrudes into the left atrium (black arrows). The distal portion of the LAA (white arrow) is not invaded by the mass on the delayed phase image.

LAA = left atrial appendage



such as skin flushing, diarrhea, bronchospasm, and cardiac valve fibrosis by secreting several amines and polypeptide hormones (2). Cardiac NETs are very rare and are usually metastatic when present. Only in a few primary cardiac NET cases have been reported in literature (3-5). The masses have an exophytic oval shape with limited movement and were distributed in the right and left ventricle walls, right atrium, right coronary cusp of the aortic valve, and epicardium. No cases of a mobile LAA mass have been reported. Diagnosis of cardiac NETs using echocardiography, cardiac CT, or MRI is challenging, and histopathological confirmation is required for a definite diagnosis. This is due to the lack of established radiologic features to distinguish the NET from other primary cardiac tumors or metastatic tumors.

When a cardiac mass is detected on imaging modalities, the first approach in diagnosis is to differentiate between tumor and thrombus, as was done in our case. In a previous study comparing imaging features of myxomas and thrombi, there is no significant difference regarding CT attenuation between two diseases (43 ± 14 HU vs. 57 ± 30 HU; $p = 0.23$) (6). In addition, old thrombi appear heterogeneous with peripheral enhancement due to the formation of fibrous capsules (7). In this regard, it is difficult to distinguish between old blood clots and tumors. However, there are some discrimination points. Scheffel et al. (6) demonstrated that mean attenuation of myxomas were significantly larger than that of thrombi (33 ± 16 mm vs. 21 ± 7 mm; $p < 0.05$). The origin, shape, and mobility differed significantly between the lesions (all $ps < 0.05$). In their results, thrombi originated in the LAA (54.5%) and posterior or lateral wall (45.5%) of the left atrium. All thrombi had a polypoid shape. The frequency of mobility was 92.3% for myxomas and 36.4% for thrombi.

After the pathologic confirmation, we found that the epicenter of the lesion seem to have been above the LAA, and there was no tumor invasion in the distal portion of the LAA on two-chamber delayed enhancement images which were reconstructed additionally (Fig. 1C). These finding suggest that this lesion is a tumor rather than a thrombus, because if it were a thrombus, the epicenter of the lesion would be in the LAA. In previously published studies of

malignant cardiac tumors, Hoffmann et al. (8) reported a location of the tumor outside the left heart, tissue inhomogeneity, and contrast enhancement were highly sensitive markers for malignancy. Araoz et al. (9) showed infiltrative growth and lobulated margins were associated with malignancy. There is no systemically organized research on the cardiac NET. However considering previous imaging studies on cardiac tumors, the findings such as epicenter (location), heterogeneous enhancement, and lobulated margin of the lesion could be helpful in diagnosing our case as tumor rather than thrombus.

Generally, management of neuroendocrine carcinoma tumors (NECs) consists of surgical resection and chemotherapy (platinum). For colon high grade NEC, which has a similar histology to NETs, the median survival is 13 months, and the overall prognosis is poor (10). Similarly, our patient died 6 months after her first hospital visit.

Herein, we reported a primary cardiac NET mimicking an LAA thrombus. A malignant tumor involving the LAA is rare; nevertheless, we must try to differentiate tumors from thrombi by considering the epicenter, degree of contrast enhancement, and the shape of the margin. We expect that our case report will assist in identifying these lesions and further help in setting the appropriate treatment direction.

Supplementary Video Legend

Video 1. xPlane imaging of transesophageal echocardiography.

Supplementary Materials

The online-only Data Supplement is available with this article at <http://dx.doi.org/10.3348/jksr.2021.0008>.

Author Contributions

Investigation, K.M.K., K.S.M.; writing—original draft, K.M.K., K.S.M.; and writing—review & editing, all authors.

Conflicts of Interest

The authors have no potential conflicts of interest to disclose.

Funding

None

REFERENCES

1. Bruce CJ. Cardiac tumours: diagnosis and management. *Heart* 2011;97:151-160
2. Hofland J, Zandee WT, de Herder WW. Role of biomarker tests for diagnosis of neuroendocrine tumours. *Nat Rev Endocrinol* 2018;14:656-669
3. Li C, Huang J, Yang X, Xia J, Xu G, Zheng H. A primary neuroendocrine tumor of the left ventricle presenting with diarrhea—an unusual experience and literature review. *Diagn Pathol* 2020;15:32
4. Wißt T, Jehn CF, Vierbuchen M, Starekova J. Solitary neuroendocrine carcinoma of the heart: a case report. *Eur Heart J Case Rep* 2018;2:ty096
5. Naqvi SY, Henry D, Furukawa S, Haber H. Primary neuroendocrine tumour of the right ventricle presenting with heart failure and cyanosis. *BMJ Case Rep* 2016;2016:bcr2016214810
6. Scheffel H, Baummueller S, Stolzmann P, Leschka S, Plass A, Alkadhi H, et al. Atrial myxomas and thrombi: comparison of imaging features on CT. *AJR Am J Roentgenol* 2009;192:639-645
7. Slonimsky E, Konen O, Di Segni E, Konen E, Goitein O. Cardiac MRI: a useful tool for differentiating cardiac thrombi from tumors. *Isr Med Assoc J* 2018;20:472-475
8. Hoffmann U, Globits S, Schima W, Loewe C, Puig S, Oberhuber G, et al. Usefulness of magnetic resonance

imaging of cardiac and paracardiac masses. *Am J Cardiol* 2003;92:890-895

9. Araoz PA, Eklund HE, Welch TJ, Breen JF. CT and MR imaging of primary cardiac malignancies. *Radiographics* 1999;19:1421-1434
10. Smith JD, Reidy DL, Goodman KA, Shia J, Nash GM. A retrospective review of 126 high-grade neuroendocrine carcinomas of the colon and rectum. *Ann Surg Oncol* 2014;21:2956-2962

좌심방이에서 발생한 혈전을 모방한 심장의 일차성 신경 내분비 종양

김명경¹ · 김성목^{1,2*} · 김은경^{2,3} · 정동섭⁴ · 최연현^{1,2}

심장에서 발생하는 종양의 대부분은 원격 전이이며 일차성 심장 종양은 드물다. 그중에서도 심장의 일차성 신경내분비 종양은 더 드물게 보고되고 있다. 우리는 기저질환이 없는 환자에서 발생한 좌심방이 종괴에 대해 보고하고자 한다. 종괴의 위치, 초음파에서의 움직임, 환자의 뇌경색 발생으로 혈전을 의심하였다. 그 후 종괴에 대한 수술적 절제를 시행하였고, 신경내분비 종양으로 진단받았다.

성균관대학교 의과대학 삼성서울병원 ¹영상의학과, ²이미징센터, ³순환기내과, ⁴흉부외과