



Chest CT Imaging Features of the Pulmonary Sequelae in Four Patients with COVID-19

COVID-19 환자의 네 증례에서 폐 후유증에 대한 흉부 CT 소견

Tae-Eun Kim, MD , Su Young Kim, MD* , Byung Hoon Lee, MD

Department of Radiology, Ilsan Paik Hospital, Inje University College of Medicine, Goyang, Korea

With the ongoing coronavirus disease 2019 (COVID-19) pandemic, there is an increasing interest in the sequelae and care in recovered patients. Although the long-term sequelae of COVID-19 are still unknown, recently published reports suggest that some of the patients have persistent symptoms and show radiologic abnormalities after discharge. Herein, we present cases of four patients with previous COVID-19 infection manifesting pulmonary sequelae, including pulmonary fibrosis or organizing pneumonia pattern with persistent dyspnea after recovery.

Index terms COVID-19; SARS-CoV-2; Computed Tomography, X-Ray; Cryptogenic Organizing Pneumonia; Pulmonary Fibrosis

INTRODUCTION

Since December 2019, coronavirus disease 2019 (COVID-19) pneumonia caused by severe acute respiratory syndrome coronavirus 2 (SARS-CoV-2), rapidly spread throughout the world (1). The typical features of chest CT findings of COVID-19 are known as bilateral, mainly peripherally located ground glass opacities (GGO) with or without consolidation (1). There are a lot of interests in not only radiologic findings during COVID-19 clinical course, but also follow-up CT findings in recovered patients due to pulmonary sequelae. Herein we report the serial chest CT findings of pulmonary sequelae, presenting pulmonary fibrosis (PF) or organizing pneumonia (OP) pattern, in 4 patients with COVID-19 pneumonia.

CASE REPORT

In all four cases, the patients had a positive real-time reverse transcription polymerase chain reaction (RT-PCR) for SARS-CoV-2 on the day of admission. All patients were dis-

Received April 9, 2021
Revised July 2, 2021
Accepted August 10, 2021

*Corresponding author
Su Young Kim, MD
Department of Radiology,
Ilsan Paik Hospital,
Inje University
College of Medicine,
170 Juhwa-ro, Ilsanseo-gu,
Goyang 10380, Korea.

Tel 82-31-910-7389
Fax 82-31-910-7369
E-mail sykim@paik.ac.kr

This is an Open Access article distributed under the terms of the Creative Commons Attribution Non-Commercial License (<https://creativecommons.org/licenses/by-nc/4.0>) which permits unrestricted non-commercial use, distribution, and reproduction in any medium, provided the original work is properly cited.

ORCID iDs

Tae-Eun Kim
<https://orcid.org/0000-0002-9221-0325>
Su Young Kim
<https://orcid.org/0000-0002-1824-0008>
Byung Hoon Lee
<https://orcid.org/0000-0003-4481-7859>

charged after clinical recovery and two consecutive negative results for SARS-CoV-2. But all patients complained persistent dyspnea after discharge. The overall clinical assessment of 4 patients are summarized in Table 1.

CASE 1

A 66-year-old male with an unremarkable prior medical history. On admission, a chest radiography (CXR) showed subpleural consolidation in lower zone of right lung and multifocal peribronchial GGO in both lungs (Fig. 1A). He was discharged on hospital day 14, but two weeks later, he visited our hospital with symptoms of shortness of breath. Pulmonary function test showed restrictive ventilatory defect and reduced diffusion capacity for carbon monoxide (DLCO). Follow-up CXR (at 29 days after the admission day) showed multifocal peripheral reticulonodular opacities in both lungs (Fig. 1B). Chest CT revealed bilateral GGO, reticulation, parenchymal bands and bronchial dilatation in both lower and peripheral lungs (Fig. 1C, D). These findings were suggestive of post-inflammatory pulmonary fibrotic like change.

CASE 2

A 72-year-old male had a history of congestive heart failure and angina. Initial CXR showed diffuse airspace consolidations in both lungs (Fig. 2A). He was discharged a month

Table 1. Overall Clinical Assessment of 4 Patients with COVID-19

Patient Number	1	2	3	4
Age, years/sex	66/M	72/M	56/M	75/M
Hospitalization period	14 days	1 month	23 days	14 days
Initial CXR findings	Subpleural consolidation in lower zone of right lung and multifocal peribronchial GGO in both lungs	Diffuse airspace consolidations in both lungs	Bilateral dense peripheral consolidations in mid and lower zones of both lungs	Not provided
Days from admission to follow-up CT	29	79	23	47
Follow-up CT findings	Bilateral GGO, reticulation, parenchymal bands and bronchial dilatation in both lower and peripheral lungs	Subpleural GGO, reticulation, ILS thickening and traction BE in both lungs	Patchy GGO and mixed consolidations distributed peripherally in the both lungs and shows crazy paving pattern	Multifocal patchy GGO and mixed consolidations with peripheral dominance in both lungs
Pulmonary function test*				
FVC (L)/FVC (% predicted)	2.54/65	2.85/77	3.19/63	Not provided
FEV1 (L)/FEV1 (% predicted)	1.93/71	2.33/94	2.73/76	Not provided
FEV1/FVC (%)	76	82	86	Not provided
DLCO (mL/mm Hg/min)/DLCO (% predicted)	9.7/53	8.9/54	18.2/71	Not provided

*At the same time of follow-up CT.

BE = bronchiectasis, COVID-19 = coronavirus disease 2019, CXR = chest radiography, DLCO = diffusion capacity for carbon monoxide, FEV1 = forced expiratory volume in the first second, FVC = forced vital capacity, GGO = ground glass opacities, ILS = interlobular septal

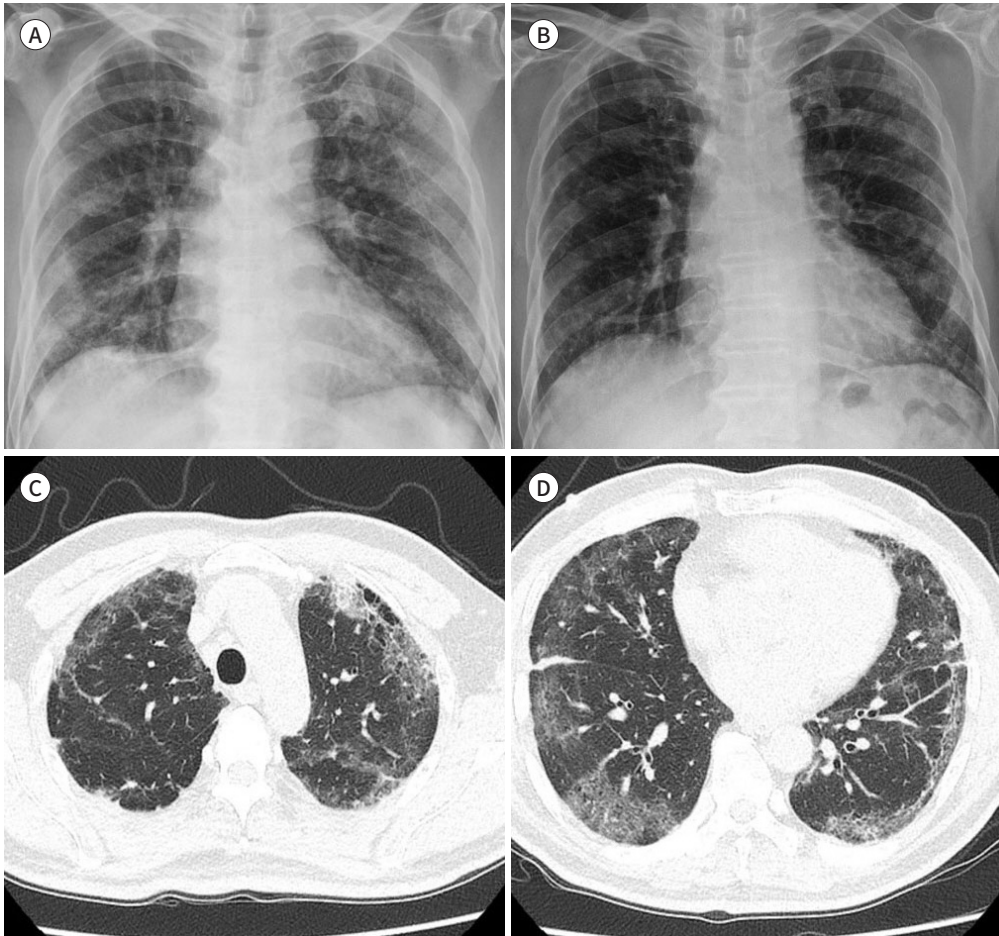
Fig. 1. Imaging features in case 1.

A. Initial chest PA shows subpleural consolidation in lower zone of the right lung and multifocal peribronchial GGO in both the lungs.

B. On follow-up chest PA (at 29 days after the admission day), multifocal peripheral reticulonodular opacities are noted in both the lungs.

C, D. Follow-up chest CT (at 29 days after the admission day) reveals bilateral GGO, reticulation, parenchymal bands, and bronchial dilatation in both lower and peripheral lungs.

GGO = ground glass opacities, PA = posteroanterior



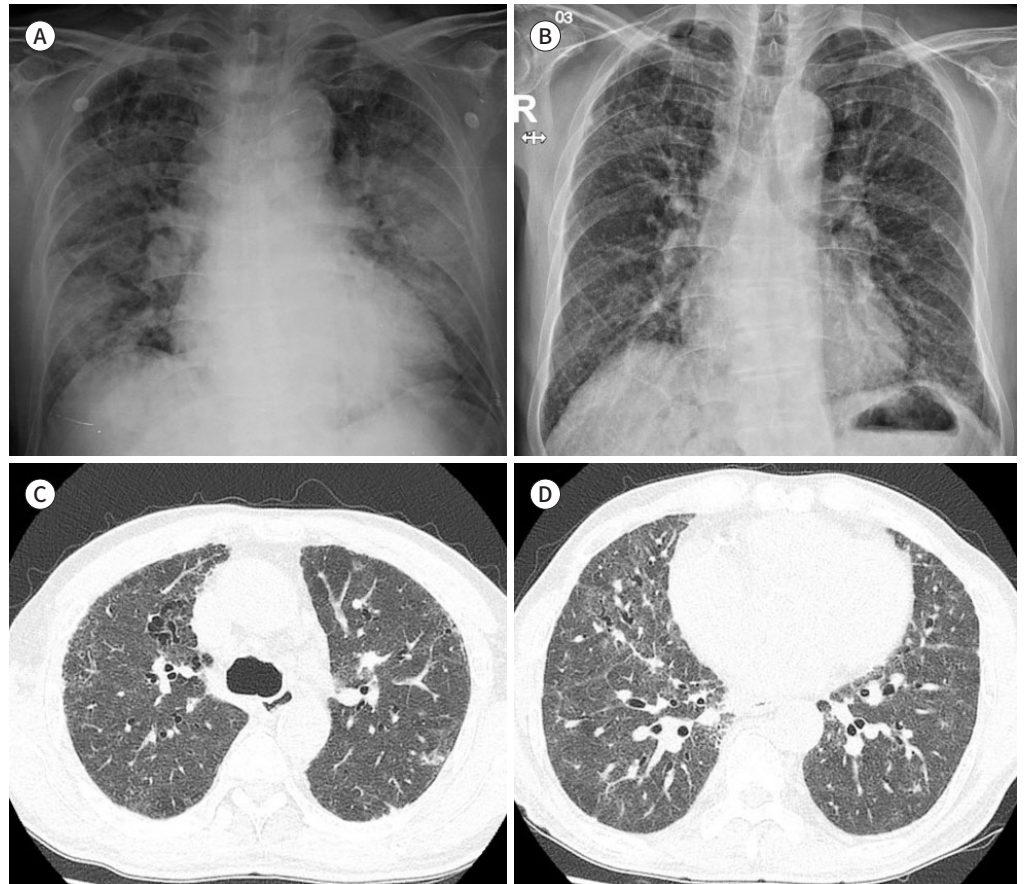
later, and also complained severe shortness of breath after discharge. Pulmonary function test showed restrictive ventilatory defect and reduced DLCO. Follow-up CXR (at 79 days after the admission day) showed bilateral subpleural reticular opacities (Fig. 2B). Chest CT demonstrated subpleural GGO, reticulation, interlobular septal thickening and traction bronchiectasis (BE) in both lungs (Fig. 2C, D), suggesting fibrotic like changes.

CASE 3

A 56-year-old male had a history of hypertension. Initial CXR showed bilateral dense peripheral consolidations in mid and lower zones of both lungs (Fig. 3A). 6 days later, CXR showed marked increase in the extent of peripheral consolidations in both lungs (Fig. 3B). He was hospitalized for 3 weeks due to severe symptoms, and CXR on day of discharge (at 23 days after the admission day) presented residual peripheral consolidations in both lungs (Fig.

Fig. 2. Imaging features in case 2.**A.** Initial chest PA shows diffuse airspace consolidations in both the lungs.**B.** Follow-up chest PA (at 79 days after the admission day) shows bilateral subpleural reticular opacities.**C, D.** Follow-up chest CT (at 79 days after the admission day) demonstrates subpleural ground glass opacity, reticulation, interlobular septal thickening, and traction bronchiectasis in both lungs.

PA = posteroanterior



3C). Chest CT on day of discharge (at 23 days after the admission day) revealed patchy GGO and mixed consolidations with some crazy paving pattern in the peripheral portions of both lungs (Fig. 3D). CT findings were suggestive of OP pattern. On day of discharge, pulmonary function test showed restrictive ventilatory defect and reduced DLCO. He complained persistent dyspnea even after discharge, and admitted on our hospital for corticosteroid therapy on illness day 40 days (prednisolone 1 mg/kg/day). After 18 days of corticosteroid therapy, follow-up CXR (at 58 days after the admission day) showed that consolidations had been absorbed, and noted residual GGO in the both lungs with peripheral distribution (Fig. 3E). Follow-up CT (at 58 days after the admission day) revealed that resolution of consolidations with residual patchy GGO, reticulation and traction BE (Fig. 3F), consistent with resolution of OP pattern and residual fibrotic component.

CASE 4

A 75-year-old male had esophageal cancer diagnosed in 2014. He was discharged on hospi-

Fig. 3. Imaging features in case 3.

A. Initial chest PA shows bilateral dense peripheral consolidations in the mid- and lower zones of both lungs.

B. Chest PA shows marked increase in the extent of peripheral consolidations in both lungs 6 days later.

C, D. Chest PA and CT on the day of discharge; **(C)** chest PA shows residual peripheral consolidations in both lungs; **(D)** CT shows patchy GGO and mixed consolidations with some crazy-paving pattern in the peripheral portions of both lungs, suggesting organizing pneumonia pattern.

E, F. Follow-up chest PA and CT (at 58 days after the admission day) after corticosteroid therapy. **(E)** chest PA shows absorbed consolidations and residual GGO in both lungs with peripheral distribution; **(F)** CT shows resolution of consolidations with residual patchy GGO, reticulation, and traction bronchiectasis.

GGO = ground glass opacities, PA = posteroanterior

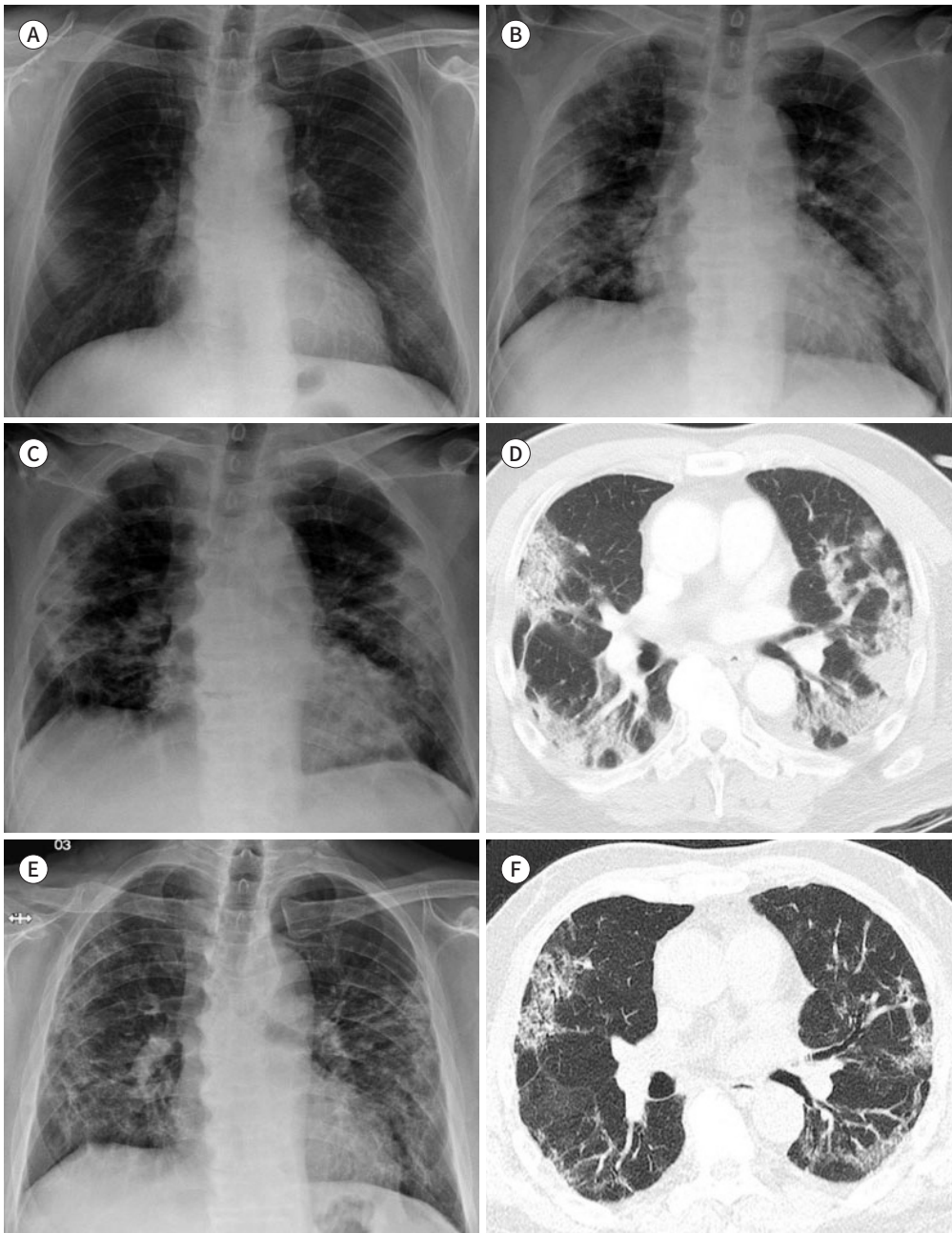
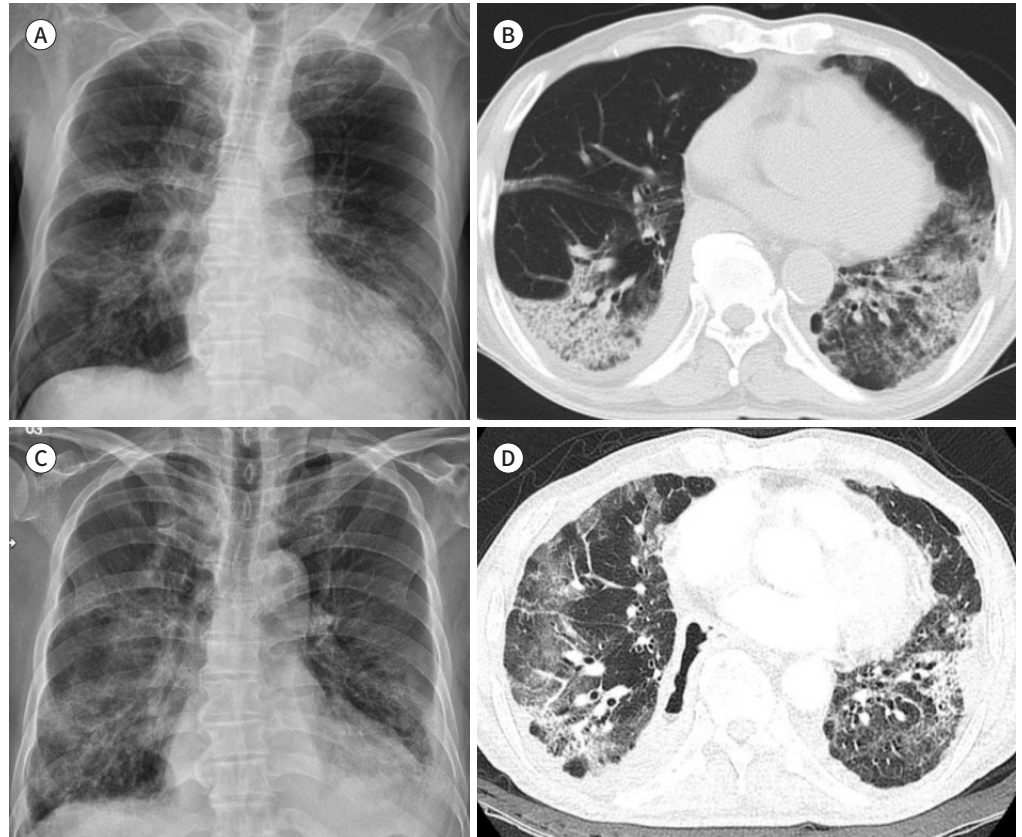


Fig. 4. Imaging features in case 4.

A, B. Chest PA and CT on the day of discharge. Chest PA shows patchy consolidations and GGO in both lower zones (**A**); CT shows patchy GGO and mixed consolidations with peripheral dominance in lower zones of both lungs (**B**).

C, D. Follow-up (at 47 days after the admission day) chest PA reveals progression of patchy consolidations and GGO in both lungs (**C**); CT presents multifocal patchy GGO and mixed consolidations with increased extent in both lungs (**D**).

GGO = ground glass opacities, PA = posteroanterior



tal day 14, and complained persistent shortness of breath. On day of discharge (at 14 days after the admission day), CXR showed patchy consolidations and GGO in both lower zones (Fig. 4A) and CT showed patchy GGO and mixed consolidations with peripheral dominance in lower zones of both lungs (Fig. 4B). Follow-up CXR (at 47 days after the admission day) revealed progression of patchy consolidations and GGO in both lungs (Fig. 4C) and CT showed multifocal patchy GGO and mixed consolidations with increased extent in both lungs (Fig. 4D). These findings resembled OP pattern.

This study was approved by the Institutional Review Board of our institution, and the requirement for informed consent was waived (IRB No. ISPAIK 2021-07-004)

DISCUSSION

Although acute COVID-19-related morbidity and mortality are well documented, but long-term pulmonary sequelae of COVID-19 and efficient treatments has not been established yet. Middle East Respiratory Syndrome (MERS) and severe acute respiratory syndrome (SARS),

the two other strains of the coronavirus family known as highly contagious pathogens, are genetically similar to COVID-19 (2). Previous studies have reported that MERS and SARS showed long-term pulmonary sequelae such as PF (2, 3). So, there is concern that COVID-19 may have long-term pulmonary sequelae.

PF can be idiopathic but caused by chronic inflammation (2). PF has been detected on follow-up imaging in patients who recovered from viral pneumonia, such as MERS and SARS (2, 3). The findings of parenchymal bands, irregular interfaces, traction BE and coarse reticular pattern are considered as evidence of fibrosis (3). Previous studies reported that the PF development in patients with SARS who have been discharged after treatment, and the patients with evidence of fibrosis are older, have higher rate of intensive care unit admission, and higher peak opacification on chest radiographs (3). One long-term study revealed that there were interstitial lung abnormalities in 4.6% of patients with SARS after 15 years (2). Although there is no long period of research yet, several recent studies reported that the findings of fibrotic like change have been seen in patients with COVID-19 after discharge (4-6).

Wei et al. (6), found 39% of patients had residual fibrosis on follow-up CT scan about a month after hospital admission. They also observed that fibrosis is more likely to occur in the elderly and patients with a large range of lesions and severe conditions. At 3 months after discharge, van Gassel et al. (5), reported that high prevalence of pulmonary sequelae in mechanically ventilated patients of COVID-19. They found that 89% of cases showed GGO and 67% of cases showed reticulation, fibrous bands and BE suggesting PF. Han et al. (4), revealed that 35% of patients who recovered from severe COVID-19 pneumonia developed PF within 6 months. This study identified that an older age, longer hospital stays, tachycardia, ARDS, noninvasive mechanical ventilation and higher lung involvement on initial chest CT are independent predictors for fibrotic changes of lungs. So, these findings are similar to SARS and suggest that COVID-19 patients may also have long term sequelae.

OP is a histological pattern of lung injury associated with a wide range of etiologies. The histological finding in OP is characterized by granulation tissue within alveoli and bronchioles (7). Radiological findings of OP typically include peripheral, bilateral, lower lobe predominant consolidation and GGO, with subpleural or bronchovascular distribution (7). OP can be either idiopathic (cryptogenic OP) or secondary (secondary OP), and secondary OP has been reported in viral infections, such as influenza, MERS and SRAS. And corticosteroids are the standard treatment for OP, which often result in rapid clinical and radiological improvement (7, 8).

In a German study, of 38 patients with COVID-19, 3 (12.5%) patients exhibited clinical worsening after a phase of transient recovery, and they presented later developed severe OP pattern on CT scan. And they showed response for corticosteroid therapy (9). In other Brazilian case, three patients experienced worsening symptoms after initial improvement, revealed a pattern compatible with OP on CT scan with an average of 24 days from symptom onset to having a follow-up CT scan. In this case, patients also showed marked clinical improvement after corticosteroid treatment for an average of 7 days (8). In a Japan study, two patients also complained persistent dyspnea although PCR of SARS-CoV-2 was twice negative after treatment. CT showed an OP pattern, one was taken on the 43 days of illness day and one on the 29 days. Additionally, diagnosis was based on transbronchial lung biopsy, showing histopatho-

logical findings of OP. They also presented rapid improvement after introduction of corticosteroid (10). So, follow-up CT scans are important for the identification of patients having OP pattern and appropriate corticosteroid treatment should be performed.

In conclusion, our report of cases also revealed that COVID-19 infection leaved pulmonary sequelae such as PF or OP pattern. However, this study has a short-term follow-up period of 29 to 79 days, there is a limitation in analyzing how long these sequelae lasts. Although the long-term pulmonary sequelae of COVID-19 are still unknown, follow-up imaging after discharge should be considered in patients with persistent pulmonary symptoms.

Author Contributions

Conceptualization, all authors; investigation, K.T.; supervision, K.S.Y., L.B.H.; writing—original draft, K.T.; and writing—review & editing, K.S.Y., L.B.H.

Conflicts of Interest

The authors have no potential conflicts of interest to disclose.

Funding

None

REFERENCES

1. Shi H, Han X, Jiang N, Cao Y, Alwalid O, Gu J, et al. Radiological findings from 81 patients with COVID-19 pneumonia in Wuhan, China: a descriptive study. *Lancet Infect Dis* 2020;20:425-434
2. Vasarmidi E, Tsitoura E, Spandidos DA, Tzanakis N, Antoniou KM. Pulmonary fibrosis in the aftermath of the COVID-19 era (Review). *Exp Ther Med* 2020;20:2557-2560
3. Antonio GE, Wong KT, Hui DS, Wu A, Lee N, Yuen EH, et al. Thin-section CT in patients with severe acute respiratory syndrome following hospital discharge: preliminary experience. *Radiology* 2003;228:810-815
4. Han X, Fan Y, Alwalid O, Li N, Jia X, Yuan M, et al. Six-month follow-up chest CT findings after severe COVID-19 pneumonia. *Radiology* 2021;299:E177-E186
5. van Gassel RJJ, Bels JLM, Raafs A, van Bussel BCT, van de Poll MCG, Simons SO, et al. High prevalence of pulmonary sequelae at 3 months after hospital discharge in mechanically ventilated survivors of COVID-19. *Am J Respir Crit Care Med* 2021;203:371-374
6. Wei J, Yang H, Lei P, Fan B, Qiu Y, Zeng B, et al. Analysis of thin-section CT in patients with coronavirus disease (COVID-19) after hospital discharge. *J Xray Sci Technol* 2020;28:383-389
7. Drakopanagiotakis F, Polychronopoulos V, Judson MA. Organizing pneumonia. *Am J Med Sci* 2008;335:34-39
8. de Oliveira Filho CM, Vieceli T, de Fraga Bassotto C, da Rosa Barbato JP, Garcia TS, Scheffel RS. Organizing pneumonia: a late phase complication of COVID-19 responding dramatically to corticosteroids. *Braz J Infect Dis* 2021;25:101541
9. Vadász I, Husain-Syed F, Dorfmueller P, Roller FC, Tello K, Hecker M, et al. Severe organising pneumonia following COVID-19. *Thorax* 2021;76:201-204
10. Kanaoka K, Minami S, Ihara S, Tanaka T, Yasuoka H, Komuta K. Secondary organizing pneumonia after coronavirus disease 2019: two cases. *Respir Med Case Rep* 2021;32:101356

COVID-19 환자의 네 증례에서 폐 후유증에 대한 흉부 CT 소견

김태은 · 김수영* · 이병훈

Coronavirus disease 2019 (이하 COVID-19)의 대유행이 지속됨에 따라 COVID-19 감염에서 회복된 환자들의 후유증과 치료에 많은 관심이 발생하고 있다. COVID-19의 장기적인 후유증은 아직 알려지지 않았지만, 최근 발표된 문헌에 따르면 일부 환자들은 퇴원 후에도 증상이 지속되며 영상의학적 이상 소견을 보였다. 우리는 COVID-19 회복 후에 지속적인 호흡 곤란이 있던 네 명의 환자들 증례에서 폐 섬유화 또는 기질화 폐렴 패턴을 나타내는 폐 후유증을 보고하고자 한다.

인제대학교 의과대학 일산백병원 영상의학과