









# Isolated Intracranial Rosai–Dorfman Disease Mimicking Meningioma: A Case Report

뇌수막종으로 오인된 두개 내에만 발생한 Rosai–Dorfman Disease: 증례 보고

Minji Shin, MD<sup>1</sup> , Young Jin Heo, MD<sup>1\*</sup> , Donghyun Kim, MD<sup>1</sup> ,  
Hae Woong Jeong, MD<sup>1</sup> , Jin Wook Baek, MD<sup>1</sup> , Ha Young Park, MD<sup>2</sup> 

Departments of <sup>1</sup>Radiology and <sup>2</sup>Pathology, Busan Paik Hospital, Inje University College of Medicine, Busan, Korea

Rosai–Dorfman Disease (RDD) is a rare lymphoproliferative disease, and the occurrence of isolated intracranial RDD is extremely rare. Most cases of intracranial RDDs present as dural masses showing homogenous enhancement on MRI, which makes it difficult to differentiate these masses from meningiomas before surgery unless massive cervical lymphadenopathy is observed. We herein report a rare case of isolated intracranial RDD in a 65-year-old male. Brain MRI revealed a well-defined enhancing mass-like lesion involving the right frontal convexity and subtle diffusion restriction. However, only a subtle blush was observed on the preoperative cerebral angiogram. Although instances of isolated intracranial RDD are rare, it should be considered as a potential differential diagnosis when a dural mass with hypovascularity is visualized on the cerebral angiogram.

**Index terms** Angiography; Dura Mater; Magnetic Resonance Imaging; Meningioma; Rosai–Dorfman Disease

## INTRODUCTION

Rosai–Dorfman Disease (RDD) is a rare lymphoproliferative disease and is also known as sinus histiocytosis with massive lymphadenopathy. It usually affects young males (1) and most often presents with painless cervical lymphadenopathy, fever, weight loss, and an elevated erythrocyte sedimentation rate (ESR) (2). Although 43% of RDD patients have at least one site of extra-nodal involvement (3), isolated intracranial RDD is extremely rare and accounts for approximately 5% of all extra-nodal RDD cases (4). It

Received June 29, 2021  
Revised October 8, 2021  
Accepted November 21, 2021

**\*Corresponding author**

Young Jin Heo, MD  
Department of Radiology,  
Busan Paik Hospital,  
Inje University College of Medicine,  
75 Bokji-ro, Busanjin-gu,  
Busan 47392, Korea.







Tel 82-51-890-6549

Fax 82-51-896-1085

E-mail youngjin726@hanmail.net

This is an Open Access article distributed under the terms of the Creative Commons Attribution Non-Commercial License (<https://creativecommons.org/licenses/by-nc/4.0>) which permits unrestricted non-commercial use, distribution, and reproduction in any medium, provided the original work is properly cited.

**ORCID iDs**

Minji Shin   
<https://orcid.org/0000-0002-9584-0066>  
Young Jin Heo   
<https://orcid.org/0000-0002-4765-0727>  
Donghyun Kim   
<https://orcid.org/0000-0002-3429-7557>  
Hae Woong Jeong   
<https://orcid.org/0000-0002-4912-9302>  
Jin Wook Baek   
<https://orcid.org/0000-0003-4632-4951>  
Ha Young Park   
<https://orcid.org/0000-0002-7192-2374>

usually presents as a dural mass and is frequently misdiagnosed as other extra-axial tumors, such as meningioma. Herein, we report a case of isolated intracranial RDD in a 65-year-old male patient.

## CASE REPORT

A 65-year-old-male presented with an episode of generalized tonic-clonic seizures. He had a history of left-sided motor weakness for the last 3 months, since the time of presentation. He was on medication for hypertension and previous angina. At the time of arrival to our hospital, he was conscious and well oriented, with a Glasgow Coma Scale score of 15/15. Neurologic examination revealed decreased motor function on the left side (3/5 on the Grading Motor Strength Grade). There was no lymphadenopathy or organomegaly. Laboratory test results showed no abnormalities, except for elevated ESR levels (69 mm/hr, normal: <20 mm/hr).

A brain CT scan revealed a relatively well-defined, iso-dense, extra-axial mass-like lesion with heterogeneous enhancement at the right frontal convexity (Fig. 1A). The mass was accompanied by extensive perilesional edema, resulting in right lateral ventricular compression. There was no evidence of internal calcifications or adjacent bony hyperostosis. On brain MR imaging, the mass was isointense to hypointense on T2-weighted image and hypointense on T1-weighted image. It showed heterogeneous enhancement (Fig. 1B). Therefore, the preoperative diagnosis was an extra-axial tumor, such as meningioma, solitary fibrous tumor, lymphoma, and metastasis. Cerebral angiography showed a subtle blush (Fig. 1C). Abdominopelvic and chest CT scans were performed to rule out the presence of malignancy and other nodal diseases, and there was no evidence of cervical lymphadenopathy involving the infrahyoid space was seen on chest CT.

The patient underwent right frontoparietal craniotomy, and the mass was resected entirely. Histiocytic infiltration and characteristic emperipolesis were identified on carrying out histological analysis (Fig. 1D). Immunohistochemical staining results showed the expression of the proteins CD36 and S100, but no expression of CD1a. Therefore, based on the histological findings, the patient was diagnosed with RDD involving the meninges.

During the latest follow-up examination, the patient was well and on a prescription of anti-epileptic medications, although he still had vague left motor weakness. A follow-up MRI scan was done 6 months after the surgery, which revealed that there was no definite residual enhancing lesion and previous peritumoral edema remained with decreased extent.

The need to obtain written informed consent was waived by the Institutional Review Board due to the retrospective nature of the study (IRB No. 2021-07-010).

## DISCUSSION

RDD is a rare non-neoplastic lymphoproliferative disorder and frequently presents as bilateral painless massive cervical lymphadenopathy associated with fever, night sweats, fatigue, and weight loss. The etiology of RDD is still uncertain, but viral (Human Herpes virus 6, Epstein-Barr virus) infections, cytokine-mediated migration of monocytes, and mutations disabling the SLC29A3 gene, were suggested as possible causative factors (5, 6).

**Fig. 1.** Imaging and pathologic findings of a 65-year-old male with isolated intracranial RDD.

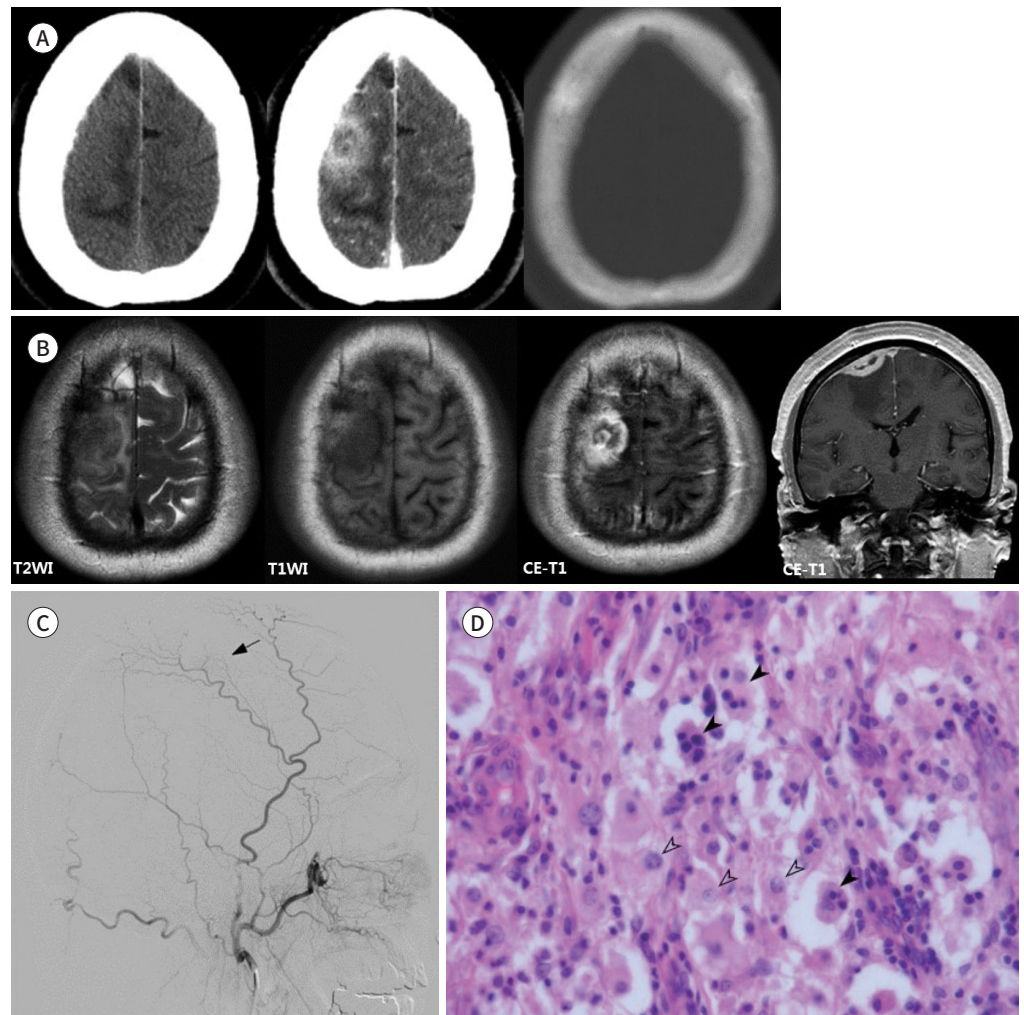
**A.** Axial CT scan shows an isodense mass-like lesion with irregular margins and heterogeneous enhancement in the right frontal convexity. There are no accompanying bony changes such as bony erosion and hyperostosis.

**B.** Axial T2- and T1WI images show a hypointense extra-axial mass in the right frontal convexity. Axial and coronal CE-T1WI images show that the mass presents heterogeneous enhancement and irregular margins. The mass is accompanied by extensive perilesional edema, leading to right lateral ventricular compression.

**C.** On the preoperative right external carotid angiogram, a subtle blush is observed in the right frontoparietal convexity (arrow), and the suspected feeder is the right middle meningeal artery.

**D.** Photomicroscopic image ( $\times 400$ , hematoxylin and eosin stain) shows characteristic emperipolesis (black arrowheads) and histiocytic infiltration (blank arrowhead).

CE = contrast-enhanced, RDD = Rosai–Dorfman Disease, T1WI = T1 weighted image, T2WI = T2 weighted image



Extra-nodal involvement is known to take place in 43% of RDD patients (3), with or without associated nodal involvement. Extra-nodal RDD may involve any organ system, but most commonly involves the skin, soft tissues, upper respiratory tract, bones, orbit, nasopharynx, salivary glands, and the central nervous system (4). Primary and isolated intracranial RDD was reported as approximately 5% of the total extra-nodal RDD cases.

Intracranial RDD, unlike systemic RDD, is usually not accompanied by constitutional symptoms such as fever, weight loss, and night sweats. However, intracranial RDD can pres-

ent variable symptoms depending on the location and size of the lesions. Patients may experience headaches, seizures, or focal neurological deficits due to the mass effect and edemas. The mean age of onset of disease was greater in patients with intracranial RDD than in patients with systemic RDD, presenting massive lymphadenopathy (7). Emperipolesis, the characteristic histopathologic feature of RDD, can be more frequently obscured by prominent fibrosis in intracranial RDD than in the classic nodal presentation (8).

Primary and isolated intracranial RDD are associated with the dura mater and commonly occur in the cerebral convexity, skull base, parasagittal regions, and suprasellar regions, similar to meningiomas (2). On CT scans, these usually appear as well-circumscribed hyperdense lesions with contrast enhancement, and perilesional edema with mass effect (4). MRI scans of RDD usually reveal isointense lesions on T1-weighted images and hypointense lesions on T2-weighted images. RDD generally shows homogenous enhancement after contrast injection (4). Due to these findings, differentiating RDD from meningiomas, Langerhans cell histiocytosis, lymphoproliferative disorders, plasma cell granulomas, granulomatous diseases, and neurofibromatosis is challenging (2). Differentiating intracranial RDD from meningiomas is more frequently difficult due to the aforementioned radiologic features. However, meningiomas frequently accompany bony changes, such as hyperostosis and calcifications, while intracranial RDDs rarely accompany these features (9). Furthermore, meningiomas often show hypervascularity on cerebral angiogram, but intracranial RDD show variable findings (10). In addition, only a minor degree of blush was identified on the preoperative angiogram in previous study (11). In our study, accompanying bony changes were not observed on the brain CT scan, and only subtle blush was observed on the preoperative cerebral angiogram. These findings may help in differentiating intracranial RDD from meningioma.

To conclude, we present a rare case of isolated intracranial RDD. RDD is typically accompanied by cervical lymphadenopathy, and intracranial involvement is extremely rare (3). Preoperative differential diagnosis with meningioma is difficult since the isolated intracranial RDD lesion is usually presents as an enhancing mass-like lesion, in relation to the dura mater without cervical lymphadenopathy. However, the absence of accompanying bony changes, such as bony erosion, hyperostosis, calcification, and the absence of angiographic hypervascularity, could help differentiate intracranial RDD from meningioma. The knowledge of these findings could help physicians and radiologic professionals efficiently diagnose RDD and differentiate it from meningiomas.

### Author Contributions

Conceptualization, H.Y.J.; data curation, S.M., H.Y.J., P.H.Y.; formal analysis, S.M., H.Y.J.; investigation, S.M., H.Y.J.; methodology, S.M., H.Y.J.; project administration, S.M., H.Y.J.; resources, S.M., H.Y.J.; supervision, H.Y.J.; validation, H.Y.J.; visualization, S.M., P.H.Y.; writing—original draft, S.M., H.Y.J.; and writing—review & editing, all author.

### Conflicts of Interest

The authors have no potential conflicts of interest to disclose.

### Funding

None

## REFERENCES

1. Lim R, Wittram C, Ferry JA, Shepard JA. FDG PET of Rosai-Dorfman disease of the thymus. *AJR Am J Roentgenol* 2004;182:514
2. Foucar E, Rosai J, Dorfman R. Sinus histiocytosis with massive lymphadenopathy (Rosai-Dorfman disease): review of the entity. *Semin Diagn Pathol* 1990;7:19-73
3. Azoulay R, Brisse H, Fréneaux P, Ferey S, Kalifa G, Adamsbaum C. Lacrimal location of sinus histiocytosis (Rosai-Dorfman-Destombes disease). *AJNR Am J Neuroradiol* 2004;25:498-500
4. Varrassi M, Corridore A, Tommasino E, Saltelli G, Bruno F, Di Sibio A, et al. MR imaging of cerebral involvement of Rosai-Dorfman disease: a single-centre experience with review of the literature. *Radiol Med* 2021;126:89-98
5. Emile JF, Abla O, Fraitag S, Horne A, Haroche J, Donadieu J, et al. Revised classification of histiocytoses and neoplasms of the macrophage-dendritic cell lineages. *Blood* 2016;127:2672-2681
6. Morgan NV, Morris MR, Cangul H, Gleeson D, Straatman-Iwanowska A, Davies N, et al. Mutations in SLC29A3, encoding an equilibrative nucleoside transporter ENT3, cause a familial histiocytosis syndrome (Faisalabad histiocytosis) and familial Rosai-Dorfman disease. *PLoS Genet* 2010;6:e1000833
7. Sharma MS, Padua MD, Jha AN. Rosai-Dorfman disease mimicking a sphenoid wing meningioma. *Neurol India* 2005;53:110-111
8. Andriko JA, Morrison A, Colegial CH, Davis BJ, Jones RV. Rosai-Dorfman disease isolated to the central nervous system: a report of 11 cases. *Mod Pathol* 2001;14:172-178
9. Wen JH, Wang C, Jin YY, Xu D, Jiang B, He XJ, et al. Radiological and clinical findings of isolated meningeal Rosai-Dorfman disease of the central nervous system. *Medicine (Baltimore)* 2019;98:e15365.
10. Adeleye AO, Amir G, Fraifeld S, Shoshan Y, Umansky F, Spektor S. Diagnosis and management of Rosai-Dorfman disease involving the central nervous system. *Neurol Res* 2010;32:572-578
11. Hadjipanayis CG, Bejjani G, Wiley C, Hasegawa T, Maddock M, Kondziolka D. Intracranial Rosai-Dorfman disease treated with microsurgical resection and stereotactic radiosurgery. Case report. *J Neurosurg* 2003;98:165-168

## 뇌수막종으로 오인된 두개 내에만 발생한 Rosai-Dorfman Disease: 증례 보고

신민지<sup>1</sup> · 허영진<sup>1\*</sup> · 김동현<sup>1</sup> · 정해웅<sup>1</sup> · 백진욱<sup>1</sup> · 박하영<sup>2</sup>

Rosai-Dorfman Disease (이하 RDD)는 드문 조직구 증식성 질환이며 두개 내에만 발생하는 경우는 매우 드물다. 대부분의 두개 내 RDD는 균질한 조영증강을 동반하는 경막의 종괴들로 나타나서, 심한 경부 림프절증을 보이지 않는 경우에는 수술하기 전에 뇌수막종과의 감별이 어렵다. 저자들은 65세 남자 환자의 두개 내에만 발생한 RDD의 드문 증례에 대해 보고하고자 한다. 뇌 MRI에서 우측 전엽 원개에 경계가 분명한 조영증강되는 종괴의 형태로 보였으며 미세한 확산제한이 관찰되었다. 하지만 수술 전 뇌혈관조영상에서는 겨우 미세한 흥조만이 보였다. 비록 두개 내에만 발생한 RDD가 드물기는 하지만, 경막에 기반한 종괴가 뇌혈관조영상에서 저혈관성의 형태로만 보일 때 감별질환으로 생각할 수 있다.

인제대학교 의과대학 부산백병원 <sup>1</sup>영상의학과, <sup>2</sup>병리과