









Feasibility of Pediatric Low-Dose Facial CT Reconstructed with Filtered Back Projection Using Adequate Kernels

필터보정역투영과 적절한 커널을 이용한 소아 저선량 안면 컴퓨터단층촬영의 시행 가능성

Hye Ji, MD¹ , Sun Kyoung You, MD² , Jeong Eun Lee, MD² ,
So Mi Lee, MD³ , Hyun-Hae Cho, MD⁴ , Joon Young Ohm, MD^{1*} 

¹Department of Radiology, Chungnam National University Hospital, Daejeon, Korea

²Department of Radiology, Chungnam National University Hospital, Chungnam National University College of Medicine, Daejeon, Korea

³Department of Radiology, School of Medicine, Kyungpook National University, Kyungpook National University Chilgok Hospital, Daegu, Korea

⁴Department of Radiology, Ewha Womans University Mokdong Hospital, Seoul, Korea

Purpose To evaluate the feasibility of pediatric low-dose facial CT reconstructed with filtered back projection (FBP) using adequate kernels.

Materials and Methods We retrospectively reviewed the clinical and imaging data of children aged < 10 years who underwent facial CT at our emergency department. The patients were divided into two groups: low-dose CT (LDCT; Group A, $n = 73$) with a fixed 80-kVp tube potential and automatic tube current modulation (ATCM) and standard-dose CT (SDCT; Group B, $n = 40$) with a fixed 120-kVp tube potential and ATCM. All images were reconstructed with FBP using bone and soft tissue kernels in Group A and only bone kernel in Group B. The groups were compared in terms of image noise, signal-to-noise ratio (SNR), and contrast-to-noise ratio (CNR). Two radiologists subjectively scored the overall image quality of bony and soft tissue structures. The CT dose index volume and dose-length product were recorded.

Results Image noise was higher in Group A than in Group B in bone kernel images ($p < 0.001$). Group A using a soft tissue kernel showed the highest SNR and CNR for all soft tissue structures (all $p < 0.001$). In the qualitative analysis of bony structures, Group A scores were found to be similar to or higher than Group B scores on comparing bone kernel images. In the qualitative analysis of soft tissue structures, there was no significant difference between Group A using a soft tissue kernel and Group B using a bone kernel with a soft tissue window setting ($p > 0.05$). Group A showed a 76.9% reduction in radiation dose compared to Group B (3.2 ± 0.2 mGy vs. 13.9 ± 1.5 mGy; $p < 0.001$).

Received January 4, 2021

Revised May 4, 2021

Accepted June 30, 2021

*Corresponding author

Joon Young Ohm, MD
Department of Radiology,
Chungnam National University
Hospital, 282 Munhwa-ro,
Jung-gu, Daejeon 35015, Korea.

Tel 82-42-220-7838

Fax 82-42-253-0061

E-mail akhnaten74@gmail.com


This is an Open Access article distributed under the terms of the Creative Commons Attribution Non-Commercial License (<https://creativecommons.org/licenses/by-nc/4.0>) which permits unrestricted non-commercial use, distribution, and reproduction in any medium, provided the original work is properly cited.

ORCID iDs

Hye Ji 


<https://>

orcid.org/0000-0001-8268-0043

Sun Kyoung You 

<https://>

orcid.org/0000-0002-1026-5809

Jeong Eun Lee 


<https://>

orcid.org/0000-0001-9566-7489

So Mi Lee 


<https://>

orcid.org/0000-0002-2073-8198

Hyun-Hae Cho 

<https://>

orcid.org/0000-0002-4865-2601

Joon Young Ohm 

<https://>

orcid.org/0000-0002-4842-9063

Conclusion The addition of a soft tissue kernel image to conventional CT reconstructed with FBP enables the use of pediatric low-dose facial CT protocol while maintaining image quality.

Index terms Dose Reduction; Face; Computed Tomography, X-Ray; Pediatrics; Image Reconstruction

INTRODUCTION

Multidetector CT (MDCT) is the imaging modality of choice for patients with facial trauma, because it facilitates the diagnosis of fractures with greater accuracy compared to radiography (1). However, higher radiation exposure is one of the disadvantages of CT (2, 3). In facial CT, the eye lens is a radiosensitive organ, and reducing the radiation dose is the most effective method of reducing risks associated with radiation exposure (4). Among the several CT scan parameters that can be manipulated to lower the radiation dose, lowering the tube potential (peak kilovoltage [kVp]) is an effective method for pediatric patients (5-7). Although it can improve image contrast, it also increases image noise.

Since facial CT is primarily used to visualize the facial bones of patients with trauma, the images are often provided only with a bone kernel. Moreover, the soft tissues are evaluated by adjusting the window level and width. Since bone is a high-contrast material, it can tolerate the image noise that accompanies the use of the low kVp protocol. However, it is difficult to evaluate soft tissue using the bone kernel image of low-dose CT (LDCT) by adjusting the window level and width (5).

Advancement in CT technology has enabled the application of iterative reconstruction (IR) that can better overcome image noise compared to filtered back projection (FBP) (3, 5). Widmann reported studies (8-12) on ultra-low-dose craniofacial/maxillofacial CT using IR techniques (adaptive statistical iterative reconstruction [ASIR] and model-based iterative reconstruction [MBIR]). However, one of the limitations of IR is that it requires new equipment.

Conventional CT requires the generation of separate images that utilize different kernels to optimize detection (13, 14). The kernel affects the appearance of image structures by sharpening the image. Different kernels have been developed for specific anatomical applications including soft tissue and bone (13, 15-17). Modification with an adequate kernel can achieve sufficient image quality. Previous studies reported that image quality could be improved by the modification of the reconstruction kernels (1, 18, 19).

We endeavored to investigate whether image quality could be maintained in low-dose facial CT without IR in the pediatric population by optimal kernel selection. We added a soft tissue kernel image to a bone kernel image to overcome the limitation regarding soft tissue evaluation using LDCT with FBP.

To the best of our knowledge, no study has investigated the application of the ultra-low-dose facial CT protocol proposed by Widmann et al. (8-12) in patients in real clinical settings. The purpose of this study was to evaluate the feasibility of LDCT using only FBP by evaluating the bone and soft tissue visualization with respect to the choice of the reconstruction kernel.

MATERIALS AND METHODS

This study was approved by the Institutional Review Board of our institution and the requirement for informed consent was waived (IRB No. 2020-07-009).

PATIENTS

We retrospectively reviewed clinical and imaging data of children younger than 10 years who underwent facial CT for various reasons at our emergency department. We excluded two patients with severe facial damage that resulted in indistinguishable anatomical structures.

The patients who underwent facial CT scans with the low tube voltage (80 kVp) protocol, from May to July 2019, were defined as Group A. Patients who underwent facial CT scans with the standard tube voltage (120 kVp) protocol, from May to July 2016, were defined as Group B.

CT SCAN PROTOCOL AND RECONSTRUCTION

All patients underwent facial CT using a 64-channel MDCT machine (SOMATOM Sensation 64, Siemens Medical Solutions, Forchheim, Germany) in the emergency room with only the tube current modulation program (CARE Dose4D). All images were reconstructed using FBP. The protocol used for Group A consisted of a fixed tube potential of 80 kVp and automatic tube current modulation (ATCM) with a reference tube current of 80 mAs. The protocol for Group B consisted of a fixed tube potential of 120 kVp and ATCM with a reference tube current of 100 mAs. Other CT scan parameters are noted in Table 1.

We prepared five sets of CT images for review (Fig. 1). We used soft tissue and bone kernels for Group A, which were subdivided into Group A1, A2, and A3. Group A1 included images reconstructed using a bone kernel with bone window setting (width, 2056; level, 250). Group A2 included images reconstructed using a bone kernel with soft tissue window setting (width, 400; level, 20). Group A3 included images reconstructed using a soft tissue kernel with a soft tissue window setting. The soft tissue kernel did not apply to Group B. Group B images were reconstructed using a bone kernel and subdivided into Group B1 and B2. Group B1 included images adjusted with bone window setting, and Group B2 included images adjusted with soft tissue window setting. Group A1 and B1 were compared for bone structures, and Group A2, A3, and B2 were compared for soft tissue structures.

Table 1. Parameters of CT Protocol

CT Parameters	Group A (Low Dose Protocol)	Group B (Standard Dose Protocol)
Tube voltage, kVp	80	120
Reference tube current-time product, mAs	80	100
Table pitch, s	1.0	1.0
Gantry rotation time, s	0.5	0.5
Slice thickness	1.0	1.0
Reconstruction kernel	Bone: H60f sharp FR Soft tissue: H30f medium smooth	

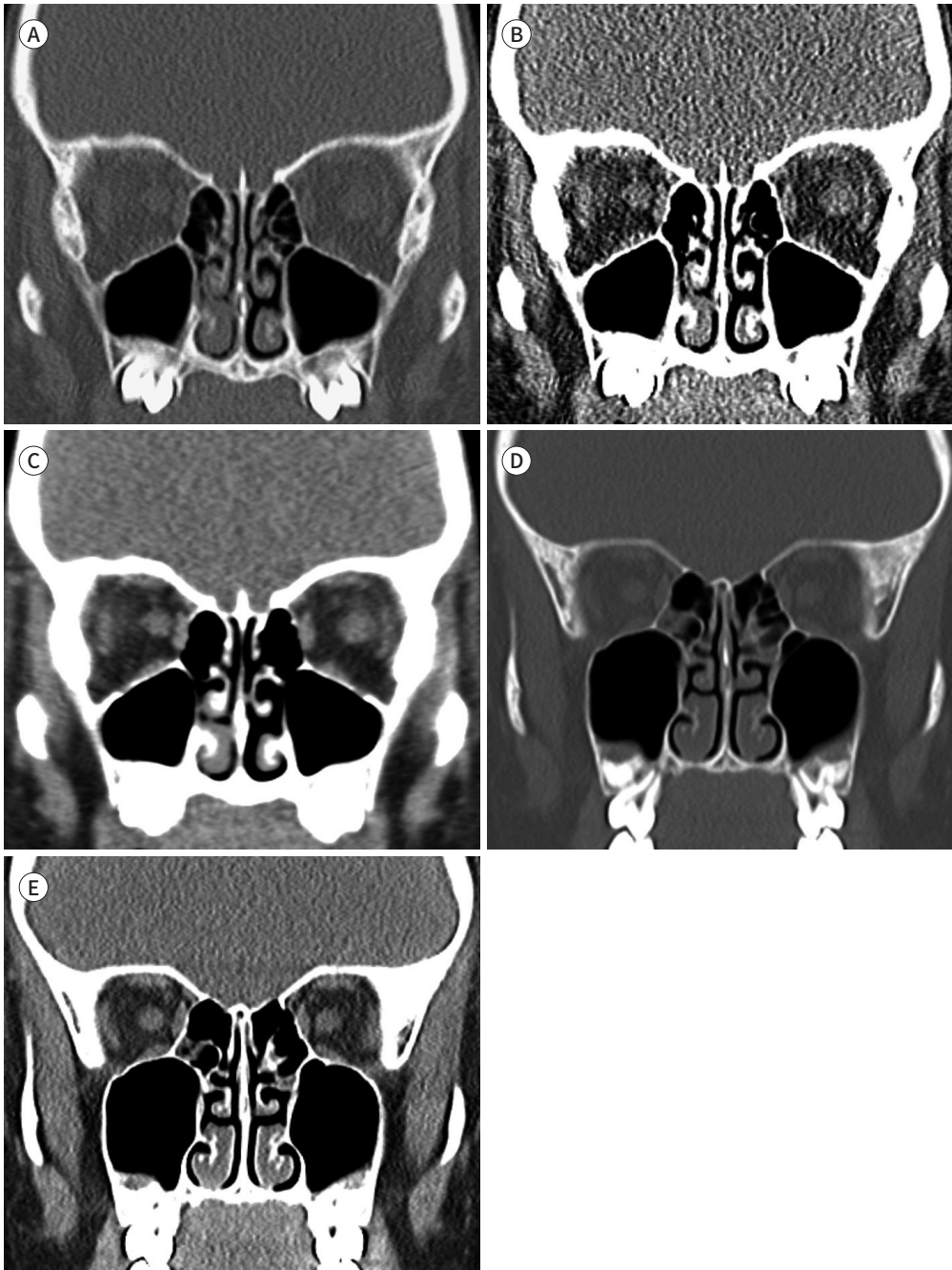
RADIATION DOSE

The CT dose index volume (CTDIvol [16 cm], mGy) and dose-length products (DLPs, mGy·cm) were recorded. These data were automatically generated at the end of each examination and stored in the picture archiving and communication system (PACS).

Fig. 1. Facial CT images using a bone or soft tissue kernel and different window settings.

A-C. Low-dose CT images representing Group A: **(A)** Group A1, bone kernel image with bone setting, **(B)** Group A2, bone kernel image with soft tissue setting, and **(C)** Group A3, soft tissue kernel image with soft tissue setting.

D, E. Standard CT images representing Group B: **(D)** Group B1, bone kernel image with bone setting and **(E)** Group B2, bone kernel image with soft tissue setting.



QUANTITATIVE IMAGE ANALYSIS

Quantitative analysis of images was performed by a third-grade radiology resident who was blinded to the clinical findings and CT parameters. We compared soft tissue structures among Group A2, B2, and A3. Several region-of-interest (ROI) measurements were performed on soft tissue structures on the PACS workstation. Image noise was defined as the standard deviation (SD) of air (SD_{air}) by manually placing the ROI (9.26 mm²), 1 cm in front of the eyeball at the level of its maximal anteroposterior diameter. The mean CT attenuation of the medial rectus muscle (mRM), optic nerve (ON), and orbital fat (OF) were measured by manually placing the ROI (range; 2.8–4.2 mm²) in each structure on the coronal scan (Fig. 2). The measurements were performed at the thickest level of the mRM.

The mean Hounsfield units (MHU) and the SD of each structure were recorded. Signal-to-noise ratio (SNR), and contrast-to-noise ratio (CNR) were calculated according to the following equations (9):

$$\text{SNR} = \frac{\text{MHU}_a}{\text{SD}_{\text{air}}} \quad (\text{MHU}_a, \text{MHU of anatomical structure; SD}_{\text{air}}, \text{SD of air})$$

The CNR of mRM and ON were calculated using the following formula:

$$\text{CNR} = \frac{\text{MHU}_a - \text{MHU}_{\text{fat}}}{\sqrt{(\text{SD}_a)^2 + (\text{SD}_{\text{fat}})^2}} \quad (\text{MHU}_{\text{fat}}, \text{MHU of fat; SD}_a, \text{SD of anatomical structure; SD}_{\text{fat}}, \text{SD of fat})$$

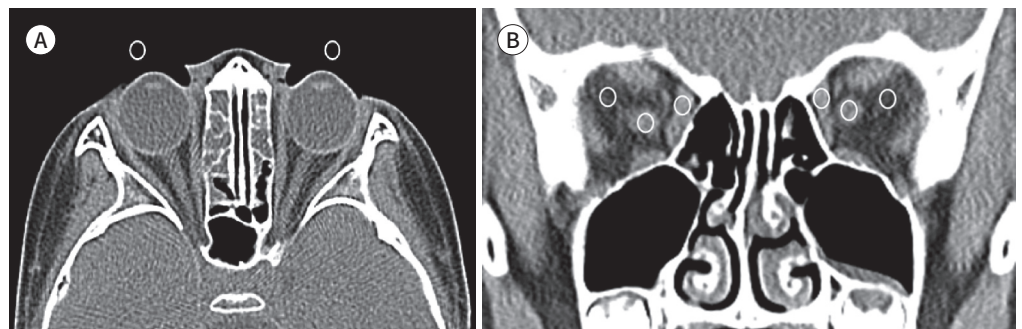
QUALITATIVE IMAGE ANALYSIS

CT images were independently reviewed by two radiologists (S.K.Y., board-certified pediatric radiologist with 12 years of experience, and H.J., a third-grade radiology resident) who were blinded to the CT parameters.

Bony structures (the nasal bone and bony orbit) were compared between Group A1 and B1. Soft tissue structures (mRM and ON) were compared among Group A2, B2, and A3.

The two radiologists rated the delineation of each structure on the CT scans using a score from 1 to 5 (1 = non-diagnostic, 2 = fair, 3 = moderate, 4 = good, 5 = excellent), which was defined by consensus between the two reviewers before starting analysis. The images were limited to two preset window settings for the bone and soft tissue. Anatomical structures were

Fig. 2. Regions of interest are drawn manually in the air in front of the eyeball on axial images (A) and in the medial rectus muscle, optic nerve, and orbital fat on coronal images (B).



evaluated bilaterally with the lower grade used between the two.

STATISTICAL ANALYSIS

Statistical analysis was performed using IBM SPSS Statistics for Windows (version 21.0., IBM Corp., Armonk, NY, USA). Variables were expressed as mean \pm SD and range. Radiation dose and quantitative image parameters such as image noise, MHU, SNR and CNR were evaluated using the student's *t* test and Kruskal–Wallis test, and a *p* value of < 0.05 was considered statistically significant. *p* values < 0.016 were considered statistically significant for multiple comparisons after Kruskal–Wallis test for Bonferroni correction. Sex ratios were compared using a Pearson's chi-squared test. Cohen's kappa statistics were used to assess the degree of interobserver agreement for qualitative analysis using MedCalc (version 17.2, Mariakerke, Belgium). The weighted kappa value was interpreted as follows: 0.81–1.00, excellent agreement; 0.61–0.80, substantial agreement; 0.41–0.60, moderate agreement; 0.21–0.40, fair agreement; and < 0.20 , poor agreement.

RESULTS

PATIENTS

The total number of patients was 113 (Group A: 73, Group B: 40). The mean age of all patients was 5.0 ± 2.6 years (range: 0.9–10.2 years). The sex ratio (boys/girls) was 52/21 in Group A and 25/15 in Group B. There were no significant differences in sex or age between Groups A and B ($p > 0.05$).

RADIATION DOSE

The mean CTDIvol and DLP of Group A were 3.2 ± 0.2 (mGy) and 81.9 ± 11.1 (mGy*cm), respectively, and those of Group B were 13.9 ± 1.5 (mGy) and 385.0 ± 0.4 (mGy*cm), respectively. The mean CTDIvol and DLP of Group A were statistically lower than that of Group B by 76.9% and 78.9%, respectively.

QUANTITATIVE ANALYSIS

The results of the quantitative analysis are presented in Table 2. The image noise of Group A3 was the lowest among the three groups ($p < 0.001$). The SNR of mRM, ON, and OF and the CNR of mRM and ON of Group A3 were the highest among all three groups (all $p < 0.001$).

QUALITATIVE ANALYSIS

The results of the qualitative analysis of bony structures are presented in Table 3. Interobserver agreements for bony structures were moderate to substantial (kappa value: 0.55–0.62). Group A1 showed a higher score than Group B1. The results of the qualitative analysis of soft tissue are presented in Table 4. Qualitative analysis of soft tissue showed moderate agreement (kappa value: 0.53 to 0.60). Group A2 showed the lowest score among the three groups ($p < 0.001$). There was no statistical difference between Group B2 and A3 (all $p > 0.016$).

Table 2. Result of Quantitative Analysis in Soft Tissue Structures

	Group A2 (Low Dose, Bone Kernel, Soft Tissue Window)	Group B2 (Standard Dose, Bone Kernel, Soft Tissue Window)	Group A3 (Low Dose, Soft Tissue Kernel, Soft Tissue Window)	p-Value	A2 vs. B2	A2 vs. A3	B2 vs. A3
CT number, mean ± SD							
Medial rectus muscle	53.8 ± 2.4	50.9 ± 4.4	53.2 ± 7.0	0.44	0.116	0.351	0.415
Optic nerve	50.6 ± 0.4	39.5 ± 12.1	42.3 ± 6.5	<0.001*	<0.001	<0.001	0.312
Orbital fat	99.9 ± 5.2	90.4 ± 5.6	103.6 ± 12.2	<0.001†	<0.001	0.121	<0.001
Image noise	23.3 ± 5.3	15.8 ± 12.7	6.3 ± 3.2	<0.001	<0.001	<0.001	<0.001
SNR, mean ± SD							
Medial rectus muscle	1.3 ± 0.5	2.4 ± 0.7	5.6 ± 2.7	<0.001	<0.001	<0.001	<0.001
Optic nerve	1.2 ± 0.5	1.9 ± 0.5	4.4 ± 1.9	<0.001‡	0.263	<0.001	<0.001
Optic fat	2.4 ± 0.8	4.3 ± 1.1	11.1 ± 5.3	<0.001	<0.001	<0.001	<0.001
CNR, mean ± SD							
Medial rectus muscle	2.4 ± 0.6	4.4 ± 1.0	8.9 ± 3.0	<0.001	<0.001	<0.001	<0.001
Optic nerve	2.3 ± 0.6	4.3 ± 1.0	9.4 ± 2.5	<0.001	<0.001	<0.001	<0.001

*No statistical significant difference between Group B2 and Group A3.

†No statistical significant difference between Group A2 and Group A3.

‡No statistical significant difference between Group A2 and Group B2.

CNR = contrast-to-noise ratio, SD = standard deviation, SNR = signal-to-noise ratio

Table 3. Result of Qualitative Analysis of Bony Structures

	Group A1 (Low Dose, Bone Kernel, Bone Window)	Group B1 (Standard Dose, Bone Kernel, Bone Window)	p-Value	κ Value
Nasal bone				
Observer 1	4.13 ± 0.75	3.90 ± 0.81	0.122	0.62
Observer 2	3.90 ± 0.80	3.57 ± 0.63	0.027	
Orbital wall				
Observer 1	4.45 ± 0.60	4.17 ± 0.74	0.034	0.55
Observer 2	4.24 ± 0.66	3.80 ± 0.72	0.001	

Table 4. Result of Qualitative Analysis of Soft Tissue Structures

	Group A2 (Low Dose, Bone Kernel, Soft Tissue Window)	Group B2 (Standard Dose, Bone Kernel, Soft Tissue Window)	Group A3 (Low Dose, Soft Tissue Kernel, Soft Tissue Window)	κ value	p-Value	A2 vs. B2	A2 vs. A3	B2 vs. A3
Medial rectus muscle								
0.6								
Observer 1	3.49 ± 0.62	4.20 ± 0.72	4.07 ± 0.67	<0.001*	<0.001	<0.001	0.415	
Observer 2	3.55 ± 0.52	4.25 ± 0.54	4.44 ± 0.64	<0.001*	<0.001	<0.001	0.312	
Optic nerve								
0.53								
Observer 1	3.53 ± 0.52	4.38 ± 0.54	4.25 ± 0.66	<0.001*	<0.001	<0.001	0.323	
Observer 2	3.48 ± 0.50	4.15 ± 0.66	4.25 ± 0.66	<0.001*	<0.001	<0.001	0.084	

*No statistical significant difference between Group B2 and Group A3.

DISCUSSION

Low-dose facial CT using low tube voltage (80 kVp) reconstructed by FBP enabled radiation dose reduction by up to 76.9% compared to that using 120 kVp. The image quality of the bone and soft tissue was maintained using bone and soft tissue kernels.

Several attempts have been made to reduce radiation dose while maintaining the image quality in facial CT (20). It is important to reduce radiation dose when undergoing facial CT because radiosensitive structures, such as lens of the eye, may be exposed to direct or scattered radiation (21). One of the drawbacks of the low tube voltage CT protocol is the increased image noise (5). In our study, the background image noise of LDCT was 67% higher than that of standard dose CT (SDCT).

Recently developed CT scanners can apply techniques, such as IR, to reduce image noise in LDCT (5). However, such techniques are not ubiquitous and are typically not available retroactively for older CT scanner models. The main strength of our study is that low-dose facial CT could maintain the image quality of the bone and soft tissue by simply adding soft tissue kernel images to conventional CT using FBP. To the best of our knowledge, this is the first study using low tube voltage and only FBP for low-dose facial CT in pediatric patients.

Based on several studies by Widmann et al. (8, 9, 11, 12), we adopted 80 kVp as the low tube voltage for pediatric facial CT; however, we did not use the fixed mAs because of concerns regarding the deterioration of image quality that might affect diagnosis. The main difference between the studies by Widmann et al. (8, 9, 11, 12) and our study was that we did not use IR and that we used LDCT in real pediatric patients, unlike Widmann et al. (8-12), who used cadavers.

The common conclusion of studies by Widmann et al. was that the ultra-low-dose protocol (fixed 80 kVp and fixed 40 mAs [CTDIvol = 2.64 mGy] with MBIR) was suitable for the diagnosis of facial/orbital fractures (8, 12) and visualization of orbital soft tissue (9).

Widmann et al. (9) reported that LDCT (2.64 mGy) with MBIR showed similar orbital soft tissue visibility as the reference dose protocol (36.69 mGy) with FBP. The quantitative analysis showed that SNR and CNR of soft tissues in Group A2 (LDCT, bone kernel, soft tissue setting) had the lowest score among the three groups (A2, B2, and A3), i.e., the worst image quality for soft tissue assessment. Facial CT after trauma should be suitable for evaluating soft tissues as well as the bone. To overcome the deterioration in the image quality of soft tissues in LDCT, we used the soft tissue kernel in addition to the bone kernel. Image noise and spatial resolution are affected by the choice of the reconstruction kernel (22). The soft tissue kernel, which is suitable for low contrast structures, showed lower image noise and spatial resolution compared to the bone kernel. As expected, the SNR and CNR of Group A3 (LDCT, soft tissue kernel, soft tissue setting) showed the highest score among all three groups. However, the qualitative analysis did not reveal any significant difference between Group B2 (SDCT, bone kernel, soft tissue setting) and A3. Thus, we concluded that Group A3 would be sufficient to replace Group B2.

When comparing the image quality of bony structures, LDCT using bone kernel had similar or higher scores compared with SDCT using bone kernel from the nasal and orbital bones. At lower tube voltage settings, the CT attenuation of the bone, having a higher atomic

number, increases because of the greater photoelectric effect. Additionally, image noise does not deteriorate the diagnostic performance in low tube voltage settings while evaluating a high-contrast structure such as the bone (5).

Widmann et al. (12) reported that when they used ASIR and MBIR for maintaining diagnostic quality, low-dose facial CT with CTDIvol of 1.0 mGy was sufficient for the detection of dislocated craniofacial fractures, while CTDIvol of 2.6 mGy was suitable for the detection of non-dislocated craniofacial fractures. Nevertheless the smoothing effect of IR is limited with respect to improving fracture detection rate.

This study has a few limitations. First, SDCT images, which were reconstructed by soft tissue kernel were not evaluated. This was a retrospective study, and the soft tissue kernel was not used for CT performed before the introduction of LDCT protocol in our institution. Although the soft tissue kernel was not used in clinical practice, it was easy to evaluate the soft tissue by adjusting the window display settings. The lack of a significant difference between Group B2 and A3 in the qualitative analysis conducted in this study supports the fact that the soft tissue kernel image is not essential in SDCT. Second, only pediatric patients younger than 10 years were included in our study because 100 kVp is used for facial CT in children aged above 10 years. Further studies that include adolescents and adults are needed to generalize our protocols.

In conclusion, LDCT with bone kernel images showed similar or higher image quality of bony structures compared with SDCT with bone kernel images. And LDCT with soft tissue kernel images showed similar image quality to that of SDCT with bone kernel and soft tissue window setting. So the addition of the soft tissue kernel image to conventional CT reconstructed by FBP enabled the using low-dose facial CT protocol while maintaining image quality.

Author Contributions

Conceptualization, Y.S.K., O.J.Y.; data curation, Y.S.K., J.H.; formal analysis, Y.S.K., J.H.; investigation, Y.S.K., J.H.; methodology, Y.S.K., J.H.; project administration, Y.S.K., J.H.; resources, Y.S.K., J.H.; software, Y.S.K., L.J.E.; supervision, L.J.E., O.J.Y.; validation, L.S.M., C.H.; visualization, Y.S.K., J.H., O.J.Y.; writing—original draft, Y.S.K., J.H., O.J.Y.; and writing—review & editing, L.J.E., L.S.M., C.H.

Conflicts of Interest

The authors have no potential conflicts of interest to disclose.

Funding

None

REFERENCES

1. Achenbach S, Boehmer K, Pflederer T, Ropers D, Seltmann M, Lell M, et al. Influence of slice thickness and reconstruction kernel on the computed tomographic attenuation of coronary atherosclerotic plaque. *J Cardiovasc Comput Tomogr* 2010;4:110-115
2. Miglioretti DL, Johnson E, Williams A, Greenlee RT, Weinmann S, Solberg LI, et al. The use of computed tomography in pediatrics and the associated radiation exposure and estimated cancer risk. *JAMA Pediatr* 2013;167:700-707
3. Zacharias C, Alessio AM, Otto RK, Iyer RS, Philips GS, Swanson JO, et al. CT: strategies to lower radiation dose. *AJR Am J Roentgenol* 2013;200:950-956
4. Czechowski J, Janeczek J, Kelly G, Johansen J. Radiation dose to the lens in sequential and spiral CT of the facial bones and sinuses. *Eur Radiol* 2001;11:711-713

5. Nagayama Y, Oda S, Nakaura T, Tsuji A, Urata J, Furusawa M, et al. Radiation dose reduction at pediatric CT: use of low tube voltage and iterative reconstruction. *Radiographics* 2018;38:1421-1440
6. Gottumukkala RV, Kalra MK, Tabari A, Otrakji A, Gee MS. Advanced CT techniques for decreasing radiation dose, reducing sedation requirements, and optimizing image quality in children. *Radiographics* 2019;39:709-726
7. Lira D, Padole A, Kalra MK, Singh S. Tube potential and CT radiation dose optimization. *AJR Am J Roentgenol* 2015;204:W4-W10
8. Widmann G, Dalla Torre D, Hoermann R, Schullian P, Gassner EM, Bale R, et al. Detection of midfacial and orbital fractures using ultralow dose CT and iterative reconstructions. Proceedings of the European Congress of Radiology-ECR 2015; 2015 Mar 4-8; Vienna: Austria: ECR; 2015:B-1244
9. Widmann G, Juranek D, Waldenberger F, Schullian P, Dennhardt A, Hoermann R, et al. Influence of ultralow-dose and iterative reconstructions on the visualization of orbital soft tissues on maxillofacial CT. *AJNR Am J Neuroradiol* 2017;38:1630-1635
10. Widmann G, Bischel A, Stratis A, Bosmans H, Jacobs R, Gassner EM, et al. Spatial and contrast resolution of ultralow dose dentomaxillofacial CT imaging using iterative reconstruction technology. *Dentomaxillofac Radiol* 2017;46:20160452
11. Widmann G, Schullian P, Hoermann R, Gassner EM, Riechelmann H, Bale R, et al. Ultralow dose CT imaging for navigated skull base surgery using ASIR and MBIR-2D and 3D image quality. *J Neurol Surg B Skull Base* 2014;75:a229
12. Widmann G, Dalla Torre D, Hoermann R, Schullian P, Gassner EM, Bale R, et al. Ultralow-dose computed tomography imaging for surgery of midfacial and orbital fractures using ASIR and MBIR. *Int J Oral Maxillofac Surg* 2015;44:441-446
13. Muschelli J. Recommendations for processing head CT data. *Front Neuroinform* 2019;13:61
14. Singh S, Kalra MK, Thrall JH, Mahesh M. Pointers for optimizing radiation dose in head CT protocols. *J Am Coll Radiol* 2011;8:591-593
15. Reshetenko TV, St-Pierre J, Artyushkova K, Rocheleau R, Atanassov P, Bender G, et al. Multianalytical study of the PTFE content local variation of the PEMFC gas diffusion layer. *J Electrochem Soc* 2013;160:F1305
16. Paul J, Krauss B, Banckwitz R, Maentele W, Bauer RW, Vogl TJ. Relationships of clinical protocols and reconstruction kernels with image quality and radiation dose in a 128-slice CT scanner: study with an anthropomorphic and water phantom. *Eur J Radiol* 2012;81:e699-e703
17. Judy PF, Swensson RG. Detection of small focal lesions in CT images: effects of reconstruction filters and visual display windows. *Br J Radiol* 1985;58:137-145
18. Weiss KL, Cornelius RS, Greeley AL, Sun D, Chang IY, Boyce WO, et al. Hybrid convolution kernel: optimized CT of the head, neck, and spine. *AJR Am J Roentgenol* 2011;196:403-406
19. Wang Y, de Bock GH, van Klaveren RJ, van Ooyen P, Tukker W, Zhao Y, et al. Volumetric measurement of pulmonary nodules at low-dose chest CT: effect of reconstruction setting on measurement variability. *Eur Radiol* 2010;20:1180-1187
20. Hooper T, Eccles G, Milliken T, Mathieu-Burry JR, Reed W. Dose reduction in CT imaging for facial bone trauma in adults: a narrative literature review. *J Med Radiat Sci* 2019;66:122-132
21. Sohaib SA, Peppercorn PD, Horrocks JA, Keene MH, Kenyon GS, Reznick RH. The effect of decreasing mAs on image quality and patient dose in sinus CT. *Br J Radiol* 2001;74:157-161
22. Greffier J, Frandon J, Larbi A, Om D, Beregi JP, Pereira F. Noise assessment across two generations of iterative reconstruction algorithms of three manufacturers using bone reconstruction kernel. *Diagn Interv Imaging* 2019;100:763-770

필터보정역투영과 적절한 커널을 이용한 소아 저선량 안면 컴퓨터단층촬영의 시행 가능성

지 헤¹ · 유선경² · 이정은² · 이소미³ · 조현혜⁴ · 엄준영^{1*}

목적 필터보정역투영(filtered back projection; 이하 FBP)법과 적절한 커널로 재구성된 소아 저선량 안면 컴퓨터단층촬영(이하 CT)의 시행 가능성을 평가하고자 한다.

대상과 방법 응급실에서 안면 CT를 촬영한 10세 이하 환자의 임상 및 영상 데이터를 후향적으로 검토하였다. 환자들을 두 그룹으로 나누었다: 고정된 80 kVp와 자동관전류변조기법을 사용하는 저선량 CT (low-dose CT, 그룹 A, $n = 73$), 고정된 120 kVp와 자동관전류변조기법을 사용하는 표준 선량 CT (standard-dose CT, 그룹 B, $n = 40$). 모든 영상은 FBP로 재구성되었다. 그룹 A는 뼈와 연조직 커널을, 그룹 B는 뼈 커널을 이용하였다. 두 그룹의 영상 잡음, 신호대잡음비(signal-to-noise ratio; 이하 SNR), 그리고 대조대잡음비(contrast-to-noise ratio; 이하 CNR)를 비교하였다. 두 명의 영상의학과 의사가 뼈와 연조직의 영상 품질에 대해 주관적으로 점수화하였다. 용적 CT 선량지수(CT dose index volume)와 선량길이곱(dose length product)을 기록하였다.

결과 영상 잡음은 그룹 A가 그룹 B보다 높았다($p < 0.001$). 연조직 커널을 사용한 그룹 A 영상에서 가장 높은 SNR과 CNR을 보였다($p < 0.001$). 뼈의 정성적 평가에서 뼈 커널 영상들을 비교하면 그룹 A가 그룹 B보다 비슷하거나 높은 점수를 보였다. 연조직의 정성적 평가에서 연조직 커널을 이용한 그룹 A와 뼈 커널에 연조직 창 설정을 이용한 그룹 B 사이에는 통계적으로 유의한 차이가 없었다($p > 0.05$). 그룹 A는 그룹 B에 비해 방사선 선량이 76.9% 감소했다(3.2 ± 0.2 mGy vs. 13.9 ± 1.5 mGy, $p < 0.001$).

결론 연조직 커널 영상을 FBP로 재구성된 전통적인 CT에 추가함으로써 영상 품질을 유지하면서 소아 저선량 안면 CT 프로토콜을 사용할 수 있다.

¹충남대학교병원 영상의학과,

²충남대학교 의과대학 충남대학교병원 영상의학과,

³경북대학교 의과대학 칠곡경북대학교병원 영상의학과,

⁴이화여자대학교 목동병원 영상의학과