




Tissue Expanders in Staged Calvarial Reconstruction: A Systematic Review

Andrea Y. Lo, BS¹ Roy P. Yu, BS¹ Anjali C. Raghuram, BA¹ Michael N. Cooper, MS¹
Holly J. Thompson, MSLIS² Charles Y. Liu, MD, PhD³ Alex K. Wong, MD^{1,4} 

¹Division of Plastic and Reconstructive Surgery, Keck School of Medicine of University of South California, Los Angeles, California

²Wilson Dental Library, Herman Ostrow School of Dentistry of University of South California, Los Angeles, California

³Department of Neurological Surgery, Keck School of Medicine of University of South California, Los Angeles, California

⁴Division of Plastic Surgery, City of Hope National Medical Center, Duarte, California

Address for correspondence Alex K. Wong, MD, 1500 East Duarte Road, Duarte, CA 91010 (e-mail: alexwong@coh.org).

Arch Plast Surg 2022;49:729–739.

Abstract

Cranioplasties are common procedures in plastic surgery. The use of tissue expansion (TE) in staged cranioplasties is less common. We present two cases of cranioplasties with TE and systematically review literature describing the use of TE in staged cranioplasties and postoperative outcomes. A systematic review was performed by querying multiple databases. Eligible articles include published case series, retrospective reviews, and systematic reviews that described use of TE for staged bony cranioplasty. Data regarding study size, patient demographics, preoperative characteristics, staged procedure characteristics, and postoperative outcomes were collected. Of 755 identified publications, 26 met inclusion criteria. 85 patients underwent a staged cranioplasty with TE. Average defect size was 122 cm², and 30.9% of patients received a previous reconstruction. Average expansion period was 14.2 weeks. The most common soft tissue closures were performed with skin expansion only (75.3%), free/pedicled flap (20.1%), and skin graft (4.7%). The mean postoperative follow-up time was 23.9 months. Overall infection and local complication rates were 3.53 and 9.41%, respectively. The most common complications were cerebrospinal fluid leak (7.1%), hematoma (7.1%), implant exposure (3.5%), and infection (3.5%). Factors associated with higher complication rates include the following: use of alloplastic calvarial implants and defects of congenital etiology ($p = 0.023$ and 0.035 , respectively). This is the first comprehensive review to describe current practices and outcomes in staged cranioplasty with TE. Adequate soft tissue coverage contributes to successful cranioplasties and TE can play a safe and effective role in selected cases.

Keywords

- ▶ plastic surgery
- ▶ cranioplasty
- ▶ tissue expander
- ▶ calvarium

received

July 21, 2021

accepted after revision

March 25, 2022

DOI <https://doi.org/>

10.1055/s-0042-1751104.

eISSN 2234-6171.

© 2022. The Korean Society of Plastic and Reconstructive Surgeons. All rights reserved.

This is an open access article published by Thieme under the terms of the Creative Commons Attribution-NonDerivative-NonCommercial-License, permitting copying and reproduction so long as the original work is given appropriate credit. Contents may not be used for commercial purposes, or adapted, remixed, transformed or built upon. (<https://creativecommons.org/licenses/by-nc-nd/4.0/>)

Thieme Medical Publishers, Inc., 333 Seventh Avenue, 18th Floor, New York, NY 10001, USA

Introduction

Cranioplasties have become a common collaborative procedure performed by plastic surgeons and various specialties such as neurosurgeons, otolaryngologists, and oral maxillofacial surgeons. Studies have shown that cranioplasty following decompressive craniectomy provides necessary protection against the development of sinking skin flap syndrome, also known as syndrome of the trephined and improves neurological performance by normalizing cerebral hemodynamics.¹⁻³ Additionally, early cranioplasties, when combined with programmable shunts, reduce the number of required surgical procedures and complications, while providing restoration of normal appearance and patient satisfaction.⁴ While commonly performed after decompressive craniectomies, cranioplasty is also performed to treat a variety of defects including, but not limited to, congenital defects such as aplasia cutis congenita and defects observed after tumor resection.

Tissue expansion (TE) is a modality that is widely employed in plastic surgery as a mean to provide adequate soft tissue coverage for a wound defect. It has been utilized in a variety of anatomic areas but most frequently for breast and trunk due to relatively loose skin in these areas.⁵ In the head and neck region, scalp TE is effective and commonly employed for areas of alopecia.⁶ In breast reconstruction, tissue expanders have been shown to result in significantly decreased rates of skin flap necrosis and reoperation, when compared with direct to implant reconstructive efforts.⁷ Additionally, tissue expanders used to aid in closure of large defects in the trunk and extremities have shown to provide good functional and satisfactory cosmetic results.⁸ While TE is a standard practice in these aforementioned reconstructive applications, its role in staged cranioplasties, where soft tissue coverage may be limited, is less established. To address this knowledge gap, we present two cases of cranioplasty using a staged tissue expander approach, followed by a systematic review of current practices and outcomes of two-staged cranioplasties.

Cases

Case 1

A 37-year-old male with history of a motor vehicle accident 15 years prior, presently showing postmultiple cranioplasties, with the last revision involving a titanium plate replacement done at an outside hospital 4 years prior to presentation, was referred to the plastic surgery service for consultation and management of a scalp wound with exposed hardware. The patient first noticed exposed plate and a wound at the vertex of his scalp at the junction of his skin flap and native skin 2 months ago. A 6 cm × 4 cm area of exposed skin with an exposed titanium mesh plate and area of alopecia surrounding the craniotomy incision was noted on physical examination. The area of exposure was dry with no drainage from the plate. At the time, the patient reported no symptoms of systemic infection and was an otherwise healthy nonsmoker with no major comorbidities. He was taken to the operating room for removal of his right titanium mesh followed by a complex closure of the scalp. Following

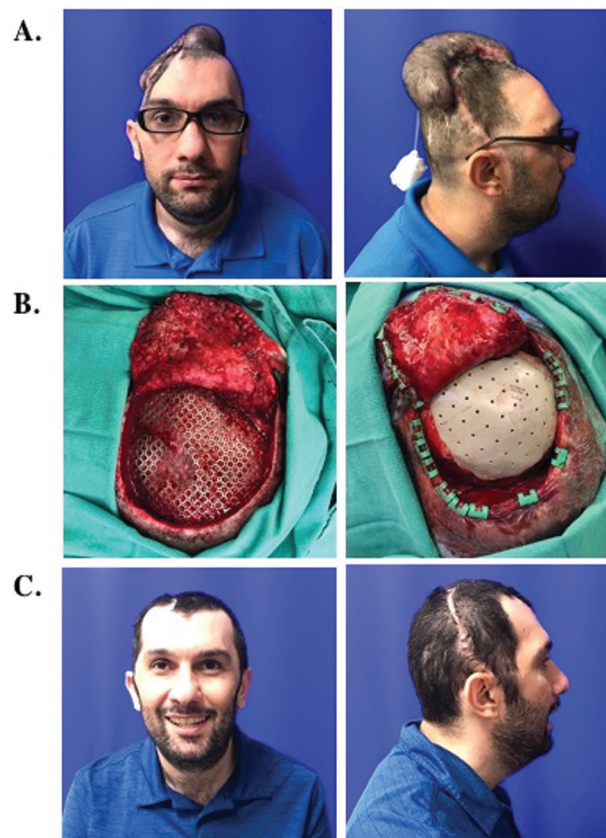


Fig. 1 Case 1. (A) Preoperative tissue expansion. (B) Intraoperative cranioplasty with placement of custom polyether ether ketone (PEEK) implant at 6 months following insertion of tissue expander. (C) Postoperative result at 1 year following secondary cranioplasty.

implant removal, a staged calvarial reconstruction with tissue expander was planned and after 2.5 months, a 15-cm crescent-shaped tissue expander was placed (►Fig. 1A). The tissue expander was gradually expanded over a 5-month period at approximately to a total approximate volume of around 210 cc to accommodate for the planned hardware. Six months following placement, the tissue expander was removed and a custom polyether ether ketone (PEEK) implant along with two no. 10 round Blake drains was placed as well (►Fig. 1B). Drains were removed approximately 2 weeks postoperatively. Six weeks following his secondary cranioplasty, the patient developed a seroma; however, on inspection, the implant was found to be intact with no evidence of damage, leaks, or infection. The seroma was incised and drained, and the implant area was irrigated well before closure. No other complications were reported and the patient has since followed-up twice with the plastic surgeon to remedy residual temporal skull defects with fat grafting. Final cosmetic results at 1 year following the patient's secondary cranioplasty can be seen in ►Fig. 1C.

Methods

A systematic literature search was completed according to the Preferred Reporting Items for Systematic Review and Meta-analysis Protocols (PRISMA-P) guidelines.⁹ The

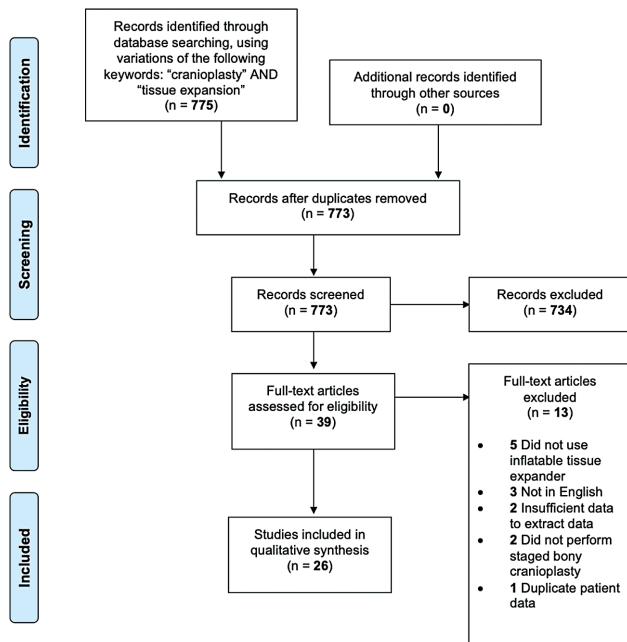


Fig. 2 PRISMA flow chart. PRISMA, Preferred Reporting Items for Systematic Review and Meta-analysis.

algorithm for article identification, screening, and review is shown in ▶**Fig. 2**. PubMed, Embase, Cochrane Library, Web of Science, and Scopus were queried without any publication date limit in July 2019. The queries used a combination of search terms, the included variations of the following keywords: "cranioplasty" AND "tissue expander." Inclusion and exclusion criteria are presented in ▶**Table 1**. To eliminate bias, two authors independently screened all articles for inclusion or exclusion, and in the case of a conflict, a third author screened as a tiebreaker.

Table 1 Inclusion and exclusion criteria

Inclusion criteria	
•	Articles published in English containing any of the following search terms: "cranioplasty," "calvarium reconstruction," "scalp reconstruction," "tissue expander," and "scalp expander"
•	Articles describing cranioplasty/calvarial reconstruction AND use of tissue expander
•	Systematic reviews, literature reviews, case reports/series, retrospective and prospective studies
Exclusion criteria	
•	Articles not published in English
•	No full text availability
•	Studies where patients underwent soft tissue or scalp reconstruction not involving the calvarium
•	Animal or non-human studies
•	Letters, comments, and editorials

Data Extraction and Analysis

From articles that met the inclusion criteria, the following data elements were extracted: study specifications, patient demographics, preoperative characteristics, bone defect characteristics, timing between initial debridement/neurosurgery and TE placement, TE characteristics including length of time of the TE remained in place, surgery details, implant specifications, and postoperative outcomes. Study specifications consisted of lead author, publication year, and study design. The patient demographic data collected included the number of patients who underwent a cranioplasty involving a two-stage tissue expander, average patient age, and comorbidities, such as smoking, diabetes, and obesity. The characteristics of the bone defect that were abstracted include location, size, and etiology of bone defect. Tissue expander characteristics noted include indication for use of a tissue expander, number of tissue expanders per patient, type of tissue expander, initial and final volume of tissue expander, and length of expansion. In terms of procedural details, the data abstracted included the patient's clinical diagnosis, neurological and/or cranioplasty procedures performed, number of patients with a previous reconstructive attempt, and method of soft tissue coverage. The implant specifications gathered included the type of calvarial implant, method of customization of calvarial implant, and length of the follow-up period. The systematic review extracted data about the following complications: infection, wound breakdown, implant exposure, hematoma, seroma, osteomyelitis, dehiscence, and cerebrospinal fluid (CSF) leak. The pooled complication rates were then graphed with a 95% confidence interval. Patient satisfaction and cosmesis were also recorded. Studies that did not report specific patient or procedural characteristics were removed from descriptive analysis for that data element.

Analyses of statistical significance between complication rates were performed considering the following variables: pediatric versus adult, defect size <100 cm² versus >100 cm², alloplastic versus autologous calvarial implants, congenital versus noncongenital defect, and trauma versus nontrauma-related defect. Complication rates were modeled as a Bernoulli's process that is approximated as a normal distribution via the Central Limit Theorem. The results were visualized on Microsoft Excel with error bars representing standard deviations (SDs) for each variable.

Results

Study Retrieval and Characteristics

▶**Fig. 2** summarizes the results of our literature search. A total of 775 articles were identified in the initial screening of which 2 were identified as duplicates and removed. We excluded 734 citations as irrelevant using the predefined inclusion and exclusion criteria (▶**Table 1**) and retrieved the full-length articles for the remaining 39 studies for secondary review. Of these 39 studies, 13 did not meet the eligibility criteria because 5 did not involve use of an inflatable tissue expander, 3 were not transcribed in English, 2 had insufficient data for extraction, 2 did not involve a staged bony cranioplasty, and 1 contained duplicate patient

Table 2 Demographic and preoperative characteristics

Study (year)	No. of patients	Age (y)	Comorbidities	Etiology of defect	Defect size (cm ²)	Previous attempt of reconstruction (no. of patients)
Akamatsu et al (2015) ¹⁰	1	8	None	Trauma	104.5	0
Argenta et al (1984) ¹¹	2	23.5 ± 26.2	None	1 Congenital 1 Tumor resection	Unknown	1
Argenta et al (1986) ²⁶	1	7	None	Congenital	156	1
Carlioni et al (2015) ¹²	5	49.8 ± 14.1	Hypertension, smoker, PE, phlebitis, MI, hypercholesterolemia, diabetes	1 Trauma 1 Decompressive craniotomy for vascular cerebral accident 3 Tumor resections	69.6 ± 41.8	5
Carlioni et al (2016) ¹³	1	30	None	1 Tumor resection	117	1
Cho et al (2012) ²⁷	1	47	None	Trauma	150	0
Cienfuegos et al (2018) ²⁸	2	27 ± 4.24	None	2 Trauma	177 ± 65.9	0
de Moraes et al (2017) ²⁹	1	26	None	Trauma	138	0
Dos Santos Rubio et al (2016) ³⁰	1	27	None	Trauma	Unknown	1
Goh (2004) ¹⁴	2	0.917	Conjoined twins	2 Congenital	200	0
Hadad et al (2016) ³¹	3	1.86 ± 0.59	None	3 Congenital	44 ± 38.2	0
Kasper et al (2012) ²⁴	2	29.5 ± 10.6	None	2 Trauma	Unknown	1
Komuro et al (2002) ²⁵	1	1	None	1 Congenital	36	0
Konofaos et al (2017) ³²	5	Unknown	Unknown	Unknown	Unknown	Unknown
Lin et al (2012) ¹⁵	3	Unknown	None	1 Trauma 1 Tumor resection 1 Functional neurosurgical procedure for intractable seizures	134 ± 46.4	3
Merlino and Carlucci (2015) ¹⁶	36	Unknown	None	19 Trauma 17 Diseased (unspecified)	Unknown	1
Miyazawa et al (2007) ¹⁷	1	55	None	1 Tumor resection	Unknown	0
Mokal and Desai (2001) ³³	1	Unknown	None	1 Trauma	Unknown	0
Mundinger et al (2016) ³⁴	6	33 ± 7.95	Diabetes	4 Trauma 1 Decompressive craniotomy for postruptured aneurysm 1 Functional neurosurgical procedure for intractable seizures	160 ± 18.2	6

Table 2 (Continued)

Study (year)	No. of patients	Age (y)	Comorbidities	Etiology of defect	Defect size (cm ²)	Previous attempt of reconstruction (no. of patients)
Nakano et al (2014) ³⁵	1	38	None	1 Epidural abscess	Unknown	0
Origitano et al (1995) ¹⁸	2	50 ± 21.2	None	1 Trauma 1 Tumor resection	110 ± 21.2	1
Ozaki et al (2017) ¹⁹	2	50 ± 18.4	None	2 Decompressive craniotomy for subarachnoid hemorrhages	Unknown	2
Cascone et al (2009) ²⁰	1	54	None	1 Trauma	Unknown	1
Sari et al (2017) ²¹	2	Unknown	None	Unknown	Unknown	Unknown
Tringali et al (2019) ²²	1	50	None	1 Osteomyelitis	Unknown	0
Zhai et al (2019) ²³	1	6	None	1 Trauma	60	1

Abbreviations: MI, myocardial infarction; PE, pulmonary embolism.
Note: Numbers are reported as mean ± standard deviation when possible.

data. The remaining 26 articles were included in the systematic review. Eligible articles included published case reports and series, retrospective reviews, and systematic reviews that described use of tissue expander for bony cranioplasty.

Preoperative Patient Characteristics

Patient preoperative characteristics identified in the included articles are provided in ►Table 2. In total, there were 85 patients included in our qualitative analysis of the 26 eligible articles. The leading indication for reconstruction was a traumatic defect (42.4%). Following traumatic defects, calvarial resection secondary to various diseases (such as tumors, cerebral vascular accidents, functional neurosurgical procedures for intractable seizures, abscesses, and osteomyelitis) was the second most common indication (40%). Congenital defects (9.4%) and other unspecified defects (8.2%) were the least common sources of defects. Defects ranged in size from 36 to 200 cm², with a mean defect size of 122 ± 55.5 cm². Patients ranged in age from 11 months to 54 years, with a mean age of 26.65 ± 20.07 years. Excluding four patients with unspecified prior surgical history, 25 patients (30.9%) had undergone at least one previous reconstruction.

Staged Cranioplasty Characteristics

Staged cranioplasty procedure characteristics are provided in ►Table 3. The mean final TE volume was 313 mL, and the average length of time a TE was placed was 14.2 ± 9.57 weeks. Regarding type of calvarial implant used in the procedure, 10.7% of patients received an autologous implant, while 89.3% received an alloplastic implant. With respect to type of soft tissue coverage performed, 75.3% of patients received skin expansion only,¹⁰⁻²⁵ 20% received additional scalp or pericranial flap coverage,^{11,18,26-35} and 4.7% received additional skin grafting^{31,33} to provide adequate skin coverage for the defect. Among those patients who received skin grafts, three patients (75%) received pericranial flap coverage as well.

Outcomes of Staged Cranioplasty Using Tissue Expander

The postoperative outcomes of staged cranioplasty using a TE are provided in ►Table 4. Among all studies, mean follow-up time ranged from 1 to 120 months. Among studies that provided individual patient data, mean follow-up time was 23.9 + 27.9 months.

Postoperative complications are summarized in ►Fig. 3. Among all 85 patients from the studies included in this review, the local complication rate, excluding reoperations or CSF leaks, was 9.41%. Hematoma (7.06%) and CSF leak (7.06%) were the most common complications. The rates for infection and reoperation were both 3.53%, with a TE involved in reoperation at a rate of 1.18% and a non-TE reoperation rate of 2.35%. Both seroma and dehiscence occurred at a rate of 1.18%, respectively. Complication rates between pediatric and adult patients were comparable at 30.8 and 30.4%, respectively ($p = 0.49$; ►Fig. 4A). In our analysis, we also found that defect size (greater vs. less

Table 3 Staged procedure characteristics

Reference	Final TE volume (mL)	Length of time TE was placed (wk)	Calvarial implant	Soft tissue coverage
Akamatsu et al (2015) ¹⁰	290	16	Custom made hydroxyapatite	Skin expansion only
Argenta et al (1984) ¹¹	600	12	Autologous rib Methyl methacrylate	Skin expansion only Scalp flap
Argenta et al (1986) ²⁶	700	12	Autologous rib	Scalp flap
Carlioni et al (2015) ¹²	253 ± 51.7	10.1 ± 3.01	Custom made hydroxyapatite	Skin expansion only
Carlioni et al (2016) ¹³	243 ± 159	12	Custom made hydroxyapatite	Skin expansion only
Cho et al (2012) ²⁷	950	9	Autologous rib	Scalp flap
Cienfuegos et al (2018) ²⁸	Unknown	Unknown	Polyether ether ketone	Scalp flap
de Moraes et al (2017) ²⁹	360	7	Castor oil	Scalp flap
Dos Santos Rubio et al (2016) ³⁰	80	8	Titanium	Pericranial flap
Goh (2004) ¹⁴	250	16 ± 5.66	Synthetic polymer	Skin expansion only
Hadad et al (2016) ³¹	323 ± 68.1	13.3 ± 2.31	Autologous bone graft from bony hyperostosis	Pericranial flaps with split thickness skin graft
Kasper et al (2012) ²⁴	Unknown	20	Polyethylene	Skin expansion only
Komuro et al (2002) ²⁵	Unknown	6	Autologous bone graft from parietal region	Skin expansion only
Konofaos et al (2017) ³²	Unknown	16	Custom made polyethylene	Scalp flap
Lin et al (2012) ¹⁵	Unknown	Unknown	Custom made polyethylene	Skin expansion only
Merlino and Carlucci (2015) ¹⁶	Unknown	Unknown	Standard polyethylene; Custom made polyethylene Custom made polyethylene/titanium	Skin expansion only
Miyazawa et al (2007) ¹⁷	450	11	Hydroxyapatite	Skin expansion only
Mokal and Desai (2001) ³³	Unknown	8	High density porous polyethylene	Scalp flap with skin graft
Mundinger et al (2016) ³⁴	300	Unknown	Polyether ether ketone	Scalp flap
Nakano et al (2014) ³⁵	Unknown	26	Solid-type artificial bone	Scalp flap
Origitano et al (1995) ¹⁸	Unknown	5 ± 1.41	Unknown	Skin expansion only Scalp flap
Ozaki et al (2017) ¹⁹	Unknown	16	Custom made polymethylmethacrylate	Skin expansion only
Cascone et al (2009) ²⁰	7.5 ± 3.54	8	Custom made hydroxyapatite	Skin expansion only
Sari et al (2017) ²¹	270	Unknown	Autologous bone graft	Skin expansion only
Tringali et al (2019) ²²	500	24	Custom made polymethylmethacrylate	Skin expansion only
Zhai et al (2019) ²³	250	60	Custom made polymethylmethacrylate	Skin expansion only

Abbreviation: TE, tissue expansion.

Note: Numbers are reported as mean ± standard deviation when possible.

than or equal to 100 cm²) did not significantly differ in complication rates with rates of 45.5 and 33.3%, respectively ($p = 0.25$, ►Fig. 4B). Type of calvarial implant significantly differed in complication rates, with alloplastic and autologous complication rates at 15.6% and 12.5%, respectively ($p = 0.023$; ►Fig. 5C). Among the alloplastic materials, polyethylene-based material was the most popular (59.5%), followed by hydroxyapatite (14.9%), polyether ether ketone

(10.8%), and polymethyl methacrylate (9.5%). There was one case that used castor oil polymer prosthesis, and the type of material was not specified in three cases. The highest complication rate among the alloplastic materials is seen in cases where custom made hydroxyapatite implants were used (54.5%) which included five hematomas and one implant exposure postoperatively. Cases that involved polyether ether ketone-based implants resulted in a 25% complication

Table 4 Outcomes of staged cranioplasty using tissue expander

Reference	Follow-up (mo)	Complications	Cosmesis
Akamatsu et al (2015) ¹⁰	50	None	Unknown
Argenta et al (1984) ¹¹	2	None	Unknown
Argenta et al (1986) ²⁶	12	1 Seroma	Unknown
Carloni et al (2015) ¹²	11 (range: 6–24)	1 implant exposure 5 Hematomas	Unknown
Carloni et al (2016) ¹³	Unknown	None	Unknown
Cho et al (2012) ²⁷	120	None	Good hair volume and distribution
Cienfuegos et al (2018) ²⁸	24	1 Infection	Shape of reconstructed area is symmetric
de Moraes et al (2017) ²⁹	28	None	Appropriate skull contour
Dos Santos Rubio et al (2016) ³⁰	Unknown	None	Good esthetic result
Goh (2004) ¹⁴	4	2 Infections 2 Reoperations of cranioplasties 1 CSF leak	significant residual calvarium defect was present but skin cover and healing was good
Hadad et al (2016) ³¹	33.3 ± 12.9	None	Unknown
Kasper et al (2012) ²⁴	Unknown	None	Cosmetically pleasing
Komuro et al (2002) ²⁵	4	1 Reoperation of cranioplasty	excellent cranial vault and scalp
Konofaos et al (2017) ³²	Unknown	2 Implant exposures	favorable long-term result was seen and was esthetically pleasing to both surgeon and patient
Lin et al (2012) ¹⁵	4.23 ± 2.49	None	good visual symmetry in 2 patients, temporal hollowing in 1 patient
Merlino and Carlucci (2015) ¹⁶	Unknown	1 Hematoma 5 CSF leaks	1 unsatisfactory symmetry with mild temporal bulging, otherwise good cosmesis
Miyazawa et al (2007) ¹⁷	7	None	Unknown
Mokal and Desai (2001) ³³	18	None	Excellent cosmesis
Munding et al (2016) ³⁴	21.9 (range: 2.7–80)	1 Wound dehiscence	Esthetic, durable results with acceptable head contour and head shape
Nakano et al (2014) ³⁵	Unknown	None	Esthetically good results in terms of contouring, minimum scarring, and hair coverage
Origitano et al (1995) ¹⁸	Unknown	None	Excellent cosmesis
Ozaki et al (2017) ¹⁹	54 ± 25.5	None	Unknown
Cascone et al (2009) ²⁰	12	None	Very good cosmesis
Sari et al (2017) ²¹	Unknown	Unknown	Good in all patients
Tringali et al (2019) ²²	12	None	Good
Zhai et al (2019) ²³	1	None	Favorable

Abbreviation: CSF, cerebrospinal fluid.

Note: Numbers are reported as mean ± standard deviation when possible.

rate, including one postoperative infection and one wound dehiscence. Cases that involved polyethylene, the most commonly reported implant material used, resulted in a 20% complication rate, including two postoperative implant exposures, one requiring reoperation, one hematoma, and five CSF leaks. No complications were reported in cases that involved polymethyl methacrylate material implants.

When stratified by etiology of defect, we also found that congenital defects had significantly higher complication rates compared with noncongenital defects at 3.13 versus 0.19%, respectively ($p = 0.035$; ► **Fig. 5A**). Lastly, we found that complication rates in cases with defects due to trauma (6.25%) were lower, however not statistically significant, from defects due to nontrauma (23.8%) etiology ($p = 0.057$; ► **Fig. 5B**).

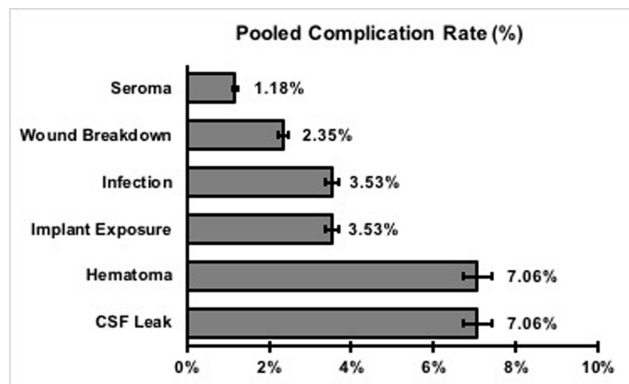


Fig. 3 Complication rates for patients receiving tissue expanded staged cranioplasty. Graphs represent average rate and bars represent the 95% confidence interval.

Discussion

Infection Rates of Staged Tissue Expanded Cranioplasties Are Relatively Low

Infection rates following cranioplasties, though variable, have been documented to be as high as 26%, as described in a retrospective review by Zanaty et al.³⁶ In the most recent systematic review of alloplastic cranioplasty reconstruction that included 3,591 patients, Oliver et al found that the overall infection rate seen after cranioplasties performed with allograft implants was 6.82%.³⁷ In our pooled analysis, we found that the average infection rate for patients who underwent a staged tissue-expanded cranioplasty was much lower at 3.5%. While our systematic review did not directly compare the results of tissue-expanded cranioplasties to that of single-staged cranioplasties, comparing our findings to similarly designed reviews in the current literature reveals that tissue-expanded staged cranioplasties have infection rates that are lower or at least comparable to those observed after traditional cranioplasties. It is unclear why the infection rate is notably lower with a staged technique. However, one theory could be that with staged procedures, there is better adherence to wound care, as frequent follow-up is necessary for the success of the procedure.

Complications Rates

In our systematic review, the local complication rate following a two-staged, tissue-expanded cranioplasties among 85 patients was 9.41%. Local complications included wound breakdown, implant exposure, hematoma, seroma, and dehiscence. This complication rate is still relatively low compared with the that seen in a recent large study of alloplastic cranioplasties Oliver et al which ranged from 11.31 to 17.19% depending on the type of alloplastic implant that was used.³⁷ Additionally, while CSF leaks and hematomas were the most common complications in our pooled analysis (7.06% for each), it is worth noting that our analysis included a case of two conjoined twins who each received complex two-staged cranioplasties.¹⁴ Although one twin developed infection during the time of TE, and both twins later developed infection and needed subsequent reoperation of the cranioplasties, the twins had adequate skin coverage and healing after 4 months of follow-up.¹⁴ We decided not to exclude this complex case from our study to demonstrate the wide variety of situations in which two-staged tissue expanded cranioplasties have been performed.

A total of 13 pediatric cases and 23 adult cases were explicitly identified in the studies we reviewed. While one can predict that TE in pediatric cases may not be safe or suitable due to their thin calvaria, complication rates between the two age groups were found to be comparable at 30.8 and 30.4% in the pediatric and adult subgroups, respectively ($p = 0.49$; ▶Fig. 4A). Yet, when cases were stratified by congenital versus noncongenital defects, we found that congenital defects had a significantly higher rate of complication compared with noncongenital defects at 3.13 versus 0.19%, respectively ($p = 0.035$; ▶Fig. 5A). This discrepancy is likely a factor of differences in sample sizes, since not all studies with multiple cases explicitly listed every patient's age. Additionally in our pediatric subgroup, we defined pediatric as age less than or equal to 18 years. Since most, if not all, congenital defects were repaired much earlier (during infant age), we can presume that the use of tissue expanders in this group likely poses significant risk for complications.

Another factor that may significantly affect complication rates is the type of calvarial implant used. In our subanalysis, we found that alloplastic implants were significantly

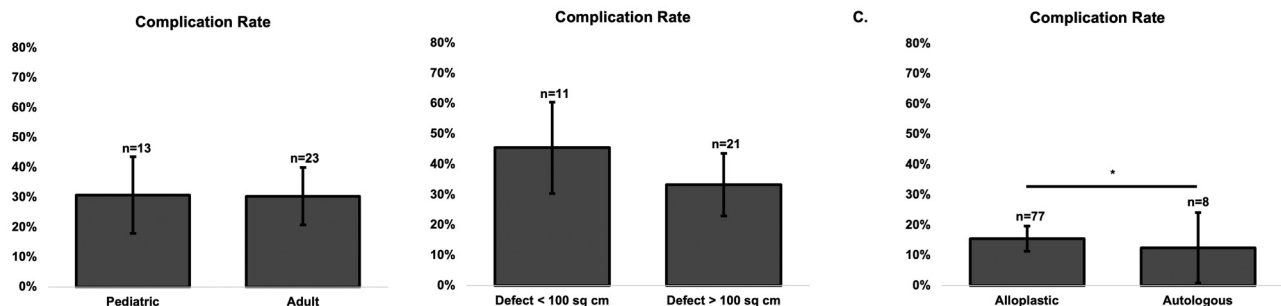


Fig. 4 Subanalyses of complication rates. (A) Complication rates for pediatric cases (30.8%, $n = 13$) vs. adult cases (30.4%, $n = 23$) are comparable ($p = 0.49$). (B) Complication rates for defect size $< 100 \text{ cm}^2$ (45.5%, $n = 11$) vs. $> 100 \text{ cm}^2$ (33.3%, $n = 21$) are not significantly different ($p = 0.253$). (C) Complication rates in patients receiving alloplastic calvarial implants (15.6%, $n = 77$) are significantly higher than those in patients receiving autologous calvarial implants (12.5%, $n = 8$) with $p = 0.023$. Numbers are reported as a proportion \pm standard deviation.

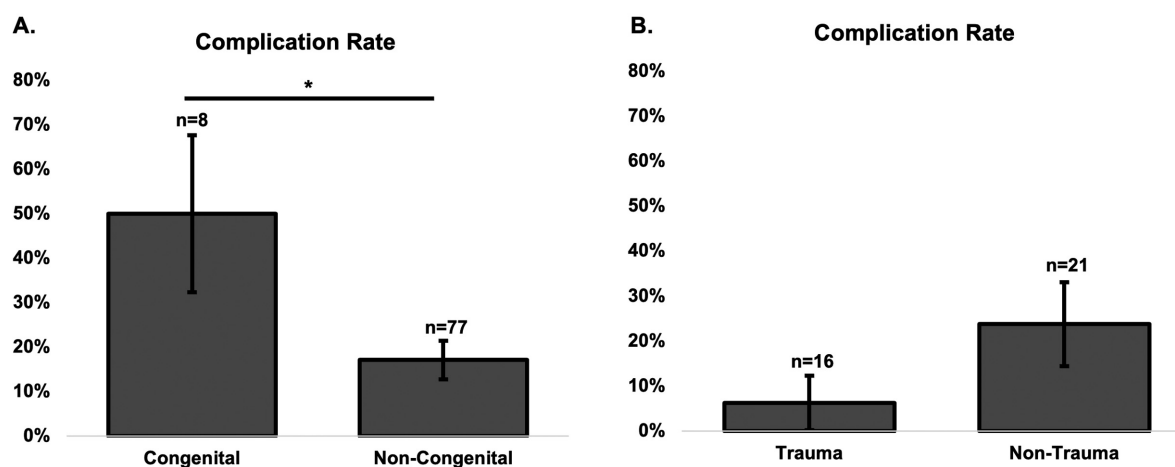


Fig. 5 Subanalyses of complication rates by etiology of defect. (A) Complication rates for congenital defects (3.13%, $n = 8$) are significantly higher than rates for noncongenital defects (0.19%, $n = 77$) with $p = 0.035$. (B) Complication rates for trauma related defects (6.25%, $n = 16$) are slightly lower than rates for nontrauma related defect (23.8%, $n = 21$), however are not significantly different ($p = 0.057$). Numbers are reported as a proportion \pm standard deviation.

associated with higher complication rates compared with autologous implants, with complication rates at 15.6 versus 12.5% in alloplastic versus autologous implants ($p = 0.023$; ►Fig. 4C). However, this statistic should be viewed with caution, as the sample sizes between the two groups differed vastly with alloplastic implants being more commonly used compared with autologous implants ($n = 77$ and 8, respectively). Among the eight cases that used autologous implants, only one postoperative complication occurred which was a seroma.

Timing of Tissue Expansion

In this review, we define tissue-expanded cranioplasties as traditional two-staged procedures. Not all studies reviewed provided information regarding the time between initial debridement/neurosurgery and TE placement. However, when provided, the timing varied greatly between 1 week and 1,040 weeks, with an average of 117.5 weeks (or 29.3 months) seen in 25 patient cases from the studies we reviewed. The average amount of time the scalp was expanded was 14.2 weeks (SD = 9.57 weeks) for an average defect size of 122 cm² (SD = 55.5 cm²). During our systematic review, we encountered two studies in which surgeons elected to expand the scalp intraoperatively prior to the calvarial reconstruction. Although we have excluded these two studies from our analysis, it is worth mentioning that some surgeons have performed these intraoperative scalp expansions with cosmetically favorable results. One case report describes a 30-minute intraoperative scalp expansion using a tissue expander for craniosynostosis surgery in a 14-month-old male.³⁸ While this method seems to require additional operating time for the TE, the surgeons reported that the extra 30-minute expansion period was utilized for preparing operating instruments, as well as the osteotomies and bone flaps, rendering almost no increased overall operating time. Additionally, the 30-minute expansion period expanded the

scalp enough to provide adequate coverage for the reconstruction. Similarly, Nichols and Bottini described a cranioplasty case that yielded excellent cosmetic results with a 30-minute expansion period to cover a 13.5 cm² defect in a newborn with aplasia cutis congenita.³⁹ Though these reported cases of intraoperative scalp expansion provided for excellent healing and cosmetic outcomes, both cases involved young patients with small defects.

Limitations

While tissue expanders are widely used in various reconstructive procedures, their use in bony cranioplasties is not as well standardized in the literature, and thus, our review is limited to the number of published articles on this surgical approach. The purpose of this systematic review was to assess the landscape and safety profile of performing calvarial reconstruction with a staged tissue expander approach. Of the 775 records identified through database searching, only 26 fully met our inclusion criteria, limiting our data analysis to 85 patients. Due to the differences in types of patient data presented among the included studies, our analysis of correlations between perioperative characteristics and postoperative complications was limited to two variables, that is, defect size and cranial implant type. Additionally, because we did not include articles that described cranioplasties without the use of tissue expanders, our pooled analyses cannot be used to directly compare the results of tissue-expanded cranioplasties to those seen in single-staged cranioplasties. Therefore, a meta-analysis was not performed.

Conclusion

This is the first comprehensive review of current published literature that describes the use of tissue expanders in staged

calvarial reconstructive procedures. Overall, staged tissue-expanded calvarial reconstruction is a safe procedure that yields relatively low complication and infection rates while providing esthetically acceptable results. Scalp expansion cannot only provide adequate soft tissue coverage of the wound but also may minimize scalp and implant related complications in patients with complex calvarial reconstruction.

Patient Consent

The patient provided written informed consent for the publication and the use of his images.

Author Contributions

A.Y.L.: conceptualization, data curation, formal analysis, methodology, project administration, preparing the original draft, and review and editing. R.P.Y.: data curation, formal analysis, investigation, methodology, and preparing the original draft. A.C.R.: data curation, formal analysis, investigation, methodology, and preparing the original draft. M.N.C.: conceptualization, methodology, and preparing the original draft. H.J.T.: methodology and preparing the original draft. C.Y.L.: supervision and visualization. A.K.W.: conceptualization, project administration, supervision, validation, visualization, and preparing the original draft.

Conflict of Interest

None declared.

Prior Presentation

This study was presented as follows:

- The 2020 California Society of Plastic Surgeons Scientific Meeting: August 7–9, 2020.
- American Association of Neurological Surgeons Annual Meeting: April 25–29, 2020.

References

- 1 Cho YJ, Kang SH. Review of cranioplasty after decompressive craniectomy. *Korean J Neurotrauma* 2017;13(01):9–14
- 2 Erdogan E, Düz B, Kocaoglu M, Izci Y, Sirin S, Timurkaynak E. The effect of cranioplasty on cerebral hemodynamics: evaluation with transcranial Doppler sonography. *Neurol India* 2003;51(04):479–481
- 3 Halani SH, Chu JK, Malcolm JG, et al. Effects of cranioplasty on cerebral blood flow following decompressive craniectomy: a systematic review of the literature. *Neurosurgery* 2017;81(02):204–216
- 4 Carvi Y, Nievas MN, Höllerhage HG. Early combined cranioplasty and programmable shunt in patients with skull bone defects and CSF-circulation disorders. *Neurol Res* 2006;28(02):139–144
- 5 Manders EK, Schenden MJ, Furrey JA, Hetzler PT, Davis TS, Graham WP III. Soft-tissue expansion: concepts and complications. *Plast Reconstr Surg* 1984;74(04):493–507
- 6 Baker SR, Swanson NA. Clinical applications of tissue expansion in head and neck surgery. *Laryngoscope* 1990;100(03):313–319
- 7 Basta MN, Gerety PA, Serletti JM, Kovach SJ, Fischer JP. A systematic review and head-to-head meta-analysis of outcomes following direct-to-implant versus conventional two-stage implant reconstruction. *Plast Reconstr Surg* 2015;136(06):1135–1144
- 8 Kirschke J, Georgas D, Sand M, Bechara FG. External tissue expander for closing large defects of the extremities and trunk. *J Cutan Med Surg* 2013;17(06):423–425
- 9 Moher D, Liberati A, Tetzlaff J, Altman DGPRISMA Group. Preferred reporting items for systematic reviews and meta-analyses: the PRISMA statement. *BMJ* 2009;339:b2535
- 10 Akamatsu T, Hanai U, Kobayashi M, et al. Cranial reconstruction in a pediatric patient using a tissue expander and custom-made hydroxyapatite implant. *Tokai J Exp Clin Med* 2015;40(02):76–80
- 11 Argenta LC. Controlled tissue expansion in reconstructive surgery. *Br J Plast Surg* 1984;37(04):520–529
- 12 Carloni R, Hersant B, Bosc R, Le Guerinel C, Meningaud JP. Soft tissue expansion and cranioplasty: for which indications? *J Craniomaxillofac Surg* 2015;43(08):1409–1415
- 13 Carloni R, Herlin C, Chaput B, De Runz A, Watier E, Bertheuil N. Scalp tissue expansion above a custom-made hydroxyapatite cranial implant to correct sequela alopecia on a transposition flap. *World Neurosurg* 2016;95:616.e1–616.e5
- 14 Goh KY. Separation surgery for total vertical craniopagus twins. *Childs Nerv Syst* 2004;20(8-9):567–575
- 15 Lin AY, Kinsella CR Jr, Rottgers SA, et al. Custom porous polyethylene implants for large-scale pediatric skull reconstruction: early outcomes. *J Craniofac Surg* 2012;23(01):67–70
- 16 Merlino G, Carlucci S. Role of systematic scalp expansion before cranioplasty in patients with craniectomy defects. *J Craniomaxillofac Surg* 2015;43(08):1416–1421
- 17 Miyazawa T, Azuma R, Nakamura S, Kiyosawa T, Shima K. Usefulness of scalp expansion for cranioplasty in a case with postinfection large calvarial defect: a case report. *Surg Neurol* 2007;67(03):291–295
- 18 Origitano TC, Izquierdo R, Scannicchio LB. Reconstructing complex cranial defects with a preformed cranial prosthesis. *Skull Base Surg* 1995;5(02):109–116
- 19 Ozaki M, Narita K, Kurita M, Iwashina Y, Takushima A, Harii K. Implantation of thickened artificial bone for reduction of dead space and prevention of infection between implant and dura in secondary reconstruction of the skull. *J Craniofac Surg* 2017;28(04):888–891
- 20 Cascone P, Gennaro P, Ramieri V, Esposito V. Forehead trauma outcomes: restoration of brain, soft tissues, and bone defects: a 3-step treatment. *J Craniofac Surg* 2009;20(02):498–501
- 21 Sari R, Tonge M, Bolukbasi FH, et al. Management of failed cranioplasty. *Turk Neurosurg* 2017;27(02):201–207
- 22 Tringali G, D'Ammando A, Bono B, Colombetti A, Franzini A. Two-staged frontal bone defect reconstruction: perioperative assessment of scalp vascularization using near-infrared indocyanine green video angiography (Visionsense Iridium). *World Neurosurg* 2019;126:502–507
- 23 Zhai Z, Yu L, Ren T, Jin X, Yang X, Qi Z. Use of vacuum-assisted wound closure and tissue expansion in revision cranioplasty for a large-sized composite defect in a child. *J Craniofac Surg* 2019;30(03):838–840
- 24 Kasper EM, Ridgway EB, Rabie A, Lee BT, Chen C, Lin SJ. Staged scalp soft tissue expansion before delayed allograft cranioplasty: a technical report. *Neurosurgery* 2012;71(1, suppl operative):15–20
- 25 Komuro Y, Yanai A, Seno H, et al. Surgical treatment of aplasia cutis congenita of the scalp associated with bilateral coronal synostosis. *J Craniofac Surg* 2002;13(04):513–519
- 26 Argenta LC, Dingman RO. Total reconstruction of aplasia cutis congenita involving scalp, skull, and dura. *Plast Reconstr Surg* 1986;77(04):650–653
- 27 Cho JY, Jang YC, Hur GY, et al. One stage reconstruction of skull exposed by burn injury using a tissue expansion technique. *Arch Plast Surg* 2012;39(02):118–123
- 28 Cienfuegos R, Fernández G, Cruz A, Sierra E. Cranial bone reconstruction with customized implants after trauma [in Spanish]. *Cir Cir* 2018;86(03):289–295

- 29 de Moraes SLC, Afonso AMP, Santos RGD, Mattos RP, Duarte EBG. Reconstruction of the cranial vault contour using tissue expander and castor oil prosthesis. *Craniofacial Trauma Reconstr* 2017;10(03):216-224
- 30 Dos Santos Rubio EJ, Bos EM, Dammers R, Koudstaal MJ, Dumans AG. Two-stage cranioplasty: tissue expansion directly over the craniectomy defect prior to cranioplasty. *Craniofacial Trauma Reconstr* 2016;9(04):355-360
- 31 Hadad I, Meara JG, Rogers-Vizena CR. A novel local autologous bone graft donor site after scalp tissue expansion in aplasia cutis congenita. *J Craniofac Surg* 2016;27(04):904-907
- 32 Konofaos P, Thompson RH, Wallace RD. Long-term outcomes with porous polyethylene implant reconstruction of large craniofacial defects. *Ann Plast Surg* 2017;79(05):467-472
- 33 Mokal NJ, Desai MF. Calvarial reconstruction using high-density porous polyethylene cranial hemispheres. *Indian J Plast Surg* 2011;44(03):422-431
- 34 Munding GS, Latham K, Friedrich J, et al. Management of the repeatedly failed cranioplasty following large postdecompressive craniectomy: establishing the efficacy of staged free latissimus dorsi transfer/tissue expansion/custom polyetheretherketone implant reconstruction. *J Craniofac Surg* 2016;27(08):1971-1977
- 35 Nakano T, Yoshikawa K, Kunieda T, et al. Treatment for infection of artificial dura mater using free fascia lata. *J Craniofac Surg* 2014;25(04):1252-1255
- 36 Zanaty M, Chalouhi N, Starke RM, et al. Complications following cranioplasty: incidence and predictors in 348 cases. *J Neurosurg* 2015;123(01):182-188
- 37 Oliver JD, Banuelos J, Abu-Ghname A, Vyas KS, Sharaf B. Alloplastic cranioplasty reconstruction: a systematic review comparing outcomes with titanium mesh, polymethyl methacrylate, polyether ether ketone, and norian implants in 3591 adult patients. *Ann Plast Surg* 2019;82(5S, suppl 4):S289-S294
- 38 Onishi K, Maruyama Y, Seiki Y. Intra-operative scalp expansion for wound closure without tension in craniosynostosis operation-technical innovation. *J Craniofacial Surg* 1995;23(05):317-320
- 39 Nichols DD, Bottini AG. Aplasia cutis congenita. Case report. *J Neurosurg* 1996;85(01):170-173