



Foreign body aspirations in dental clinics: a narrative review

Jin-Young Huh

Division of Pulmonary, Allergy and Critical Care Medicine, Department of Internal Medicine, Chung-Ang University Gwang-Myeong Hospital, Chung-Ang University College of Medicine, Gwang-Myeong, Republic of Korea

Foreign body aspiration can produce a medical emergency. Obstruction of the airways can be life-threatening, and complications may develop in less-severe cases if it is left untreated. Although it is more prevalent in children by approximately three times, adults can still experience it, and it is more frequently related to healthcare in adults. Objects used in dental treatment are usually placed in the oral cavity and can be ingested or inhaled by accident. Dental treatment has been identified as an important cause of the misplacement of foreign bodies in the airway. However, few reports have been published on dentistry-related foreign body aspiration. This paper discusses the disease course, management, and clinical outcomes of foreign body aspiration, especially those associated with dentistry. The patient must be examined for respiratory distress. If the patient is unstable, urgent airway management and the maneuvers for removal should be performed. Radiographs and computed tomography can help identify and locate the object. The treatment of choice is often bronchoscopy, and both flexible and rigid endoscopes can be used depending on the situation. Preventive measures need to be implemented to avoid inhalation accidents given the potential consequences. Though the incidence is rare, healthcare levels need to be enhanced to avert morbidity and mortality. Radiological evaluation and bronchoscopy are vital for management.

Keywords: Bronchoscopy; Dentistry; Foreign Bodies; Inhalation.

This is an Open Access article distributed under the terms of the Creative Commons Attribution Non-Commercial License (<http://creativecommons.org/licenses/by-nc/4.0/>) which permits unrestricted non-commercial use, distribution, and reproduction in any medium, provided the original work is properly cited.

INTRODUCTION

Foreign body aspiration may require urgent medical attention. If an object obstructs the airway completely and management is delayed, the patient could die or suffer hypoxic brain injuries [1,2]. Recognizing an event and providing appropriate care can be lifesaving. Unnoticed aspiration accidents can lead to various pulmonary complications [3,4].

Objects related to dental practice are vulnerable to aspiration because of their position in the oral cavity. In

dental clinics, events can occur regardless of the time or type of procedure. These critical events require prompt referral in dentistry [5,6]. As in other foreign body aspiration cases, dentistry-related aspirations also require timely intervention because the medical consequences can include a critical state or death in severe cases [7,8]. Prevention and management measures must be in place; otherwise, practitioners may be held liable for various claims [9,10].

Few reports on foreign body aspiration in dental clinics and associated medical departments have appeared in the literature, despite the importance of understanding it, and

Received: April 1, 2022 • Revised: May 15, 2022 • Accepted: May 17, 2022

Corresponding Author: Jin-Young Huh, Division of Pulmonary, Allergy and Critical Care Medicine, Department of Internal Medicine, Chung-Ang University College of Medicine, Gwang-Myeong Hospital, 110, Deokan-ro, Gwangmyeong-si, Gyeonggi-do, Republic of Korea
Phone: +82-2-2610-6669 Fax: +82-2-2610-6624 E-mail: huhjy@caumc.or.kr

Copyright© 2022 Journal of Dental Anesthesia and Pain Medicine

Table 1. Incidence of ingestion or aspiration in dental clinics

Report (Author, year of publication)	Number of ingestion cases	Number of aspiration cases	Duration of the study period	Number of patients treated in the clinic
Susini et al., 2007 [22]	464	44	11 years	24651
Hisanaga et al., 2010 [12]	11	0	1 year	933.1 per day
*Obinata et al., 2011 [11]	23	0	5 years	NA
Tiwana et al., 2004 [24]	25	1	10 years	100000 per year on average
†Hisanaga et al., 2014 [23]	39	1	4 years	NA

*, incidence of ingestion was 0.0037% per year; †, incidence of ingestion or aspiration was 0.0044% per year; NA, not available.

no consensus regarding its management has emerged. Complications and prognoses are not well-known. Thus, this narrative review discusses the disease course, treatment modalities, and outcomes of dental object inhalation.

INCIDENCE

Most of the foreign bodies that enter beyond the oral cavity tract are ingested into the gastrointestinal tract, and only a small percentage is aspirated into the airway [5,11, 12], due to the anatomy of the pharynx and physiology of the swallowing process [13]. This is also true of cases involving dental materials. A retrospective study of accidental ingestion or aspiration over five years at a university-run dental clinic in Japan found no cases of aspiration among 23 patients [11]. A systematic review of retained foreign objects during dental procedures found that 89.5% of cases were ingestion cases and only the remaining 10.5% were aspiration cases [5]. Despite their lower incidence, aspirated cases are potentially more dangerous, as they are more frequently life-threatening [14].

Foreign body aspiration is a common cause of emergency room visits in children. In the United States, the incidence was 29.9 per 100,000 people in 2001, and the estimated number of emergency room visits was 17,537 [15]. For adults, the incidence is lower, and cases occur in about one third of children [16,17], with most patients aged three years or less [16,18]. The predisposition of younger patients to foreign body aspiration

Table 2. Aspirated dental items reported in review articles [22-24]

Aspirated objects	Number of cases
Prosthesis & Crown	32
Inlay	7
Screw post	5
Amalgam	2
Endodontic file	1

Data presented as number (%).

can be explained by their tendency to place objects in their mouth, lack of teeth, and immature swallowing coordination [18]. Children have small airways, and the locations of foreign bodies in their airways differ from those in adults. A report of a single-center experience of over 20 years found that foreign bodies were located in the proximal airways (larynx, trachea, right and left main bronchus) more frequently in children (74%) than in adults (43%) [16]. This discrepancy may be attributable to the size of the airways. Among adults, foreign body aspiration most typically occurs in patients aged 60 or more [5,19]. Adult cases are more commonly associated with healthcare equipment [20], with dental materials identified as one of the most common causes. [20,21]. The occurrence (cases/dentists) per year has been reported to be 0.021 by French insurance companies [22]. Over a four-year period at a dental hospital in Tokyo, 0.0038% of the annual cumulative number of patients at the hospital experienced ingestion or aspiration, and among the 40 patients, aspiration was found in one patient [23]. Another report from a dental clinic in North Carolina found 36 cases of ingestion or aspiration over a 10-year-period and one patient with a dental foreign body in the airway [24] (Table 1).

A review conducted by Hou et al. found that aspiration was common in implantation, prosthodontics, and restorative dentistry [5]. The most commonly aspirated dental items were prostheses, inlay cores, dental crowns [11,12,22], and screw drivers [3] (Table 2). In pediatric cases, extracted teeth are commonly swallowed [11,25]. The years of professional experience of the practitioners involved in the cases have tended to be shorter [11,12,25]. Reports show that no specific times of day are associated with more frequent accidents [11,12,25].

Dentures can also be ingested or aspirated. A literature review conducted between 2009 and 2019 identified 85 cases worldwide. More men (84.7%) were involved, and most patients did not have cognitive dysfunction (77.4%). Eating (15.2%), sleeping (8.2%), and intubation (7.1%) were common precipitating events [26].

The risk factors for the aspiration of foreign bodies in dentistry have not been fully elucidated. The anecdotal nature of most reports in the literature limits analysis. Neurologic disorders, dental procedures, medical procedures, loss of consciousness due to trauma, and alcohol or sedative use have been found to be predisposing factors for foreign body aspiration among adults in retrospective studies [20,27]. Potential risk factors for foreign body aspiration during dental procedures include intravenous sedation, local anesthesia, supine position, inadequate lightning, ineffective assistants [5,28], professional experience of the practitioner [11,12,25], and specific types of procedures [5,12]. Further studies are required to validate these results.

CLINICAL MANIFESTATION

Foreign body aspiration can cause various symptoms and signs. The type of aspirated material and the location of the aspirate in the bronchial tree, the length of time between aspiration and diagnosis, and the host's response to foreign bodies may be related to variable clinical manifestations [29-31]. Clinical manifestations may range from asymptomatic to fatal.

In children, the typical response after foreign body aspiration is choking [32]. Choking may have a high predictive value for the presence of a foreign body in the airway [33]. Other common symptoms include cough, vomiting, and dyspnea [34]. The most common finding on physical examinations is decreased breath sound on the affected site [33,35]. Other possible findings include stridor, which is indicative of an upper airway obstruction. Wheezing, cough, and decreased breath sounds have been described as the classic triad. The specificity has been reported to be high [33-36], but recent studies show that only around 15% [33,34] present with the classic triad. Dyspnea accompanied by wheezing can lead to misdiagnosis as asthma [37,38] or acute bronchiolitis [39] (Table 3).

Adults are often asymptomatic or have milder symptoms [40,41]. The most common symptom after foreign body aspiration is cough, followed by dyspnea [42,43]. Other notable symptoms included hemoptysis [41,42], choking [16,21], fever [16,44], and vomiting [41] (Table 3).

Foreign body aspiration can also cause negative-pressure pulmonary edema. Negative thoracic pressure is induced by inspiratory effort in the presence of an obstructed glottis. Negative pressure results in high permeability or hydrostatic edema. To manage this, the airway must be secured via endotracheal intubation. Positive-pressure ventilation with supplementary oxygen is then provided. Although pulmonary edema usually resolves within 24-48 hours, further management may be needed in patients with severe hypoxemia. Diuretics, low tidal volume ventilation, and β -agonists are options [45].

Various airway tissue reactions, including inflammation, granulation, endobronchial stenosis, and edema, can result from foreign body aspiration [46]. Stenosis can result in dyspnea, sputum production, chest pain, and fever with obstructive infection. Tissue response is related to the nature of the aspirate and duration since aspiration. Organic foreign bodies remaining in the airway for longer periods cause more mucosal irritation, leading to chronic inflammation and granulation [47]. Inorganic materials

Table 3. Symptoms and signs of all-cause aspirations in the reviewed articles

Report (Author, year)	Patient characteristics	Number of cases	Symptoms	Signs
Nasir, et al., 2021 [33]	Patient < 11	16	Cough (69%), dyspnea (69%), vomiting (56%)	Stridor (31%), fever (31%), cyanosis (25%)
Oguz, et al. 2000 [35]	Pediatric	53	Cough (54.5%), vomiting (7.5%), dyspnea (5.6%)	Unilaterally decreased breathing sound (52.8%), wheezing (45.2%), Cyanosis (41.5%)
Midulla, et al., 2005 [34]	Pediatric	82	Cough (75.7%), dyspnea (38.6%), gasping (5.7%)	Localized decreased breath sound (62.8%), Localized wheezing (30%), diffuse wheezing (25.7%)
Paksu, et al., 2012 [36]	Pediatric	147	Cough (81.0%), dyspnea (60.0%), vomiting (13.9%)	Localized decreased breath sound), wheezing (27.0%), tachypnea (16.8%)
Ramos, et al., 2009 [21]	Patients > 14 years old	32	Cough (22%), choking (19%)	NA
Soysal, et al., 2006 [114]	Patients who underwent bronchoscopy after diagnosed with foreign body aspiration	140	Cough (60.7%), dyspnea (39.3%)	Decreased breathing sound (50%), rales (50%), tachypnea (50%)
Foltran, et al., 2012 [2]	Meta-analysis, patients of all ages	174 articles, 30,477 patients	Cough (61.2%), choking (46.8%), dyspnea (34.6%)	Decreased respiratory movement (65.9%), decreased air entry (63.3%), decreased sound (50.4%)

NA, not available.

incite less inflammation but cause direct trauma and can be wedged in the bronchial tree [48]. Aspirations associated with dental procedures are typically composed of inorganic materials. A review of dental aspirations found that the most common aspirated objects were prostheses/crowns (58.2%), followed by inlay cores (12.7%), and screwdrivers/screws (10.9%). Other reported objects include endodontic files/reamers, bridges, and burs/drills [5].

EVALUATIONS

Early management of foreign body aspiration requires an evaluation of the patient's respiratory state. Signs of patient instability must be checked [49]. Patients with respiratory distress require maneuvers for removal and emergency airway management [50]. Stable patients are likely to have only partial obstruction, but caution needs to be taken to avoid complete obstruction or a displacement of the foreign body deeper into the airway via diagnostic or therapeutic maneuvers [49] (Fig. 1).

In stable patients, the location and identity of the foreign body must be evaluated [49]. Imaging studies are

essential at this stage. They confirm that foreign bodies are indeed present and can help identify the object. Moreover, the location of the object and associated complications needs to be examined [51-53]. Radiographs play an important role [51-55]. Radiographs are inexpensive, widely available, and sensitive for detecting radiopaque objects [53]. Secondary findings of airway obstruction such as air trapping, atelectasis, mediastinal shifting, and consolidation can also be detected [53]. However, some foreign bodies are undetectable, and radiographs are not sensitive to other tracheal and bronchial disorders [53].

Multidetector computed tomography (MDCT) can be used in cases where radiographs are inconclusive [51,54]. MDCT provides not only rapid examination but also reconstructed two-dimensional (coronal and sagittal) and three-dimensional (virtual bronchoscopy) images. [53, 56]. The virtual bronchoscopy can provide views of the internal walls of the tracheobronchial tree, thus accurately depicting the location of the foreign body and related changes [1,56]. MDCT can also aid in correcting previous misdiagnoses of aspirations as another condition, such as acute bronchiolitis [39]. A systematic review of the central airways via CT can improve the detection of

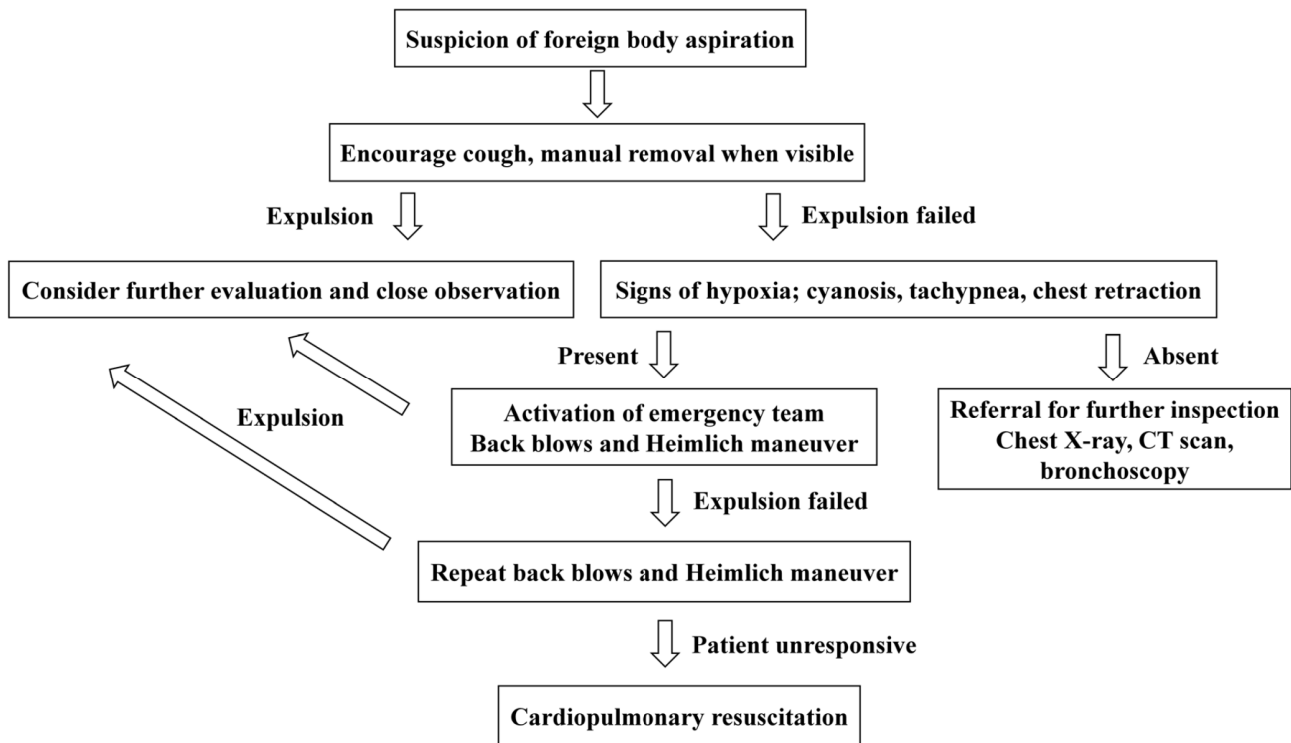


Fig. 1. Summary of management flow when dental material aspiration is suspected. CT, computed tomography.

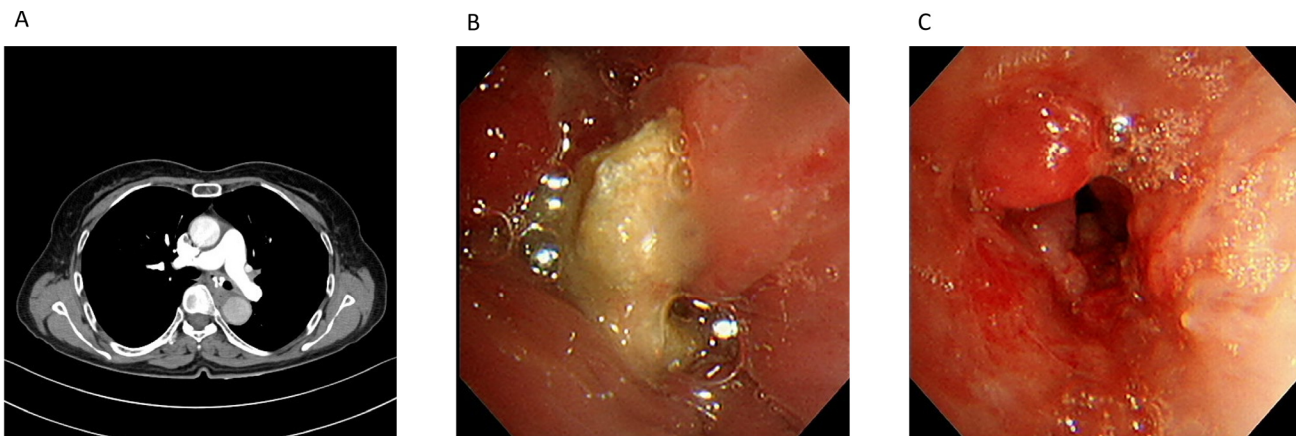


Fig. 2. Case of 74-year-old woman who presented with dyspnea. (A) Chest computed tomography showing a calcified foreign body in the left main bronchus. (B) Bronchoscopic visualization of the foreign body. (C) Flexible bronchoscopy with a retrieval basket was performed to remove the foreign body. Granulated tissue was observed after the removal.

abnormalities that may go unnoticed [57]. Owing to its high sensitivity (100%) and specificity (98%), MDCT has been advocated as a diagnostic tool to avoid routine bronchoscopy in suspected cases of foreign body aspiration [58]. However, MDCT has several disadvantages. Exposure to radiation is potentially harmful, and the use of contrast media has adverse effects in some populations [53]. Access to this modality might also be

limited. Unlike bronchoscopy, MDCT cannot be used for diagnostic and therapeutic purposes.

While bronchoscopy is the treatment modality of choice for the retrieval of foreign bodies in the airway, flexible bronchoscopy can also be used for diagnostic purposes. Patients who are suspected of aspiration without abnormal physical examination and radiologic findings should receive bronchoscopy [27,59] (Fig. 2). The procedure is relatively

easy, safe, and cost-effective [41,60]. As relatively few adult patients remember the aspiration event, bronchoscopy can be considered if the patient has recurrent lung disease or risk factors for aspiration but the results of imaging studies are ambiguous [27].

TREATMENT

1. Initial bystander-assisted removal of foreign body object

Coughing should be encouraged in conscious patients. If the foreign body is not removed via cough and the object is seen in the mouth, manual removal can be considered. Blind finger sweeps should be avoided because they can dislodge the object or inflict injury to the nasopharynx [61]. When such attempts fail, further management depends on the degree of respiratory distress. Tachypnea, nasal flaring, retractions, and cyanosis are warning signs [62]. When warning signs are absent, the patient can be referred to the medical department for radiological evaluations, elective removal procedures, or observation. However, in cases of severe obstruction, healthcare providers with expertise in airway management should be consulted immediately [63]. Additional potential bystander interventions include abdominal thrusts and back blows. Abdominal thrusts and the Heimlich maneuver have yielded better survival rates, with satisfactory neurological outcomes. However, major complications, including traumatic damage to the abdominal organs and vessels, have been reported [64, 65]. An abdominal thrust maneuver is contraindicated in infants, and back blows are now recommended prior to abdominal thrusts [61]. To perform back blows, the care provider must stand behind the patient, place one arm across the chest, lean the patient forward, and then slap five times between the shoulders with hand heels. Abdominal thrusts can be performed when back blows are ineffective. The maneuver is performed by the care provider by standing behind the patient, wrapping the arms around the upper abdomen, two inches above the

belly button, then making a fist with one hand with the other hand held tightly over the fist and thrusting five times inward and upward [66]. The maneuvers can be repeated. If the patient becomes unconscious during the process, cardiopulmonary resuscitation should begin.

2. Rigid and flexible bronchoscopy

Both rigid and flexible bronchoscopies can be performed by an endoscopist for foreign bodies retained in the airways. It has been reported that 0.16 to 0.33% [21,27,67-69] of all adult bronchoscopy cases are due to foreign bodies in the airway. Flexible endoscopy constitutes most bronchoscopy cases globally, especially in adults [70,71] (Table 4).

Rigid bronchoscopy is the method of choice for foreign body removal in children [31]. The advantages of rigid bronchoscopy include better resolution and a larger diameter. The procedure's success rate in children is very high, with only a few cases requiring surgical intervention. In a case series of 2,624 patients from Algeria, the success rate was 97% [72]. Other international studies have reported comparable rates [73-75]. However, rigid bronchoscopy is not available in most healthcare facilities and requires general anesthesia [63].

Flexible bronchoscopes are widely used in adult patients with foreign body airway obstruction [63]. They can be used for both diagnosis and treatment. They cause less trauma and can reach the more distal bronchi [76]. The procedure can be performed under moderate sedation instead of general anesthesia and muscle relaxants [77]. Even among pediatric patients, reports of foreign body removal under flexible bronchoscopy are growing, with success rates comparable to those of procedures with rigid bronchoscopes [78,79]. However, flexible bronchoscopes cannot completely replace rigid bronchoscopes. When removing sharp objects such as glass, nails, or thumbtacks, flexible bronchoscopes do not protect the airway, whereas rigid bronchoscopes do [63]. Some objects, such as teeth, are not removable with tools available for flexible bronchoscopes [77,80]. There are no randomized controlled trials comparing rigid and

Table 4. Treatment and mortality for all-cause aspiration in reviewed articles

Report (Author, year)	Patient characteristics	Number of patients	Flexible BS, success rates	Rigid BS, success rates	Surgery requirement	Mortality
Ramos, et al., 2009 [21]	Patients > 14 years old	32	NA	NA	15.6%	0%
Mise, et al., 2008 [27]	Adult patients who underwent flexible BS for foreign body removal	86	98.8%	NA	1.2%	0%
Debeljak, et al., 1999 [67]	Adult patients who underwent BS for foreign body removal	62	67.7%	96.8% (after both flexible and rigid bronchoscopy)	1.6%	0%
Casalini, et al., 2013 [68]	Patients who underwent BS for foreign body removal	159	96%	100%	0%	0%
Boyd, et al., 2009 [69]	Adult patients who underwent BS for foreign body removal	20	90%	NA	0%	20%
Pasaoglu, et al., 1991 [115]	Pediatric patients who underwent BS for foreign body removal	639	NA	96.7%	0.3%	7.8%
De Palma, et al., 2020 [116]	Patients < 16 years who underwent BS for foreign body removal	51	97%	67%	0%	0%
Boufersaoui, et al., 2013 [72]	Patients < 18 years who underwent BS for foreign body removal	2624	NA	97%	2.6%	0.26%
Ganie, et al., 2014 [73]	Patients who underwent BS for foreign body removal	55	NA	94.5%	5.5%	0%
Dortler, et al., 2019 [74]	Patients < 16 years who underwent BS for foreign body removal	86	NA	100%	0%	0%
Goyal, et al., 2020 [75]	Pediatric patients treated for foreign body aspiration	37	NA	94.6%	5.4%	0%
Dong, et al., 2012 [40]	Adult patients admitted for foreign body aspiration	200	96.5%	NA	3.5%	0%
Cutrone, et al., 2011 [76]	Children admitted for foreign body aspiration	206	NA	99.5%	0.5%	0%
Fang, et al., 2015 [77]	Adult patients who underwent BS for foreign body removal	94	90.4%	100%	1.1%	0%
Tang, et al., 2009 [80]	Pediatric patients who underwent flexible BS for foreign body aspiration	1027	91.3%	100%	0%	0%
Swanson, et al., 2002 [78]	Patients ≤ 16 years who underwent BS for foreign body removal	39	100%	86.7%	0%	0%
Kim, et al., 2018 [79]	Pediatric patients who underwent flexible BS for foreign body aspiration	20	90.0%	NA	10%	0%
Hou, et al., 2017 [5]	Review of case reports of dental foreign body aspiration	20	NA	NA	5%	0%

BS, bronchoscopy; NA, not available.

flexible bronchoscopy to guide the practice, but they can be used complementarily [81-83].

In general, foreign body aspirations at dental clinics can be managed using bronchoscopy [5,9]. Fortunate cases, with spontaneous expulsion after impaction, have been reported [84-86], but most cases require further management, usually with bronchoscopes. Both rigid and flexible bronchoscopes have been used for management [5,87-89]. In a few cases, surgical resection was

performed after unsuccessful interventions [28,90,91]. It is unclear whether rigid or flexible bronchoscopy is more suitable for patients with foreign body obstruction in dental practice. The nature and location of the object and the expertise of the medical center are decisive factors.

3. Anesthesia during bronchoscopy

Flexible bronchoscopy in adults is often performed under moderate sedation under monitored anesthesia [92].

Topical anesthesia is applied to the oropharynx and laryngopharynx using a spray gargle or gel [93]. Under a condition of conscious sedation, foreign bodies can be extracted via the mouth without positive pressure or jet ventilation [63]. A British Thoracic Society guideline recommends a combination of benzodiazepines and opioids during flexible bronchoscopy, with midazolam and fentanyl as the preferred drugs [93]. Other available medications include remifentanyl [94], propofol [95], ketamine [96], and dexmedetomidine [97]. They can be administered by a bronchoscopist or anesthesiologist [98-100].

Rigid bronchoscopy requires deep sedation because the procedure is stimulating and uncomfortable for patients [92,101]. Total intravenous anesthesia with propofol and remifentanyl can be used effectively and safely. As in flexible bronchoscopy, dexmedetomidine and ketamine are alternatives [92]. Ventilation techniques for rigid bronchoscopy are a cause for concern, as optimal ventilation must be achieved during airway procedures. Positive-pressure ventilation and jet ventilation have been applied [92,101]. For children, since rigid bronchoscopy is still considered the first choice for the management of foreign bodies, procedures under general anesthesia are frequent. Sevoflurane can be used in children for induction and maintenance, as it provides more stable hemodynamics and respiration, as well as faster induction and recovery [102]. Alternatively, total intravenous anesthesia with propofol and remifentanyl can be used in children [103,104].

PREVENTIONS IN DENTAL CLINICS

Prevention of accidental aspiration during dental procedures has been emphasized [9,105]. Although accidents may occur at any time, procedures considered higher-risk include periodontal treatment, direct restorative treatment, indirect restorative treatment, removable prosthodontic treatment, and endodontics [106]. Other potential risk factors include decreased gag

reflex in the elderly and patients with neurologic conditions and an altered state of consciousness [107]. These situations warrant a higher level of attention to the possibility of inhalation accidents, and barrier techniques can be used. Dental equipment must be checked periodically to ensure that the handpieces hold burs securely and that other small objects are affixed securely. Rubber dams are known to be the easiest and most effective method of preventing aspiration and ingestion [9]. Rubber dams have been used for more than 150 years and have the additional benefits of reducing microbial contamination, enhancing visibility, improving visual access to the canal, optimizing moisture control, and retracting soft tissues. Despite these advantages, the use of rubber dams is often overlooked because it is perceived as difficult and time-consuming by practitioners, who also think patients do not like it. However, several reports show patient satisfaction with the use of rubber dams, and their application needs to be encouraged [108]. In cases where a rubber dam cannot be applied, such as in orthodontic, prosthodontic, and various microsurgical procedures, a gauze screen (4 × 4 inches) can be used to block the access of objects into the oropharynx [9]. The gauze itself can also be aspirated; it can be controlled by attaching a floss or by leaving a long trailing edge of the gauze [107]. Nonetheless, gauze screens may not be tolerated in some cases owing to gag reflexes or the limited space available for procedures with enlarged tongues [9,109]. Such cases should avoid alignment of the oral cavity and laryngopharynx in a straight line during the procedure [9,110]. If the patient is in a straight position, an object dropped into the pharynx may not cause a gag reflex or foreign body sensation. The head rest and chair can be adjusted to the upright or reverse Trendelenburg position [8]. A dental floss or ligature wire can be tied to avoid the incidence. Handles for hex drivers are also available. A lip retractor with a magnet has also been devised to maintain mouth tissue retraction and to magnetically attach accidentally dropped instruments [111].

PROGNOSIS OF DENTAL FOREIGN BODY ASPIRATION

The reported treatment success rate for dental foreign body aspiration is high. A review of reported cases from 1974 to 2014 found that 16 of 20 patients (80.0%) had a successful endoscopic retrieval, three (15.0%) had a lung resection, and one (5.0%) had spontaneous excretion [5]. However, there are reports of morbidity and mortality [8,26]. Kim et al. reported a patient aged > 90 years who had tooth #14 extracted. During the process, the gold crown of the tooth was aspirated, and, despite transfer to the emergency room and successful bronchoscopic removal, the patient deteriorated and died after intensive care [8].

Delayed recognition and management can result in pulmonary complications. Pneumonia and abscesses can develop, causing respiratory symptoms, such as cough, sputum, and dyspnea [3]. In severe cases, chest infections can lead to sepsis [112]. A tooth impacted in the main bronchus has been reported to cause air trapping and respiratory failure, acting as a ball valve allowing air to enter during inspiration, but occluding during expiration [113]. Other possible serious complications of foreign bodies in the airway include pneumothorax, atelectasis, bronchiectasis, hemorrhage, and bronchoesophageal fistula [9,39].

CONCLUSION

The aspiration of objects related to dental practices can occur. Such patients require urgent attention and should be referred to healthcare facilities, where further evaluations can be performed. The mainstay of treatment is bronchoscopy; in some cases, surgical resection of the lung is required. Missed foreign bodies in the airways can cause further pulmonary complications.

AUTHOR ORCID*s*

Jin-Young Huh: <https://orcid.org/0000-0003-4317-8047>

AUTHOR CONTRIBUTIONS

Jin-Young Huh: Conceptualization, Data curation, Investigation, Methodology, Validation, Visualization, Writing - original draft, Writing - review & editing

CONFLICT OF INTEREST: The author has no conflicts of interest.

REFERENCES

1. Gang W, Zhengxia P, Hongbo L, Yonggang L, Jiangtao D, Shengde W, Chun W. Diagnosis and treatment of tracheobronchial foreign bodies in 1024 children. *J Pediatr Surg* 2012; 47: 2004-10.
2. Foltran F, Ballali S, Passali FM, Kern E, Morra B, Passali GC, et al. Foreign bodies in the airways: a meta-analysis of published papers. *Int J Pediatr Otorhinolaryngol* 2012; 76: S12-9.
3. Fields RT, Jr., Schow SR. Aspiration and ingestion of foreign bodies in oral and maxillofacial surgery: a review of the literature and report of five cases. *J Oral Maxillofac Surg* 1998; 56: 1091-8.
4. Dibiasse AT, Samuels RH, Ozdiler E, Akcam MO, Turkkahraman H. Hazards of orthodontics appliances and the oropharynx. *J Orthod* 2000; 27: 295-302.
5. Hou R, Zhou H, Hu K, Ding Y, Yang X, Xu G, et al. Thorough documentation of the accidental aspiration and ingestion of foreign objects during dental procedure is necessary: review and analysis of 617 cases. *Head Face Med* 2016; 12: 23.
6. Gou Y, Ungvijanpunya N, Chen L, Zeng Y, Ye H, Cao L. Clear aligner vs fixed self-ligating appliances: orthodontic emergency during the 2020 coronavirus disease 2019 pandemic. *Am J Orthod Dentofacial Orthop* 2022; 161: e400-6.
7. Hadad H, de Jesus LK, Poli PP, Garcia-Júnior IR, Souza

- F, de Oliveira FRG. Aspiration of the dental crown in an elderly patient. *Radiol Case Rep* 2021; 16: 2280-5.
8. Kim E, Noh W, Panchal N. Mortality from an aspiration of dental crown during extraction. *Gerodontology* 2017; 34: 498-500.
 9. Yadav RK, Yadav HK, Chandra A, Yadav S, Verma P, Shakya VK. Accidental aspiration/ingestion of foreign bodies in dentistry: a clinical and legal perspective. *Natl J Maxillofac Surg* 2015; 6: 144-51.
 10. Ramugade MM, Sagale AA. A review of medicolegal considerations of endodontic practice for general dental practitioners. *J Int Soc Prev Community Dent* 2018; 8: 283-8.
 11. Obinata K, Satoh T, Towfik AM, Nakamura M. An investigation of accidental ingestion during dental procedures. *J Oral Sci* 2011; 53: 495-500.
 12. Hisanaga R, Hagita K, Nojima K, Katakura A, Morinaga K, Ichinohe T, et al. Survey of accidental ingestion and aspiration at Tokyo Dental College Chiba Hospital. *Bull Tokyo Dent Coll* 2010; 51: 95-101.
 13. Matsuo K, Palmer JB. Anatomy and physiology of feeding and swallowing: normal and abnormal. *Phys Med Rehabil Clin N Am* 2008; 19: 691-707, vii.
 14. Zitzmann NU, Elsasser S, Fried R, Marinello CP. Foreign body ingestion and aspiration. *Oral Surg Oral Med Oral Pathol Oral Radiol Endod* 1999; 88: 657-60.
 15. Centers for Disease Control and Prevention (CDC). Nonfatal choking-related episodes among children--United States, 2001. *MMWR Morb Mortal Wkly Rep* 2002; 51: 945-8.
 16. Baharloo F, Veyckemans F, Francis C, Biettlot MP, Rodenstein DO. Tracheobronchial foreign bodies: presentation and management in children and adults. *Chest* 1999; 115: 1357-62.
 17. Rafanan AL, Mehta AC. Adult airway foreign body removal. What's new? *Clin Chest Med* 2001; 22: 319-30.
 18. Yang C, Hua R, Xu K, Hua X, Ma P, Zheng JN, et al. The role of 3D computed tomography (CT) imaging in the diagnosis of foreign body aspiration in children. *Eur Rev Med Pharmacol Sci* 2015; 19: 265-73.
 19. Soroudi A, Shipp HE, Stepanski BM, Ray LU, Murrin PA, Chan TC, et al. Adult foreign body airway obstruction in the prehospital setting. *Prehosp Emerg Care* 2007; 11: 25-9.
 20. Limper AH, Prakash UB. Tracheobronchial foreign bodies in adults. *Ann Intern Med* 1990; 112: 604-9.
 21. Ramos MB, Fernández-Villar A, Rivo JE, Leiro V, García-Fontán E, Botana MI, et al. Extraction of airway foreign bodies in adults: experience from 1987-2008. *Interact Cardiovasc Thorac Surg* 2009; 9: 402-5.
 22. Susini G, Pommel I, Camps J. Accidental ingestion and aspiration of root canal instruments and other dental foreign bodies in a French population. *Int Endod J* 2007; 40: 585-9.
 23. Hisanaga R, Takahashi T, Sato T, Yajima Y, Morinaga K, Ohata H, et al. Accidental ingestion or aspiration of foreign objects at Tokyo Dental College Chiba Hospital over last 4 years. *Bull Tokyo Dent Coll* 2014; 55: 55-62.
 24. Tiwana KK, Morton T, Tiwana PS. Aspiration and ingestion in dental practice: a 10-year institutional review. *J Am Dent Assoc* 2004; 135: 1287-91.
 25. Fuangtharnthip P, Pujareern P, Pachimsawat P, Loeksomphot P, Janjarussakul P, Manopatanakul S. Accidental swallowing of dental objects during pediatric dental care in thailand. *J Int Soc Prev Community Dent* 2021; 11: 671-7.
 26. Daniels J, Oremule B, Tsang W, Khwaja S. A 10-year review of the complications caused by ingested and aspirated dentures. *Ear Nose Throat J* 2021; 100: 574-80.
 27. Mise K, Jurcev Savicevic A, Pavlov N, Jankovic S. Removal of tracheobronchial foreign bodies in adults using flexible bronchoscopy: experience 1995-2006. *Surg Endosc* 2009; 23: 1360-4.
 28. Cossellu G, Farronato G, Carrassi A, Angiero F. Accidental aspiration of foreign bodies in dental practice: clinical management and prevention. *Gerodontology* 2015; 32: 229-33.
 29. Reilly JS, Walter MA, Beste D, Derkay C, Muntz H, Myer CM, et al. Size/shape analysis of aerodigestive foreign bodies in children: a multi-institutional study. *Am J Otolaryngol* 1995; 16: 190-3.
 30. Shostak E. Foreign body removal in children and adults:

- review of available techniques and emerging technologies. *AME Med J* 2018; 3: 75.
31. Zur KB, Litman RS. Pediatric airway foreign body retrieval: surgical and anesthetic perspectives. *Paediatr Anaesth* 2009; 19: 109-17.
 32. Passali D, Gregori D, Lorenzoni G, Cocca S, Loglisci M, Passali FM, Bellussi L. Foreign body injuries in children: a review. *Acta Otorhinolaryngol Ital* 2015; 35: 265-71.
 33. Nasir ZM, Subha ST. A five-year review on pediatric foreign body aspiration.. *Int Arch Otorhinolaryngol* 2021; 25: e193-9.
 34. Midulla F, Guidi R, Barbato A, Capocaccia P, Forenza N, Marseglia G, et al. Foreign body aspiration in children. *Pediatr Int* 2005; 47: 663-8.
 35. Oğuz F, Citak A, Ünüvar E, Sidal M. Airway foreign bodies in childhood. *Int J Pediatr Otorhinolaryngol* 2000; 52: 11-6.
 36. Paksu S, Paksu MS, Kilic M, Guner SN, Baysal K, Sancak R, Ozturk F. Foreign body aspiration in childhood: evaluation of diagnostic parameters. *Pediatr Emerg Care* 2012; 28: 259-64.
 37. Mitchell CA, Kreiger P, Goff C, Shah UK. Pediatric foreign body aspiration: a nidus for *Aspergillus* colonization. *Int J Pediatr Otorhinolaryngol* 2015; 79: 938-40.
 38. Shah K, Guarderas J, Krishnaswamy G. Aspiration-induced pulmonary syndromes. *Ann Allergy Asthma Immunol* 2016; 117: 479-82.
 39. Cho HK, Cho KY, Cho SY, Sohn S. Bronchial foreign body aspiration diagnosed with MDCT. *Clin Exp Pediatr* 2007; 50: 781-4.
 40. Dong YC, Zhou GW, Bai C, Huang HD, Sun QY, Huang Y, Han YP, Li Q. Removal of tracheobronchial foreign bodies in adults using a flexible bronchoscope: experience with 200 cases in China. *Intern Med* 2012; 51: 2515-9.
 41. Ma W, Hu J, Yang M, Yang Y, Xu M. Application of flexible fiberoptic bronchoscopy in the removal of adult airway foreign bodies. *BMC Surg* 2020; 20: 165.
 42. Lin L, Lv L, Wang Y, Zha X, Tang F, Liu X. The clinical features of foreign body aspiration into the lower airway in geriatric patients. *Clin Interv Aging* 2014; 9: 1613-8.
 43. Altuntas B, Aydin Y, Eroglu A. Foreign bodies in trachea: a 25-years of experience. *Eurasian J Med* 2016; 48: 119-23.
 44. Swanson KL, Prakash UBS, McDougall JC, Midthun DE, Edell ES, Brutinel MM, et al. Airway foreign bodies in adults. *J Bronchology Interv Pulmonol* 2003; 10: 107-11.
 45. Bhattacharya M, Kallet RH, Ware LB, Matthay MA. Negative-Pressure Pulmonary Edema. *Chest* 2016; 150: 927-33.
 46. Sehgal IS, Dhooria S, Ram B, Singh N, Aggarwal AN, Gupta D, et al. Foreign body inhalation in the adult population: experience of 25,998 bronchoscopies and systematic review of the literature. *Respir Care* 2015; 60: 1438-48.
 47. Mehta RM, Rashmi N, Bajaj P, Krishnan S, Srinivasan L. Airway stenosis related to foreign body aspiration: an under-recognized long term complication. *Clin Med Insights Case Rep* 2019; 12: 1179547619863816.
 48. Panigrahi B, Sahay N, Samaddar DP, Chatterjee A. Migrating foreign body in an adult bronchus: an aspirated denture. *J Dent Anesth Pain Med* 2018; 18: 267-70.
 49. Oyama LC. Foreign bodies of the ear, nose and throat. *Emerg Med Clin North Am* 2019; 37: 121-30.
 50. Fidkowski CW, Zheng H, Firth PG. The anesthetic considerations of tracheobronchial foreign bodies in children: a literature review of 12,979 cases. *Anesth Analg* 2010; 111: 1016-25.
 51. Pugmire BS, Lim R, Avery LL. Review of ingested and aspirated foreign bodies in children and their clinical significance for radiologists. *Radiographics* 2015; 35: 1528-38.
 52. Pinto A, Muzj C, Gagliardi N, Pinto F, Setola FR, Scaglione M, et al. Role of imaging in the assessment of impacted foreign bodies in the hypopharynx and cervical esophagus. *Semin Ultrasound CT MR* 2012; 33: 463-70.
 53. Lee EY, Restrepo R, Dillman JR, Ridge CA, Hammer MR, Boiselle PM. Imaging evaluation of pediatric trachea and bronchi: systematic review and updates. *Semin Roentgenol* 2012; 47: 182-96.
 54. Saeed Bamashmos A, Heshmetzadeh Behzadi A, Elfatairy K, Megahed A, Kochar P, Hegde R. Foreign bodies of body orifices: a pictorial review. *Clin Imaging* 2021; 80: 180-9.
 55. Laya BF, Restrepo R, Lee EY. Practical imaging evaluation

- of foreign bodies in children: an update. *Radiol Clin North Am* 2017; 55: 845-67.
56. Veras TN, Hornburg G, Schnier AM, Pinto LA. Use of virtual bronchoscopy in children with suspected foreign body aspiration. *J Bras Pneumol* 2009; 35: 937-41.
57. Lawrence DA, Branson B, Oliva I, Rubinowitz A. The wonderful world of the windpipe: a review of central airway anatomy and pathology. *Can Assoc Radiol J* 2015; 66: 30-43.
58. Gibbons AT, Casar Berazaluce AM, Hanke RE, McNinch NL, Person A, Mehlman T, Rubin M, Ponsky TA. Avoiding unnecessary bronchoscopy in children with suspected foreign body aspiration using computed tomography. *J Pediatr Surg* 2020; 55: 176-81.
59. Osman EZ, Swift A. Management of foreign bodies in the ears and upper aerodigestive tract. *Br J Hosp Med (Lond)* 2007; 68: M189-91.
60. Dikensoy O, Usalan C, Filiz A. Foreign body aspiration: clinical utility of flexible bronchoscopy. *Postgrad Med J* 2002; 78: 399-403.
61. Olasveengen TM, Mancini ME, Perkins GD, Avis S, Brooks S, Castrén M, et al. Adult basic life support: 2020 international consensus on cardiopulmonary resuscitation and emergency cardiovascular care science with treatment recommendations. *Circulation* 2020; 142: S41-91.
62. Berdan EA, Sato TT. Pediatric airway and esophageal foreign bodies. *Surg Clin North Am* 2017; 97: 85-91.
63. Hewlett JC, Rickman OB, Lentz RJ, Prakash UB, Maldonado F. Foreign body aspiration in adult airways: therapeutic approach. *J Thorac Dis* 2017; 9: 3398-409.
64. Otero Palleiro MM, Barbagelata López C, Fernández Pretel MC, Salgado Fernández J. Hepatic rupture after Heimlich maneuver. *Ann Emerg Med* 2007; 49: 825-6.
65. Desai SC, Chute DJ, Desai BC, Koloski ER. Traumatic dissection and rupture of the abdominal aorta as a complication of the Heimlich maneuver. *J Vasc Surg* 2008; 48: 1325-7.
66. Ojeda Rodriguez JA, Ladd M, Brandis D. Abdominal Thrust Maneuver. In: *StatPearls*. Treasure Island, FL, StatPearls Publishing. 2022.
67. Debeljak A, Sorli J, Music E, Kecelj P. Bronchoscopic removal of foreign bodies in adults: experience with 62 patients from 1974-1998. *Eur Respir J* 1999; 14: 792-5.
68. Casalini AG, Majori M, Anghinolfi M, Burlone E, D'Ippolito R, Toschi M, et al. Foreign body aspiration in adults and in children: advantages and consequences of a dedicated protocol in our 30-year experience. *J Bronchology Interv Pulmonol* 2013; 20: 313-21.
69. Boyd M, Watkins F, Singh S, Haponik E, Chatterjee A, Conforti J, Chin R Jr. Prevalence of flexible bronchoscopic removal of foreign bodies in the advanced elderly. *Age Ageing* 2009; 38: 396-400.
70. Simpson FG, Arnold AG, Purvis A, Belfield PW, Muers MF, Cooke NJ. Postal survey of bronchoscopic practice by physicians in the United Kingdom. *Thorax* 1986; 41: 311-7.
71. Prakash UB, Offord KP, Stubbs SE. Bronchoscopy in North America: the ACCP survey. *Chest* 1991; 100: 1668-75.
72. Boufersaoui A, Smati L, Benhalla KN, Boukari R, Smail S, Anik K, et al. Foreign body aspiration in children: experience from 2624 patients. *Int J Pediatr Otorhinolaryngol* 2013; 77: 1683-8.
73. Ganie FA, Wani ML, Ahangar AG, Lone GN, Singh S, Lone H, et al. The efficacy of rigid bronchoscopy for foreign body aspiration. *Bull Emerg Trauma* 2014; 2: 52-4.
74. Dorterler ME, Kocaman OH, Gunendi T, Boleken ME. a single-center experience of pediatric foreign-body aspiration: A retrospective 4-year case series. *Lung India* 2019; 36: 202-6.
75. Goyal S, Jain S, Rai G, Vishnu R, Kamath GS, Bishnoi AK, Gaude Y, Kumara V, Joshi H, Reddy R. Clinical variables responsible for early and late diagnosis of foreign body aspiration in pediatrics age group. *J Cardiothorac Surg* 2020; 15: 271.
76. Cutrone C, Pedruzzi B, Tava G, Emanuelli E, Barion U, Fischetto D, et al. The complimentary role of diagnostic and therapeutic endoscopy in foreign body aspiration in children. *Int J Pediatr Otorhinolaryngol* 2011; 75: 1481-5.
77. Fang YF, Hsieh MH, Chung FT, Huang YK, Chen GY, Lin SM, Lin HC, Wang CH, Kuo HP. Flexible bronchoscopy with multiple modalities for foreign body

- removal in adults. *PLoS One* 2015; 10: e0118993.
78. Swanson KL, Prakash UB, Midthun DE, Edell ES, Utz JP, McDougall JC, Brutinel WM. Flexible bronchoscopic management of airway foreign bodies in children. *Chest* 2002; 121: 1695-700.
 79. Kim K, Lee HJ, Yang EA, Kim HS, Chun YH, Yoon JS, et al. Foreign body removal by flexible bronchoscopy using retrieval basket in children. *Ann Thorac Med* 2018; 13: 82-5.
 80. Tang LF, Xu YC, Wang YS, Wang CF, Zhu GH, Bao XE, Lu MP, Chen LX, Chen ZM. Airway foreign body removal by flexible bronchoscopy: experience with 1027 children during 2000-2008. *World J Pediatr* 2009; 5: 191-5.
 81. Batra H, Yarmus L. Indications and complications of rigid bronchoscopy. *Expert Rev Respir Med* 2018; 12: 509-20.
 82. Alraiyes AH, Machuzak MS. Rigid bronchoscopy. *Semin Respir Crit Care Med* 2014; 35: 671-80.
 83. Goussard P, Pohunek P, Eber E, Midulla F, Di Mattia G, Merven M, et al. Pediatric bronchoscopy: recent advances and clinical challenges. *Expert Rev Respir Med* 2021; 15: 453-75.
 84. Abraham ZS, Kahinga AA, Mapondella KB, Massawe ER, Ntunaguzi D. Spontaneous expulsion of an intrabronchial sharp metallic foreign body and migration to the gastrointestinal tract at Muhimbili National Hospital: case report and literature review. *Int J Surg Case Rep* 2020; 72: 423-5.
 85. Ameku K, Higa M. Spontaneous expulsion and migration of a bronchial foreign body: a flustering rare dental accident. *Int J Case Rep Imag* 2017; 8: 668-71.
 86. Robinson FG, Ray DS, Kalim S. Impression material lodged in the hypopharynx: a clinical report. *J Prosthet Dent* 2021: 1-4.
 87. Arana Ribeiro J, Martins Natal R, Matos Gomes R. Dental implant screwdriver aspiration. *Pulmonology* 2022; 28: 239-40.
 88. Araujo SCS, Bustamante JED, de Souza AAB, Peixoto LC, Amaral MBF. Aspiration of dental items: case report with literature review and proposed management algorithm. *J Stomatol Oral Maxillofac Surg* 2021; 1: 1-7.
 89. Selin K, Gözde I, Günbay T, Kahraman S, Çelik F. Implant screwdriver aspiration during dental procedure at a geriatric patient: a case report. *Ege Tıp Dergisi* 2022; 61: 111-4.
 90. Sopeña B, García-Caballero L, Diz P, De la Fuente J, Fernández A, Díaz JA. Unsuspected foreign body aspiration. *Quintessence Int* 2003; 34: 779-81.
 91. Israel HA, Leban SG. Aspiration of an endodontic instrument. *J Endod* 1984; 10: 452-4.
 92. de Lima A, Kheir F, Majid A, Pawlowski J. Anesthesia for interventional pulmonology procedures: a review of advanced diagnostic and therapeutic bronchoscopy. *Can J Anaesth* 2018; 65: 822-36.
 93. Du Rand IA, Blaikley J, Booton R, Chaudhuri N, Gupta V, Khalid S, et al. British Thoracic Society guideline for diagnostic flexible bronchoscopy in adults: accredited by NICE. *Thorax* 2013; 68 Suppl 1: i1-i44.
 94. Lee H, Choe YH, Park S. Analgosedation during flexible fiberoptic bronchoscopy: comparing the clinical effectiveness and safety of remifentanyl versus midazolam/propofol. *BMC Pulm Med* 2019; 19: 240.
 95. Crawford M, Pollock J, Anderson K, Glavin RJ, MacIntyre D, Vernon D. Comparison of midazolam with propofol for sedation in outpatient bronchoscopy. *Br J Anaesth* 1993; 70: 419-22.
 96. Hwang J, Jeon Y, Park HP, Lim YJ, Oh YS. Comparison of alfentanil and ketamine in combination with propofol for patient-controlled sedation during fiberoptic bronchoscopy. *Acta Anaesthesiol Scand* 2005; 49: 1334-8.
 97. Pertzov B, Krasulya B, Azem K, Shostak Y, Izhakian S, Rosengarten D, et al. Dexmedetomidine versus propofol sedation in flexible bronchoscopy: a randomized controlled trial. *BMC Pulm Med* 2022; 22: 87.
 98. Magazine R, Sisupalan KN, Surendra VU, Chogtu B, Acharya PR, Guddattu V. Effect of bronchoscopist-directed sedation and other factors on patient comfort during diagnostic flexible bronchoscopy. *Scientifica (Cairo)* 2022; 2022: 8643844.
 99. Tariq A, Hill NS, Price LL, Ismail K. Incidence and nature of respiratory events in patients undergoing bronchoscopy under conscious sedation. *J Bronchology Interv Pulmonol* 2022: 1-7.
 100. Jo YY, Kwak HJ. Sedation strategies for procedures

- outside the operating room. *Yonsei Med J* 2019; 60: 491-9.
101. Pathak V, Welsby I, Mahmood K, Wahidi M, MacIntyre N, Shofer S. Ventilation and anesthetic approaches for rigid bronchoscopy. *Ann Am Thorac Soc* 2014; 11: 628-34.
102. Liao R, Li JY, Liu GY. Comparison of sevoflurane volatile induction/maintenance anaesthesia and propofol-remifentanyl total intravenous anaesthesia for rigid bronchoscopy under spontaneous breathing for tracheal/bronchial foreign body removal in children. *Eur J Anaesthesiol* 2010; 27: 930-4.
103. Malherbe S, Whyte S, Singh P, Amari E, King A, Ansermino JM. Total intravenous anesthesia and spontaneous respiration for airway endoscopy in children—a prospective evaluation. *Paediatr Anaesth* 2010; 20: 434-8.
104. Tschiedel E, Eckerland M, Felderhoff-Mueser U, Dohna-Schwake C, Stehling F. Sedation for bronchoscopy in children: a prospective randomized double-blinded trial. *Pediatr Pulmonol* 2021; 56: 1221-9.
105. Umesan UK, Chua KL, Balakrishnan P. Prevention and management of accidental foreign body ingestion and aspiration in orthodontic practice. *Ther Clin Risk Manag* 2012; 8: 245-52.
106. Hellyer P, Radford D. An evaluation of defensive dentistry: w(h)ither the profession? *Br Dent J* 2017; 223: 885-8.
107. Cameron SM, Whitlock WL, Tabor MS. Foreign body aspiration in dentistry: a review. *J Am Dent Assoc* 1996; 127: 1224-9.
108. Ahmed HM, Cohen S, Lévy G, Steier I, Bukiet F. Rubber dam application in endodontic practice: an update on critical educational and ethical dilemmas. *Aust Dent J* 2014; 59: 457-63.
109. Doh RM. Foreign body aspiration during dental treatment under general anesthesia: A case report. *J Dent Anesth Pain Med* 2019; 19: 119-23.
110. Jeon HS, Lee JH. Prevention and management of foreign body ingestion and aspiration during the dental treatment. *J Dent Rehabil Appl Sci* 2018; 34: 63-71.
111. Ismael G, Alameida LD, Lacerda TSP. Prevention from swallowing or aspiration in dentistry for elderly patients. *MOJ Gerontol Ger* 2018; 3: 106-8.
112. Jillela S, Subrahmanyam R. A safer technique of nasogastric tube insertion in a patient with basilar skull fractures. *Br J Anaesth* 2015; 115(eLetters Supplement).
113. Madan K, Aggarwal AN, Bhagat H, Singh N. Acute respiratory failure following traumatic tooth aspiration. *BMJ Case Rep* 2013; 2013: bcr2012008393.
114. Soysal O, Kuzucu A, Ulutas H. Tracheobronchial foreign body aspiration: a continuing challenge. *Otolaryngol Head Neck Surg* 2006; 135: 223-6.
115. Paşaoğlu I, Doğan R, Demircin M, Hatipoğlu A, Bozer AY. Bronchoscopic removal of foreign bodies in children: retrospective analysis of 822 cases. *Thorac Cardiovasc Surg* 1991; 39: 95-8.
116. De Palma A, Brascia D, Fiorella A, Quercia R, Garofalo G, Genuardo M, et al. Endoscopic removal of tracheobronchial foreign bodies: results on a series of 51 pediatric patients. *Pediatr Surg Int* 2020; 36: 941-51.