

Prophylactic Mastectomy and Implant-Based Breast Reconstruction of BRCA1/2 Mutation-Positive Patients in Korea

Joon Seok Lee^{1,*}, Jeeyeon Lee², Ho Yong Park², Jung Dug Yang¹

¹Department of Plastic and Reconstructive Surgery, School of Medicine, Kyungpook National University, Kyungpook National University Chilgok Hospital, Daegu, Korea

²Department of Surgery, School of Medicine, Kyungpook National University, Daegu, Korea

Purpose: Mastectomy is performed as a surgical treatment for patients with breast cancer who have the BRCA 1/2 mutation. In this study, we have reported the trends in Korea for both immediate breast reconstruction and prophylactic mastectomy. **Methods:** This retrospective study was conducted from 2019 to 2021. Both skin-sparing mastectomy and immediate implant-based breast reconstruction with prepectoral and/or subpectoral techniques were performed in five patients with BRCA 1/2 mutations. Data on age; body mass index; cancer stage; BRCA 1/2 mutation; estrogen receptor, progesterone receptor, and human epidermal growth factor receptor 2 expression; diagnosis; and complications were collected. **Results:** The average (\pm standard deviation [SD]) age was 44.0 ± 6.48 years old; BMI 24.5 ± 2.25 kg/m²; and breast volumes were 365.8 ± 70.34 and 382.4 ± 96.33 cc for right and left ones, respectively. The BRCA 1 and 2 were diagnosed in four and one patients, respectively. The estrogen and progesterone receptors and human epidermal growth factor receptor 2 were detected in one (20%), one (20%), and three (60%) patients, respectively. The applied implant-based breast reconstruction techniques for ten breasts were subpectoral technique ($n=7$, 70%) and prepectoral technique ($n=3$, 30%). For the cancer stage, those with I, II, and III stages were one (20%), two (40%), and one (20%), respectively. There were no major complications such as infection, seroma. **Conclusion:** When mastectomy is performed as surgical treatment in BRCA 1/2 mutation positive breast cancer patients, it is possible to obtain a better outcome with both implant-based breast reconstruction and different circumstances between breast cancer and contralateral breast.

Key words: BRCA 1/2 mutation, Contralateral prophylactic mastectomy, Bilateral breast reconstruction

ORIGINAL ARTICLE

Received: March 13, 2022
Revised: March 27, 2022
Accepted: March 31, 2022

Correspondence to: Joon Seok Lee
Department of Plastic and Reconstructive Surgery, School of Medicine, Kyungpook National University Kyungpook National University Chilgok Hospital, 807 Hoguk-ro, Buk-gu, Daegu 41404, Korea
Tel: +82-53-420-5688
Fax: +82-53-425-3879
E-mail: leejspo@knu.ac.kr

ORCID
Joon Seok Lee: <https://orcid.org/0000-0002-1580-0487>

Copyright © 2022, Interdisciplinary Society of Genetic & Genomic Medicine

This is an Open Access article distributed under the terms of the Creative Commons Attribution Non-Commercial License (<https://creativecommons.org/licenses/by-nc/4.0>) which permits unrestricted non-commercial use, distribution, and reproduction in any medium, provided the original work is properly cited.

INTRODUCTION

Recently, with the development of equipment and technology, the early diagnosis rate of breast cancer has improved. Concurrently, various genetic tests and treatment methods have also been developed to predict a good prognosis. Generally, once unilateral breast cancer is diagnosed, the amount of resection is determined according to the tumor size. During this process, a BRCA gene mutation test is also usually performed. Breast cancer is the most common cancer among women worldwide and in Korea, and approximately 7% cases are hereditary [1]. Hereditary breast cancer generally refers to a mutation in the BRCA1 or 2 genes, and a confirmed mutation can increase the risk of acquiring breast cancer by 60%–80% [1]. In Korea, the estimated cumulative risk of breast cancer by the age of 70 years is 72.1%/66.3% in the presence of BRCA 1/2 mutation, respectively [2]. Thus, a positive BRCA gene mutation can be considered to be associated with a high risk of breast cancer. In particular, BRCA2 mutation-positive breast cancer tends to show similar pathological features to those of sporadic breast cancer, whereas BRCA1 mutation-positive breast cancer shows features different from

those of sporadic breast cancer. Therefore, triple-negative breast cancer (TNBC) is considered in cases in which the estrogen receptor (ER), progesterone receptor (PR), and human epidermal growth factor receptor 2 (HER2) are all not expressed [3-5]. Other studies reported that 57% of BRCA1 mutations and 23% of BRCA2 mutations in TNBC [6]. It is reported that clinical outcomes are similar when comparing sporadic breast cancer and BRCA-related cancer [7]. Based on these studies, in a patient with a positive BRCA gene mutation diagnosed with breast cancer in one breast, the possibility of developing cancer in the contralateral breast cannot be eliminated. In this case, even if only one breast, a very important anatomical structure symbolizing femininity, is resected, there can be great impact and pain. Particularly, when bilateral mastectomy is decided because of a BRCA gene mutation, breast reconstruction is essentially considered. The oncological safety of unilateral breast reconstruction performed immediately together with mastectomy has already been confirmed, and such treatments have been increasingly used recently. Previously, the concept of prophylactic mastectomy was viewed negatively due to oriental thinking. However, in recent years, owing to the improvement in socioeconomic and educational status of patients, the application of prophylactic mastectomy has been increasing. This has led to an increase in the rate of contralateral prophylactic mastectomy (CPM), especially in patients with early-stage, low-risk unilateral breast cancer [8,9]. Therefore, in this study, we have reported about bilateral implant-based breast reconstruction in BRCA 1/2 mutation-positive breast cancer.

METHODS

Study design

The Institutional Review Board of Kyungpook National University Chilgok Hospital (No. 2018-05-005-001) approved this prospective study, and all patients provided informed consent for collecting, analyzing and publishing their data (including deidentified photographs) for research purposes.

From January 2019 to June 2021, immediate implant-based breast reconstruction was performed after nipple-sparing mastectomy on both sides in five patients with BRCA 1/2 mutation-positive breast cancer. Among them, one was not diagnosed with breast cancer. The following patient characteristics were evaluated: age; body mass index (BMI); preoperative breast volume; implant volume; cancer staging; smoking status (smoker/non-smoker); use of radiotherapy and chemotherapy; presence of BRCA 1/2 mutation; and ER, PR, and HER2 expression.

Photometry was performed preoperatively and at 1, 3, 6, and 12 months postoperatively.

Patient selection

This prospective randomized study included patients (1) who were diagnosed with BRCA 1/2 mutation, (2) who were 30–60 years old at the time of surgery, and (3) who underwent immediate implant-based breast reconstruction after nipple-sparing mastectomy on both sides. This study excluded patients (1) who were diagnosed with advanced stage III or IV breast cancer, (2) who were unable to complete the self-reported questionnaire owing to a history of cognitive impairment, (3) who had a history of neurological and musculoskeletal disorders, and (4) who had a history of alcohol or drug abuse.

Surgical procedure

Selection of skin-sparing mastectomy incision

After discussing with an oncological breast surgeon and a plastic surgeon, (1) a lateral incision from the nipple to the axillary area, (2) an incision of approximately one-third of the lateral part of the inframammary fold using endoscopy, and (3) an approximately 4–5-cm incision in the mid-axillary line for robot-assisted mastectomy were preferred by the patients and were appropriately performed according to the breast size.

Implant-based breast reconstruction: subpectoral and/or prepectoral technique

The appropriate technique was determined according to a skin sparing mastectomy and by checking the shape of the breast defect. If the breast height was longer than the breast width of the defect, the subpectoral plane was used to reduce the depression of the upper pole of the breast with a round implant and the upper part was covered with the pectoralis major muscle. The insufficient implant pocket of the inferolateral part was custom-made for patients with an acellular dermal matrix (ADM), and subsequently, the implant was inserted. However, if the width and height of the breast were similar or wider, a large ADM was used as a prepectoral plane according to the width to create a pocket with full coverage of the anterior part of the breast implant and then proceeded with sparing of the pectoralis major muscle (Fig. 1). In both techniques, to minimize foreign body reaction to the implant, after applying two lines of the negative suction drain, irrigation was performed using an antibiotic irrigation solution (povidone-iodine, 50 cc; isepamicin, 80 mg; cefazolin, 1 g in 500 mL of sterile saline). Then, after betadine redraping of the incision

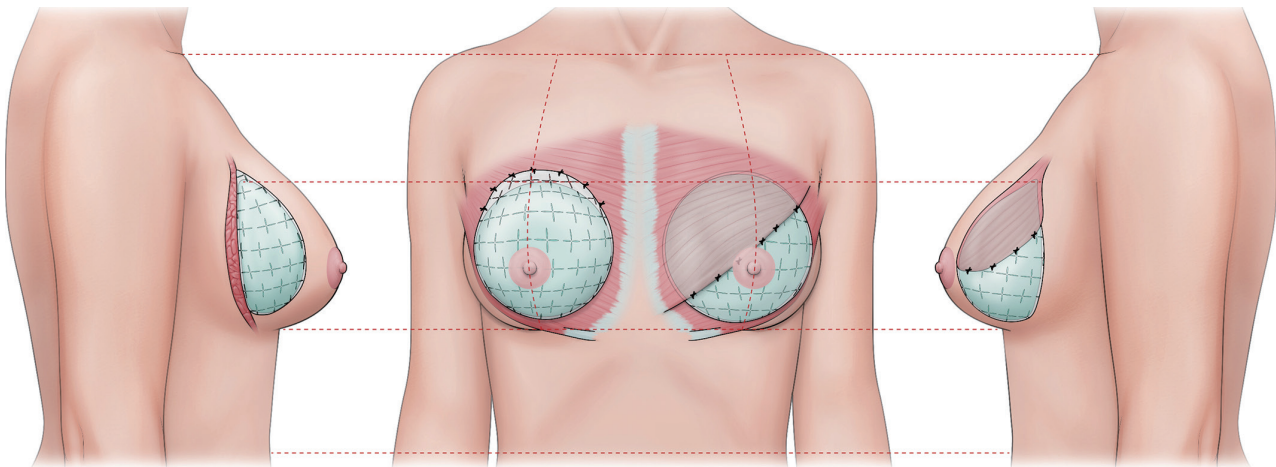


Fig. 1. Concept illustration of implant-based breast reconstruction in BRCA 1/2 positive patient. In the case of a BRCA 1/2 positive patient diagnosed with left breast cancer, the mastectomy area is wider for oncological safety in the affected left breast, and is smaller in the right breast based on the concept of contralateral prophylactic mastectomy, and the thickness of the breast skin flap is preserved. Because the finding on both sides is different, the size of the breast implant is different, and the technique is selected according to the patient's situation.

site and implant insertion, the ADM was checked in terms of the location of the drain; after positioning it at the desired location, the shape of the reconstructed breast, and symmetry of both sides was confirmed. However, before the final implant selection, the most appropriate profile for the patient was selected through an implant sizer, and the same implant of the same size was not always inserted into both breasts because of the difference in the mastectomy defects on the two sides.

RESULTS

For the five patients with BRCA 1/2 mutation positive, their average (\pm standard deviation [SD]) age was 44.0 ± 6.48 years old; BMI 24.5 ± 2.25 kg/m²; and breast volumes were 365.8 ± 70.34 and 382.4 ± 96.33 cc for right and left ones, respectively. The BRCA 1 and 2 were diagnosed in four and one patients, respectively. The estrogen and progesterone receptors and human epidermal growth factor receptor 2 were detected in one (20%), one (20%), and three (60%) patients, respectively. For the axillary operation, lymph node biopsy ($n=3$, 60%) and axillary lymph node dissection ($n=1$, 20%) were reported. The applied implant-based breast reconstruction techniques for ten breasts were subpectoral technique ($n=7$, 70%) and prepectoral technique ($n=3$, 30%). Only one patient was found to receive radiotherapy as an adjuvant one and four patients were found to receive chemotherapy as a neo ($n=2$, 40%) and adjuvant ($n=2$, 40%). For the cancer stage, those with I, II, and III stages were one (20%), two (40%), and one (20%), respec-

Table 1. Patient's demographics. Average \pm Standard deviation

Category	n=5 (10 breasts)
Age	44.0 \pm 6.48
BMI	24.5 \pm 2.25
Breast volume (R/L)	365.8 \pm 70.34/382.4 \pm 96.33
BRCA 1/2	4 (80%)/1 (20%)
ER/PR/HER2	1 (20%)/1 (20%)/3 (60%)
TNBC/non-TNBC	1 (20%)/3 (60%)
Axillary OP	
- SLNB	3 (60%)
- ALND	1 (20%)
- None	1 (20%)
Subpectoral/prepectoral (breast)	7 (70%)/3 (30%)
Radiotherapy	
- Adjuvant	- 1 (20%)
- None	- 4 (80%)
Chemotherapy	
- Neoadjuvant	- 2 (40%)
- Adjuvant	- 2 (40%)
- None	- 2 (40%)
Cancer stage	
1/2/3	1 (20%)/2 (40%)/1 (20%)
Pathology	
- IDC	- 4 (80%)
- None	- 1
ADM (breast)	
- CGCryoderm	- 4 (40%)
- MegaDerm	- 3 (30%)
- BellaCell HD	- 3 (30%)

BMI, body mass index; BRCA, breast cancer gene; ER, estrogen receptor; PR, progesterone receptor; HER 2, human epidermal growth factor receptor 2; TNBC, triple negative breast cancer; SLNB, sentinel lymph node sampling; ALND, axillary lymph node dissection; OP, operation; IDC, invasive ductal carcinoma; ADM, acellular dermal matrix.

tively. The invasive ductal carcinoma (n=4, 80%) accounted for most of the pathologic diagnosis. There were no major complications such as Infection, seroma, and implant rupture and both nipple necrosis was found in a patient (Table 1).

DISCUSSION

BRCA 1/2 is a gene that provides genetic information on breast cancer. Generally, it is diagnosed more often in younger patients than in older patients; this trend is similar worldwide and in Korea. This trend may be due to a selection bias as younger patients more readily agree to undergo genetic testing. In particular, patients with BRCA1 mutation tend to have higher histological and nuclear grades and a lower proportion of ductal carcinoma in situ (DCIS) than those without BRCA1 mutation. However, the T stage distribution was not significantly different in the BRCA2 group, and notably, the axillary lymph node involvement was found to be more frequent in the BRCA2 group. ER, PR, and HER2 statuses are very important factors for treatment and prognosis as they have crucial clinical implications. In particular, BRCA1 mutation tends to occur more frequently in triple-negative breast cancer [10-12]. In addition, it has been reported that BRCA-related breast cancer has a clinical outcome similar to that of sporadic breast cancer [6,7]. Research on the molecular basis for the phenotype specificity of BRCA1 is ongoing. A previous study has shown that the BRCA1 gene can induce ER α mRNA expression [13]. Therefore, ER α expression can be inhibited in the case of positive BRCA1 mutations [14]. Research at the molecular level and

that on the relationship with PR or HER2 is ongoing. In the case of axillary lymph node involvement, the possibility of involvement is generally high when the tumor size is large, but the possibility is slightly lower in the case of positive BRCA 1 mutation [15]. Studies on the presence of BRCA 1/2 mutations; association with ER, PR, and HER2 receptors; and analysis of axillary lymph node involvement, prognosis, and treatment are ongoing. If the differences and similarities with patients with sporadic breast cancer are identified and the basics of the relationship at the molecular level are revealed, a positive outcome for breast cancer patients can be predicted in the future. Based on these analyses, surgical treatment should be administered and long-term analysis of cases in which immediate breast reconstruction was performed after mastectomy must be performed. Usually, breast cancer is diagnosed first, and genetic testing is performed later with patient consent while investigating the family history and specifics. If patients are positive for BRCA 1/2 mutation, they have a very high probability of being diagnosed with breast cancer even though they may not have it yet. Therefore, the option to remove the breasts simultaneously can be explained to patients. As life expectancy increases and the rate of early diagnosis increases, there will be a gradual change in the tendency to recommend contralateral prophylactic mastectomy (CPM) if there is a gene mutation. In addition, the cancer risk on the contralateral breast can be reduced by up to 95% in the case of CPM [8,9]. Surgical treatment is performed for these reasons, and the scope of mastectomy must be slightly different between patients diagnosed with breast cancer and those undergoing surgery due to a BRCA

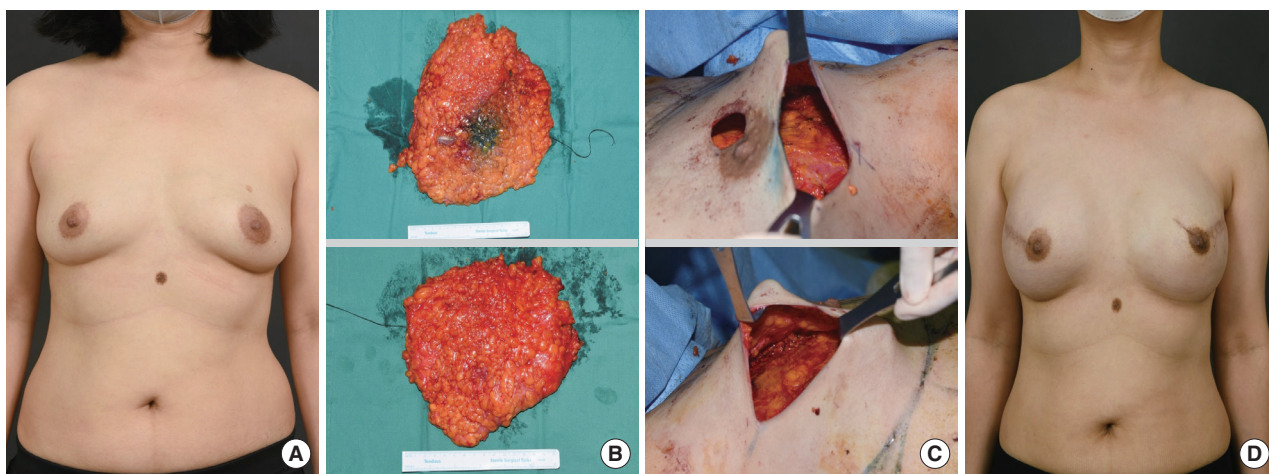


Fig. 2. Prophylactic mastectomy and immediate implant-based breast reconstruction. (A) Preoperative findings. Left breast cancer patient with BRCA 1 mutation positive patient. (B) Specimen. upper; Left breast, lower; Right breast. (C) Breast defect and skin flap after mastectomy. upper; Left breast, lower; Right breast. (D) Postoperative 1 year findings.

1/2 mutation. When cancer is diagnosed first, axillary lymph node sampling must be performed simultaneously and, if necessary, axillary lymph node dissection should be performed. Mastectomy also requires a safety margin; hence, rather than excising only the breast tissue, efforts are being made to reduce the recurrence rate by excising a sufficiently larger tissue than the range. However, in the case of CPM, as breast cancer is not diagnosed, axillary lymph node sampling is unnecessary, and only the mammary gland tissue is excised to preserve a thicker skin flap, which can be considered an advantage for breast reconstruction. As both sides are usually reconstructed, implant-based breast reconstruction rather than autologous tissue reconstruction is often chosen because the recovery time is lesser. This can be the reason why there is a possibility of using implants of different sizes in different ways for both breast reconstructions (Figs 1, 2). The thick skin flap reduces the appearance of the implant projected through it, resulting in a better aesthetic outcome. Complications such as sloughing and, in severe cases, partial necrosis, may be reduced, to some extent, to provide a better blood supply. It may cause, however, necrosis since the blood supply to the nipple-areolar complex (NAC) part is poor. This is considered the problem of difference in the vascular formation variation or preoperative chemotherapy or radiotherapy, rather than problem of the surgical technique. Recently, high-quality ADM (acellular dermal matrix) of various sizes can be used for implant-based breast reconstruction, which is very useful for creating implant pockets. Moreover, complications such as infection or seroma are gradually decreasing. As such, the possibility of occurrence, treatment, and prognosis of BRCA 1/2 mutation and breast cancer can be predicted, and surgical treatment is performed in parallel based on these factors. Recently, the quality of life of the patients, a very important factor, is increasingly. Because there is no correlation between cancer and immediate implant-based breast reconstruction, the trend is expected to change with the concept of prophylactic mastectomy and breast reconstruction. In the future, it can be expected that the cancer incidence rate will be predicted at the genetic level before cancer is diagnosed and that the concept of total care for a better life will flow into a safer, more practical, and aesthetic outcome for the rest of the lifetime.

In conclusion, despite the limitation of having a small sample size, we were able to investigate the association between BRCA 1/2 mutation and breast cancer incidence. Therefore, when mastectomy is performed as surgical treatment, it is possible to obtain a better outcome with both implant-based

breast reconstruction by considering the symmetry of the breast and different circumstances between diagnosed and undiagnosed breast cancer.

CONFLICT OF INTERESTS

The authors declare that they have no conflicts of interest to disclose.

ACKNOWLEDGEMENTS

None

REFERENCES

1. Yu JH, Lee JW, Son BH, Kim SW, Park SK, Lee MH, et al. Characteristics of BRCA1/2 mutation-positive breast cancers in Korea: a comparison study based on multicenter data and the Korean Breast Cancer Registry. *J Breast Cancer* 2014;17:129-35.
2. Robson ME, Boyd J, Borgen PI, Cody HS 3rd. Hereditary breast cancer. *Curr Probl Surg* 2001;38:387-480.
3. Seo JH, Cho DY, Ahn SH, Yoon KS, Kang CS, Cho HM, et al. BRCA1 and BRCA2 germline mutations in Korean patients with sporadic breast cancer. *Hum Mutat* 2004;24:350.
4. Han SA, Park SK, Ahn SH, Son BH, Lee MH, Choi DH, et al. The breast and ovarian cancer risks in Korea due to inherited mutations in BRCA1 and BRCA2: a preliminary report. *J Breast Cancer* 2009;12:92-9.
5. Byrski T, Gronwald J, Huzarski T, Grzybowska E, Budryk M, Stawicka M, et al. Response to neo-adjuvant chemotherapy in women with BRCA1-positive breast cancers. *Breast Cancer Res Treat* 2008;108:289-96.
6. Atchley DP, Albarracin CT, Lopez A, Valero V, Amos CI, Gonzalez Angulo AM, et al. Clinical and pathologic characteristics of patients with BRCA-positive and BRCA-negative breast cancer. *J Clin Oncol* 2008;26:4282-8.
7. Kriege M, Seynaeve C, Meijers-Heijboer H, Collee JM, Menke-Pluymers MB, Bartels CC, et al. Distant disease-free interval, site of first relapse and post-relapse survival in BRCA1- and BRCA2-associated compared to sporadic breast cancer patients. *Breast Cancer Res Treat* 2008;111:303-11.
8. Panchal H, Pilewskie ML, Shekter CC, Alborno CR, Razdan SN, Disa JJ, et al. National trends in contralateral prophylactic mastectomy in women with locally advanced breast cancer. *J Surg Oncol* 2019;119:79-87.
9. Boughey JC, Attai DJ, Chen SL, Cody HS, Dietz JR, Feldman SM, et al. Contralateral prophylactic mastectomy (CPM) consensus statement from the American Society of Breast Surgeons: data on CPM Outcomes and Risks. *Ann Surg Oncol* 2016;23:3100-5.
10. Atchley DP, Albarracin CT, Lopez A, Valero V, Amos CI, Gonzalez-Angulo AM, et al. Clinical and pathologic characteristics of patients with BRCA-positive and BRCA-negative breast cancer. *J*

- Clin Oncol 2008;26:4282-8.
11. Lagos-Jaramillo VI, Press MF, Ricker CN, Dubeau L, Mai PL, Weitzel JN. Pathological characteristics of BRCA-associated breast cancers in Hispanics. *Breast Cancer Res Treat* 2011;130:281-9.
 12. Gonzalez-Angulo AM, Timms KM, Liu S, Litton JK, Potter J, Lanchbury JS, et al. Incidence and outcome of BRCA mutations in unselected patients with triple receptor-negative breast cancer. *Clin Cancer Res* 2011;17:1082-9.
 13. Hosey AM, Gorski JJ, Murray MM, Quinn JE, Chung WY, Stewart GE, et al. Molecular basis for estrogen receptor alpha deficiency in BRCA1-linked breast cancer. *J Natl Cancer Inst* 2007;99:1683-94.
 14. Gorski JJ, Kennedy RD, Hosey AM, Harkin DP. The complex relationship between BRCA1 and ERalpha in hereditary breast cancer. *Clin Cancer Res* 2009;15:1514-8.
 15. Dent R, Trudeau M, Pritchard KI, Hanna WM, Kahn HK, Sawka CA, et al. Triple-negative breast cancer: clinical features and patterns of recurrence. *Clin Cancer Res* 2007;13(15 Pt 1):4429-34.