

# Comparison of healing assessments of periapical endodontic surgery using conventional radiography and cone-beam computed tomography: A systematic review

Garima Sharma<sup>1,\*</sup>, Dax Abraham<sup>1</sup>, Alpa Gupta<sup>1</sup>, Vivek Aggarwal<sup>2</sup>, Namrata Mehta<sup>1</sup>,  
Sucheta Jala<sup>1</sup>, Parul Chauhan<sup>1</sup>, Arundeeep Singh<sup>1</sup>

<sup>1</sup>Department of Conservative Dentistry and Endodontics, Manav Rachna Dental College, Faridabad, Haryana, India

<sup>2</sup>Department of Conservative Dentistry and Endodontics, Faculty of Dentistry, Jamia Millia Islamia, New Delhi, India

## ABSTRACT

**Purpose:** This systematic review aimed to compare assessments of the healing of periapical endodontic surgery using conventional radiography and cone-beam computed tomography (CBCT).

**Materials and Methods:** This review of clinical studies was conducted according to the Preferred Reporting Items for Systematic Reviews and Meta-Analyses (PRISMA) checklist. All articles published from 1990 to March 2020 pertaining to clinical and radiographic healing assessments after endodontic surgery using conventional radiography and CBCT were included. The question was “healing assessment of endodontic surgery using cone-beam computed tomography.” The review was conducted by manual searching, as well as undertaking a review of electronic literature databases, including PubMed and Scopus. The studies included compared radiographic and CBCT assessments of periapical healing after periapical endodontic surgery.

**Results:** The initial search retrieved 372 articles. The titles and abstracts of these articles were read, leading to the selection of 73 articles for full-text analysis. After the eligibility criteria were applied, 11 articles were selected for data extraction and qualitative analysis. The majority of studies found that CBCT enabled better assessments of healing than conventional radiography, suggesting higher efficacy of CBCT for correct diagnosis and treatment planning. A risk of bias assessment was done for 10 studies, which fell into the low to moderate risk categories.

**Conclusion:** Three-dimensional radiography provides an overall better assessment of healing, which is imperative for correct diagnosis and treatment planning. (*Imaging Sci Dent* 2022; 52: 1-9)

**KEY WORDS:** Cone-Beam Computed Tomography; Apicoectomy; Systematic Review

## Introduction

The paramount importance of being able to perform a predictable assessment after endodontic therapy is gaining recognition. A peri-radicular infection may persist even after adequate root canal treatment.<sup>1</sup> Normal function, a lack of clinical symptoms, and osseous regeneration signs in radiographs coupled with the re-establishment of a periodontal ligament space are indicators of favourable healing of apical periodontitis.<sup>2</sup> Assessments of periapical surgery

are usually based on clinical and radiographic criteria.<sup>3</sup> Two-dimensional (2D) radiography is commonly employed for the assessment of the extent of radiographic healing. The limitations of 2D radiography have paved the way for 3-dimensional (3D) evaluations of the healing site through cone-beam computed tomography (CBCT).

Apical surgery is performed to eradicate tissues showing signs of necrosis or infection. This involves apicoectomy (apical resection) of the tooth, with or without a retrograde filling.<sup>4</sup> However, the healing of periapical tissues after resection is the sole indication of the success of periapical surgery.

Although it may seem traumatic, the assessment of periapical surgery is more satisfactory than that of orthograde treatment. The inception of microsurgery has begun to dimi-

Received July 30, 2021; Revised October 3, 2021; Accepted October 11, 2021

Published online November 18, 2021

\*Correspondence to : Dr. Garima Sharma

Department of Conservative Dentistry and Endodontics, Manav Rachna Dental College, Faridabad, Haryana 121001, India

Tel) 91-8544947590, E-mail) sgarima56@gmail.com

Copyright © 2022 by Korean Academy of Oral and Maxillofacial Radiology

This is an Open Access article distributed under the terms of the Creative Commons Attribution Non-Commercial License (<http://creativecommons.org/licenses/by-nc/3.0>) which permits unrestricted non-commercial use, distribution, and reproduction in any medium, provided the original work is properly cited.

Imaging Science in Dentistry · pISSN 2233-7822 eISSN 2233-7830

nish perceptions of conventional periapical surgery as traumatic. There is documented evidence of a 90% success rate with microsurgery.<sup>5</sup> Follow-up after every treatment is the backbone of achieving a predictable treatment assessment. Although the histopathologic diagnosis remains the gold standard for evaluating the extent of healing, evidence exists that CBCT produces highly accurate assessments.<sup>3</sup>

CBCT and microsurgery go hand in hand to achieve successful endodontic therapy. Presently, CBCT imaging is frequently used for diagnosis and treatment planning in surgical endodontics.<sup>6</sup> CBCT has enabled new possibilities for clinicians as compared with conventional radiographic methods, which replicate 3D structures as 2D images; instead, CBCT is a 3D imaging method that offers the possibility to view a specific tooth or teeth in any view.<sup>7</sup>

The 2D healing categories proposed by Rud et al.<sup>8</sup> and Molvin et al.<sup>9</sup> may not be satisfactory for periapical assessments. CBCT scans make it possible to visualise the third dimension because they can be rearranged and reviewed in all dimensions; consequently, one can assess the lesion to near perfection. For the purpose of assessing healing after apical surgery, a new guideline involving the use of CBCT images have been proposed. Specifically, healing can be assessed based on 3D imaging using the RAC/B indices (R = resection plane, A = apical area, C = cortical plate, B = bone healing overall), and the modified Penn 3D criteria.<sup>3,6,10</sup> Another classification of healing criteria classification was initially described by Zetterqvist<sup>11</sup> in 1991 and advanced by Jesslén et al.,<sup>12</sup> wherein software such as ImageJ is used to delimit defects.<sup>13</sup>

A major obstacle in 2D radiography is the overlap of anatomic structures in the area of interest, which poses challenges both for diagnosis and healing assessments. Hence, the purpose of this systematic review was to compare conventional radiography and CBCT used for healing assessments after periapical endodontic surgery.

## Materials and Methods

The protocol of the systematic review was prepared based on the Preferred Reporting Items for Systematic Reviews and Meta-Analyses (PRISMA) checklist. The protocol was registered in the International Prospective Register of Systematic Reviews (PROSPERO) with reference acknowledgement number 183955. The population, intervention, comparison, and outcome (PICO) framework of a systematic review was used to formulate the review question, and the formulated question was “healing assessments of periapical endodontic surgery using conventional radiography

and cone-beam computed tomography.”

### Literature Search Strategy

The following databases were employed to conduct the literature search: MEDLINE/PubMed and Scopus, as well as a manual reverse search performed using suitable Medical Subject Headings (MeSH; <https://www.ncbi.nlm.nih.gov/mesh>) terms or keywords. MeSH terms were used in conjunction with the Boolean operators “AND” and “OR” to build a set of keywords to focus the search. In PubMed and Scopus the following search was performed: (“endodontic surgery” OR “periapical surgery” OR “apicoectomy” OR “periradicular surgery” OR “root end surgery” AND “endodontic failure” OR “periapical curettage” OR “periapical pathology” AND (“cone-beam computed tomography” [MeSH Terms] OR “cone-beam computed tomography” OR “healing assessment”). The collected data were searched manually and reverse-searched in order to identify and avoid duplication, and the final studies were selected after applying and framing using the PRISMA checklist (Table 1).<sup>14</sup>

### Inclusion and exclusion criteria

Prior to inclusion, the abstracts and titles of all articles were screened and identified by electronic and manual searches. Articles that did not meet the criteria for inclusion were accordingly filtered out. All the remaining articles were thoroughly and independently screened.

The inclusion criteria were: a) all studies published in the period from 1990 to 2020, b) clinical studies published in the English language, c) studies with adult human patients indicated for periapical surgery, d) studies comparing radiographic healing in periapical surgery cases using both CBCT and periapical radiographs, e) studies with follow-up evaluation done by CBCT, f) studies involving both periapical radiographs and tomographic analysis including patients who underwent CBCT concurrently with periapical surgery, and g) studies with at least 6 months of follow-up.

The exclusion criteria were: a) studies without postoperative CBCT evaluations, b) studies of patients with root fractures or iatrogenic perforations, c) studies including patients with the presence of any systemic disease or history of any medication use, d) studies done on paediatric patients, e) studies only using CBCT, and f) studies only using periapical radiographs.

### Quality assessment and data extraction

Two examiners (G.S. and A.G.) used the following parameters to extract data and analyse each study: author (year)/

**Table 1.** Summary of clinically-based publications and their characteristics

| Author                             | Type of study                                       | Subjects  | Follow-up   | Criteria   | Result   |
|------------------------------------|---|---|---|--|--|
| von Arx et al. (2016) <sup>3</sup> | Prospective clinical study                          | Total 54<br>(25 males, 29 females)<br>Age: 24-73 years  | 1 year  | Healing criteria presented by Rud et al. <sup>8</sup> and Molven et al. <sup>9</sup> Rating of 1: no radiolucency present, rating of 2: scar-type radiolucency, rating of 3: lesion-type radiolucency.   | The CBCT rating was on average 10.4% lower (better) and 30.1% higher (worse) than the PA ratings; CBCT images showed in nearly a third of the evaluated cases a worse situation than PA. |
| Curtis et al. (2018) <sup>2</sup>  | Retrospective clinical study                        | Total 97<br>(54 males, 43 females)<br>Age: 19-86 years  | 23 months   | Healing was determined by preoperative and postoperative PARL volumes, the percent change in volume, and the mean volume change in EMS.  | Postoperative CBCT imaging was more sensitive and specific than PA radiography in assessing PARL and has demonstrable usefulness in assessments.   |
| Kruse et al. (2018) <sup>20</sup>  | Prospective follow-up study                         | Total 74 teeth<br>from 66 patients<br>(32 males of 39-90 years,<br>42 females of 34-85 years) | Between 2012 and 2016 for patients who received treatment between 2004 and 2010 | Healing criteria presented by Rud et al. <sup>8</sup> and Molven et al. <sup>9</sup> : 1) complete healing, 2) incomplete healing, 3) uncertain healing, or 4) unsatisfactory healing.   | The additional use of CBCT for long-term follow-up examinations after SER led to more teeth diagnosed  |
| Kruse et al. (2017) <sup>4</sup>   | Clinical follow-up study                            | Total 66<br>(39 males of 39-90 years,<br>31 females of 31-82 years)                           | 7 years   | Healing criteria presented by Rud et al. <sup>8</sup> and Molven et al. <sup>9</sup> : 1) complete healing, 2) incomplete healing, 3) uncertain healing, or 4) unsatisfactory healing.   | Not all lesions observed in CBCT represented periapical inflammatory lesions.  |
| Kurt et al. (2014) <sup>18</sup>   | Prospective, randomized, controlled, clinical study | Total 39<br>Age: > 18 years   | 12 months   | The healing criteria classification described by Zetterqvist <sup>11</sup> and developed by Jesslén et al. <sup>12</sup>   | Preoperative CBCT examination demonstrated positive contributions to the treatment assessments.  |
| Parmar et al. (2019) <sup>17</sup> | Randomized controlled trial                         | Total 30<br>Age: ≥ 16 years   | 12 months   | Radiographic healing in 2D images (PA X-ray films) was assessed according to Molven's criteria. <sup>9</sup> 1) complete healing, 2) incomplete healing, 3) uncertain healing, or 4) unsatisfactory healing. The modified Penn 3D criteria were used to assess the 3D healing in CBCT scans, dichotomized as successful or unsuccessful. For additional analysis RAC indices and the B index were also assessed. | Both CBCT and PA allowed similar assessments of healing after periapical surgery.  |
| Safi et al. (2019) <sup>21</sup>   | Randomized controlled trial                         | Total 120 teeth<br>Age: ≥ 18 years  | 15 months   | Two-dimensional healing on PA radiography was determined according to the criteria established by Rud et al. <sup>8</sup> and Molven et al. <sup>9</sup> . The modified Penn 3D criteria were used to assess the 3D healing.   | The overall success rate, PA: 93.3%, CBCT: 85%.  |

**Table 1.** Continued

| Author                                     | Type of study                        | Subjects  | Follow-up                        | Criteria   | Result  |
|--|--------------------------------------|---|----------------------------------|--|---|
| Schloss et al. (2017) <sup>10</sup>        | Clinical study                       | Total 44 (18 males, 26 females)<br>Age: mean 45.9 years | 1 year                           | Molven's criteria, <sup>9</sup> as complete, incomplete, uncertain, or unsatisfactory healing, were used for the 2D healing assessment. Defects were expressed in percentages. The modified Penn 3D criteria were used to evaluate surgical endodontic healing by CBCT imaging. Defect area calculation was performed using volumes at the highest resolution. | CBCT analysis allowed a more precise evaluation of periapical lesions and healing of endodontic microsurgery than periapical films. |
| Meschi et al. (2020) <sup>1</sup>          | Randomized controlled clinical trial | Total 44  | 1 year                           | For the PA qualitative analysis, the scoring criteria of Molven et al. <sup>9</sup> for evaluation of assessment after RES were applied. For the qualitative analysis of the CBCTs RAC/B indices were evaluated.   | The qualitative CBCT assessment for apical area significantly higher than periapical radiograph.                                    |
| Tanomaru-Filho et al. (2015) <sup>13</sup> | Clinical study                       | Total 11  | 48 hours, 4 months, and 8 months | In periapical radiographic analysis, the ImageJ software was used to delimit the outline of the periapical lesions on a computer monitor. In the tomographic analysis, an analysis of the images provided by CBCT was performed directly on the computer monitor screen by means of a software program.  | CBCT is more capable of determining the absence of periapical bone repair than conventional 2-dimensional radiographs.              |
| Christiansen et al. (2009) <sup>19</sup>   | Clinical study                       | Total 50 (24 males, 26 females)                         | 1 week and 12 months             | Bone defects on the periapical radiographs were measured as the maximum vertical distance from the resection surface at the central point of the root filling to the most apical part of the defect. The CBCT images were individually reconstructed and images were sectioned in the coronal and sagittal planes.   | It was found that 67% more defects were detected on CBCT.   |

CBCT: cone-beam computed tomography, P.A.R.L.: periapical radiolucency, EMS: endodontic microsurgery, SER: surgical endodontic retreatment, 2D: 2-dimensional, 3D: 3-dimensional, PA: periapical radiograph

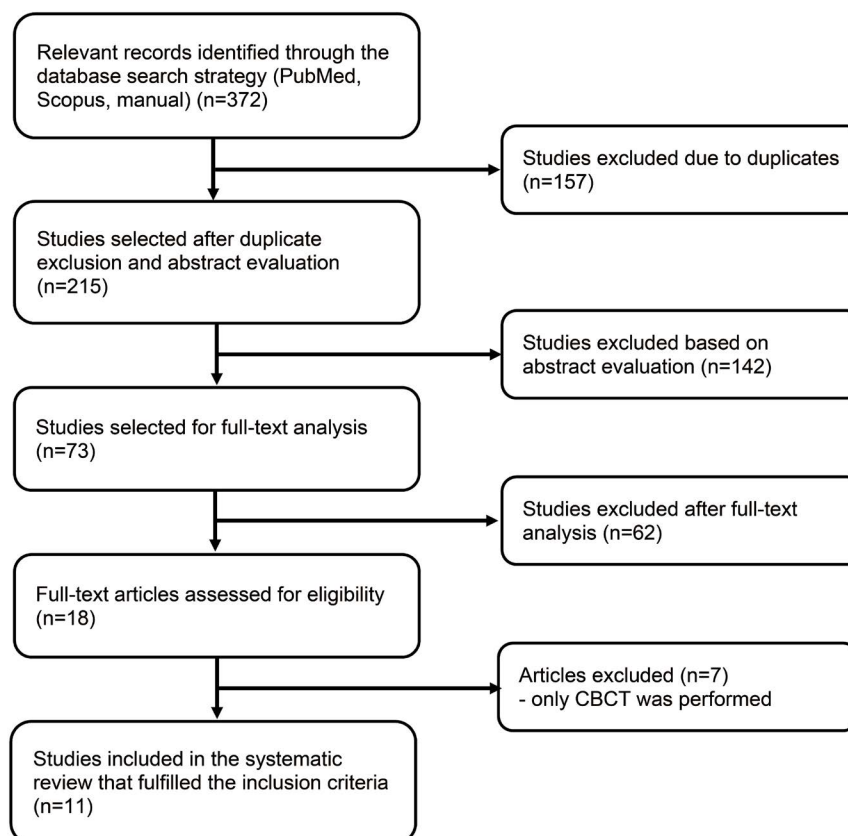


Fig. 1. Preferred Reporting Items for Systematic Reviews and Meta-Analyses (PRISMA) flowchart.

country, name of the journal, language of the study, diagnostic criteria, endodontic surgery healing assessment, age group, study design, and sample size, determined as per the guidelines issued by the NHS National Services Scotland.<sup>15</sup> Disagreements between the 2 authors were resolved by a third author. Risk of bias was evaluated using the 2014 Joanna Briggs Institute checklist.<sup>16</sup> The examiners independently evaluated the risk of bias for each study, which was followed by a discussion of every point.

## Results

The search strategy employed is presented in Figure 1. By undertaking a search of electronic databases and a manual search, 372 articles were identified as relevant. After excluding duplicate articles, 215 articles were screened and included for abstract evaluation. Finally, 11 articles satisfying the inclusion criteria were included in the systematic review.

### Study characteristics

In the final analysis, 11 studies were included, all of which were related to periapical radiography and CBCT used for endodontic surgery healing assessments. Table 1

shows a summary of the main features of the included studies. The interpretation of the 11 studies showed that they used both types of radiographic assessments (periapical radiography and CBCT) that were deemed relevant for this systematic review. All the studies were clinical, and the maximum follow-up duration was 1 year.<sup>1,3,10,17-19</sup> The studies conducted periapical surgery irrespective of the material used.

The criteria used by each individual study for postsurgical healing assessment with 2D and 3D imaging were presented in detail. The results of healing were reported using inconsistent units, such as percentages,<sup>2,3,17,18,20,21</sup> cubic millimetres,<sup>4,10,13,19</sup> and results in the form of true positives and true negatives. Studies applied the criteria of Rud et al. (1972)<sup>8</sup> and Molven et al. (1987)<sup>9</sup> to classify outcomes into 1) complete healing, 2) incomplete healing, 3) uncertain healing, or 4) unsatisfactory healing.<sup>1,3,4,10,17,20,21</sup> The modified Penn 3D criteria were also used to assess 3D healing using CBCT scans.<sup>10,17,21</sup>

### Risk of bias

The risk-of-bias assessment was done on 10 studies using the Joanna Briggs Institute Critical Appraisal Checklist.

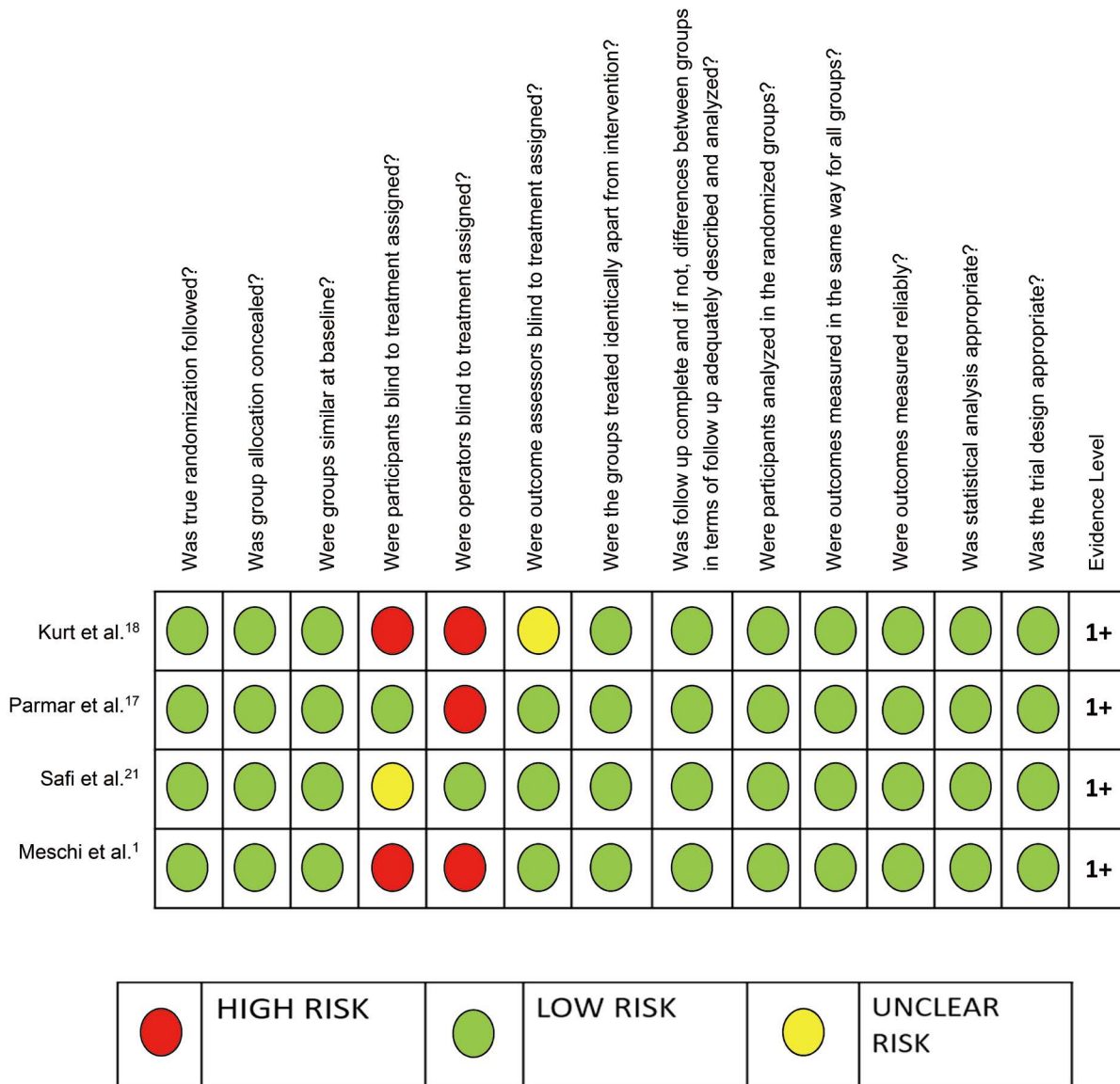


Fig. 2. Risk of bias assessment in clinical studies.

Four of these 10 studies were randomized controlled trials,<sup>1,17,18,21</sup> which had a low to moderate risk of bias (Fig. 2). Only one study had a low risk of bias,<sup>21</sup> with an evidence level of 1+. The remaining 6 studies were nonrandomized clinical studies (Fig. 3),<sup>3,4,10,13,19,20</sup> which had a low to moderate risk of bias and an evidence level of 2+. For all studies, the evidence level was determined following the guidelines given by the NHS National Services Scotland.<sup>15</sup>

### Discussion

The aim of this systematic review was to analyse studies comparing healing assessments as evaluated using 2D and 3D radiographic methods - irrespective of the retrograde

filling material, membrane used, site, or case - in terms of the new CBCT-based criteria for radiographic assessment.

Complete periapical repair and regeneration are markers of successful endodontic therapy.<sup>22</sup> Pursuant to the introduction of microsurgical principles, periapical surgery has become a highly significant treatment option in the field of modern endodontics.

Periapical surgical procedures entail the removal of infected and/or necrotic tissues; apicoectomy involves resection of the apical part of the tooth and preparation of the apical cavity for the insertion of a retrograde filling material.<sup>23</sup> The established protocol for apical surgery involves full-thickness mucoperiosteal flap reflection, osteotomy preparation, and root-end resection, along with ultrasonic prepa-

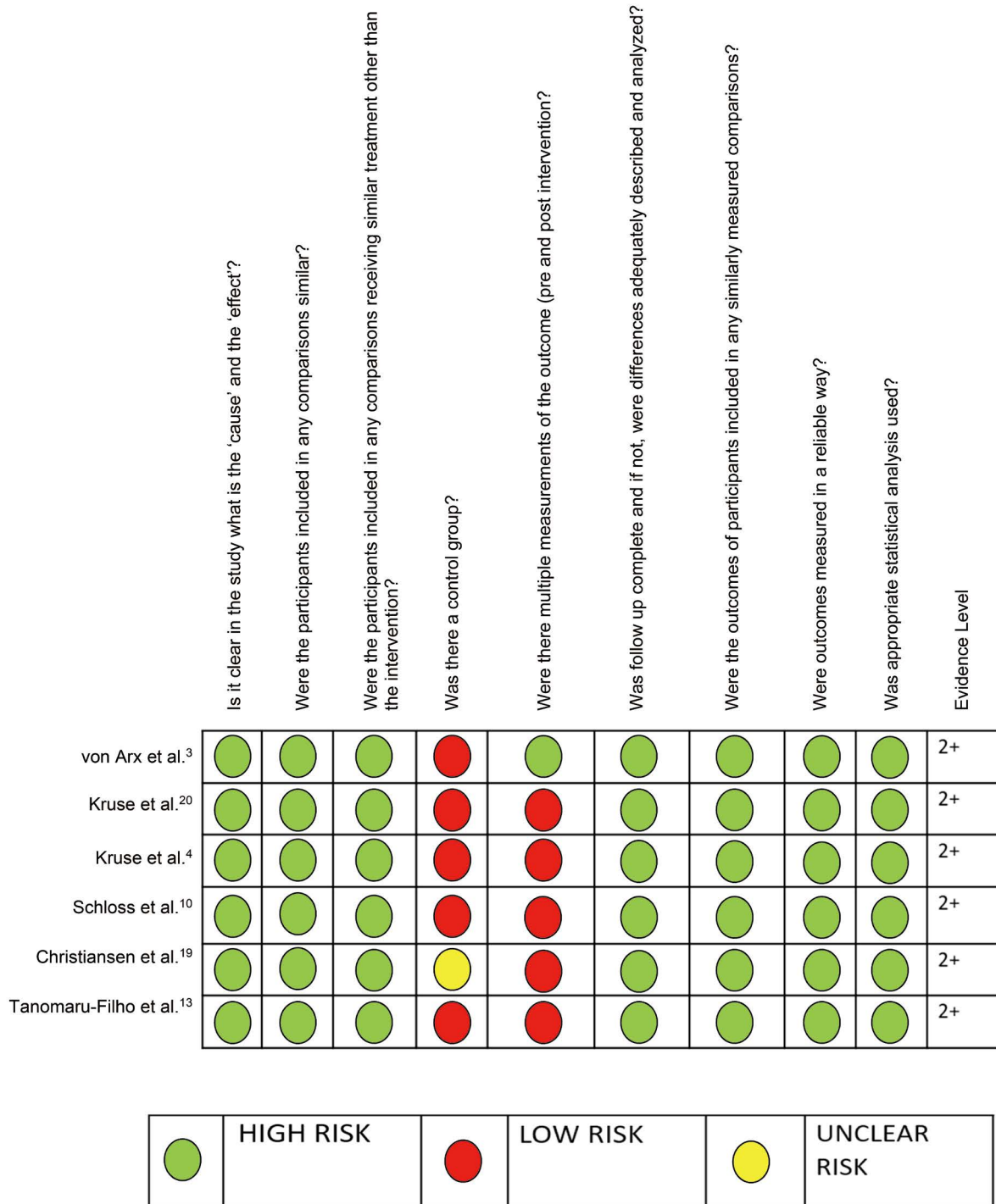


Fig. 3. Risk of bias assessment in clinical studies.

ration and root-end fillings.<sup>2</sup> Most original studies applied Molven's criteria for assessing healing after endodontic surgery, including the criteria of periapical radiographs showing potential clinical symptoms and radiographic healing, whereas evaluations of surgical endodontic healing based on CBCT imaging were conducted according to the modified

Penn 3D criteria.<sup>10</sup>

The introduction of CBCT in endodontic has made it possible to assess the periapical region with much greater accuracy.<sup>17</sup> Introduced in 1996, maxillofacial CBCT - created through the pioneering efforts of users of conventional computed tomography (CT) and micro-CT - provided the

first clinically practical technology that envisaged 3D imaging for endodontic considerations.<sup>24</sup> CBCT is a highly accurate 3D imaging technique, in addition to being one of the foremost diagnostic tools enabling the assessment of regenerated tissue. There is a high correlation between predictions based on CBCT and those based on histologic evidence, indicating that CBCT is an effective, non-invasive tool for the diagnosis of periapical lesions.<sup>23,25</sup>

Studies have demonstrated that the radiographic assessment of periapical healing differs between conventional periapical radiographs and CBCT imaging.<sup>6</sup> Many clinical studies have shown that 3D imaging provides a superior assessment of postoperative healing after periapical surgery than 2D imaging,<sup>17</sup> and more recent studies have confirmed that in cases where CBCT is employed for posttreatment radiographic follow-up, the rate of detection of persisting or non-healing periapical lesions after surgical endodontic retreatment is higher.<sup>20</sup>

Therefore, the use of CBCT prior to periradicular surgery can ensure accurate treatment planning.<sup>18</sup> Further, CBCT imaging shows a higher level of sensitivity in identifying periapical lesions than digital radiography.<sup>2</sup>

While periapical radiography is an integral part of endodontics used in both diagnosis and treatment, it also has some widely acknowledged limitations. Although periapical radiographs provide considerable important information about factors such as the progression, regression, and continuity of apical periodontitis, in some instances the periradicular region cannot be correctly evaluated using periapical radiographs. Pathologic bone loss in the apical region, unless in the late stages of its development, is usually undetectable on periapical radiographs. Furthermore, even if such pathologic bone loss presents on a periapical radiograph, its true dimensions are likely to be underrepresented. The superior capabilities of CBCT free the observer from the need to account for the issue of superimposition of structures in multiple planes, which is the primary issue with periapical radiography as an imaging modality. Multiple factors including the thickness of the cortical bone, the angle of incidence of X-rays, the extent and location of a lesion, and the existence of neighbouring anatomical structures may influence the 2D radiographic evaluation of periapical lesions. In contrast, the results obtained from the 3D measurement and evaluation of periapical lesions using CBCT images are usually considerably more reliable than the results obtained using 2D radiographs.<sup>26</sup> Grimard et al.<sup>27</sup> compared the measurements obtained from periapical radiographs and CBCT images, with the measurements recorded directly during periodontal surgery; the results showed that

the measurements from CBCT imaging had strong correlations with the actual measurements obtained during surgery, whereas periapical radiographs correlated less favourably. Another study implied that with the aid of CBCT, periapical radiolucencies as small as 0.5-1.0 mm in diameter could be detected and measured.<sup>24</sup> Further studies have also demonstrated the superiority of CBCT imaging over periapical radiographs in the detection and diagnosis of apical periodontitis.<sup>9</sup>

Several authors have studied correlations between the dimensions of postoperative bone defects and the assessments of endodontic microsurgery. Von Arx et al.<sup>28</sup> reported that the mesiodistal dimension of the bony crypt had a strong correlation with postoperative healing at follow-up examinations. Song et al.<sup>29</sup> concluded that the height of the remaining buccal bone plate was a significant indicator of surgical outcomes.<sup>5</sup> Molven's criteria were used to assess radiographic healing in 2D images (periapical X-ray films) as complete healing, incomplete healing, uncertain healing, and unsatisfactory healing.<sup>9</sup> The modified Penn 3D criteria were employed in the assessment of 3D healing using CBCT scans.<sup>10</sup> While 2D radiographic measurements only show the mesiodistal and apico-coronal extension, assessments based on 3D CBCT scans also measure and provide the depth of lesions.<sup>17</sup>

A review of the relevant literature showed that CBCT detects more periapical lesions than periapical radiography.<sup>4</sup> While there may be limitations in the use of CBCT imaging to represent smaller defects in an accurate manner, digital periapical radiography has been demonstrated to be even less accurate than CBCT imaging in this regard. The limitations of the study include the fact that results were inconsistently presented as cubic millimetres, volume, or percentages. Regular follow-up is required after endodontic surgery to evaluate the healing process. Few studies have compared postoperative healing assessed using periapical radiography versus CBCT with a follow-up period of 1 year.<sup>21</sup>

An advantage of this systematic review is that it included clinical studies and randomized control trials with a low risk of bias and a high grade of evidence (levels of 2 +/1 +). This review could conclude that many studies have shown insubstantial differences in healing assessments after periapical endodontic surgery using CBCT and conventional radiography, although some studies have shown that 3D radiography enables an overall better assessment of healing, which is imperative for correct diagnosis and treatment planning.

**Conflicts of Interest:** None



## References

- Meschi N, Vanhoenacker A, Strijbos O, Camargo Dos Santos B, Rubbers E, Peeters V, et al. Multi-modular bone healing assessment in a randomized controlled clinical trial of root-end surgery with the use of leukocyte-and platelet-rich fibrin and an occlusive membrane. *Clin Oral Investig* 2020; 24: 4439-53.
- Curtis DM, VanderWeele RA, Ray JJ, Wealleans JA. Clinician-centered outcomes assessment of retreatment and endodontic microsurgery using cone-beam computed tomographic volumetric analysis. *J Endod* 2018; 44: 1251-6.
- von Arx T, Janner SF, Hänni S, Bornstein MM. Agreement between 2D and 3D radiographic outcome assessment one year after periapical surgery. *Int Endod J* 2016; 49: 915-25.
- Kruse C, Spin-Neto R, Reibel J, Wenzel A, Kirkevang LL. Diagnostic validity of periapical radiography and CBCT for assessing periapical lesions that persist after endodontic surgery. *Dentomaxillofac Radiol* 2017; 46: 20170210.
- Kim D, Ku H, Nam T, Yoon TC, Lee CY, Kim E. Influence of size and volume of periapical lesions on the outcome of endodontic microsurgery: 3-dimensional analysis using cone-beam computed tomography. *J Endod* 2016; 42: 1196-201.
- von Arx T, Janner SF, Hänni S, Bornstein MM. Evaluation of new cone-beam computed tomographic criteria for radiographic healing evaluation after apical surgery: assessment of repeatability and reproducibility. *J Endod* 2016; 42: 236-42.
- Patel S, Durack C, Abella F, Shemesh H, Roig M, Lemberg K. Cone beam computed tomography in endodontics - a review. *Int Endod J* 2015; 48: 3-15.
- Rud J, Andreasen JO, Jensen JE. Radiographic criteria for the assessment of healing after endodontic surgery. *Int J Oral Surg* 1972; 1: 195-214.
- Molven O, Halse A, Grung B. Observer strategy and the radiographic classification of healing after endodontic surgery. *Int J Oral Maxillofac Surg* 1987; 16: 432-9.
- Schloss T, Sonntag D, Kohli MR, Setzer FC. A comparison of 2- and 3-dimensional healing assessment after endodontic surgery using cone-beam computed tomographic volumes or periapical radiographs. *J Endod* 2017; 43: 1072-9.
- Zetterqvist L, Hall G, Holmlund A. Apicectomy: a comparative clinical study of amalgam and glass ionomer cement as apical sealants. *Oral Surg Oral Med Oral Pathol* 1991; 71: 489-91.
- Jesslén P, Zetterqvist L, Heimdahl A. Long-term results of amalgam versus glass ionomer cement as apical sealant after apicectomy. *Oral Surg Oral Med Oral Pathol Oral Radiol Endod* 1995; 79: 101-3.
- Tanomaru-Filho M, Jorge ÉG, Guerreiro-Tanomaru JM, Reis JM, Spin-Neto R, Gonçalves M. Two- and tridimensional analysis of periapical repair after endodontic surgery. *Clin Oral Investig* 2015; 19: 17-25.
- Moher D, Liberati A, Tetzlaff J, Altman DG, PRISMA Group. Preferred reporting items for systematic reviews and meta-analyses: the PRISMA statement. *Ann Intern Med* 2009; 151: 264-9.
- Harbour R, Miller J. A new system for grading recommendations in evidence based guidelines. *BMJ* 2001; 323: 334-6.
- The Joanna Briggs Institute. Reviewer's Manual. Australia: The Joanna Briggs Institute 2014.
- Parmar PD, Dhamija R, Tewari S, Sangwan P, Gupta A, Duhan J, et al. 2D and 3D radiographic outcome assessment of the effect of guided tissue regeneration using resorbable collagen membrane in the healing of through-and-through periapical lesions - a randomized controlled trial. *Int Endod J* 2019; 52: 935-48.
- Kurt SN, Üstün Y, Erdogan Ö, Evlice B, Yoldas O, Öztunc H. Outcomes of periradicular surgery of maxillary first molars using a vestibular approach: a prospective, clinical study with one year of follow-up. *J Oral Maxillofac Surg* 2014; 72: 1049-61.
- Christiansen R, Kirkevang LL, Gotfredsen E, Wenzel A. Periapical radiography and cone beam computed tomography for assessment of the periapical bone defect 1 week and 12 months after root-end resection. *Dentomaxillofac Radiol* 2009; 38: 531-6.
- Kruse C, Spin-Neto R, Wenzel A, Vaeth M, Kirkevang LL. Impact of cone beam computed tomography on periapical assessment and treatment planning five to eleven years after surgical endodontic retreatment. *Int Endod J* 2018; 51: 729-37.
- Safi C, Kohli MR, Kratchman SI, Setzer FC, Karabucak B. Outcome of endodontic microsurgery using mineral trioxide aggregate or root repair material as root-end filling material: a randomized controlled trial with cone-beam computed tomographic evaluation. *J Endod* 2019; 45: 831-9.
- Singh S, Singh A, Singh S, Singh R. Application of PRF in surgical management of periapical lesions. *Natl J Maxillofac Surg* 2013; 4: 94-9.
- Karan NB, Aricioğlu B. Assessment of bone healing after mineral trioxide aggregate and platelet-rich fibrin application in periapical lesions using cone-beam computed tomographic imaging. *Clin Oral Investig* 2020; 24: 1065-72.
- Scarfè WC, Levin MD, Gane D, Farman AG. Use of cone beam computed tomography in endodontics. *Int J Dent* 2009; 2009: 634567.
- López FU, Kopper PM, Cucco C, Della Bona A, de Figueiredo JA, Vier-Pelisser FV. Accuracy of cone-beam computed tomography and periapical radiography in apical periodontitis diagnosis. *J Endod* 2014; 40: 2057-60.
- Tsai P, Torabinejad M, Rice D, Azevedo B. Accuracy of cone-beam computed tomography and periapical radiography in detecting small periapical lesions. *J Endod* 2012; 38: 965-70.
- Grimard BA, Hoidal MJ, Mills MP, Mellonig JT, Nummikoski PV, Mealey BL. Comparison of clinical, periapical radiograph, and cone-beam volume tomography measurement techniques for assessing bone level changes following regenerative periodontal therapy. *J Periodontol* 2009; 80: 48-55.
- von Arx T, Jensen SS, Hänni S. Clinical and radiographic assessment of various predictors for healing outcome 1 year after periapical surgery. *J Endod* 2007; 33: 123-8.
- Song M, Kim SG, Shin SJ, Kim HC, Kim E. The influence of bone tissue deficiency on the outcome of endodontic microsurgery: a prospective study. *J Endod* 2013; 39: 1341-5.