

Nonoperative management of colon and mesocolon injuries caused by blunt trauma: three case reports

Naa Lee, MD ^{ID}, Euisung Jeong, MD ^{ID}, Hyunseok Jang, MD ^{ID}, Yunchul Park, MD ^{ID}, Younggoun Jo, MD ^{ID}, Jungchul Kim, MD ^{ID}

Division of Trauma, Department of Surgery, Chonnam National University Hospital, Chonnam National University Medical School, Gwangju, Korea

The therapeutic approach for colon injury has changed continuously with the evolution of management strategies for trauma patients. In general, immediate laparotomy can be considered in hemodynamically unstable patients with positive findings on extended focused assessment with sonography for trauma. However, in the case of hemodynamically stable patients, an additional evaluation like computed tomography (CT) is required. Surgical treatment is often required if prominent mesenteric extravasation, free fluid, bowel infarction, and/or colon wall perforation are observed. However, immediate intervention in hemodynamically stable patients without indications for surgical treatment remains questionable. Three patients with colon and mesocolon injuries caused by blunt trauma were treated by nonoperative management. At the time of admission, they were alert and their vital signs were stable. Colon and mesocolon injuries, large hematoma, colon wall edema, and/or ischemia were revealed on CT. However, no prominent mesenteric extravasation, free fluid, bowel infarction, and/or colon wall perforation were observed. In two cases, conservative treatment was performed without worsening abdominal pain or laboratory tests. Follow-up CT showed improvement without additional treatment. In the third case, follow-up CT and percutaneous drainage were performed in considering the persistent left abdominal discomfort, fever, and elevated inflammatory markers of the patient. After that, outpatient CT showed improvement of the hematoma. In conclusion, nonoperative management can be considered as a therapeutic option for mesocolon and colon injuries caused by blunt trauma of selected cases, despite the presence of large hematoma and ischemia, if there are no clear indications for immediate intervention.

Keywords: Nonpenetrating wounds; Conservative treatment; Colon; Mesocolon; Case reports

Received: March 2, 2022

Revised: August 3, 2022

Accepted: August 17, 2022

Correspondence to

Jungchul Kim, MD

Division of Trauma, Department of Surgery, Chonnam National University Hospital, Chonnam National University Medical School, 160 Baekseo-ro, Dong-gu, Gwangju 61469, Korea

Tel: +82-62-220-5442

E-mail: jckim15@naver.com

INTRODUCTION

The therapeutic approach for colon and mesocolon injuries have changed continuously with the evolution of management strategies for trauma patients. However, there is ongoing debate regarding the therapeutic approach for blunt trauma. In general,

immediate laparotomy can be considered in hemodynamically unstable patients with positive findings on extended focused assessment with sonography for trauma (eFAST) [1]. However, in the case of hemodynamically stable patients, an additional evaluation is required [2]. Surgical treatment is often required if prominent mesenteric extravasation, free fluid, bowel infarction, and/

or colon wall perforation are observed on computed tomography (CT) [2]. Except for the above cases, nonoperative management is more often used and may be appropriate [3]. However, there are no clear guidelines for other colon and mesocolon injuries caused by blunt trauma. The blunt trauma causes serosal tears and devascularization of the colon without any findings that requires immediate treatment during initial evaluation, and it can eventually progress to bowel infarction or perforation [4]. Therefore, surgical intervention is considered necessary when hypoenhancement of the bowel wall is observed. However, immediate intervention in hemodynamically stable patients without prominent perforation or necrosis remains questionable [5].

In this study, we present several cases of nonoperative management of colon and mesocolon injuries caused by blunt trauma. The study was exempted from review by the Institutional Review Board of Chonnam National University Hospital due to minimal risk to subjects (No. CNUH-EXP-2021-284). Written informed consents were obtained from the patients.

CASE REPORTS

Case 1

A 67-year-old male patient was brought to the emergency department via a local hospital with a headache, chest, and abdomi-

nal pain caused by a traffic accident while walking. At the time of admission, the patient was alert, and his vital signs were stable, and left lower quadrant abdominal tenderness was noted. The patient is a known diabetic and has been under medications for 20 years with no other medical history. The results of laboratory investigations were as follows: white blood cell count, $20.2 \times 10^3/\mu\text{L}$ ($4.8 \times 10^3/\mu\text{L}$ – $10.8 \times 10^3/\mu\text{L}$); hemoglobin, 11.1 g/dL (12–18 g/dL); and lactate, 4.79 mmol/L (0.5–2.2 mmol/L). C-reactive protein (CRP) level was within normal limits. Radiological investigations revealed acute subdural hemorrhage, acute subarachnoid hemorrhage, fracture in the left transverse process of the L2 vertebra, left kidney injury, and fracture in the right superior wall of the orbit. The Injury Severity Score (ISS) was 13. CT scan performed 2 hours posttrauma at a local hospital revealed extravasation and a hematoma in the descending mesocolon (Fig. 1A). However, the patient's vital signs were stable. CT was repeated 5 hours posttrauma. There was no extravasation; however, ischemia in the splenic flexure of the colon could not be ruled out, and there was a diffuse edematous wall thickening in the descending colon and splenic flexure with hematoma of the mesocolon.

Abdominal pain was monitored continuously, and the patient began to drink water on the 1st day posttrauma, and ate liquid diet on the 2nd day. Conservative treatment was performed

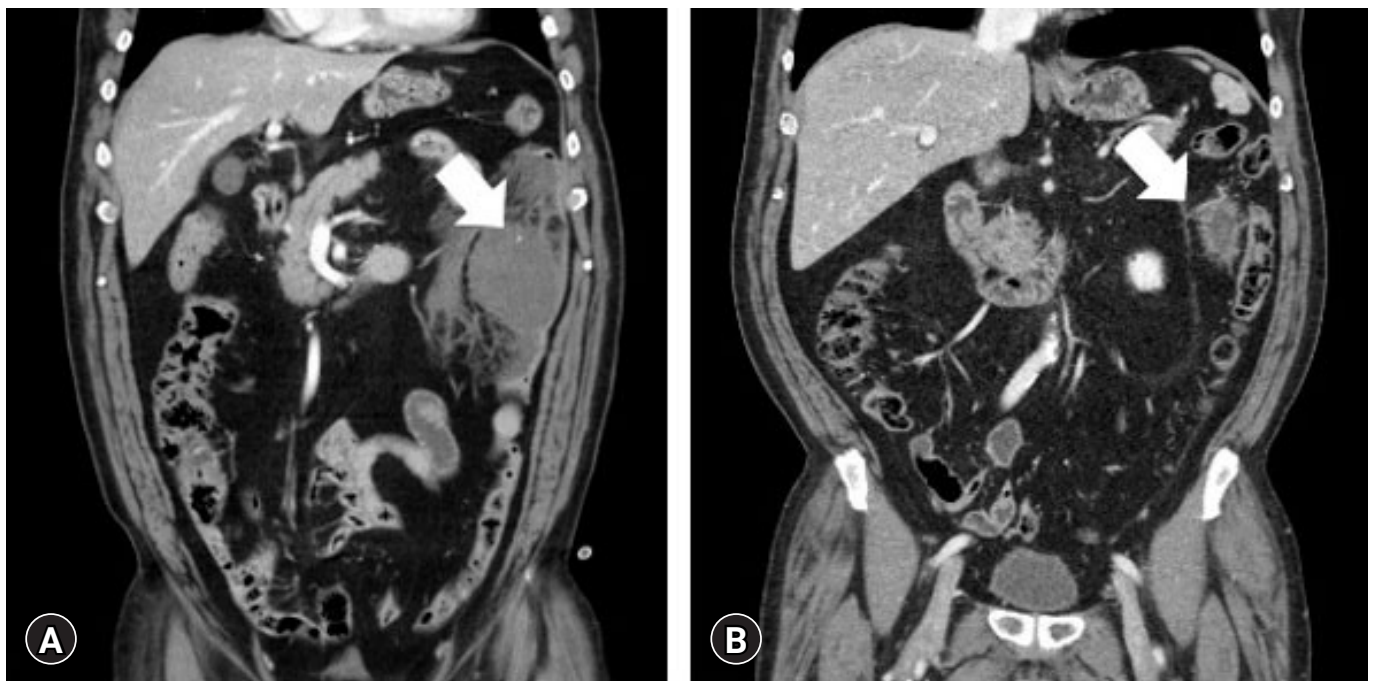


Fig. 1. Computed tomography scan performed (A) 2 hours and (B) 7 weeks posttrauma. (A) Extravasation (arrow) and a hematoma in the descending mesocolon. (B) A small amount of hematoma in the descending mesocolon (arrow).

without worsening abdominal pain or laboratory investigations. CT scan performed on the 10th day posttrauma revealed absorption of the hematoma without any deterioration, infarction, or perforation. Subsequently, CT scan performed 7 weeks posttrauma in the outpatient department revealed a small amount of hematoma and mild soft tissue stranding in the descending mesocolon (Fig. 1B).

Case 2

A 73-year-old male patient was brought to the emergency department via a local hospital with abdominal pain caused by falling over and bumping into a brick. At the time of admission, the patient was alert, and his vital signs were stable, and lower abdominal tenderness was noted. The patient is a known hypertension and has been under medication for 10 years. In addition, he was prescribed aspirin before 13 years due to stroke and continues to take the drug. The results of laboratory investigations were as follows: white blood cell count, $14.8 \times 10^3/\mu\text{L}$ ($4.8 \times 10^3/\mu\text{L}$ – $10.8 \times 10^3/\mu\text{L}$); hemoglobin, 12.2 g/dL (12–18 g/dL); lactate, 2.49 mmol/L (0.5–2.2 mmol/L); and CRP, 0.38 mg/dL (0–0.3 mg/dL). CT scan performed 4 hours posttrauma at a local hospital revealed a site suspected of ischemia and diffuse wall thickening in the sigmoid colon, and hematoma in the mesocolon with a circumference of 11 cm (Fig. 2A). He had no other injuries except

intraabdominal injury. The ISS was 4.

Abdominal pain was monitored continuously, and the patient began to drink water on the 1st day posttrauma, ate liquid diet on the 3rd day, and took aspirin on the 6th day. Conservative treatment was performed without worsening abdominal pain or laboratory investigations. CT scan performed on the 13th day posttrauma revealed absorption of the hematoma without any deterioration, infarction, or perforation. Subsequently, CT scan performed 7 weeks posttrauma in the outpatient department revealed a small 2.7-cm hematoma in the sigmoid mesocolon (Fig. 2B).

Case 3

A 48-year-old male patient was brought to the emergency department via a local hospital with abdominal pain caused by collision with another vehicle while investigating the scene of a traffic accident. At the time of admission, the patient was alert, and his vital signs were stable, and left side abdominal tenderness was noted. The patient did not report any medical history. Radiological investigation revealed fracture of the ninth rib on the left side. The results of laboratory investigations were as follows: white blood cell count, $8.2 \times 10^3/\mu\text{L}$ ($4.8 \times 10^3/\mu\text{L}$ – $10.8 \times 10^3/\mu\text{L}$); hemoglobin, 12.9 g/dL (12–18 g/dL); lactate, 1.63 mmol/L (0.5–2.2 mmol/L); and CRP, 1.14 mg/dL (0–0.3 mg/dL). CT scan performed 2 hours posttrauma at a local hospital revealed diffuse

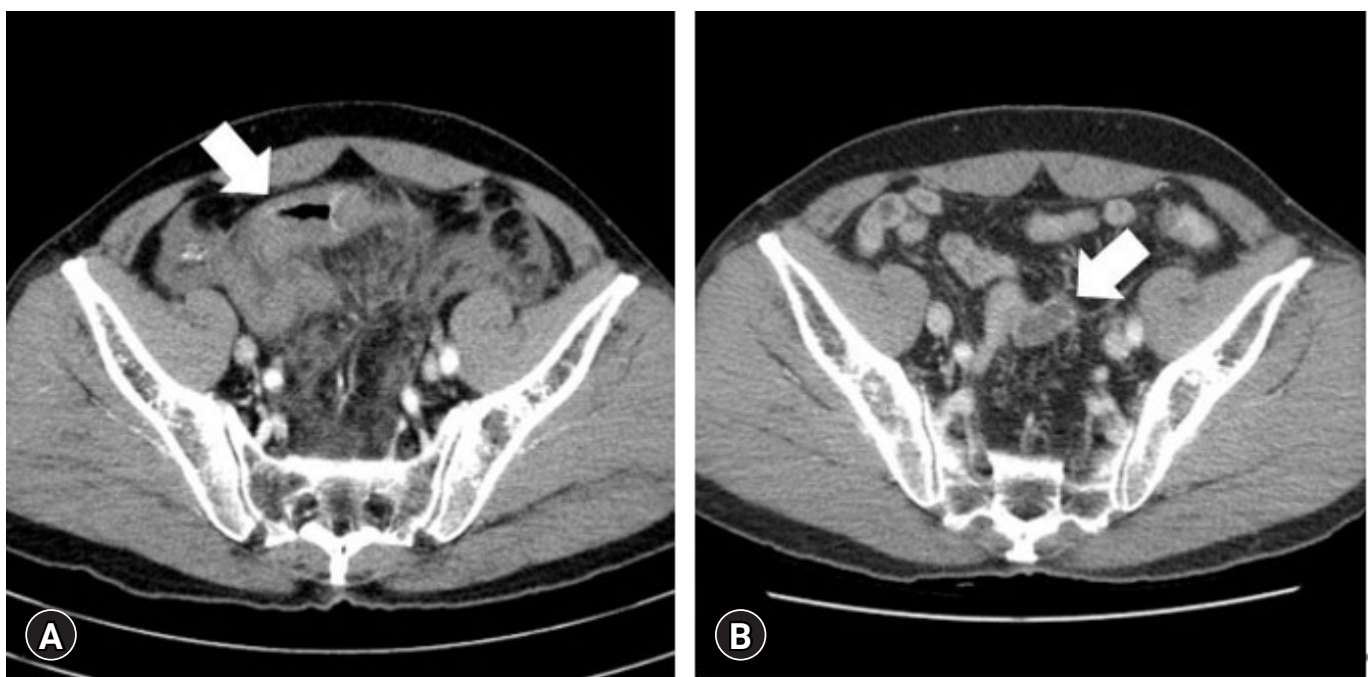


Fig. 2. Computed tomography scan performed (A) 4 hours and (B) 7 weeks posttrauma. (A) Ischemia and diffuse wall thickening in the sigmoid colon (arrow) and hematoma in the mesocolon with a circumference of 11 cm. (B) A 2.7-cm hematoma in the sigmoid mesocolon (arrow).

wall thickening in the splenic flexure and descending colon, and traumatic injury of the descending mesocolon with a hematoma measuring 13 cm (Fig. 3A). The ISS was 5.

Abdominal pain was monitored continuously, and the patient began to drink water on the 5th day posttrauma. Conservative treatment was performed without worsening abdominal pain or laboratory tests. CT scan performed on the 8th day posttrauma showed a slightly absorbed hematoma without any deterioration, infarction, or perforation of the colon.

Subsequently, the patient developed fever at the nighttime of 16th day posttrauma and complained of left side abdominal discomfort. The results of laboratory investigations were as follows: white blood cell count, $6.5 \times 10^3/\mu\text{L}$ ($4.8 \times 10^3/\mu\text{L}$ – $10.8 \times 10^3/\mu\text{L}$; neutrophils, 88.9%) and CRP, 10.57 mg/dL (0–0.3 mg/dL). Oral intake was withheld and piperacillin/tazobactam was started under close observation. To evaluate the cause of fever, abdominal CT scan was performed, which revealed more liquefaction and loculation of the hematoma measuring 7 cm and improvement in the traumatic injury of the descending mesocolon (Fig. 3B). However, considering the persistent left abdominal discomfort, fever, elevated inflammatory markers, and no other obvious cause of fever, percutaneous drainage was performed. Percutaneous drainage of the hematoma was done under fluoroscopy using an 8.5F catheter on the 18th day posttrauma. The pattern of drained fluid was dark red (old bloody), and the body fluid culture test reported no growth. The vital signs of the patient were stable without fever and improvement was observed in the inflammatory markers. The drainage catheter was maintained and removed after 7 days. Piperacillin/tazobactam was used for 9

days. Subsequently, CT scan performed 2 months posttrauma in the outpatient department revealed reduction in the size of the hematoma in the descending mesocolon to 2.8 cm (Fig. 3C).

DISCUSSION

The most common mechanism of injury in Korea is blunt injury (90.8%), as well as slip and fall down injuries (31.1%), vehicle associated accident (26.2%), and others [6]. Blunt abdominal trauma can cause intraabdominal organ injury. The intestines are the third most commonly injured organs in blunt trauma [7]. Small bowel injury accounts for 5% to 15% and colon injury accounts for 1% to 5% of blunt trauma cases [7,8]. In blunt trauma, patients with unstable vital signs and positive eFAST signs commonly require immediate intervention [1]. CT evaluation can be done in patients with stable vital signs. In colon and mesocolon injuries, specific findings on physical examination or CT, such as extraluminal fluid collection, discontinuity of the bowel wall, pneumoperitoneum, or bowel infarction, are indications for immediate intervention [9]. However, decision-making is often challenging in patients with colon and mesocolon injuries as there is no clear indications for surgical treatment [4,5].

There is currently no clear treatment guideline for the intestinal and mesenteric injury. For hollow viscus organ injury, there is a risk of increased morbidity and mortality when operation is delayed. Considering this, exploratory laparotomy had been performed in all cases of intestinal and mesenteric injury. However, there were many cases that surgery was not necessary in the end,

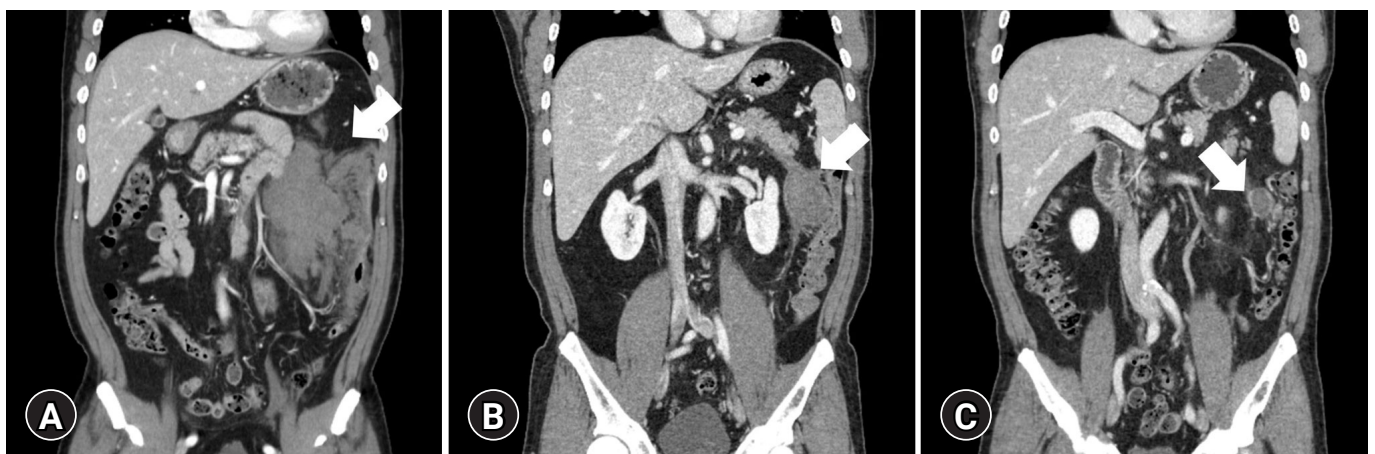


Fig. 3. Computed tomography scan performed (A) 2 hours, (B) 18 days, and (C) 2 months posttrauma. (A) Diffuse wall thickening in the splenic flexure (arrow) and descending colon, and traumatic injury of the descending mesocolon with a hematoma. (B) Liquefaction and loculation of the hematoma (arrow) and improvement in the traumatic injury of the descending mesocolon. (C) Reduction in the size of the hematoma in the descending mesocolon (arrow).

and the incidence was up to 44% for intestinal lesions and up to 31% for mesenteric lesions [3]. As a result, nonoperative management is being used more frequently and may be appropriate for hemodynamically stable patients without perforation or peritonitis [3]. Treatment trend is changing. In this case report, it is meaningful to introduce cases that nonoperative management could be performed even for colon ischemia and large hematoma of mesocolon on CT.

In the case of acute bowel ischemia with submucosal edema and a shaggy contour rather than bowel infarction, as our cases, nonoperative management can be performed if the mesenteric vessels are maintained [10]. However, as described above, bowel infarction is an immediate indication for laparotomy. Aggravation of pain and distension of abdomen or positive signs of peritonitis such as muscle guarding or rebound tenderness could indicate a worrisome situation such as progression to bowel infarction or perforation. In addition, vital signs and results of laboratory investigations are crucial and further evaluation options should be considered. The presence of devascularization and hematoma may lead to infarction and perforation; therefore, the therapeutic approach is decided based on the mechanism of injury, vital signs, symptoms, physical exam, laboratory investigations, and radiological investigations of the patient. In addition, the treatment plan can be changed according to the change of the patient's condition. The outcomes of the aforementioned cases suggest that nonoperative management could be a therapeutic option in patients with colon ischemia and mesocolon injuries with close monitoring. Moreover, this approach can be considered in cases of splenic flexure which is known as the watershed area and susceptible to ischemia, as reported in one of the aforementioned patients.

The nonoperative management of solid organ in trauma patient is a continuing trend [11]. Treatment for intestinal and mesenteric injury is also shifting towards nonoperative management unless there is an immediate indication for laparotomy [3]. By considering nonoperative management, nontherapeutic laparotomy can be reduced, and it can reduce the patient's pain and cost due to unnecessary laparotomy, as well as reduce morbidity such as mechanical ileus, hernia, and infection [12].

However, in the event of worsening of the patient's vital signs or abdominal pain or an increase in the white blood cell count, additional investigations should be considered immediately [13,14]. In particular, additional evaluation should be considered in unconscious patients in case of any change in vital signs [15]. It is important to consider the benefits of nonoperative management to the patient and the delay in surgical interven-

tion that could increase the rates of morbidity and mortality [4,5].

Moreover, the long-term outcomes of patients who undergo nonoperative treatment should be evaluated. Intraabdominal abscess is one of the complications of nonoperative management of blunt trauma. Although many posttraumatic hematomas resolve on their own, percutaneous approaches may be useful for therapeutic and diagnostic purposes [11].

In conclusion, nonoperative management can be considered as a therapeutic option for mesocolon and colon injuries caused by blunt trauma of selected cases, despite the presence of large hematoma and ischemia, if there are no clear indications for immediate intervention.

NOTES

Ethical statements

The study was exempted from review by the Institutional Review Board of Chonnam National University Hospital due to minimal risk to subjects (No. CNUH-EXP-2021-284). Written informed consents were obtained from the patients.

Conflicts of interest

The authors have no conflicts of interest to declare.

Funding

None.

Author contributions

Conceptualization: EJ; Methodology: HJ; Software: HJ; Formal analysis: EJ; Investigation: NL; Resources: YP; Data curation: NL; Supervision: YJ; Project administration: JK; Visualization: YP, EJ; Writing—original draft: NL, HJ; Writing—review & editing: YJ, JK. All authors read and approved the final manuscript.

REFERENCES

1. Feliciano DV, Mattox KL, Moore EE. Trauma. 9th ed. New York: McGraw Hill; 2020.
2. Brofman N, Atri M, Hanson JM, Grinblat L, Chughtai T, Brenneman F. Evaluation of bowel and mesenteric blunt trauma with multidetector CT. *Radiographics* 2006;26:1119–31.
3. Bege T, Brunet C, Berdah SV. Hollow viscus injury due to blunt trauma: a review. *J Visc Surg* 2016;153(4 Suppl):61–8.
4. Singh M, Dalal S, Amandeep VS. Delayed presentation of an isolated sigmoid colon injury following blunt abdominal

- trauma: a case report & review of literature. *OGH Rep* 2017;6:75–6.
5. Tilden W, Griffiths M, Cross S. Vascular bowel and mesenteric injury in blunt abdominal trauma: a single centre experience. *Clin Radiol* 2021;76:213–23.
 6. Byun CS, Park IH, Oh JH, Bae KS, Lee KH, Lee E. Epidemiology of trauma patients and analysis of 268 mortality cases: trends of a single center in Korea. *Yonsei Med J* 2015;56:220–6.
 7. Dauterive AH, Flancbaum L, Cox EF. Blunt intestinal trauma. A modern-day review. *Ann Surg* 1985;201:198–203.
 8. Fakhry SM, Allawi A, Ferguson PL, et al. Blunt small bowel perforation (SBP): an Eastern Association for the Surgery of Trauma multicenter update 15 years later. *J Trauma Acute Care Surg* 2019;86:642–50.
 9. Kim HC, Shin HC, Park SJ, et al. Traumatic bowel perforation: analysis of CT findings according to the perforation site and the elapsed time since accident. *Clin Imaging* 2004;28:334–9.
 10. Romano S, Lassandro F, Scaglione M, Romano L, Rotondo A, Grassi R. Ischemia and infarction of the small bowel and colon: spectrum of imaging findings. *Abdom Imaging* 2006;31:277–92.
 11. Stawicki SP. Trends in nonoperative management of traumatic injuries: a synopsis. *Int J Crit Illn Inj Sci* 2017;7:38–57.
 12. Bowie JM, Badiee J, Calvo RY, et al. Outcomes after single-look trauma laparotomy: a large population-based study. *J Trauma Acute Care Surg* 2019;86:565–72.
 13. Sharpe JP, Magnotti LJ, Weinberg JA, et al. Applicability of an established management algorithm for colon injuries following blunt trauma. *J Trauma Acute Care Surg* 2013;74:419–24.
 14. Lannes F, Scemama U, Maignan A, et al. Value of early repeated abdominal CT in selective non-operative management for blunt bowel and mesenteric injury. *Eur Radiol* 2019;29:5932–40.
 15. Brekke IJ, Puntervoll LH, Pedersen PB, Kellett J, Brabrand M. The value of vital sign trends in predicting and monitoring clinical deterioration: a systematic review. *PLoS One* 2019;14:e0210875.