

Coinfection of *Sphingomonas paucimobilis* meningitis and *Listeria monocytogenes* bacteremia in an immunocompetent patient: a case report

Sang Woon Bae¹, Jong Ho Lee²

¹Department of Internal Medicine, Yeungnam University Hospital, Daegu, Korea

²Department of Laboratory Medicine, Yeungnam University College of Medicine, Daegu, Korea

This report describes a case of coinfection of *Sphingomonas paucimobilis* meningitis and *Listeria monocytogenes* bacteremia in a 66-year-old immunocompetent female patient. The patient had undergone traditional procedures, including acupuncture, which possibly caused the coinfection. During treatment with susceptible antibiotics for bacterial meningitis, she developed hydrocephalus on the third day. Consequently, the patient recovered with a mild neurological deficit of grade 4 motor assessment in both upper and lower extremities at discharge. *S. paucimobilis* and *L. monocytogenes* are rare pathogens in developed countries, occurring only during environmental outbreaks. *S. paucimobilis* meningitis is rarely reported. Hence, the various presentations of *S. paucimobilis* meningitis and the antibiotic regimen for its treatment are hereby reported, in addition to a review of other similar reported cases. This case is a possible traditional procedure-related infection. Appropriate oversight and training should be emphasized regarding preventive measures of this kind of infection. A team approach with neurologists and neurosurgeons is imperative in treating patients with hydrocephalus-complicated meningitis.

Keywords: Bacteremia; Coinfection; *Listeria*; Meningitis; *Sphingomonas*

Introduction

Sphingomonas paucimobilis is a gram-negative, nonfermenter, and community-acquired bacteria [1]. *Sphingomonas* spp. has been isolated from seawater, river water, wastewater, mineral water, and water-based hospital equipment [2]. Several hospital outbreaks of *S. paucimobilis*, mainly catheter-associated infections, have been reported [3,4]. Although *S. paucimobilis* has low virulence, it may still cause meningitis and bacteremia. *S. paucimobilis* infection involving the central nervous system can manifest as meningitis and ventriculitis.

Listeria monocytogenes is a gram-positive pathogenic bacterium found in soil and water [5]. Community-acquired infections generally occur during foodborne outbreaks [6]. Common *L. monocytogenes* infections have been reported as gastrointestinal tract infections, meningitis, and bacteremia [6,7]. Infections in neonates and the elderly have higher rates of mortality and morbidity [6,7].

This case report described the case of an immunocompetent host with *S. paucimobilis* meningitis and *L. monocytogenes* bacteremia.

Received: April 24, 2021 • Revised: May 15, 2021 • Accepted: May 16, 2021

Corresponding author: Sang Woon Bae, MD

Department of Internal Medicine, Yeungnam University Hospital, 170 Hyeonchung-ro, Nam-gu, Daegu 42415, Korea

Tel: +82-53-620-3145 • Fax: +82-53-654-8386 • E-mail: sangoon@gmail.com

Copyright © 2022 Yeungnam University College of Medicine, Yeungnam University Institute of Medical Science

This is an Open Access article distributed under the terms of the Creative Commons Attribution Non-Commercial License (<http://creativecommons.org/licenses/by-nc/4.0/>) which permits unrestricted non-commercial use, distribution, and reproduction in any medium, provided the original work is properly cited.

Case

Ethical statements: This study was approved by the Institutional Review Board (IRB) of the Yeungnam University Hospital (IRB No: 2020-01-018). Written informed consent was obtained for publication of this case report and accompanying images.

A 66-year-old woman complained of fever, slight drowsiness, and neck stiffness for 5 days. The patient complained of no gastrointestinal symptoms. Eight days before her admission, she had received acupuncture more than 100 times and moxibustion cupping on both sides of her posterior neck. She had no history of diabetes, hypertension, or corticosteroid use. Thirteen months before this event, the patient had received her final adjuvant chemotherapy for breast cancer after mastectomy. One day before her admission, she had visited a nearby hospital, and the brain magnetic resonance imaging (MRI) findings were unremarkable and showed no meningeal enhancement. The hospital referred her to a tertiary hospital for further evaluation of her neck stiffness as she had no Kernig or Brudzinski signs. There were few round thin bruise-like lesions from the previous cupping procedure without tenderness or swelling on inspection. Her vital signs were as follows: blood pressure, 160/100 mmHg; heart rate, 75 beats/min; respiratory rate, 20 breaths/min; and body temperature, 39.1°C. Her initial Glasgow Coma Scale (GCS) score was 15, while her motor assessment result was grade 5. Her sensory assessment result was unremarkable. The initial cerebrospinal fluid (CSF) analysis results revealed a white blood cell (WBC) count of 429/ μ L (polymorphonucleocytes [PMN], 62%), red blood cell count of 100/ μ L, glucose of 11 mg/dL, adenosine deaminase of 19.7 IU/L, protein level of 369.51 mg/dL, and an opening pressure of 100 mmHg. The fluid was yellowish with a turbid nature. For culture, an uncentrifuged CSF sample was inoculated onto one blood agar plate (Komed Corp., Ltd., Seongnam, Korea), one chocolate agar plate (Komed Corp., Ltd.), and BBL Fluid thioglycollate medium (BD, Sparks, MD, USA).

Identification and antimicrobial susceptibility tests were performed using VITEK 2 (software version 08.01; bioMérieux, Marcy-l'Étoile, France). The laboratory blood results were as follows: WBC of 11,520/ μ L, hemoglobin of 13 g/dL, high-sensitivity C-reactive protein of 18.791 mg/dL, erythrocyte sedimentation rate of 33 mm/hr, glucose of 174 mg/dL, and total protein of 6.08 g/L. For blood culture, each bottle of two blood culture media sets (BACT/ALERT SA & SN; bioMérieux) was inoculated with 10 to 15 mL of blood. The identification process was performed using VITEK MS (bioMérieux). VITEK 2 was used for antimicrobial

susceptibility tests for the blood culture. The patient was diagnosed with bacterial meningitis. She received antibiotic treatment with vancomycin and ceftazidime. Intravenous dexamethasone sodium phosphate (0.6 mg/kg/day every 6 hours) was given for 5 days.

On her third hospitalization day (HD), her mental status deteriorated, and she was intubated. Subsequently, brain computed tomography (CT) showed signs consistent with hydrocephalus (Fig. 1), and an emergency external ventricular drainage (EVD) was inserted. On HD 5, the culture results of the initial CSF sample revealed *S. paucimobilis*, which was susceptible to cefotaxime (minimal inhibitory concentration [MIC] \leq 1), ciprofloxacin (MIC = 0.5), ceftazidime (MIC = 8), and cefepime (MIC \leq 1) but resistant to colistin (MIC \geq 16). Two bottles of the initial blood culture results revealed *L. monocytogenes* susceptible to ampicillin (MIC \leq 0.25) and vancomycin (MIC = 0.5) but resistant to ciprofloxacin (MIC = 1) and oxacillin (MIC \geq 4). The treatment was switched to ampicillin/sulbactam and ceftriaxone on the HD 6.

The patient's mental status and laboratory findings gradually improved. On the 14th HD at 3:25 PM, the EVD was removed, as she responded to all verbal questions and directions (intact place, time, and person orientation, and her motor grade was 4), and she was transferred from the intensive care unit to a general ward. Two hours after EVD was removed, the patient exhibited a sudden deterioration of mental status (deep drowsiness) and presented with an enlarged left ventricle, which was seen on brain CT and received a second EVD insertion. CSF analysis results were as follows: WBC count of 12/ μ L (PMN, 90%), red blood cell count of 3,500/ μ L, glucose of 61 mg/dL, and protein level of 29.28 mg/dL. The fluid was pinkish. Later, the neurosurgery team inserted a ventriculoperitoneal (VP) shunt. On HD 28, her GCS score was 15; her motor assessment results were all grade 4; her Mini-Mental State Examination (MMSE) score was 11; her functional ambulation categories (FAC) score was 2. She was transferred to a rehabilitation hospital on HD 91. About 5 months later, the patient's status improved to a GCS score of 15, motor grades 4, a FAC score of 3.5, and an MMSE score of 21.

Overall, the patient's antibiotic regimen consisted of ceftriaxone (2 g every 12 hours) and vancomycin (1 g every 12 hours) for 6 days, followed by switching to ampicillin/sulbactam (3 every 6 hours) and ceftriaxone (2 g every 12 hours) for 21 days. Thus, her antibiotic treatment lasted for a total of 26 days.

Discussion

S. paucimobilis can be isolated from seawater, river water, invertebrates residing in water, and water distribution systems, including hospital environments [2]. This organism is often responsible for

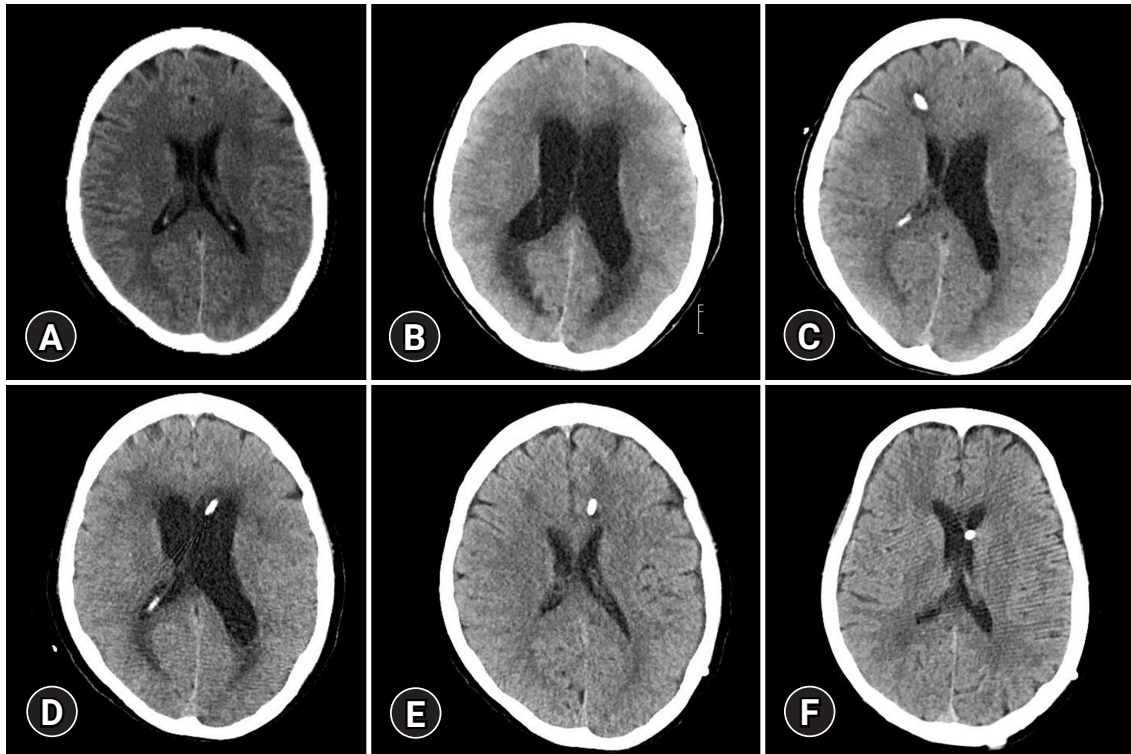


Fig. 1. Computed tomography images of the brain. (A) On hospitalization day (HD) 1, without enlarged ventricles; (B) on HD 3, with the enlarged ventricle; (C) on HD 10, with the enlarged left ventricle and emergency external ventricular drainage, inserted at right Kocher's point; (D) on HD 32, with the enlarged ventricle and emergency external ventricular drainage, inserted at left Kocher's point; (E) on HD 45, with a normal ventricle size and ventriculoperitoneal (VP) shunt inserted at left Kocher's point; and (F) 4 months after discharge, with normal-sized ventricles and VP shunt.

catheter-associated infections and hospital outbreaks [3,4]. *S. paucimobilis* infection usually occurs in severely ill patients, including immunocompromised patients, due to its low virulence. Most case reports of *S. paucimobilis* infection presented with primary bacteremia and were often associated with catheter-associated infections [3,4,8]. Only a few cases of *S. paucimobilis* central nervous system infection have been reported (Table 1) [4,9-15]. When this pathogen infects the central nervous system and the adjacent tissue, the prognosis varies from baseline function recovery to severe disability and even death [9-11]. The treatment duration for meningitis caused by gram-negative bacteria has not been clearly defined [16].

Table 1 contains nine case reports of *S. paucimobilis* meningitis, including this case. Bacterial meningitis is challenging to diagnose due to its various clinical signs and symptoms [17]. Among these reports, some had normal radiological findings with atypical clinical presentations of meningitis during the first clinical visit, like this case [13,15]. Four out of nine *S. paucimobilis* meningitis cases were complicated with hydrocephalus [4,10,13].

L. monocytogenes, a foodborne pathogen, is relatively common. More than 70% of listeriosis cases occur in patients with recognized underlying diseases, such as liver disease, cancer, and diabetes [18].

In the current case, the patient had no gastrointestinal symptoms. However, it must be noted that she had breast cancer, for which she had received the last adjuvant chemotherapy 13 months before. Her history of breast cancer and age of 66 years had thus increased her risk of listeriosis [18]. Furthermore, there are several cases of listeriosis that are linked to traditional procedures such as acupuncture [19]. Mixed infections in adult bacterial meningitis were reviewed by Chang et al. [20]. The authors analyzed 12 cases of CSF polymicrobial culture results. They concluded that mixed-infection adult bacterial meningitis was mainly of a nosocomial nature and associated with underlying conditions such as VP shunt.

Two different pathogens were obtained in the CSF and blood from the initial evaluation in the presented patient. Given her past medical history, a coinfection with *S. paucimobilis* meningitis and *L. monocytogenes* bacteremia without gastrointestinal signs and symptoms suggested a possible procedure-related infection from the acupuncture and cupping after moxibustion.

Xu et al. [19] reviewed 308 cases of acupuncture, moxibustion, and cupping that were associated with adverse events. One of the most common adverse events in these cases was infection. Traditional procedures, including acupuncture, are often performed by

Table 1. Case reports of *Sphingomonas paucimobilis* meningitis

Study	Age (yr) /sex	Country/year	Immunologic status and history	Radiological finding	CSF/Whole blood culture result	Treatment and duration	Outcome
Hajjiroussou et al. [9]	39/M	United Kingdom/1979	Immunocompetent	Not mentioned in the report	<i>Sphingomonas paucimobilis</i> / <i>S. paucimobilis</i>	Streptomycin, rifampicin, isoniazid for 4 days	Recovery to baseline
Tai and Velayuthan [10]	31/M	Malaysia/2014	Immunocompetent, open wound in the leg	In CT, meningeal enhancement, and cerebral edema	<i>S. paucimobilis</i> /not commented in the report	Ceftriaxone, acyclovir, anti-TB medication for 3 days	Death
Bolen et al. [11]	39/F	United States/2015	Immunocompromised	In MRI, diffuse periventricular T2 hyperintensities along the lateral ventricles and the third ventricle consistent with ventriculitis	<i>S. paucimobilis</i> /not commented in the report	Vancomycin, ceftriaxone, ampicillin for 21 days	Recovery to baseline
Deveci et al. [12]	14.5/M	Turkey/2017	Immunocompetent	In MRI, meningeal contrasting of the frontal region, T2 signal increase, findings of mucosal thickening, and leveling in paranasal sinuses	<i>S. paucimobilis</i> /negative result	Vancomycin, ceftriaxone for 14 days	Recovery to baseline
Göker et al. [4]	48/F	Turkey/2017	Immunocompetent	Basal ganglia and intra-ventricular hemorrhage. No evidence of infection	<i>S. paucimobilis</i> /not commented in the report	Meropenem for 46 days	Death
Mehmood et al. [13]	50/F	United States/2018	Immunocompetent	Unremarkable neck CT and brain MRI	<i>S. paucimobilis</i> /not commented in the report	Meropenem for 21 days	Recovery to baseline
Ciftci et al. [14]	13/F	Turkey/2018	Immunocompetent, with VP shunt placed ten years ago	Not mentioned in the report	<i>S. paucimobilis</i> /not commented in the report	Vancomycin, meropenem, VP shunt removal, levofloxacin for 35 days	Recovery to baseline
Orozco-Hernández et al. [15]	3/M	Colombia/2019	Immunocompetent, exposure to contaminated water	Unremarkable brain CT	<i>S. paucimobilis</i> /negative result	Ceftriaxone for 14 days	Recovery to baseline
Current case	66/F	South Korea/2021	Immunocompetent, final chemotherapy 1-year ago due to breast cancer	Unremarkable initial brain MRI, brain CT on HD 3 showed signs of hydrocephalus	<i>S. paucimobilis</i> / <i>Listeria monocytogenes</i>	Ceftriaxone and vancomycin switched to ampicillin/sulbactam and ceftriaxone on HD 6 for 21 days	Bed-ridden with VP shunt, recovering without permanent neurological deficit

CSF, cerebrospinal fluid; M, male; F, female; CT, computed tomography; TB, tuberculosis; MRI, magnetic resonance imaging; VP, ventriculoperitoneal; HD, hospitalization day.

unlicensed people without medical training. There are many open classes and YouTube videos teaching and promoting traditional procedures to the public that do not discuss the concepts of infectious diseases or regulations issued by proper authorities. Public bath places equipped with cupping and moxibustion are ubiquitous. Furthermore, in reviewing this case and other case reports of procedure-related infection, licensed medical practitioners are also responsible for procedure-related infections. The risk of infectious diseases in these settings should be emphasized through proper supervision and education from qualified authorities.

For patients like this, close observation is recommended to initiate surgical treatment without delay. Constant neurological observation, prompt surgical responses, and a suitable antibiotic regimen are essential for treating *S. paucimobilis* meningitis complicated with hydrocephalus.

Notes

Conflicts of interest

No potential conflict of interest relevant to this article was reported.

Author contributions

Conceptualization, Methodology, Investigation, Visualization, Resources, Supervision: SWB; Data curation, Validation: SWB, JHL; Writing-original draft: SWB; Writing-review & editing: SWB, JHL.

ORCID

Sang Woon Bae, <https://orcid.org/0000-0003-0860-4303>

Jong Ho Lee, <https://orcid.org/0000-0002-6837-838X>

References

- Cheong HS, Wi YM, Moon SY, Kang CI, Son JS, Ko KS, et al. Clinical features and treatment outcomes of infections caused by *Sphingomonas paucimobilis*. *Infect Control Hosp Epidemiol* 2008;29:990–2.
- Ryan MP, Adley CC. *Sphingomonas paucimobilis*: a persistent Gram-negative nosocomial infectious organism. *J Hosp Infect* 2010;75:153–7.
- Crane LR, Tagle LC, Palutke WA. Outbreak of pseudomonas paucimobilis in an intensive care facility. *JAMA* 1981;246:985–7.
- Göker T, Aşık RZ, Yılmaz MB, Çelik İ, Tekiner A. *Sphingomonas paucimobilis*: a rare infectious agent found in cerebrospinal fluid. *J Korean Neurosurg Soc* 2017;60:481–3.
- Kim T, Kim DY, Sung H, Kim MN, Kim SH, Choi SH, et al. A case of pneumonia with pleural effusion caused by *Listeria monocytogenes*. *Infect Chemother* 2012;44:87–91.
- Schlech WF. Epidemiology and clinical manifestations of *Listeria monocytogenes* infection. *Microbiol Spectr* 2019;7:GPP3-0014-2018.
- Pagliano P, Ascione T, Boccia G, De Caro F, Esposito S. *Listeria monocytogenes* meningitis in the elderly: epidemiological, clinical and therapeutic findings. *Infez Med* 2016;24:105–11.
- Toh HS, Tay HT, Kuar WK, Weng TC, Tang HJ, Tan CK. Risk factors associated with *Sphingomonas paucimobilis* infection. *J Microbiol Immunol Infect* 2011;44:289–95.
- Hajiroussou V, Holmes B, Bullas J, Pinning CA. Meningitis caused by *Pseudomonas paucimobilis*. *J Clin Pathol* 1979;32:953–5.
- Tai ML, Velayuthan RD. *Sphingomonas paucimobilis*: an unusual cause of meningitis: case report. *Neurol Med Chir (Tokyo)* 2014;54:337–40.
- Bolen RD, Palavecino E, Gomadam A, Balakrishnan N, Datar S. *Sphingomonas paucimobilis* meningitis and ventriculitis in an immunocompromised host. *J Neurol Sci* 2015;359:18–20.
- Deveci N, Gürkan N, Belet N, Baysal SU. *Sphingomonas paucimobilis*: an uncommon cause of meningitis. *J Pediatr Inf* 2017;11:e124–8.
- Mehmood H, Khan N, Ullah S, Ullah A, Marwat A. A rare case of *Sphingomonas paucimobilis* meningitis in the absence of cerebrospinal fluid pleocytosis. *J Investig Med High Impact Case Rep* 2018;6:2324709618756424.
- Ciftci N, Dagi HT, Alkan G, Ates F, Tuncer I. Meningitis due to *Sphingomonas paucimobilis* in a pediatric patient: a case report. *Acta Microbiol Bulg* 2018;34:126–9.
- Orozco-Hernández JP, Valencia-Vásquez A, Gil-Restrepo AF. *Sphingomonas paucimobilis* meningitis in a child: first case report. *EC Neurol* 2019;11:127–9.
- Quagliarello VJ, Scheld WM. Treatment of bacterial meningitis. *N Engl J Med* 1997;336:708–16.
- van de Beek D, de Gans J, Spanjaard L, Weisfelt M, Reitsma JB, Vermeulen M. Clinical features and prognostic factors in adults with bacterial meningitis. *N Engl J Med* 2004;351:1849–59.
- Goulet V, Hebert M, Hedberg C, Laurent E, Vaillant V, De Valk H, et al. Incidence of listeriosis and related mortality among groups at risk of acquiring listeriosis. *Clin Infect Dis* 2012;54:652–60.
- Xu S, Wang L, Cooper E, Zhang M, Manheimer E, Berman B, et al. Adverse events of acupuncture: a systematic review of case reports. *Evid Based Complement Alternat Med* 2013;2013:581203.
- Chang WN, Lu CH, Huang CR, Chuang YC. Mixed infection in adult bacterial meningitis. *Infection* 2000;28:8–12.