

Original Article

## Color Distribution of Maxillary Permanent Incisors in Korean Pediatric Patients Using a Spectrophotometer

Seunghyun Oh, Hyuntae Kim, Teo Jeon Shin, Hong-Keun Hyun, Young-Jae Kim, Jung-Wook Kim, Ki-Taeg Jang, Ji-Soo Song  
Department of Pediatric Dentistry, Dental Research Institute, School of Dentistry, Seoul National University, Seoul, Republic of Korea

### Abstract

This study aims to analyze the color distribution of maxillary permanent incisors in Korean pediatric patients and determine the effects of age and root developmental stage on tooth color. The L\*a\*b\* values of 404 sound and fully erupted maxillary incisors without dental caries, restorations, trauma history or discoloration from 101 Korean patients between ages 7 and 15, with a mean age  $10.0 \pm 1.5$ , were analyzed with a spectrophotometer. CIE L\*a\*b\* values were 84.01, 0.17, and 24.07 in maxillary central incisors, and 82.33, 0.31, and 25.99 in maxillary lateral incisors. L\* values of maxillary central incisors were higher, and b\* values of maxillary central incisors were lower than those of maxillary lateral incisors ( $p < 0.001$ ). The color differences among the subregions exceeded the clinical perceptibility threshold in both of the maxillary central and lateral incisors. L\* value for children at age 10 and younger was 84.13 in maxillary central incisors and 84.04 in maxillary lateral incisors, and those of older patients were 80.62 and 80.56, respectively. L\* value of maxillary incisors of children at age 10 and younger was significantly higher than that of older patients. The root developmental stage did not affect tooth color. This study suggests that the color differences between maxillary central and lateral incisors and among the subregions of a tooth and the effects of age should be considered for aesthetic restorations of permanent incisors in pediatric patients. [J Korean Acad Pediatr Dent 2022;49(4):414-427]

### Keywords

Maxillary incisors; Spectrophotometer; Color distribution; Dental developmental stage; Chronological age; Dental age

## Introduction

Recently, the importance of aesthetic restorations has emerged not only in

### ORCID

Seunghyun Oh  
<https://orcid.org/0000-0002-4004-1275>  
Hyuntae Kim  
<https://orcid.org/0000-0003-2915-8584>  
Teo Jeon Shin  
<https://orcid.org/0000-0003-4499-8813>  
Hong-Keun Hyun  
<https://orcid.org/0000-0003-3478-3210>  
Young-Jae Kim  
<https://orcid.org/0000-0003-4916-6223>  
Jung-Wook Kim  
<https://orcid.org/0000-0002-9399-2197>  
Ki-Taeg Jang  
<https://orcid.org/0000-0002-4060-9713>  
Ji-Soo Song  
<https://orcid.org/0000-0002-4469-5903>

### Article history

Received July 12, 2022  
Revised September 5, 2022  
Accepted September 7, 2022

© 2022 Korean Academy of Pediatric Dentistry  
© This is an Open Access article distributed under the terms of the Creative Commons Attribution Non-Commercial License (<http://creativecommons.org/licenses/by-nc/4.0>) which permits unrestricted non-commercial use, distribution, and reproduction in any medium, provided the original work is properly cited.

### Corresponding author: Ji-Soo Song

Department of Pediatric Dentistry, Dental Research Institute, School of Dentistry, Seoul National University, 101 Daehak-ro, Jongno-gu, Seoul, 03080, Republic of Korea  
Tel: +82-2-2072-3080 / Fax: +82-2-744-3599 / E-mail: pedosong@snu.ac.kr

### Funding information

This work was supported by the New Faculty Startup Fund from Seoul National University.

adults but also in children and adolescents[1]. It shows that the color reproduction that harmonizes with the oral environment should be considered in addition to pain relief and functional rehabilitation in the anterior restoration. For growing children whose gingiva shape and crown exposure are constantly changing, direct composite resin restoration is preferable in cases of crown fracture, because it allows for a relatively simple procedure and preservation of tooth structure[2].

The color is recognized by the detection of the wavelengths of reflected visible light by the human eye. The color has properties of hue, brightness, and saturation. The Commission International de L'Eclairage (CIE) defined the color space in 1976, and it has been mainly used for quantifying the color properties recognized by the human eye[3]. CIE color space system is expressed by  $L^*$ ,  $a^*$ , and  $b^*$  values as three-dimensional spatial coordinates.  $L^*$  value quantifies perceptual lightness, which defines black as 0 and white as 100.  $a^*$  value is relative to green to red color scale, and  $b^*$  value is relative to blue to yellow color scale. The color difference,  $\Delta E^*_{ab}$ , is defined as a vector in the color space. The formula of the color difference is  $\Delta E^*_{ab} = ((\Delta L^*)^2 + (\Delta a^*)^2 + (\Delta b^*)^2)^{1/2}$ . Perceptibility refers to the perception of the difference between two colors, and acceptability is defined as the clinically acceptable color difference. The perceptibility threshold ranges from  $\Delta E^*_{ab} = 1.0$  to 3.7, and  $\Delta E^*_{ab}$  of 2.7 has been set as the clinical perceptibility threshold[4]. For acceptability, the threshold ranges from  $\Delta E^*_{ab} = 2.7$  to 6.8. The acceptability threshold appears to be greater than the perceptibility threshold[5].

According to previous studies, the colors of maxillary permanent incisors differ in terms of age and race[6]. However, these studies were conducted mainly on adult patients, and only a few papers have studied the colors of permanent incisors in children and adolescents[7]. The changes in color distribution according to age and root developmental stage have rarely been studied in children and adolescents. To this end, the goal of this study is to analyze the color distribution of permanent central and lateral incisors in children and adolescents using a spectrophotometer and to determine the effects of age and

root developmental stage on the color distribution.

## Materials and Methods

### 1. Subjects

This study was conducted with the approval of the Institutional Review Board (IRB) of Seoul National University Dental Hospital (IRB No. S-D20210006). A total of 404 maxillary permanent central and lateral incisors from 101 Korean children and adolescents including 57 males and 44 females between ages 7 and 15, with a mean age of  $10.0 \pm 1.5$ , were recruited for the study (Table 1). These patients had panoramic radiographs taken at Seoul National University Dental Hospital within 6 months of the date of color measurement. The tooth color measurement was restricted to sound and fully erupted maxillary permanent incisors. Those with dental caries, restorations, trauma history or discolorations were excluded. The contents of the study were explained in detail to the patients themselves and their parents. The study was initiated only if voluntary consent was obtained.

### 2. Spectrophotometer

VITA Easyshade® V (Serial No. 50741, VITA Zahnfabrik, Bad Säckingen, Germany) was used for color measure-

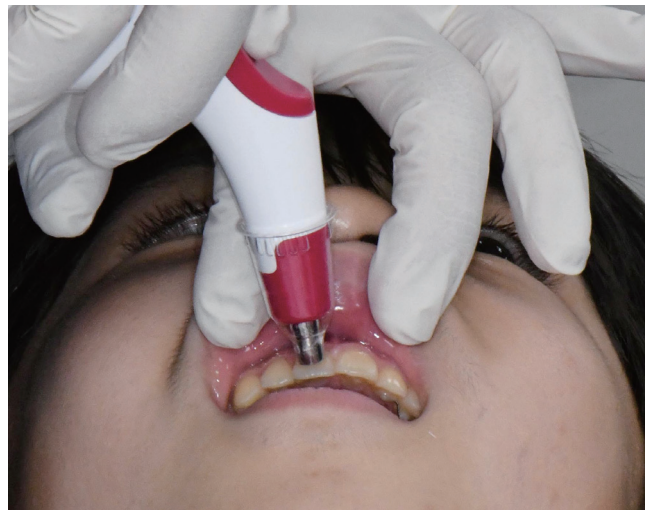**Table 1.** Distribution of the participants by gender and chronological age (n = 101)

Age (Year)	Male (n)	Female (n)	Total (n, %)
7	1	2	3 (3.0%)
8	6	12	18 (17.8%)
9	15	11	26 (25.7%)
10	9	8	17 (16.8%)
11	9	6	15 (14.9%)
12	4	1	5 (5.0%)
13	4	3	7 (6.9%)
14	6	4	10 (9.9%)
Total	54	47	101

ment of maxillary permanent incisors (Fig. 1). In previous studies, VITA Easyshade® V showed the highest precision and accuracy in comparison to other digital color measurement devices[6,8]. The diameter of the spectrometer's tip is 5.0 mm, and the range of measured wavelength is 400.0 - 700.0 nm. The light source is D65 representing noon natural light in the northern hemisphere. All the measurements used a standard light source for the color tone measurement, with a correlated color temperature of 6500.0 K.

### 3. Color measurement

For each subject, dental plaque on maxillary permanent incisors was removed with pumice using a rubber cup. The spectrophotometer was calibrated for every measurement in accordance with the manufacturer's instruction. To prevent cross infection, a new VITA Easyshade® Infection Control Shield (VITA Zahnfabrik) was used for each patient. For each tooth, the color of the entire labial surface was measured using the "averaged shade determination" mode, and colors of the cervical 1/3, middle 1/3, and incisal 1/3 subregions were measured separately using the "shade determination of the tooth area" mode. CIE L\*a\*b\* values of the tooth color were displayed on VITA Easyshade® V in reference to the VITA classical A1 - D4 shade guide. All the measurements were repeated three times and were implemented in the same place by a single dentist. The average values were used in the analysis. The Demirjian's method[9] was used to classify root developmental stages based on panoramic radiographs (Table 2).



**Fig. 1.** Measuring process of the tooth shade with VITA Easyshade® V.

### 4. Intra-investigator reliability

The intra-investigator reliability was evaluated by repeatedly measuring the maxillary permanent incisors of 10 children at 1 week intervals under identical conditions. The intra-class correlation coefficient showed 0.899, 0.951, and 0.988 in maxillary permanent central incisors and 0.977, 0.967, and 0.912 in maxillary permanent lateral incisors for L\*, a\*, and b\* values, respectively ( $p < 0.001$ ).

### 5. Data analysis

The data analysis was performed using the Statistical Package for the Social Sciences (version 26.0, IBM, Chi-

**Table 2.** Distribution of the study subjects by root developmental stage (n = 404)

Root developmental stage*	Central incisor	Lateral incisor	Total (n, %)
Stage F	14	56	70 (17.3%)
Stage G	82	66	148 (36.6%)
Stage H	106	80	186 (46.0%)
Incomplete root development	96	122	218 (54.1%)
Complete root development	106	80	186 (46.0%)

\*Evaluated using panoramic radiograph taken within 6 months of the date of color measurement and estimated using the method proposed by Demirjian et al.

chicago, IL, USA). The average and standard deviation of CIE L\*a\*b\* values of the labial surfaces of maxillary permanent incisors were collected. A paired Student's t-test was performed to test the statistical differences between the color of maxillary permanent central and lateral incisors. The analysis of variance and Pearson correlation coefficient were utilized followed by the post hoc Tukey's test for the statistical analysis of the color differences among the subregions within each tooth. The  $\Delta E^*_{ab}$  was calculated between the color values of central and lateral incisors and those of the subregions. The average and 95% confidence interval of  $\Delta E^*_{ab}$  were also calculated. An independent t-test was used for tooth color comparison between patients at age 10 and younger and patients older than the age of 10 years old. The teeth were classified into two groups depending on the completeness of root development because there were no statistically significant color differences associated with different Demirjian's stages. An independent t-test was utilized to compare the teeth with incomplete root development including Demirjian's stage F/G and those with complete root development which corresponds to Demirjian's stage H.

## Results

### 1. Color distribution of maxillary permanent incisors

CIE L\*a\*b\* values of the entire labial surface of maxillary permanent incisors are presented in Table 3. There were no differences associated with gender. L\*a\*b\* values did not show statistically significant differences between left and right incisors when tested by a paired Student's t-test. Based on this observation, all the analyses in this study used the average CIE L\*a\*b\* values of the left and right incisors.

### 2. Comparison of colors between maxillary permanent incisors

The average CIE L\*a\*b\* values of permanent incisors and the statistical analyses between central and lateral incisors are shown in Table 4. Except for a\* values of central and lateral incisors, L\* and b\* values showed statistically significant differences ( $p < 0.001$ ). Moreover, the  $\Delta E^*_{ab}$  values were greater than the clinical perceptibility threshold.

**Table 3.** CIE L\*a\*b\* values of maxillary permanent incisors

		Total Surface				Cervical 1/3				Middle 1/3				Incisal 1/3			
		Mean	SD	Min	Max	Mean	SD	Min	Max	Mean	SD	Min	Max	Mean	SD	Min	Max
Right Permanent Lateral incisor	L*	82.5	3.7	71.2	89.5	82.7	4.3	70.6	92.0	82.4	3.7	69.7	90.2	78.1	5.0	63.0	90.0
	a*	0.3	0.6	-1.9	2.1	0.9	0.7	-1.2	3.2	0.3	0.7	-1.5	2.3	-0.1	0.9	-2.4	2.0
	b*	25.8	3.4	17.6	35.3	26.9	3.1	16.7	33.9	25.9	3.3	19.1	33.5	21.9	4.1	13.3	32.4
Right Permanent Central Incisor	L*	83.9	3.9	69.0	92.0	85.5	4.3	70.5	93.3	84.1	4.0	72.1	96.4	78.6	4.2	66.5	88.9
	a*	0.2	0.8	-2.1	1.9	0.7	0.7	-1.0	3.1	0.3	0.7	-1.7	1.9	-0.6	1.1	-3.1	2.8
	b*	24.3	3.6	17.3	35.3	26.0	3.2	18.0	34.8	24.5	3.2	14.5	32.5	20.4	4.6	10.2	32.5
Left Permanent Central Incisor	L*	83.8	4.2	68.4	93.5	85.6	4.2	73.2	94.1	84.2	3.8	73.9	93.3	79.3	4.8	66.1	92.4
	a*	0.2	0.7	-1.6	1.8	0.8	0.7	-0.9	2.9	0.3	0.8	-1.7	2.3	-0.5	1.1	-2.8	2.0
	b*	23.8	3.6	14.3	34.4	26.0	3.1	19.0	35.0	24.7	3.2	17.1	33.3	20.5	4.6	12.9	33.7
Left Permanent Lateral Incisor	L*	82.2	3.8	68.5	90.1	83.5	4.5	68.2	91.9	83.3	3.4	72.9	90.5	77.9	5.8	62.7	90.0
	a*	0.4	0.6	1.40	1.8	1.2	0.9	-1.5	3.6	0.5	0.7	-1.3	2.3	-0.1	0.8	-2.0	1.9
	b*	26.2	3.6	17.7	36.3	27.6	3.2	20.4	36.2	26.9	3.6	20.0	37.6	22.3	4.4	14.5	35.0

### 3. Comparison of colors and $\Delta E^*_{ab}$ among subregions of tooth

The average CIE L\*a\*b\* values of the subregions of maxillary permanent incisors are presented in Table 4. CIE L\*a\*b\* values of both maxillary permanent central and lateral incisors showed an increasing tendency from the incisal to the cervical subregion. CIE L\*a\*b\* values showed statistically significant difference among the incisal 1/3, middle 1/3, and cervical 1/3 subregions of maxillary permanent central incisors (Table 5,  $p < 0.001$ ). For maxillary permanent lateral incisors, CIE L\*a\*b\* values

of the subregions showed statistically significant differences (Table 6,  $p < 0.001$ ), except for L\* values of the cervical 1/3 region and middle 1/3 region. The  $\Delta E^*_{ab}$  of each pair of the subregions in maxillary permanent central incisors were all above 2.7, which is the perceptibility threshold. These results indicated that the color differences among the subregions were distinguishable by the naked eye. Maxillary permanent lateral incisors also showed  $\Delta E^*_{ab}$  higher than the perceptibility threshold among the subregions, except for the  $\Delta E^*_{ab}$  between the cervical 1/3 and middle 1/3 subregions.

**Table 4.** Comparison between maxillary permanent central and lateral incisors

		Central Incisor	Lateral Incisor	<i>p</i> value*	$\Delta E^*_{ab}$ †	
		Mean (SD)	Mean (SD)		Mean (SD)	Range‡
Total	L*	84.01 (3.57)	82.33 (3.38)	< 0.0001		
	a*	0.17 (0.67)	0.31 (0.56)	0.005	3.89 (2.10)	3.46 - 4.32
	b*	24.07 (3.43)	25.99 (3.23)	< 0.0001		
Cervical	L*	85.63 (4.10)	83.18 (3.90)	< 0.0001		
	a*	0.76 (0.59)	0.87 (0.65)	0.333	3.74 (2.05)	3.33 - 4.14
	b*	25.89 (2.89)	27.33 (2.71)	< 0.0001		
Middle	L*	84.18 (3.76)	83.05 (3.00)	< 0.0001		
	a*	0.29 (0.72)	0.38 (0.60)	0.780	3.49 (1.84)	3.12 - 3.86
	b*	24.6 (3.06)	26.39 (3.16)	< 0.0001		
Incisal	L*	78.95 (4.28)	78.26 (0.50)	0.083		
	a*	-0.52 (1.08)	-0.09 (0.79)	< 0.0001	4.37 (2.69)	3.83 - 4.90
	b*	20.66 (4.37)	22.20 (4.04)	< 0.0001		

\*Paired Student's t-test between central and lateral incisors.

†  $\Delta E^*_{ab}$  between central and lateral incisors, ‡ 95% confidence interval range.

**Table 5.** Comparison between each subregion of maxillary permanent central incisors

Central Incisors	<i>p</i> value †	<i>r</i> ‡	Mean (SD)	$\Delta E^*_{ab}$ §	Range ¶
Incisal-Cervical	L*	< 0.001**	0.627		
	a*	< 0.001**	0.593	7.15 (3.11)	6.53 - 7.76
	b*	< 0.001**	0.579		
Incisal-Middle	L*	< 0.001**	0.548		
	a*	< 0.001**	0.406	9.10 (3.63)	8.38 - 9.82
	b*	< 0.001**	0.467		
Cervical-Middle	L*	< 0.001**	0.183		
	a*	< 0.001**	0.336	3.03 (1.50)	2.74 - 3.33
	b*	< 0.001**	0.213		

† Analysis of variance between tooth regions (\*\* means  $p < 0.001$ , post hoc: Tukey), ‡ Pearson correlation coefficient, §  $\Delta E^*_{ab}$  between tooth regions, ¶ 95% confidence interval range.

**Table 6.** Comparison between each subregions of maxillary permanent lateral incisors

Lateral Incisors		$p$ value <sup>†</sup>	$r$ <sup>‡</sup>	Mean (SD)	$\Delta E^*_{ab}$ <sup>§</sup>	Range <sup>  </sup>
Incisal-Cervical	L*	< 0.001**	0.479	6.95 (3.45)		6.27 - 7.64
	a*	< 0.001**	0.557			
	b*	< 0.001**	0.600			
Incisal-Middle	L*	< 0.001**	0.505	7.92 (3.51)		7.22 - 8.61
	a*	< 0.001**	0.326			
	b*	< 0.001**	0.325			
Cervical-Middle	L*	0.669	0.015	2.73 (1.55)		2.43 - 3.04
	a*	< 0.001**	0.366			
	b*	< 0.05*	0.154			

<sup>†</sup>Analysis of variance between tooth regions (\*\* means  $p < 0.001$ , \* means  $p < 0.05$ , post hoc: Tukey), <sup>‡</sup>Pearson correlation coefficient, <sup>§</sup> $\Delta E^*_{ab}$  between tooth regions, <sup>||</sup>95% confidence interval range.

#### 4. Comparison of tooth color by chronological age

CIE L\*a\*b\* values of maxillary permanent incisors at each age and the correlation coefficients are shown in Table 7. CIE L\*a\*b\* values of maxillary permanent central incisors showed a negative correlation to age. The differences between CIE L\*a\*b\* values of maxillary permanent incisors in patients at age 10 and younger and patients older than 10 years old are presented in Fig. 2. Only L\* value of maxillary permanent central and lateral incisors showed a statistically significant difference between age

groups.

#### 5. Comparison of tooth color by root developmental stage

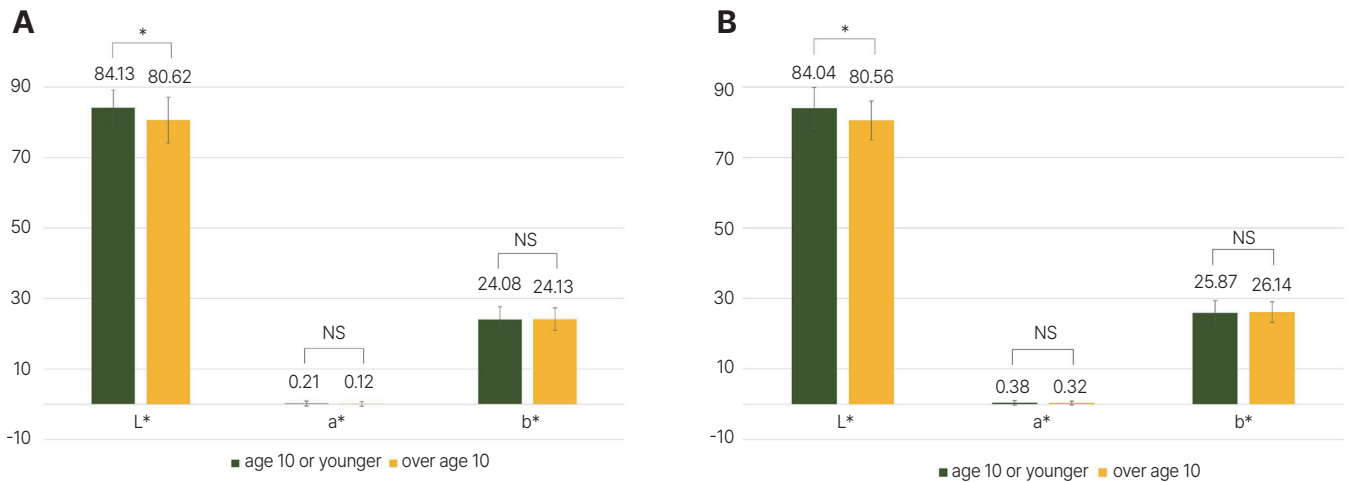
The differences between CIE L\*a\*b\* values of maxillary permanent incisors with incomplete root development and complete root development are shown in Fig. 3. All CIE L\*a\*b\* values showed no statistically significant differences according to root developmental stage.

**Table 7.** CIE L\*a\*b\* values of the entire surface of maxillary permanent incisors according to age

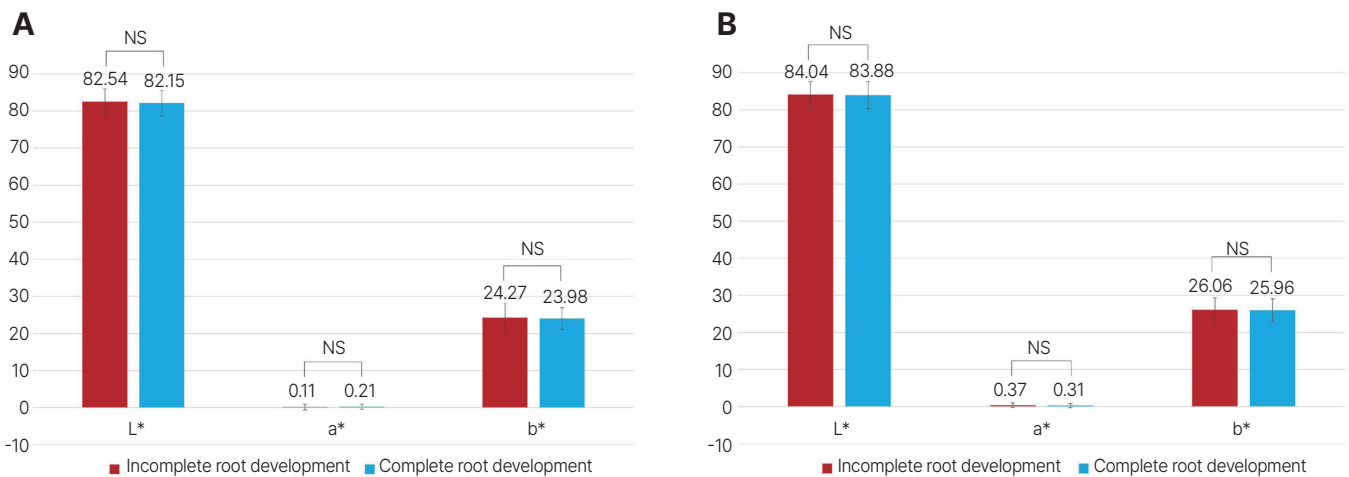
Age (Year)	n	Central Incisors			Lateral Incisors		
		L*	a*	b*	L*	a*	b*
7	3 (2.97%)	84.02 (5.40)	0.87 (0.45)	26.6 (3.60)	82.15 (3.74)	0.73 (0.55)	26.33 (3.26)
8	18 (17.82%)	84.10 (2.59)	0.50 (0.63)	24.04 (3.72)	82.30 (3.19)	0.02 (0.70)	25.10 (4.32)
9	26 (25.75%)	83.38 (3.58)	0.23 (0.74)	24.04 (3.72)	82.21 (3.26)	0.36 (0.62)	25.65 (3.40)
10	17 (16.83%)	83.42 (4.72)	0.19 (0.64)	24.17 (3.61)	82.00 (3.65)	0.20 (0.73)	25.35 (3.92)
11	15 (14.85%)	83.19 (5.29)	0.26 (0.85)	25.00 (3.41)	81.18 (5.40)	0.34 (0.73)	26.14 (3.27)
12	5 (4.95%)	82.15 (6.36)	0.20 (0.45)	24.16 (2.73)	80.47 (7.53)	0.52 (0.37)	27.97 (2.59)
13	7 (6.93%)	79.90 (6.75)	-0.19 (0.94)	23.86 (2.83)	80.42 (7.35)	0.28 (0.41)	26.23 (1.34)
14	10 (9.90%)	79.57 (6.01)	-0.13 (0.70)	22.63 (3.67)	81.8 (7.19)	0.30 (0.60)	26.01 (2.71)
$\rho$		-0.914	-0.908	-0.710	-0.674	-0.148	-0.371
$p$ value		< 0.05	< 0.05	< 0.05	0.067	0.722	0.464

$\rho$  Pearson correlation coefficient.





**Fig. 2.** (A) Comparison of maxillary permanent central incisors of patients age 10 and younger and over age 10. (B) Comparison of maxillary permanent lateral incisors of patients age 10 and younger and over age 10. \* means statistically significant difference. NS means no statistically significant difference.



**Fig. 3.** (A) Comparison of maxillary permanent central incisors with complete and incomplete root development. (B) Comparison of maxillary permanent lateral incisors with complete and incomplete root development. NS means no statistically significant difference from independent t-test.

## 6. Distribution of VITA shade

VITA shade measurements by the spectrophotometer showed that B3 shade matched 37.6% and 49.5% of maxillary permanent central and lateral incisors, respectively (Table 8). In case of patients of age 7, A1 shade was most

common for both maxillary permanent central and lateral incisors. For maxillary permanent central incisors, A3 shade was most prominent for ages 8 to 11 and B3 shade for ages above 11. For maxillary permanent lateral incisors, A3 and B3 shades were the most prominent for age 8 to 9 and age above 9, respectively (Table 9).

**Table 8.** Distribution of best matching VITA classical A1–D4® shade for maxillary permanent incisors

VITA shade	Central Incisors		Lateral Incisors	
	n	%	n	%
A1	15	14.8	9	8.9
A2	3	3.0	0	0.0
A3	31	30.7	34	33.6
A3.5	1	1.0	2	2.0
A4	3	3.0	2	2.0
B1	0	0.0	2	2.0
B2	7	6.9	2	2.0
B3	38	37.6	50	49.5
B4	3	3.0	0	0.0

## Discussion

One of the most important and difficult problems in aesthetic restoration is the choice of tooth color. For selecting an accurate color, precise measurement of tooth color is mandatory. As the importance of aesthetic restoration is increasingly emphasized in pediatric dentistry, it is required to precisely match the restoration color to adjacent teeth.

Fracture of permanent incisors is one of the most frequent traumas at all ages, but particularly frequent in ages 7 to 12[10]. As fracture of permanent incisor due to trauma can entail negative impact on a child's oral function, aesthetics, and psychological status, a proper recovery of its shape and color is desired[11]. In order to achieve successful aesthetic restoration in pediatric patients, analyzing the optical characteristics of the central and lateral incisors is critical to accurately matching the color. Direct composite resin restoration is the most viable treatment option for pediatric patients; however, it is challenging to reproduce the tooth colors with composite resin. For this reason, it is important to accumulate data on the colors of maxillary permanent incisors in children and adolescents.

The color measurement using shade guides, which has been traditionally used, has limitations in quantitatively and precisely measuring the color distribution of the natural teeth. Also, shades tend to differ by manufacturer even though they use the same color system. Measurer subjectivity can also be a limitation. Compared to the measurements based on the shade guide, optical measurements by colorimeters and spectrophotometers are considered to be more reliable and objective. Com-

**Table 9.** Distribution of best matching VITA classical A1–D4® shade for maxillary permanent incisors at different chronological ages

Age (Year)	Central Incisors (n, %)							Lateral Incisors (n, %)						
	A1	A2	A3	A4	B1	B2	B3	A1	A2	A3	A4	B1	B2	B3
7	3 (100.0%)	0 (0.0%)	0 (0.0%)	0 (0.0%)	0 (0.0%)	0 (0.0%)	0 (0.0%)	2 (66.7%)	0 (0.0%)	0 (0.0%)	0 (0.0%)	1 (33.3%)	0 (0.0%)	0 (0.0%)
8	1 (5.6%)	0 (0.0%)	11 (61.1%)	0 (0.0%)	0 (0.0%)	1 (5.6%)	5 (27.7%)	2 (11.1%)	1 (5.6%)	8 (44.4%)	0 (0.0%)	0 (0.0%)	0 (0.0%)	7 (38.9%)
9	1 (3.8%)	0 (0.0%)	15 (57.8%)	0 (0.0%)	1 (3.8%)	0 (0.0%)	9 (34.6%)	1 (3.8%)	0 (0.0%)	13 (50.0%)	0 (0.0%)	0 (0.0%)	0 (0.0%)	12 (46.2%)
10	1 (5.9%)	0 (0.0%)	10 (58.8%)	0 (0.0%)	0 (0.0%)	0 (0.0%)	6 (35.3%)	0 (0.0%)	0 (0.0%)	6 (35.3%)	0 (0.0%)	0 (0.0%)	0 (0.0%)	11 (64.7%)
11	0 (0.0%)	0 (0.0%)	9 (60.0%)	0 (0.0%)	0 (0.0%)	0 (0.0%)	6 (40.0%)	0 (0.0%)	0 (0.0%)	3 (20.0%)	0 (0.0%)	0 (0.0%)	0 (0.0%)	12 (80.0%)
12	0 (0.0%)	0 (0.0%)	2 (40.0%)	0 (0.0%)	0 (0.0%)	0 (0.0%)	3 (60.0%)	0 (0.0%)	0 (0.0%)	0 (0.0%)	0 (0.0%)	0 (0.0%)	0 (0.0%)	5 (100.0%)
13	1 (14.3%)	0 (0.0%)	2 (28.6%)	0 (0.0%)	0 (0.0%)	0 (0.0%)	4 (57.1%)	0 (0.0%)	0 (0.0%)	2 (28.6%)	0 (0.0%)	0 (0.0%)	0 (0.0%)	5 (71.4%)
14	2 (20.0%)	0 (0.0%)	3 (30.0%)	0 (0.0%)	0 (0.0%)	0 (0.0%)	5 (50.0%)	1 (10.0%)	0 (0.0%)	0 (0.0%)	0 (0.0%)	0 (0.0%)	1 (10.0%)	8 (80.0%)



pared to spectrophotometers which use a wide range of wavelength for color measurement including ultraviolet, visible, and infrared, colorimeters use a fixed wavelength in the visible range[12]. This restricts colorimeters in detecting the reflectance and metamerism[13]. For this reason, spectrophotometers are considered to be more suitable for precise color measurement. Several studies have proven that spectrophotometers present significantly higher accuracy and reliability in color measurement than colorimeters[12,13]. This study used VITA Easyshade® system, which is a spot-measuring contact-type spectrophotometer, to obtain the color information of teeth. VITA Easyshade® presented 92.6% in accuracy and 96.4% in reliability[13]. This is notably higher than those of colorimeters. The availability of various measurement modes, such as “averaged shade determination” mode, “shade determination of the tooth area” mode, “restoration color verification” mode, and “shade tab” mode, is another advantage of VITA Easyshade® system[14].

Spot-measuring contact-type spectrophotometers have some limitations. First, edge loss occurs when measuring the reflectance of translucent materials. The light transmitted through a translucent material spreads beyond the measurement area and may not be measured by the device[15]. This phenomenon can occur if the measurement spot is smaller than the measuring tip, if the measurement surface is not flat, or if the measuring tip cannot contact closely to the measurement surface. With edge loss, the amount of reflected light can be decreased resulting in underestimated actual CIE L\*a\*b\* values[16]. A VITA Easyshade® V spectrophotometer includes multiple spectrometers for measuring scattered light at two different distances within the photosphere in the ring in order to minimize edge loss[17]. To further minimize edge loss, a measuring tip was placed as close as possible and perpendicular to the labial surface of the tooth in each measurement.

Another limitation of the spectrophotometer is the relatively large diameter of the measuring tip compared to the clinical crown length. The diameter of the measuring tip is 5.0 mm. According to Song et al.[18], the average crown lengths of maxillary permanent central

incisors and maxillary permanent lateral incisors are 9.9 mm and 8.5 mm, respectively. To minimize the overlapping measurement area, the measuring tip was placed as closely as possible to the cervical line, incisal edge, or center area of each tooth while measuring the cervical and incisal subregions.

The total surface of central incisors had CIE L\*a\*b\* values of  $84.01 \pm 3.57$ ,  $0.17 \pm 0.67$ , and  $24.07 \pm 3.43$ , respectively. The total surface of lateral incisors had CIE L\*a\*b\* values of  $82.33 \pm 3.38$ ,  $0.31 \pm 0.56$ , and  $25.99 \pm 3.23$ , respectively. Compared to the color values reported in previous studies conducted on adults ages 18 years and older, CIE L\*a\*b\* values of children and adolescents in this study showed higher L\* and b\* values[17,19]. The inverse correlation of L\* and b\* values with age was also reported in other studies[20]. The age-dependent changes in L\* values can be interpreted as a result of secondary dentin accumulation which makes the tooth harder, less permeable, and darker in color[21]. The changes in b\* values are considered to be a result of the gradual loss of the enamel layer over time. Consequently, dentin, which is more yellow than the white enamel layer, reveals its color[22].

In comparison to CIE L\*a\*b\* values of maxillary primary incisors reported in the study conducted by Choi et al.[23], the color of maxillary permanent incisors in this study is darker and has more yellow shade. This difference between permanent and primary teeth is consistent with the results of the previous studies[24]. This may be attributed to the fact that primary incisors have more water content than permanent incisors. The structure of primary incisors with thin enamel and dentin layers and a large pulp chamber is also considered to be the cause of the color difference.

Maxillary permanent central incisors presented higher L\* values and lower a\* and b\* values compared to maxillary permanent lateral incisors. Only L\* and b\* values showed statistically significant differences. Karamen et al.[6] and Pustina-Krasniqi et al.[25] reported that L\* value of maxillary permanent central incisors is significantly higher than that of maxillary permanent lateral incisors, which is consistent with the results of this study.

Unlike the results reported by Karamen et al.[6],  $b^*$  value of maxillary permanent central incisors in this study was lower than that of maxillary permanent lateral incisors. This means that maxillary permanent central incisors were brighter and has more blue shade than maxillary permanent lateral incisors in this study population.

Significant differences were observed between each subregion within a tooth, except for  $L^*$  values between the middle 1/3 and the cervical 1/3 region in maxillary permanent lateral incisors.  $L^*$  value increased from the incisal 1/3 to the cervical 1/3 region.  $a^*$  and  $b^*$  values also increased in the same direction. Previous studies concluded that redness and yellowness increase from the incisal 1/3 region to the cervical 1/3 region[26,27]. The main reason for the color difference between subregions is the selective wavelength absorption of dentin. The color is determined by the thickness of dentin and enamel[28]. Similar to the previous study[26], the color differences between subregions were larger than the clinical perceptibility threshold of 2.7 in all subjects of this study. This indicates that the color differences are easily distinguishable by the naked eye. The  $\Delta E^*_{ab}$  between the subregions were similar to the previous study[26].  $L^*$ ,  $a^*$ , and  $b^*$  values of the middle 1/3 region showed a strong correlation with those of the cervical 1/3 region and the incisal 1/3 region. According to this correlation, it should be possible to predict the color of other subregions based on the color of one subregion of a tooth. If more data can be accumulated with accurate measurement devices, it will be possible to generate a useful database for predicting the color of one subregion based on the color of another subregion to produce restorations and prostheses with a more suitable color.

$L^*a^*b^*$  values of maxillary permanent central incisors showed a negative correlation with age with a correlation coefficient  $\rho = 0.914, 0.908, 0.710$  respectively, as presented in Table 7. There was no correlation between age and the color values of maxillary permanent lateral incisors. The majority of maxillary permanent central incisors studied in this study were at the Demirjian's stage G and H, and the proportion of maxillary permanent central incisors with complete root development tended to increase

with patients' age. On the other hand, maxillary permanent lateral incisors included a considerable number of stage F (Table 2), and there was no clear pattern of age-dependent root development. Based on this observation, it is considered that the correlation of CIE  $L^*a^*b^*$  values with age is not as strong in maxillary permanent lateral incisors as in maxillary central incisors between age 7 and 14. Future studies with a larger sample size will be necessary. In both of maxillary permanent central and lateral incisors, the tooth colors were brighter in patients age 10 and younger. According to Kuremoto et al.[29], age 9.7 is when root development of maxillary permanent incisors is completed, and the mean age of this study population was  $10.0 \pm 1.5$ . For this reason, the age of 10 years old was used as the criterion for dividing groups. Similar results were reported in Jahangiri et al.[20]. The dentin layer becomes harder and less permeable with age as the dental pulp shrinks and secondary dentin forms, resulting in darker tooth color[22]. At the same time, the pigments and ions can diffuse through enamel, and accumulate at the interface of dentin and enamel and within dentin[21]. Meera et al.[30] and Goodkind and Schwabacher[19] reported that the deposition of secondary dentin mainly contributes to changes in teeth color with age. A limitation of this study was that the number of patients aged 7 and 12 to 14 years old was insufficient to confirm the age-dependent color change. Future studies with a sufficient sample size at each age are necessary.

Although several studies have reported the effect of age on the color of maxillary permanent incisors[30], there are no reliable databases of the tooth color in relation to root developmental stage. There was no significant color difference between teeth with Demirjian stage F, G and H. The teeth were classified into a group with incomplete root development and a group with complete root development. While  $L^*$  value decreased with increasing age, the color values did not show statistically significant differences associated with root developmental stage. This differs from the reports of the previous studies[31], which suggested that teeth become darker and yellower as the root develops, because the accumulation of sec-

ondary dentin is a crucial event for the tooth darkening process. Savas et al.[7] suggested that an incomplete calcification process of teeth with an open apex can cause color differences with root developmental stage, as underdeveloped teeth have low levels of mineralization and porous structures. The reason why it was not possible to confirm the color difference in relation to root developmental stage in this study is possibly because of the sample size differences between the incomplete and complete root development groups. Since only patients with fully erupted incisors were included in this study, those in Demirjian Stage F were only 6.9% among maxillary permanent central incisors and 17.3% among all the teeth studied. Incisors with earlier root developmental stages were not included. Hence this study cannot exactly reflect the impact of root development on tooth color due to insufficient sample size for each stage of root development.

Since there is no standard colorimetric system, each company selects a shade guide of choice to manufacture restorative materials[32]. VITA classical A1 - D4® is the most widely used shade guide. It consists of 16 specimens from A1 to D4 with different chroma and brightness. 'A' stands for reddish - brown; 'B' stands for reddish - yellow; 'C' stands for gray; and 'D' stands for reddish - gray. The number indicates the brightness, with the smallest number being the brightest[32]. In maxillary permanent incisors, A2 and B3 shades appear most frequently[6]. In this study, B3 shade is the most frequent in both maxillary permanent central incisors and lateral incisors which is consistent with the previous studies[6]. In patients younger than age 7, the best matching VITA shade for both maxillary permanent central and lateral incisors was A1. Considering the small sample size for patients at age 7, future studies with more samples will be necessary to confirm A1 as the best matching VITA shade for age 7. As chronological age increased the best matching VITA shade for each age group showed darker and more yellow shades (Table 9). Based on this observation, A1 shade seems suitable for the restoration of maxillary permanent incisors in children under the age of 7 years old, and the darker and more yellow resin for older

patients.

In this study, the colors of maxillary permanent incisors were measured using the spectrophotometer with known accuracy and reliability. This study was intended to provide a database for the color distribution of maxillary permanent incisors in children and adolescents. It is meaningful that all the color measurements of maxillary permanent incisors were performed with the same spectrophotometer under consistent conditions.

Additional studies with greater sample sizes should be conducted, and the results should be compared to the existing studies, as a limitation of this study is the small sample size of maxillary permanent central incisors with incomplete root development and maxillary permanent lateral incisors with complete root development. The diameter of the measuring tip of the spectrophotometer could have been another limitation. Because of the relatively large diameter of the measuring tip of the spectrophotometer, the color measuring area for the cervical 1/3, middle 1/3 and incisal 1/3 subregions may have overlapped to some extent. Hence, a measuring tip with a smaller diameter is required for accurate color evaluation of tooth subregions.

## Conclusion

In this study, the colors of maxillary permanent central and lateral incisors were measured using the spectrophotometer and quantified by CIE L\*a\*b\* system.

The average CIE L\*a\*b\* values of maxillary permanent central incisors were  $L^* = 84.01 \pm 3.57$ ,  $a^* = 0.17 \pm 0.67$ , and  $b^* = 24.07 \pm 3.43$ . The average values of maxillary permanent lateral incisors were  $L^* = 82.33 \pm 3.38$ ,  $a^* = 0.31 \pm 0.56$ , and  $b^* = 25.99 \pm 3.23$ . The  $\Delta E^*_{ab}$  between maxillary permanent central and lateral incisors and  $\Delta E^*_{ab}$  between the subregions of teeth were greater than the clinical perceptibility threshold. CIE L\*a\*b\* values showed statistically significant differences among the subregions of maxillary permanent incisors. The brightness was highest in the cervical 1/3 region, and redness and yellowness increased from the incisal 1/3 region to the cervical 1/3 region. Patients 10 years old and younger

showed statistically higher  $L^*$  values than older patients.

Based on the results of this study, the color differences between the central and lateral incisors and among sub-regions of a tooth, and the effects of age on tooth color should be considered for the aesthetic restorations of permanent incisors in children and adolescents.

## Acknowledgments

This work was supported by the New Faculty Startup Fund from Seoul National University.

## Conflicts of Interest

The authors have no potential conflicts of interest to disclose.

## References

1. Woo D, Sheller B, Williams B, Mancl L, Grembowski D : Dentists' and parents' perceptions of health, esthetics, and treatment of maxillary primary incisors. *Pediatr Dent*, 27:19-23, 2005.
2. Oliveira GM, Ritter AV : Composite resin restorations of permanent incisors with crown fractures. *Pediatr Dent*, 31:102-109, 2009.
3. Horn DJ, Bulan-Brady J, Hicks ML : Sphere spectrophotometer versus human evaluation of tooth shade. *J Endod*, 24:786-790, 1998.
4. Ragain Jr. JC, Johnston WM : Color acceptance of direct dental restorative materials by human observers. *Color Res Appl*, 25:278-285, 2000.
5. Hyun HK, Lee YK, Kim YJ, Kim JW, Jang KT, Kim CC, Hahn SH, Lee SH : Color distribution of maxillary primary incisors in Korean children. *Color Res Appl*, 35:153-158, 2010.
6. Karaman T, Altintas E, Eser B, Yildirim TT, Oztekin F, Bozoglan A : Spectrophotometric evaluation of anterior maxillary tooth color distribution according to age and gender. *J Prosthodont*, 28:E96-E102, 2019.
7. Savas S, Kavrik F, Yasa B, Kucukyilmaz E : Spectrophotometric color analysis of maxillary permanent central incisors in a pediatric population: a preliminary study. *Int J Paediatr Dent*, 27:420-427, 2017.
8. Dozić A, Kleverlaan CJ, El-Zohairy A, Feilzer AJ, Khashayar G : Performance of five commercially available tooth color-measuring devices. *J Prosthodont*, 16:93-100, 2007.
9. Demirjian A, Goldstein H, Tanner JM : A new system of dental age assessment. *Hum Biol*, 45:211-227, 1973.
10. Güngör HC : Management of crown-related fractures in children: An update review. *Dent Traumatol*, 30:88-99, 2014.
11. Magno MB, Jural LA, do Valle Nogueira A, Lenzi MM, Pithon MM, Maia LC : Impact of crown fracture treatment on oral health-related quality of life of children, adolescents, and their families: A prospective clinical study. *Int J Paediatr Dent*, 29:86-93, 2019.
12. Chu SJ, Trushkowsky RD, Paravina RD : Dental color matching instruments and systems. Review of clinical and research aspects. *J Dent*, 38(Suppl 2):E2-E16, 2010.
13. Kim-Pusateri S, Brewer JD, Davis EL, Wee AG : Reliability and accuracy of four dental shade matching devices. *J Prosthet Dent*, 101:193-199, 2009.
14. VITA Easysshade® V - Instructions for use. Available from URL: [https://mam.vita-zahnfabrik.com/portal/ecms\\_mdb\\_download.php?id=108102&sprache=en&fallback=&cls\\_session\\_id=&neuste\\_version=1](https://mam.vita-zahnfabrik.com/portal/ecms_mdb_download.php?id=108102&sprache=en&fallback=&cls_session_id=&neuste_version=1) (Accessed on June 4, 2021).
15. Bayindir F, Kuo S, Johnston WM, Wee AG : Coverage error of three conceptually different shade guide systems to vital unrestored dentition. *J Prosthet Dent*, 98:175-185, 2007.
16. Kim J, Paravina R, Chen JW : In vivo evaluation of color of primary teeth. *Pediatr Dent*, 29:383-386, 2007.
17. Paravina RD, O'Keefe KL, Kuljic BL : Color of permanent teeth: a prospective clinical study. *Balkan J Stomatol*, 10:93-97, 2006.
18. Song JW, Leesungbok R, Park SJ, Chang SH, Ahn SJ, Lee SW : Analysis of crown size and morphology, and gingival shape in the maxillary anterior dentition in Korean young adults. *J Adv Prosthodont*, 9:315-320, 2017.

19. Goodkind RJ, Schwabacher WB : Use of a fiber-optic colorimeter for in vivo color measurement of 2830 anterior teeth. *J Prosthet Dent*, 58:535-542, 1987.
20. Jahangiri L, Reinhardt SB, Mehra RV, Matheson PB : Relationship between tooth shade value and skin color: an observational study. *J Prosthet Dent*, 87:149-152, 2002.
21. Morley J : The esthetics of anterior tooth aging. *Curr Opin Cosmet Dent*, 4:35-39, 1997.
22. Davis MC, Walton RE, Rivera EM : Sealer distribution in coronal dentin. *J Endod*, 28:464-466, 2002.
23. Choi W, Lee S, Jih M, Sunh M, Lee N : Color Comparison of Maxillary Primary Anterior Teeth and Various Composite Resins using a Spectrophotometer. *J Korean Acad Pediatr Dent*, 49:1-13, 2022.
24. Baik BJ, Oh KS, Kim JG, Yang CH : The Comparative study on the color of the deciduous teeth and restorative materials. *J Korean Acad Pediatr Dent*, 29:376-381, 2002.
25. Pustina-Krasniqi T, Shala K, Staka G, Bicaj T, Ashmedi E, Dula L : Lightness, chroma, and hue distributions in natural teeth measured by a spectrophotometer. *Eur J Dent*, 11:36-40, 2017.
26. O'Brien WJ, Hemmendinger H, Boenke KM, Linger JB, Groh CL : Color distribution of three regions of extracted human teeth. *Dent Mater*, 13:179-185, 1997.
27. Paravina RD, Majkic G, Imai FH, Powers JM : Optimization of tooth color and shade guide design. *J Proshodont*, 16:269-276, 2007.
28. Price RB, Murphy DG, Dérand T : Light energy transmission through cured resin composite and human dentin. *Quintessence Int*, 31:659-667, 2000.
29. Kuremoto K, Okawa R, Matayoshi S, Kokomoto K, Nakano K : Estimation of dental age based on the developmental stages of permanent teeth in Japanese children and adolescents. *Sci Rep*, 12:3345, 2022.
30. Meera R, Shieh J, Muthu MS : In vivo evaluation of the color of anterior primary teeth. *J Dent Child*, 78:154-158, 2011.
31. Elamin HO, Abubakr NH, Ibrahim YE : Identifying the tooth shades in group of patients using Vita Easyshade. *Eur J Dent*, 9:213-217, 2015.
32. Cho KY, Hwang IN, Choi HR, Oh WM : Comparative Evaluation of Light-cured Composite Resins Based on Vita Shade by Spectrocolorimeter. *J Korean Acad Conserv Dent*, 23:424-432, 1998.



## 분광광도계를 이용한 한국 소아 환자의 상악 영구 절치 색조 분석

오승현 · 김현태 · 신터전 · 현홍근 · 김영재 · 김정욱 · 장기택 · 송지수  
 서울대학교 치의학대학원 소아치과학교실

이 연구의 목적은 한국 소아 및 청소년 환자의 상악 영구전치의 색조 분포를 분석하고, 환자의 연령과 치근 발육 정도가 색조에 미치는 영향을 확인하는 것이다. 평균 연령  $10.0 \pm 1.5$  세인 7세에서 15세 사이의 한국 어린이 101명에서 치아우식, 수복물, 외상 이력과 변색이 없으며 건전하고 충분히 맹출한 상악 영구 중절치와 측절치 404개의 국제조명위원회  $L^*a^*b^*$  값을 분광광도계를 이용하여 측정하였다.  $L^*a^*b^*$  값은 상악 중절치에서 84.01, 0.17, 24.07, 상악 측절치에서 82.33, 0.31, 25.99로 나타났다. 상악 중절치가 상악 측절치에 비해  $L^*$  값은 높고  $b^*$  값은 낮았다( $p < 0.001$ ). 치아 각 부위 사이의 색조 차이는 상악 중절치와 상악 측절치 모두에서 임상 허용의 한계치보다 높았다. 10세 이하의 소아 청소년의  $L^*$  값은 상악 중절치와 상악 측절치에서 각각 84.14 및 84.04였으며, 11세 이상의 소아 청소년의  $L^*$  값은 상악 중절치와 상악 측절치에서 각각 80.62 및 80.56였다. 10세 이하 환자의 상악 절치의  $L^*$  값이 11세 이상 환아에 비해 높게 나타났다. 치근 발육 정도에 따른 색조 차이는 없었다. 이 연구에서는 소아 환자의 상악 영구 절치 심미 수복을 위해서 상악 중절치와 상악 측절치 사이의 색조 차이와 치아 각 부위 사이의 색조 차이, 그리고 연령에 따른 색조 차이를 고려해야 할 것을 제안한다. [J Korean Acad Pediatr Dent 2022;49(4):414-427]

원고접수일 2022년 7월 12일  
 원고최종수정일 2022년 9월 5일  
 원고채택일 2022년 9월 7일

© 2022 대한소아치과학회  
 © 이 글은 크리에이티브 커먼즈 코리아 저작자표시-비영리 4.0 대한민국 라이선스에 따라 이용하실 수 있습니다.

교신저자 송지수  
 (03080) 서울시 종로구 대학로 101 서울대학교 치의학대학원 소아치과학교실  
 Tel: 02-2072-3080 / Fax: 02-744-3599 / E-mail: pedosong@snu.ac.kr