

Effects of Both Abdominal Drawing-In Maneuver and Co-Contraction of Hip Adductor Muscle while Bridge Exercise on Abdominal Muscle

Gyeong-Hui Park · Jin-Hwa Lee · You-Mi Jung · Dongyeop Lee, PT, PhD ·
Ji-Heon Hong, PT, PhD · Jae-Ho Yu, PT, PhD · Jin-Seop Kim, PT, PhD · Seong-Gil Kim, PT, PhD[†]
Department of Physical Therapy, College of Health Science, Sunmoon University

Received: October 18 2022 / Revised: October 19 2022 / Accepted: November 16 2022

© 2022 J Korean Soc Phys Med

| Abstract |

PURPOSE: This study examined the effect of bridge exercise-abdominal draw-in maneuver (ADIM) with hip adductor co-contraction on the TrA thickness and whether it is effective as a core stability exercise.

METHODS: The subjects of this study, 33 men with no history in the past and who provided prior consent, were selected through interviews with male students of S University. The subjects performed five movements, including bridge exercise and ADIM, and performed two demonstrations and two exercises in advance. The abdominal muscles were measured using ultrasonography once in each movement, and the abdominal muscle tone was measured using a soft tissue tone measurement.

RESULTS: There was a significant difference in the thickness between the TrA and Internal Oblique Muscles at various bridge positions ($p < .05$), and no significant difference

with the External Oblique Muscle ($p < .05$). There was no significant difference in muscle tone in the Rectus abdominis part ($p > .05$), but a significant difference in the Oblique Muscle part ($p < .05$). The muscle tone of the Oblique Muscles by position showed a significant difference in Bridge, BHa, and BA compared to the rest position ($p < .05$), but no significant difference with BHaA ($p > .05$).

CONCLUSION: The thickness of TrA could be increased through bridge exercise, and TrA could be activated properly using ADIM and may be an effective exercise for core stabilization.

Key Words: Abdominal draw-in maneuver, Bridge exercise, Hip adduction co-contraction, Transverse abdominis, Ultrasound

I. Introduction

Today, 50% of the population suffers from lumbar back pain [1]. It is one of the most frequent disorders reported worldwide [2]. Recently, many studies have been conducted on the relationship between the spinal instability and back pain. The structure of the spine is unstable compared to other bones. Hence, the role of local muscles is vital in

[†]Corresponding Author : Seong-Gil Kim
sungkil83@naver.com, <https://orcid.org/0000-0002-2487-5122>
This is an Open Access article distributed under the terms of the Creative Commons Attribution Non-Commercial License (<http://creativecommons.org/licenses/by-nc/3.0>) which permits unrestricted non-commercial use, distribution, and reproduction in any medium, provided the original work is properly cited.

maintaining stability [3]. A person with back pain exhibits a deficiency in TrA (Transverse Abdominis) activation, showing that the local abdominal muscle of the subject with back pain has a motor control disorder [4]. Changes in the muscles around the spine are related to chronic back pain [5,6]. Other abdominal muscles (constituting the abdominal wall), Internal oblique (IO), External Oblique muscle (EO), and Rectus Abdominis (RA) should be considered together when attempting to understand the effect on low back pain rather than being limited to TrA [11].

Muscles for spinal stabilization include TrA and multifidus. TrA is used to prevent excessive low back movement and is reported to be activated first in case of lack of stability or sudden movement [7,8]. The thickness change of TrA measured by ultrasound in recent years is a valuable indicator to evaluate functional factors [9,10]. In the above studies, abdominal muscle activation was observed through the abdominal draw-in maneuver (ADIM), a method for activating TrA and IO [8,12-15]. In addition, many studies have shown that local abdominal muscles and hip adductor co-contraction are effective [16-21]. ADIM has been shown to contribute to the stabilization of the spine [3,22-24]. The hip muscles are attached to the pelvis and connected to the local abdominal muscle [25,26]. Research shows that activating the hip adductor muscles and hip abductor muscles is effective in activating the deep muscles [3,27,28]. Some researchers argue that TrA should be trained separately because deep muscles contribute to spinal stability differently than superficial muscles [8]. As a result, many clinicians apply exercises that combine various hip adductor muscle activations for patients with low back based on previous studies [27,28]. Therefore, core stability exercise that activates the deep muscles has become a therapeutic exercise form [2].

Postures related to core stability are being studied. The core stability can be strengthened using leg exercises and prone and side-lying positions [23,29]. The bridge exercise

is used in the core stabilization program and is applied to patients with low back pain. Bridge exercise retrains the coordination of the superficial and deep muscles to aid postural control [24,30,31].

Although bridge exercise, ADIM, and hip adduction co-contraction individually had significant effects, the correlation on the effect on the TrA thickness has not been identified. Co-activation of ADIM results in effective performance ability for training for lumbar stability and can effectively induce the co-contraction of muscles. It can also reduce the compensation caused by Bridge exercise. Therefore, this study examined the effect of bridge exercise-ADIM with hip adductor co-contraction on TrA thickness.

II. Methods

1. Participants

This study was conducted on 33 healthy adult men at S University in Asan, Chungcheongnam-do. Before participating in the study, all subjects were fully explained the purpose and method of the study. The participants in this study were those who had no injuries and had no past medical history and everyone who gave prior consent. Applicants had no back pain or abdominal or back surgery within six months and had no abnormalities in general health. The Institutional Review Board (IRB) of Sunmoon University approved this study (SM-202204-021-2). After explaining the purpose and method of the experiment to all participants, a written informed consent was signed. The information on the participants is as follows (Table 1).

Table 1. General characteristics of the subjects (n = 33)

Variable	Mean ± SD
Age (year)	22.82 ± 3.18
Height (cm)	174.21 ± 4.94
Weight (kg)	72 ± 10.08

SD, standard deviation.

2. Measurement Equipment

The thickness of the abdominal muscles was measured by ultrasound imaging (ultrasonography, eZono3000, Germany, 2011) as the instrument used in the experiment (Fig. 2). US used B (brightness) mode and a 7–10 MHz linear probe. The muscle tension of the abdominal muscles was measured using a contact soft tissue measurement (MyotonPRO, Myoton, Estonia, 2019). In addition, to measure the angle of the knee joint, the knee joint angle was set to 60° using an electronic joint angle meter (Goniometer, Absolute Axis Digital Goniometer, 2008) in the starting position of the movement. The measurers completed a three-month training program following a specific protocol before starting this measurement. The measuring equipment is as follows (Fig. 1).

1) Muscle Thickness

The position of the oblique was measured between the

12th rib and the iliac crest based on the middle axillary line. During measurement, the position of the probe was adjusted so that the fascia junction of the TrA was separated by 1 cm from the inside of the ultrasound monitor. The ultrasound image was taken at the end of exhalation. After fixing the image, the thickness of the abdominal muscle was measured at the thickest part between the fascia and the fascia using an electronic caliper [14,32,33]. The measurement position is as follows (Fig. 2).

2) Muscle Tone

The muscle tone of the RA muscle part was measured at a point approximately 3 cm next to the umbilicus. The muscle tone of the oblique muscle part was measured between the 12th rib and the iliac crest based on the middle axillary line, the same as the ultrasound. The probe was placed vertically to the surface, and pressure was applied until the probe was green. After the measurement, the muscle tone

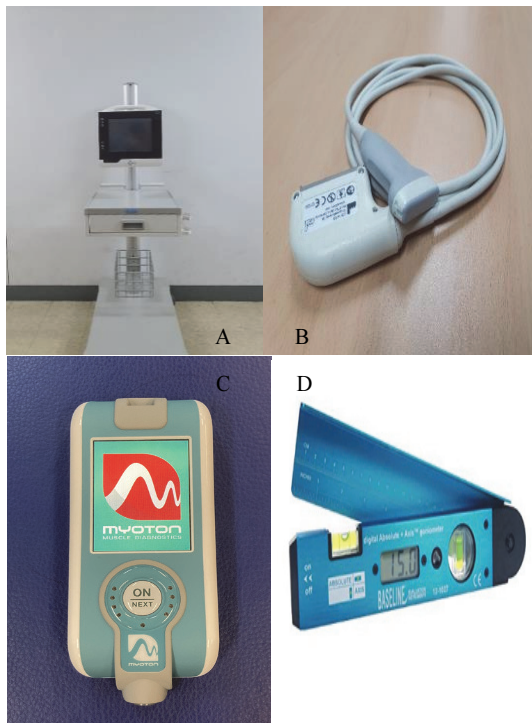


Fig. 1. Measurement equipment.

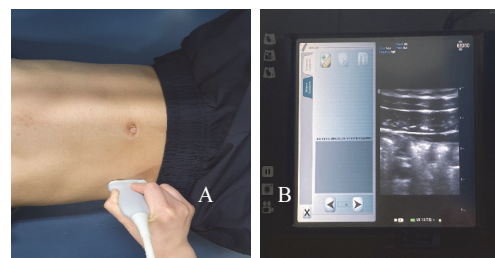


Fig. 2. Muscle thickness.

A: Between the 12th rib and iliac crest based on the middle axillary line

B: a (External Oblique), b (Internal Oblique), c (TrA)

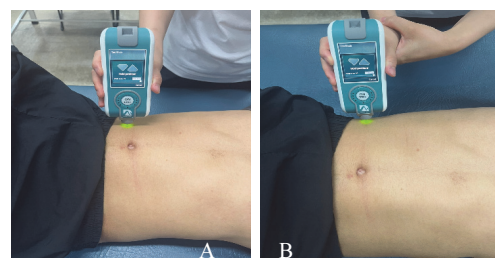


Fig. 3. Muscle tone.

A: Rectus Abdominis Part B: Oblique Part

has checked through the frequency of vibration (Hz), and the normal range was set to 12–18 Hz. When the coefficient of variation was 3% or more, it was measured again [32,34,35]. The measurement position is as follows (Fig. 3).

3. Experimental Procedures

The thickness of the abdominal muscles was measured under five different test conditions: 1) Rest, 2) Bridge, 3) Bridge with hip adduction (BHa), 4) Bridge with ADIM (BA), and 5) Bridge with hip adduction – ADIM (BHAA). The demonstration was performed twice for each exercise so that the participants could recognize the movement.

Subsequently, the participants performed the exercises at least twice. The participants rested with their arms next to their trunk and knee bent at 60° (The knee angle was set through an electronic goniometer). They were instructed to breathe comfortably while avoiding unnecessary body movements and muscle contractions. This position is the resting position and the starting position of all movements. The table for the procedure is as follows (Fig. 4).

1) Bridge exercise

For the bridge exercise, the pelvis was lifted from the start position to the point where the shoulders, hips, and

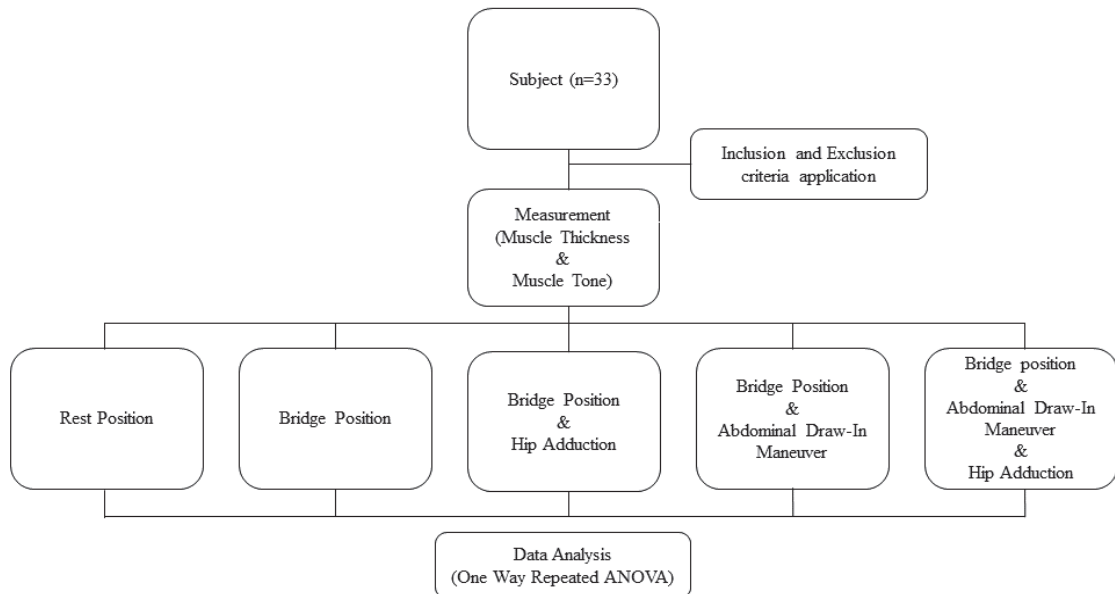


Fig. 4. Research procedure.

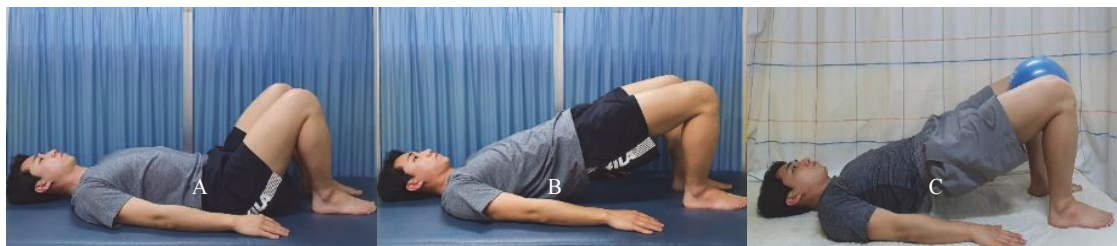


Fig. 5. Bridge position.

A: Rest position B: Bridge position C: Bridge & Hip adduction

knees were in a straight line. At this time, the participants were instructed to "reduce the use of low back muscles to the maximum and use hip muscles to lift the pelvis" In addition, to activate the hip adductor muscles together, the researcher gave verbal instructions to the participants to place an overball between their knees: "Press the ball as hard as possible with both knees" [8,36]. The exercise position is as follows (Fig. 5).

2) Abdominal Draw-In Maneuver

The instructions for ADIM were given verbally: "contract your abdominal muscles thinking that you attach your umbilicus in the direction of your spine" while breathing normally in the start position. During the ADIM practice, the participants received visual feedback through ultrasound images and recognized the contraction of the TrA. In addition, when performing the ADIM, care was taken to prevent an excessive posterior tilt of the pelvis in the same way as the bridge exercise [17,22,25,36,37].

4. Data Analysis

All statistical analyses calculated the mean and standard deviation for each measurement using the SPSS 25.0 statistical software program. After performing normality verification, One Way Repeated ANOVA was used to

check the thickness and muscle tone of the external oblique muscle, internal oblique muscle, and transverse abdominis during each position. Post-hoc analysis was performed using a Fisher's LSD test. The η^2 value was used to determine the effect size for each exercise. Furthermore, the difference between the contraction thickness ratio of each position and the contraction thickness ratio of the rest position was compared to understand the effect of each exercise on thickness better. The statistical significance level was set at $p = .05$.

III. Results

1. Muscle Thickness

This study measured and compared the thickness of the abdominal muscles when performing different exercises. The thickness is as follows (Table 2). The normality test showed that all variables followed a normal distribution. Repeat Measures ANOVA was performed to compare the thickness of each exercise. There was a significant difference between various bridge exercises and TrA and IO ($p < .05$) (Table 2). There was no significant difference from the EO ($p > .05$) (Table 2). The thickness of TrA and IO of the BA and BHaA were significantly different from the rest position ($p < .05$) (Table 2). However, there

Table 2. Comparison of the muscle thickness on abdominal muscles according to each position

Muscle	Rest	Bridge	BHa	BA	BHaA	F	P	Effect size (η^2)
EO (mm)	3.43 ± 1.0	3.61 ± 1.01	3.77 ± 1.03	3.72 ± 1.25	3.55 ± 1.09	1.232	.288	.944
IO (mm)	7.19 ± 1.79 D, E > A	7.31 ± 1.88 D, E > B	7.42 ± 1.76 D, E > C	8.37 ± 2.22 A, B, C < D	8.34 ± 2.57 A, B, C < E	6.611	.000*	.954
TrA (mm)	3.68 ± .83 B, C, D, E > A	4.31 ± 1.2 A < B D, E > B	4.06 ± .93 A < C D, E > C	5.46 ± 1.35 A, B, C < D	5.62 ± 1.56 A, B, C < E	19.042	.000*	.968

* $p < .05$; Mean (mm) ± Standard Deviation (mm); EO, External Oblique Muscle; IO, Internal Oblique Muscle; TrA, Transverse Abdominis; BHa, Bridge with hip adduction; BA, Bridge with ADIM; BHaA, Bridge with hip adduction and ADIM; ^AStatistically different from Rest; ^BStatistically different from Bridge; ^CStatistically different from BHa; ^DStatistically different from BA.; ^EStatistically different from BHaA.

was no significant difference between BA and BHaA of TrA and IO. ($p > .05$).

2. Contraction Thickness Ratio

Based on the rest position, the thickness of the abdominal muscles measured during different bridge positions was compared with the contraction thickness ratio (%) in four movements (Table 3, Fig. 6). The contraction thickness ratio (CTR) of EO was not significantly different for all

movements. ($p > .05$, Table 3). The CTR of IO was significantly different in BA and BHaA ($p < .05$) (Table 3). The CTR of TrA was significantly different in Bridge, BA, and BHaA ($p < .05$) (Table 3).

3. Muscle Tone

The muscle tone of the abdominal muscles for each position is as follows (Table 4). There was no significant difference in muscle tone of the Rectus abdominis part.

Table 3. Comparison of the contraction thickness ratio on abdominal muscles according to each position

Muscle	EO (mm)	Compared with Rest (%)	IO (mm)	Compared with Rest (%)	TrA (mm)	Compared with Rest (%)
Rest	3.43 ± 1.0 (mm)		7.19 ± 1.79 (mm)		3.68 ± .83 (mm)	
Bridge	3.61 ± 1.0 (mm)	5.24 ± 1.91 (%)	7.31 ± 1.88 (mm)	1.66 ± 1.26 (%)	4.31 ± 1.2 (mm)	17.11 ± 9.22* (%)
BHa	3.77 ± 1.03 (mm)	9.91 ± 3.11 (%)	7.42 ± 1.76 (mm)	3.19 ± 1.82 (%)	4.06 ± .93 (mm)	10.32 ± .57 (%)
BA	3.72 ± 1.25 (mm)	8.45 ± 7.45 (%)	8.37 ± 2.22 (mm)	16.41 ± 2.85* (%)	5.46 ± 1.35 (mm)	48.36 ± 4.79* (%)
BHaA	3.55 ± 1.09 (mm)	3.49 ± 2.47 (%)	8.34 ± 2.57 (mm)	15.99 ± 10.35* (%)	5.62 ± 1.56 (mm)	52.71 ± 11.84* (%)

* $p < .05$; Mean (mm) ± Standard Deviation (mm); EO, External Oblique Muscle; IO, Internal Oblique Muscle; TrA, Transverse Abdominis; BHa, Bridge with hip adduction; BA, Bridge with ADiM; BHaA, Bridge with hip adduction and ADiM; ^AStatistically different from Rest; ^BStatistically different from Bridge; ^CStatistically different from BHa; ^DStatistically different from BA; ^EStatistically different from BHaA.

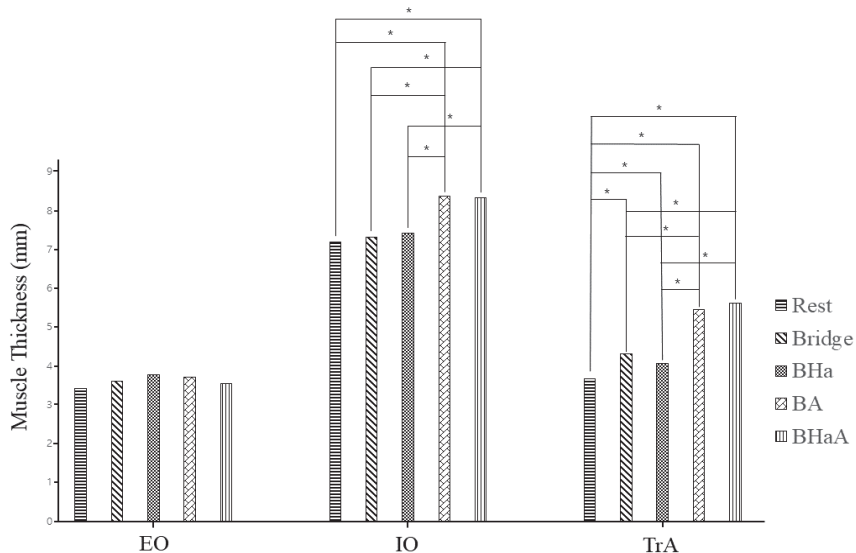


Fig. 6. Muscle thickness of the abdominal muscle in each bridge position.

BHa, Bridge with hip adduction; BA, Bridge with ADiM; BHaA, Bridge with hip adduction and ADiM

Table 4. Comparison of muscle tone on abdominal muscles according to each exercise condition

Muscle	Rest	Bridge	BHa	BA	BHaA	F	P	Effect Size (η ²)
Rectus Abdominis Muscle (Hz)	12.24 ± 1.76	12.55 ± 1.91	12.52 ± 1.9	12.35 ± 2	12.57 ± 2.12	2.525	.062	.979
Oblique Muscle (Hz)	13.18 ± .94 B, C, D > A	13.88 ± 1.14 A, C > B	13.58 ± 1.26 A < C B > C	13.9 ± 2.25 A < D	13.9 ± 2.47	4.434	.006*	.968

* p < .05; Mean (mm) ± Standard Deviation (mm); BHa, Bridge with hip adduction; BA, Bridge with ADIM; BHaA, Bridge with hip adduction and ADIM; ^AStatistically different from Rest; ^BStatistically different from Bridge; ^CStatistically different from BHa; ^DStatistically different from BA.; ^EStatistically different from BHaA.

A significant difference in the muscle tone of the oblique muscle part was observed. Post-hoc analysis for each position showed a significant difference in the muscle tone of the oblique muscle in the Bridge, BHa, and BA position compared to the rest position, but there was no significant difference noted with BHaA (Table 4).

IV. Discussion

1. Muscle Thickness

The Rest and Bridge position showed a difference in contraction thickness ratio (CTR). As a result, the bridge position was significant for TrA. In addition, the bridge position with ADIM (BA) was more effective than when only the bridge position was implemented with a CTR. Hence, ADIM was effective in TrA contraction. In addition, the BA position showed the largest difference among the others except for external resistance as CTR [8]. This showed that the bridge and ADIM affect TrA, and when ADIM is combined at the bridge position, it is effective for the thickness change of TrA. This is consistent with the present research. In another study, TrA increased in the bridge and BA positions [38]. It was consistent with the argument that core stabilization exercise with Bridge excise and ADIM activates the local abdominal muscles. Furthermore, when considering the application of bridge exercise and ADIM to prevent lower back pain, it is

recommended to apply ADIM while maintaining the bridge position first [38].

In this study, the thickness of the contraction of TrA in the BHaA was the largest. However, there was no significant difference between BA and BHaA. This means that the effect of hip adductor co-contraction on TrA is less than that of ADIM. Previous studies showed that hip adduction affects abdominal muscle activation, similar results were expected in this study, but the results were different [12,13,39-41]. Park et al. reported long-term effects through regular exercise for eight weeks [40]. In this study, however, only short-term effects were observed without training and feedback. Previous studies confirmed that properly performed hip adduction through a device can set a specific intensity [17,45]. In the present study, On the other hand, the overball was instructed to contract as much as possible during hip adduction. It was confirmed visually that the overball was contracted. However, this makes it difficult to confirm that the hip adductor muscles are properly contracted. In this study, the thickness of RA was not measured, but measurements of the thickness of EO located in the superficial area as RA showed that EO was activated the most in BHa. Therefore, the thickness of the TrA dose changes relatively while the thickness of EO increases during hip adductor co-contraction. The reason why BHaA did not affect TrA is that it has been reported that the contraction

thickness of TrA does not increase reaching a maximum of 20–30% [8].

2. Muscle Tone

The thickness of the superficial muscles decreased as the thickness of the deep muscles increased because there have been few studies measuring the muscle tone of the abdominal muscles [8]. It was expected that the muscle tone of the Rectus abdominis part, which is the most superficial among the elements constituting the abdominal wall, would decrease and the muscle tone of the oblique muscle part would increase, but the results were not. The reason for these results is that because this study was a one-time measurement to compare the acute effects of exercise, and the activation of the global muscle, which is fast-twitch fiber, was higher than that of the local muscle, which is slow-twitch fiber, so the RA muscle tone did not decrease [42]. In a study using a muscle tone-measuring device [34,43], the normal range of the vibration frequency (F) was set to 12–18 Hz. When muscle tone exceeded the normal range, the blood supply decreased, and the tension of each muscle increased [43]. Mense et al. suggested that high muscle tone could contribute to abnormal movement and chronic pain [44]. Based on previous studies, in the case of the RA part, which showed no difference in muscle tone, the muscle tone was within the normal range despite performing the bridge position.

The main results of this study are that bridge exercise and ADIM have a significant effect on TrA. ADIM is effective for TrA and IO and is most effective when combined with the bridge position. Therefore, this exercise is used to activate deep muscles selectively, such as TrA [13,45–48]. Second, the thickness of TrA was increased the most in the BHaA position. However, the single application of hip adduction did not affect the abdominal muscles.

This study had several limitations. First, all subjects were physically healthy men who did not experience low

back pain within six months. For patients or athletes with low back pain, there may be a difference in the thickness of the abdominal muscles. These findings cannot be generalized to all age groups and patients with low back pain. Second, in this study, ADIM education was conducted in the measurement stage because performing ADIM correctly in a short period can affect the results. On the other hand, this study observed only short-term effects. Therefore, future studies should examine the long-term effects of ADIM. Lastly, this study could not accurately control the intensity of hip adduction. Therefore, in future research, intensity should be classified in more detail using the MVIC value of EMG.

V. Conclusion

Therefore, the thickness of TrA can be increased while limiting the activation of superficial muscles through bridge exercise. In particular, ADIM can be used to activate TrA. As a stabilization exercise, it is suggested to perform ADIM, which activates the deep muscles.

References

- [1] Andersson GB. Epidemiological features of chronic low-back pain. *Lancet*. 1999;354(9178):581-5.
- [2] Brumitt J, Matheson JW, Meira EP. Core stabilization exercise prescription, part I: Current concepts in assessment and intervention. *Sports Health*. 2013;5(6): 504-9.
- [3] Lee D, Park J, Lee S. Effects of bridge exercise on trunk core muscle activity with respect to sling height and hip joint abduction and adduction. *J Phys Ther Sci*. 2015;27(6):1997-9.
- [4] Himes ME, Selkow NM, Gore MA, et al. Transversus abdominis activation during a side-bridge exercise progression is similar in people with recurrent low back pain and healthy controls. *J Strength Cond Res*.

- 2012;26(11):3106-12.
- [5] Wu Z, Wang Y, Ye Z, et al. Effects of age and sex on properties of lumbar erector spinae in healthy people: Preliminary results from a pilot study. *Front Physiol.* 2021;14:79.
- [6] Hides JA, Richardson CA, Jull GA. Multifidus muscle recovery is not automatic after resolution of acute, first-episode low back pain. *Spine (Phila Pa 1976).* 1996;21(23):2763-9.
- [7] Hodges PW, Richardson CA. Feedforward contraction of transversus abdominis is not influenced by the direction of arm movement. *Exp Brain Res.* 1997;114(2):362-70.
- [8] Dafkou K, Kellis E, Ellinoudis A, et al. The effect of additional external resistance on inter-set changes in abdominal muscle thickness during bridging exercise. *J Sports Sci Med.* 2020;19(1):102-11.
- [9] Hodges PW, Pengel LH, Herbert RD, et al. Measurement of muscle contraction with ultrasound imaging. *Muscle Nerve.* 2003;27(6):682-92.
- [10] Misuri G, Colagrande S, Gorini M, et al. In vivo ultrasound assessment of respiratory function of abdominal muscles in normal subjects. *Eur Respir J.* 1997;10(12):2861-7.
- [11] Whittaker JL, Warner MB, Stokes M. Comparison of the sonographic features of the abdominal wall muscles and connective tissues in individuals with and without lumbopelvic pain. *J Orthop Sports Phys Ther.* 2013; 43(1):11-9.
- [12] Jang EM, Kim MH, Oh JS. Effects of a bridging exercise with hip adduction on the EMG activities of the abdominal and hip extensor muscles in females. *J Phys Ther Sci.* 2013;25(9):1147-9.
- [13] Richardson CA, Jull GA. Muscle control-pain control. What exercises would you prescribe?. *Man Ther.* 1995;1(1):2-10.
- [14] Bjerkefors A, Ekblom MM, Josefsson K, et al. Deep and superficial abdominal muscle activation during trunk stabilization exercises with and without instruction to hollow. *Man Ther.* 2010;15(5):502-7.
- [15] Coqueiro KR, Bevilacqua-Grossi D, Bérzin F, et al. Analysis on the activation of the VMO and VLL muscles during semisquat exercises with and without hip adduction in individuals with patellofemoral pain syndrome. *J Electromyogr Kinesiol.* 2005;15(6):596-603.
- [16] Hides J, Stanton W, Freke M, et al. MRI study of the size, symmetry and function of the trunk muscles among elite cricketers with and without low back pain. *Br J Sports Med.* 2008;42(10):809-13.
- [17] Hides JA, Wong I, Wilson SJ, et al. Assessment of abdominal muscle function during a simulated unilateral weight-bearing task using ultrasound imaging. *J Orthop Sports Phys Ther.* 2007;37(8):467-71.
- [18] Miao P, Xu Y, Pan C, et al. Vastus medialis oblique and vastus lateralis activity during a double-leg semisquat with or without hip adduction in patients with patellofemoral pain syndrome. *BMC Musculoskeletal Disord.* 2015;16:289.
- [19] Hodges PW, Richardson CA. The influence of isometric hip adduction on quadriceps femoris activity. *Scand J Rehabil Med.* 1993;25(2):57-62.
- [20] Kim MH, Yoo WG. Optimal and maximal loads during hip adduction exercise by asymptomatic people. *J Phys Ther Sci.* 2014;26(5):777-8.
- [21] Cholewicki J, Juluru K, McGill SM. Intra-abdominal pressure mechanism for stabilizing the lumbar spine. *J Biomech.* 1999;32(1):13-7.
- [22] Springer BA, Mielcarek BJ, Nesfield TK, et al. Relationships among lateral abdominal muscles, gender, body mass index, and hand dominance. *J Orthop Sports Phys Ther.* 2006;36(5):289-97.
- [23] Bakkum BW, Cramer GD. *Clinical Anatomy of the Spine, Spinal Cord, and Ans.* (3th ed). United States. Mosby Inc. 2014.
- [24] Thomas WM. *Anatomical trains; myofascial meridians for manual and movement therapists.* (4th ed). London. Churchill Livingstone. 2014.
- [25] Teyhen DS, Miltenberger CE, Deiters HM, et al. The

- use of ultrasound imaging of the abdominal drawing-in maneuver in subjects with low back pain. *J Orthop Sports Phys Ther.* 2005;35(6):346-55.
- [26] Bø K, Stien R. Needle EMG registration of striated urethral wall and pelvic floor muscle activity patterns during cough, Valsalva, abdominal, hip adductor, and gluteal muscle contractions in nulliparous healthy females. *NeuroUrol Urodyn.* 1994;13(1):35-41.
- [27] Amorim AC, Cacciari LP, Passaro AC, et al. Effect of combined actions of hip adduction/abduction on the force generation and maintenance of pelvic floor muscles in healthy women. *PLoS One.* 2017;12(5):e0177575.
- [28] Cho M. The effects of bridge exercise with the abdominal drawing-in maneuver on an unstable surface on the abdominal muscle thickness of healthy adults. *J Phys Ther Sci.* 2015;27(1):255-7.
- [29] Hemborg B, Moritz U, Hamberg J, et al. Intraabdominal pressure and trunk muscle activity during lifting—effect of abdominal muscle training in healthy subjects. *Scand J Rehabil Med.* 1983;15(4):183-96.
- [30] Ljunggren AE, Weber H, Kogstad O, et al. Effect of exercise on sick leave due to low back pain. A randomized, comparative, long-term study. *Spine (Phila Pa 1976).* 1997;22(14):1610-7.
- [31] Hides JA, Miokovic T, Belavý DL, et al. Ultrasound imaging assessment of abdominal muscle function during drawing-in of the abdominal wall: An intrarater reliability study. *J Orthop Sports Phys Ther.* 2007;37(8):480-546.
- [32] Saliba SA, Croy T, Guthrie R, et al. Differences in transverse abdominis activation with stable and unstable bridging exercises in individuals with low back pain. *N Am J Sports Phys Ther.* 2010;5(2):63-73.
- [33] McMeeken JM, Beith ID, Newham DJ, et al. The relationship between EMG and change in thickness of transversus abdominis. *Clin Biomech (Bristol, Avon).* 2004;19(4):337-42.
- [34] Ito K, Noraka K, Ogaya S, et al. Surface electromyography activity of the rectus abdominis, internal oblique, and external oblique muscles during forced expiration in healthy adults. *J Electromyogr Kinesiol.* 2016;28:76-81.
- [35] Muckelt PE, Warner MB, Cheliotis-James T, et al. Protocol and reference values for minimal detectable change of MyotonPRO and ultrasound imaging measurements of muscle and subcutaneous tissue. *Sci Rep.* 2022;12(1):1-11.
- [36] Moffett JK, Torgerson D, Bell-Syer S, et al. Randomised controlled trial of exercise for low back pain: clinical outcomes, costs, and preferences. *BMJ.* 1999;319(7205):279-83.
- [37] Teyhen DS, Bluemle LN, Dolbeer JA, et al. Changes in lateral abdominal muscle thickness during the abdominal drawing-in maneuver in those with lumbopelvic pain. Doctor's Degree. *J Orthop Sports Phys Ther.* 2009;39(11):791-8.
- [38] HA, Lee KC, Bae WS. The Effect of Abdominal muscle drawing-in exercise during bridge exercise on abdominal muscle thickness, using for real-time ultrasound imaging. *J Korean Soc Phys Med.* 2013;8(2): 231-8.
- [39] Jin PT, Cho M, Shim S, et al. Comparison of trunk Muscle activity according to hip abduction angle during plank exercise. *Phys Ther Rehabil Sci.* 2019;8(3):162-9.
- [40] Park JC, Lee DK. The Effects of bridge exercise with one hip joint adduction on trunk muscle thickness. *J Kor Phys Ther.* 2020;32(6):354-8.
- [41] Puntumetakul R, Saiklang P, Tapanya W, et al. The effects of core stabilization exercise with the abdominal drawing-in maneuver technique versus general strengthening exercise on lumbar segmental motion in patients with clinical lumbar instability: A randomized controlled trial with 12-month follow-up. *Int J Environ Res Public Health.* 2021;18(15):7811.
- [42] Plotkin DL, Roberts MD, Haun CT, et al. Muscle fiber type transitions with exercise training: Shifting perspectives. *Sports (Basel).* 2021;9(9):127.
- [43] Lo WLA, Yu Q, Mao Y, et al. Lumbar muscles biomechanical characteristics in young people with chronic spinal pain. *BMC Musculoskelet Disord.* 2019;

- 20(1):559.
- [44] Mense, S., Gerwin, R. *Muscle Pain: Understanding the Mechanisms*. Berlin, Heidelberg. Springer. 2010.
- [45] Rainville J, Hartigan C, Martinez E, et al. Exercise as a treatment for chronic low back pain. *Master's Degree. Spine J*. 2004;4(1):106-15.
- [46] van Tulder M, Malmivaara A, Esmail R, et al. Exercise therapy for low back pain: a systematic review within the framework of the cochrane collaboration back review group. *Doctor's Degree. Spine (Phila Pa 1976)*. 2000;25(21):2784-96.
- [47] Lee JY, Lee DY. The effect of therapeutic abdominal drawing-in maneuver using ultrasonography on lateral abdominal muscle thickness and balance. *J Back Musculoskelet Rehabil*. 2018;31(6):1139-43.
- [48] Urquhart DM, Hodges PW. Differential activity of regions of transversus abdominis during trunk rotation. *Eur Spine J*. 2005;14(4):393-400.