



Original Article

Effect of Astaxanthin on Anti-Inflammatory and Anti-Oxidative Effects of Astaxanthin Treatment for Atopic Dermatitis-induced Mice

Jin Woo Park, Ho-Sueb Song*

Department of Acupuncture and Moxibustion Medicine, College of Korean Medicine, Gachon University, Seongnam, Korea

**ABSTRACT****Article history:**

Submitted: July 27, 2021

Revised: August 05, 2021

Accepted: August 18, 2021

Keywords:

astaxanthin, atopic dermatitis, anti-inflammation anti-oxidative

Background: This study sought to determine whether the antioxidant effects of astaxanthin (AST) could have an anti-inflammatory effect to reduce inflammation caused by atopic dermatitis (AD).

Methods: Using a mouse model of AD induced by phthalic acid (PA), the levels of inflammation, inflammatory agents, and evidence of antioxidant activity were examined in PA treated mice ($n = 3$), PA-AST treated mice ($n = 3$), and a control group of mice ($n = 3$). This included measurements of ear thickness, levels of mast cells, IgE, inflammatory cytokine, malondialdehyde (MDA), hydrogen peroxide, HO-1, and GPx-1.

Results: AST treatment significantly prevented inflammation as measured by ear thickness ($p < 0.05$), mast cell count ($p < 0.001$), and IgE concentration in the blood ($p < 0.001$). Levels of TNF- α ($p < 0.001$), IL-1 β ($p < 0.001$), IL-6 ($p < 0.001$), and MDA ($p < 0.05$) were also significantly lower. In addition, GSH levels increased significantly ($p < 0.001$), and the level of hydrogen peroxide significantly reduced ($p < 0.01$). The expression of HO-1, GPx-1 increased.

Conclusion: In this small experimental study, AST acted on inflammatory mechanisms that induced AD, through anti-inflammatory and antioxidant mechanisms, and is a candidate of interest in the clinical treatment of AD.

<https://doi.org/10.13045/jar.2021.00178>
 pISSN 2586-288X eISSN 2586-2898

©2021 Korean Acupuncture & Moxibustion Medicine Society. This is an open access article under the CC BY-NC-ND license (<http://creativecommons.org/licenses/by-nc-nd/4.0/>).

Introduction

Atopic dermatitis (AD) is an inflammatory skin disease that frequently recurs and may become chronic [1]. AD develops at a young age and has an increasing prevalence worldwide, including in both developing and developed countries [2]. AD is characterized by pruritus, itching, dry skin, skin wrinkles, eczema, and elevated serum IgE levels [3]. Preventative treatment of AD approaches from a variety of directions such as moisturizing and managing the skin, or training in avoidance of deteriorating factors which may cause symptoms to recur or worsen, or therapeutic in the form of treatment for symptom relief using topical steroid treatment, and use of immunosuppressants [4].

But Side effects of these therapeutic treatments may include skin atrophy, secondary infections due to immunosuppressant use, rebound phenomenon, and thinning of the epidermal barrier due to steroid use [5]. Therefore, for systemic and long-term treatment, treatments with less side effects and toxicity are needed. The

pathology of AD has been proposed as a cause of genetic factors, immune system disorders, exposure to environmental pollutants, and defects in skin barrier dysfunction [6].

Recently, a study has shown that oxidative stress also may be a factor which causes and exacerbates AD [7]. Inflammatory cells release free oxygen and oxidative stress affects genes which may damage DNA, and promote inflammation of tissues through pro-inflammatory cytokines [8]. As a result, repeated infections break down epidermal barriers and modify the gene-based immune system, leading to a vicious cycle of infection, which contributes to the prolonged AD [9]. Meanwhile, there are high levels of oxidative stress in patients with AD due to increased lipid peroxidation and decreased antioxidant levels [10]. Therefore, in order to treat chronic skin diseases such as AD, studies are needed to examine antioxidants that reduce oxidative stress, remove reactive oxygen species (ROS) and reactive nitrogen species (RNS), but have few side effects in the human body.

Astaxanthin (AST) is a carotenoid pigment that has recently been

*Corresponding author. Ho-Sueb Song

Department of Acupuncture and Moxibustion Medicine, College of Korean Medicine, Gachon University, Incheon, Korea

E-mail: hssong70@gachon.ac.krORCID: Jin Woo Park <https://orcid.org/0000-0002-5284-3857>, Ho-Sueb Song <https://orcid.org/0000-0001-5306-8795>©2021 Korean Acupuncture & Moxibustion Medicine Society. This is an open access article under the CC BY-NC-ND license (<http://creativecommons.org/licenses/by-nc-nd/4.0/>).

recognized for its excellent antioxidant action, and AST is found in various marine animals such as lobsters, salmon, trout, shrimps, eggs, and red sea monkeys, and has recently been reported to have excellent antioxidant action [11]. It can also be synthesized in microbes, microalgae, plants, and bacteria. Chlorophyte alga *Hematococcus pluvialis* has been reported to contain the highest level of AST in nature when exposed to ultraviolet light or sunlight [12].

AST has been studied for a variety of effects, including antioxidant action, protection from UV light, detoxification in the liver, nervous system recovery, anti-cancer, anti-inflammatory, immune function activation, and whitening effect [13]. AST antioxidant capacity has been reported to be 100 to 500 times higher than the known antioxidants, and 5 to 15 times higher than other carotenoids such as lycopene, lutein, and β -carotene [14].

A study has reported that AST inhibits intracellular oxidation produced by various ROS, and reduces neurotoxicity induced by hydrogen peroxide (H_2O_2) or serum deprivation [15]. AST has also been reported to improve AD and contact dermatitis by controlling inflammatory cytokines and inflammatory mechanisms [16-18]. Anti-inflammatory effects of AST [19] and liposomal AST [13] in PA-induced animal models of AD have been reported.

In this study, we would like to investigate the inhibitory effects of AST on AD by focusing on the antioxidant capacity of AST.

Materials and Methods

Materials

AST (Sigma-Aldrich Korea Ltd.) is extracted from *Haematococcus pluvialis*.

Animal treatment

The animal testing protocols used in this study were closely examined for ethical and scientific management procedures and approved by the Chungbuk National University-Institutional Animal Care and Use Committee (Approval no.: CBNUA-1073-17-01).

HR-1 mice (8-week-old, $n = 9$) were randomly divided into 3 groups. In the 1st group (PA + vehicle, $n = 3$), 100 μ L (10 μ L/cm²) of 5% PA solution was applied to the back of the ear 3 times a week for 4 weeks. In the 2nd group (PA + AST 1, $n = 3$), PA was applied as in Group 1, and 100 μ L of 1 mg/mL (10 μ g/cm²) AST was used 3 hours later. HR-1 mice of the same age became 3rd group, the control group ($n = 3$).

Measurement of epidermal thickness

To measure the degree of skin inflammation caused by PA treatment, the thickness of the ear was measured using a thickness gauge (Digimatic Indicator, Mitsutoyo Co., Tokyo, Japan).

Histological techniques

Samples from the ears and the skin from the back of the ears were collected from euthanized mice, fixed with 10% formalin, loaded in paraffin wax, and cut into 5 μ m-thick slices. The skin sections were dyed with hematoxylin and eosin (H&E), and the dermis and epidermis thickness were measured with the Leica Application Suite (Leica Microsystems, Wetzlar, Germany).

The mast cells stained with toluidine blue were detected. After following deparaffinization and dehydration of the skin sections, the ears and back of the skin were stained with a 0.25% solution

(Sigma-Aldrich, MO, USA) of toluidine blue. The presence of mast cells was examined with light microscopy per specific area, the number of mast cells was checked using the Leica Application Suite (Leica Microsystems, Wetzlar, Germany).

Enzyme-linked immunosorbent assay for detection of serum IgE concentration

Serum IgE concentrations were measured using enzyme-linked immunosorbent assay (ELISA) kits following the manufacturer's instructions (Shibayagi, Gunma, Japan). Captured antibodies were plated into the Nunc C lower immune plate in the kit, and was washed 3 times with cleaning solution (50 mM Tris, 0.14 M NaCl, 0.05% Tween 20, pH 8.0). The serum samples, and standards (diluted with buffer solution) were added to the wells, and the plates were incubated for 2 hours. The wells were re-cleaned with cleaning solution, 50 μ L of biotin-conjugated anti-IgE antibody (1,000 \times dilution) was added to each well and incubated for another 2 hours.

After washing the well with the cleaning solution again, the horseradish peroxidase conjugated detection antibodies (2,000 times dilution) were aliquoted into each well and incubated for 1 hour. The enzyme reaction was then initiated by adding a tetramethylbenzidine substrate solution (100 mM sodium acetate buffer pH 6.0, 0.006% H_2O_2) and incubating the plate at room temperature for 20 minutes. Finally, the reaction was terminated with addition of an acidic solution (reaction stopper, 1 M H_2SO_4), and absorbance of the yellow product was measured spectrophotometrically at 450 nm. The final concentration of IgE was calculated using a standard curve.

RNA quantification

RT-qPCR was performed as described in Lee's report [20]. Briefly, total RNA was collected from mouse skin tissues using the Ribo^{EX} RNA Extraction Kit (GeneAll Biotechnology, Seoul, Korea) and cDNA was synthesized using the High-Capacity RNA-to-cDNA kit (Applied Biosystems, Foster City, CA, USA). RT-qPCR was performed using specific primers with the StepOnePlusTM PCR System (Applied Biosystems, Foster City, CA, USA). Levels of mRNA were normalized to the 18S sequence, which was used as a house-keeping control. The fold change between groups was determined for all targets using the $2^{-\Delta\Delta Ct}$ method. Specific primer sequences are described below.

Oxidative stress assay

Hydrogen peroxide (H_2O_2) was measured using the Hydrogen Peroxide Assay Kit (Biovision, Milpitas, CA, USA). Glutathione (GSH)/ glutathione oxide ratio detection test kits (Abcam, Cambridge, MA, USA) were used to analyze the levels of GSH and glutathione oxide. Malondialdehyde (MDA) levels were measured using the TBARS Assay Kit in accordance with manufacturer guidelines (Cayman, Ann Arbor, MI, United States).

Western blot analysis

The 100 mg ear skin tissues were harvested, and homogenized with lysis buffer [50 mM Tris pH 8.0, 150 mM NaCl, 0.02% sodium azide, 0.2% SDS, 1 mM phenylmethylsulfonyl fluoride (PMSF), 10 μ L/ml aprotinin, 1% igapal 630 (Sigma Chem. Co. St. Louis, MO, USA), 10 mM NaF, 0.5 mM EDTA, 0.1 mM EGTA and 0.5% sodium deoxycholate]. The extracts were centrifuged at 23,000 g for 1 hour. An equal amount of protein (20 μ g) was separated

on a sodium dodecyl sulfate (SDS)/10%-polyacrylamide gel, and transferred to a nitrocellulose membrane (Hybond enhanced chemotherapy, Amersham Pharmacia Biotech Inc., Piscataway, NJ, USA). Blots were blocked for 2 hours at room temperature with 5% (w/v) non-fat dried milk in Tris-buffered saline [10 mM Tris (pH 8.0) and 150 mM NaCl] solution containing 0.05% tween-20. The membrane was incubated for 4 hours at room temperature with specific antibodies: Mouse monoclonal antibodies directed against HO-1 (1:1,000), GP×1 (1:1,000; Genetex, Irvine, CA, USA) were used in the study. The blot was then incubated with the corresponding conjugated anti-rabbit immunoglobulin G-horseradish peroxidase (Santa Cruz Biotechnology Inc. Santa Cruz, CA, USA). Immunoreactive proteins were detected using an enhanced chemotherapy (ECL) Western blotting detection system.

Statistical analysis

The experiments were repeated three times, and all experiments were repeated at least 3 times, resulting in similar results. All statistical analysis was performed with GraphPad Prism 5 software (Version 5.03; GraphPad software, Inc., CA, USA). Group differences were analyzed by one-way ANOVA followed by Tukey's multiple comparison test. All values are presented as mean \pm standard deviation (SD). Significance was set at $p < 0.05$ for all tests.

Results

Effects of AST on ear thickness and morphology

Ear thickness and ear morphology were observed to investigate whether treatment with AST could inhibit changes in the ear

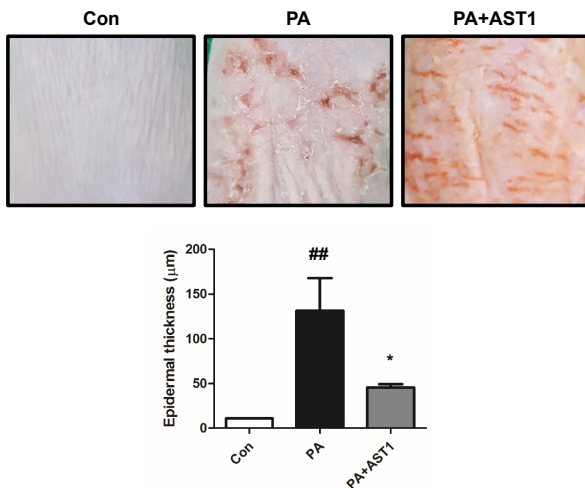


Fig. 1. Changes in the morphology and thickness of mice ears. PA and PA+AST1 treatment was performed 3 times a day, for 4 weeks, then the thickness of the ear was measured to determine the extent of inflammation of the ear epidermis. The skin thickness of the ear and morphology induced by PA treatment in the mice was compared with the PA+AST1 treated mice.

Mice treated with ASTe; 100 µL of 1 mg/mL (10 µg/cm²).

Data shown represent the mean \pm SD ($n = 3$).

PA (phalic acid) treated group.

PA+AST1 treated group [AST: 100 µL of 1 mg/mL (10 µg/cm²)] 3 hour after PA treatment.

^{##} $p < 0.01$, statistically significant compared with control.

^{*} $p < 0.05$ significantly different from PA treated group.

caused by PA procedures. Significant differences in the ear thickness of PA+ ($p < 0.05$) AST1 group were detected at a concentration of 1 mg/mL (10 µg/cm²) AST 100 µL after PA treatment, compared with the PA treatment group (Fig. 1). In addition, symptoms consisting of erythema, edema, and erosion were observed in the PA treatment group compared with the control group. These changes in ear morphology were dramatically different in PA+AST1 group treated group [AST: 100 µL of 1 mg/mL (10 µg/cm²; Fig. 1)].

Effect of AST on change of histology and mast cell in the mice ear skin

To investigate the histological inhibitory effect of AST treatment, histological analysis of the ear skin was performed. The epidermis of the ear was thicker in the PA treatment group compared with the control group. However, the thickness in the PA+AST1 group was less than the thickness measured in the PA group (Fig. 2). Ear skin tissues were stained with toluidine blue to determine mast cell infiltration into the dermis induced by PA treatment. In the dermis of ear skin, the number of mast cells increased significantly in PA-induced mice compared with the control group, and this increase was significantly ($p < 0.001$) inhibited by the application of AST in PA+AST1 group ($p < 0.001$; Fig. 2).

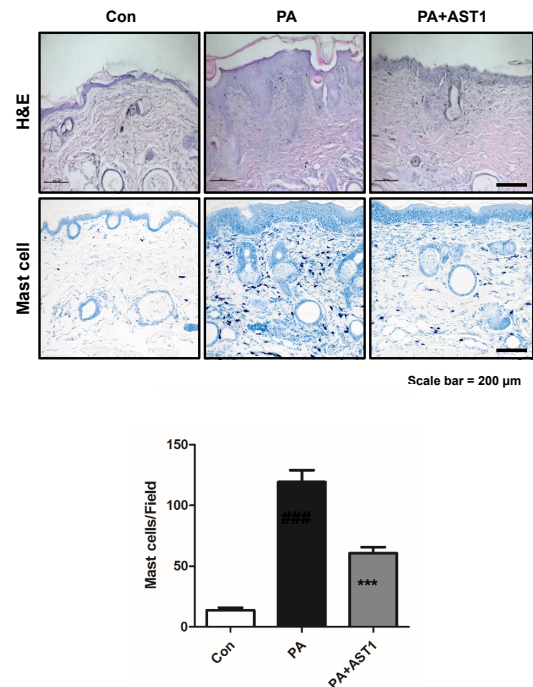


Fig. 2. Histopathological analysis of ear skin. After the sections of ear tissue were stained with hematoxylin and eosin, histopathological changes were observed at $\times 200$ magnification (scale bars, 100 µm). Mast cells infiltrate was observed in the control, PA, and PA+AST1 groups. The sections of ear tissue were stained with 0.25% toluidine blue and observed at $\times 200$ magnification (scale bars, 100 µm) and the number of infiltrated mast cells per specific area was measured.

Data shown represent the mean \pm SD ($n = 3$).

PA treated group, PA+AST1 treated group [100 µL of 1 mg/mL (10 µg/cm²)] 3 hour after PA treatment.

^{###} $p < 0.001$, statistically significant compared with control.

^{***} $p < 0.001$ significantly different from PA treated group.

Effect of AST on IgE concentration

To determine the inhibitory effect of AST 100 μL of 1 mg/mL (10 $\mu\text{g}/\text{cm}^2$) on serum IgE concentration in the blood an ELISA kit was used. The topical application of PA caused a significant increase in IgE concentration compared with control group ($p < 0.01$). However, when the PA group was compared with the PA+AST1 group, it was observed that the concentration of IgE in the AST group was significantly less ($p < 0.001$; Fig. 3).

Effects of AST on inflammatory cytokines

To investigate the effect of AST on inflammatory cytokines, TNF- α , IL1 β and IL-6 were quantified by Real-Time PCR. The level of TNF- α , IL-1 β and IL-6 in PA treated group was significantly ($p < 0.01$) higher compared with control group. However, the levels in the PA+AST1 treated group were statistically significantly lower compared with PA-treated group ($p < 0.001$; Fig. 4)

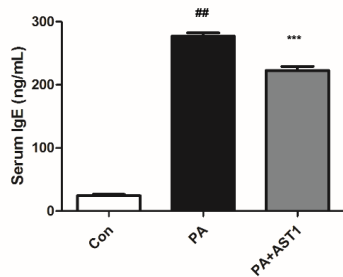


Fig. 3. Effects of AST treatment on serum IgE in mice. After all the treatments were completed, mice were sacrificed using anesthesia. Serum IgE concentration were quantified by ELISA. To measure serum IgE concentration, blood samples were taken from the abdominal veins of the mice.

Data shown represent the mean \pm SD ($n = 3$).

PA treated group, PA+AST1 treated group [100 μL of 1 mg/mL (10 $\mu\text{g}/\text{cm}^2$) 3 hour after PA treatment.

^{##} $p < 0.01$, statistically significant compared with control group.

^{***} $p < 0.001$ significantly different from PA treated group.

Effect of the AST treatment on MDA production

Oxidative stress under PA-induced skin inflammation conditions was evaluated using the level of MDA (an indicator of peroxidizing lipids). The level of MDA was significantly elevated in the PA-treated group compared with control group ($p < 0.01$). In the PA+AST1 treated group the level of MDA was significantly less compared with PA-treated group ($p < 0.05$; Fig. 5).

Effect on GSH

Total GSH, a major antioxidant, was investigated to determine oxidative stress under PA-induced AD skin conditions and AST capacity to alleviate AD. The total GSH was significantly lower in PA-treated group compared with the control group ($p < 0.001$), but in the PA+AST1 treated group, compared with PA-treated group, there was a significantly higher level of GSH ($p < 0.001$; Fig. 6).

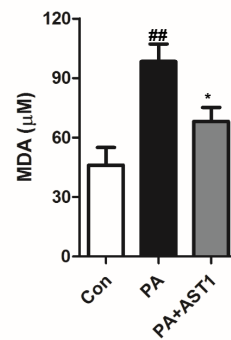


Fig. 5. Effect of the AST treatment on MDA production. AST relieves oxidative stress in PA-induced AD in skin tissues in mice.

Data shown are representative of the mean \pm SD ($n = 3$).

PA treated group, PA+AST1 treated group [100 μL of 1 mg/mL (10 $\mu\text{g}/\text{cm}^2$) 3 hour after PA treatment.

^{##} $p < 0.01$, statistically significant compared with control.

^{*} $p < 0.05$ significantly different from PA treated group.

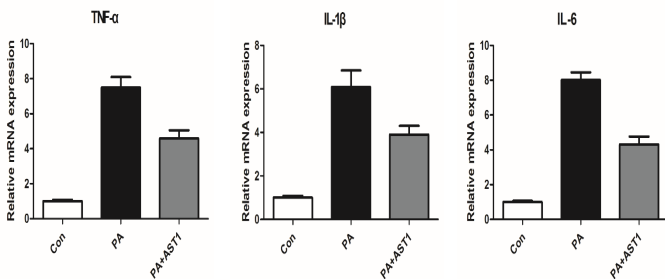


Fig. 4. Effect of AST on cytokine expressions in mice. To extract total RNA for mRNA quantification, Easy-BLURTM total RNA Extraction Kit (inNtRON Biotech, Daejeon, Korea) was used. For synthesizing of cDNA, High-Capacity cDNA Reverse Transcription Kits (Applied Biosystems, Foster city, CA) were used in accordance with manufacturer's instructions.

Data shown represent the mean \pm SD ($n = 3$).

PA treated group, PA+AST1 treated group [100 μL of 1 mg/mL (10 $\mu\text{g}/\text{cm}^2$) 3 hour after PA treatment.

^{##} $p < 0.01$, statistically significant compared with control.

^{***} $p < 0.001$ significantly different from PA treated group.

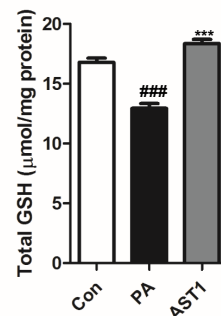


Fig. 6. Effect of AST on GSH concentration increase. Data are shown the mean \pm SD ($n = 3$).

PA treated group, PA+AST1 treated group [100 μL of 1 mg/mL (10 $\mu\text{g}/\text{cm}^2$) 3 hours after PA treatment.

^{###} $p < 0.001$, statistically significant compared with control.

^{***} $p < 0.001$ significantly different from PA treated group.

The effect of AST on the increase of superoxide dismutase activity

To determine the effect of AST on increasing superoxide dismutase (SOD) activity, Oxidative stress conditions were investigated by observing H_2O_2 levels in PA-induced skin conditions. The H_2O_2 level was significantly higher in the PA-treated group compared with the control group ($p < 0.001$), but in the PA+AST1 treated group compared with PA-treated group, the level of H_2O_2 was significantly lower ($p < 0.01$; Fig. 7).

Effect of AST treatment on GPx-1, HO-1 activity

The expression of antioxidant-related genes, such as GPx-1 and HO-1 was further investigated by Western blot analysis, and it showed that the expression of HO-1 and GPx-1 was lower in PA-treated group compared with control, but in the PA+AST1 treated group compared with PA-treated group, it was higher (Fig. 8).

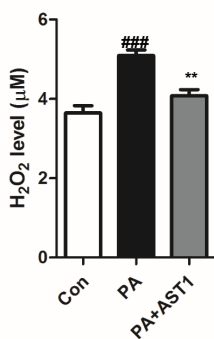


Fig. 7. AST in PA treated mice significantly lowers the level of hydrogen peroxide. H_2O_2 activity increased compared with the PA group. AST relieved oxidative stress (indirectly) in PA-induced mice tissues. Data shown represent the mean \pm SD ($n = 3$). PA treated group, PA+AST1 treated group [100 μ L of 1 mg/mL (10 μ g/cm²)] 3 hour after PA treatment.

^{###} $p < 0.001$, statistically significant compared with control.

^{**} $p < 0.01$ significantly different from PA treated group.

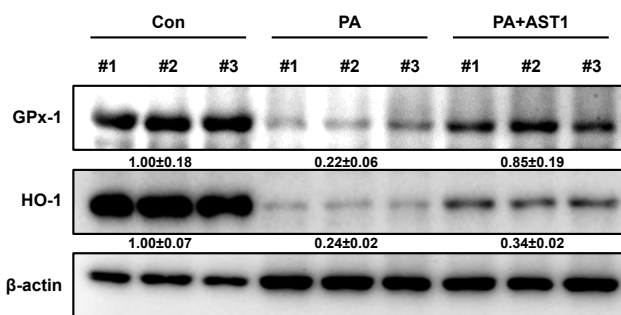


Fig. 8. Effect of AST treatment on GPx-1, HO-1 activity. AST relieved oxidative stress in PA-induced mice tissues. Expression of antioxidant-related markers in skin tissues, HO-1 and GPx-1 were determined by Western blot. #1-3 refer to skin tissues of the different mice in the same group.

β -actin was used an internal control.

Each blot is representative of 3 experiments.

Data are shown the mean \pm SD ($n = 3$).

Con, control, PA treated group, PA+AST1 treated group [100 μ L of 1 mg/mL (10 μ g/cm²)] 3 hours after PA treatment.

Discussion

AD is a chronic skin condition/disease characterized by frequent skin barrier defects and variable T-helper cell infiltration [21]. AD has a highly complex pathophysiological mechanism which has not yet been fully identified, but oxidative stress, gastro-microbiome, and aeroallergens, have recently been reported as important factors [22]. AD is a systemic condition/disease that is not limited to skin problems, and focus should be on the interrelationships between other organs. A study on the correlation between the skin and intestinal microbiome in patients with AD reported the need for sufficient time and continuous treatment to recover microbial diversity [23]. A significant decrease in intestinal microbiome was observed after using local calcineurin inhibitors, steroids, and antibiotics in treatment of AD [23]. In clinics, antihistamines, immunosuppressants and local corticosteroids are used to treat AD [24]. However, these treatments are merely aimed at relieving the symptoms of AD rather than treating the cause. Moreover, there is toxicity and side effects associated with long-term use of antihistamines, immunosuppressants and local corticosteroids. Therefore, there is a need for new insight and therapeutic materials in the treatment of AD; natural products [25], and herbal medicines [26] have been studied.

AST, (3') Dihydroxy β carotene4,4'dione) is a carotenoid pigment found in various marine animals [11]. The microalgae *H. pluvialis* has the highest detectable levels of natural AST. Mammals lack the ability to synthesize AST and rely on dietary intake. Studies investigating the effects of AST on healthy adults have reported no adverse effects or toxicity of *H. pluvialis* AST in the experimental dose [12]. Recently, commercial production and processing of natural AST has become possible, making it more available as a treatment [12].

Inflammation is a natural bioimmune defense system that secretes inflammatory factors to protect the body and removes harmful stimuli from outside [27]. In particular, the skin removes ROS from the inflammatory site and inhibits the expression of anti-inflammatory genes (NF- κ B) in the inflammatory mechanism. AD is believed to be a disease in which these immune mechanisms have been modulated [28].

Oxidative stress caused by an imbalance of production and storage of ROS has been studied with regards to the inflammation of cells and damage to tissues, affecting cell aging, and various organ diseases (cancer, arthritis, diabetes, dermatitis, and cardiovascular disorders) [29]. Oxidative stress activates the transcription of NF- κ B, which results in inflammatory enzymes (INOS, cyclooxygenase-2 (COX-2) producing inflammatory agents (NO, PGE₂), which promote inflammatory cytokine production [30].

Pro-inflammatory cytokines (such as IL-6, IL-1 β , TNF- α , Interleukin-4) are secreted from Th2 cells, causing complex inflammatory reactions that cause the production of ROS and RNS [31].

The ROS and RNS produced as a result of cytokine release and oxidative stress enhance the inflammatory process, affecting cell survival and leading to endothelial cell activation away from the lesion [29,32]. Mast cells, macrophages and keratinocytes involved in inflammation are also activated by oxidative stress [30].

Malondialdehyde (MDA) is produced during the lipid peroxidation of polysaturated fatty acids (PUFAs), and because ROS is so unstable, ROS-related tissue destruction is observed as an indirect end product of lipid peroxidation processes such as MDA production [33].

SOD is an intracellular antioxidant enzyme, and GPx is a major enzyme required to convert hydrogen peroxide into oxygen and

water, so it is used as an important biomarker to indirectly show oxidative damage to tissues [34]. Clinical and experimental animal studies of AD using AST as treatment have reported significant anti-inflammatory effects [16-20] and balanced Th1 cells and Th2 cells [28].

In this study, we investigated the anti-inflammatory effect on AD through the antioxidant capacity of AST based on the study that oxidative stress is a major factor in the development and deterioration of AD [10]. We further focused on the antioxidant effect of AST by measuring antioxidant biomarkers such as glutathione, (GSH), SOD, glutathione peroxidase-1 (GPx-1), heme-oxygenase 1e (HO-1).

In this study, we observed ear thickness and levels of inflammatory mediators such as, the number of mast cells, and levels of IgE, inflammatory cytokines, and MDA in PA-induced AD in mice to test hypertrophic treatment for AD. To determine whether AST could effectively and dramatically block the pathway of inflammation, nuclear factor expression, and enzymes. In addition, oxidative stress was investigated to determine whether AST can improve levels of antioxidant agents such as GSH, SOD, GPx-1, HO-1 to prevent side effects and find potential for long-term treatment.

Compared with the control group, mice ear thickness was thicker in the PA treatment group (which showed skin changes caused by AD) compared with the PA+AST1 group suggesting that AST had stabilized the inflammatory mechanism.

The observation of mast cell counts in mice ear dermis showed a significantly higher mast cell count in PA-induced mice compared with the number of inflammatory mast cells in the PA+AST1 group.

Analysis of mouse blood confirmed that the concentration of IgE in the PA group was significantly higher in the PA+AST group, suggesting that there was a stabilizing of inflammation.

The levels of inflammatory cytokines TNF- α , IL-1 β and IL-6 increased significantly in the PA treatment group and was significantly lower in the PA+AST1 treatment group.

Oxidative MDA levels of peroxide lipids, which can indirectly identify oxidative stress conditions, were significantly higher in the PA treatment group, compared with the PA+AST1 treatment group.

The levels of GSH measured as an indirect marker of antioxidant activity to protect the human body under oxidative stress, was significantly lower in the PA-treated group compared with the controls, and the PA+AST1-treated group.

H₂O₂ levels, the result of enzyme SOD activity, which plays an important role in antioxidant defense mechanisms, was significantly higher in PA-treated groups compared with the control group, and the PA+AST1-treated group.

The expression of antioxidant-related genes (GPx-1, HO-1) detected in Western blotting resulted in a lower expression in the PA treatment group compared with the PA+AST1 treatment group.

Therefore, the antioxidant activity capacity of AST is meaningful in the treatment of AD, and at the same time suggests a good alternative to the treatment of AD prevention and treatment in the future. However, the limitation of this study was the small size of the study ($n = 9$) which was performed in an animal model. Further studies are necessary.

Conflicts of Interest

Ho-Sueb Song has been the editor in chief of Journal of Acupuncture Research since April 2011, but had no role in the decision to publish this original article. No other potential conflict of interest relevant to this article was reported.

Ethical Statement

This research did not involve any human or animal experiment.

References

- [1] Leung DYM, Bieber T. Atopic dermatitis. *Lancet* 2003;361:151-160.
- [2] Asher MI, Montefort S, Björkstén B, Lai CK, Strachan DP, Weiland SK et al. Worldwide time trends in the prevalence of symptoms of asthma, allergic rhinoconjunctivitis, and eczema in childhood: ISAAC Phases One and Three repeat multicountry cross-sectional surveys. *Lancet* 2006;368:733-743.
- [3] Lopez Carrera YI, Al Hammadi A, Huang YH, Llamado LJ, Mahgoub E, Tallman AM. Epidemiology, Diagnosis, and Treatment of Atopic Dermatitis in the Developing Countries of Asia, Africa, Latin America, and the Middle East: A Review. *Dermatol Ther* 2019;9:685-705.
- [4] Kobusiewicz A, Zalewska-Janowska AM, Lesiak A, Narbutt J. Management of severe atopic dermatitis in adult patients. *Przegląd Dermatologiczny* 2020;107:234-245.
- [5] Coondoo A, Phiske M, Verma S, Lahiri K. Side-effects of topical steroids: A long overdue revisit. *Indian Dermatol Online J* 2014;5:416-425.
- [6] Thyssen JP, Rinnov MR, Vestergaard C. Disease Mechanisms in Atopic Dermatitis: A Review of Aetiological Factors. *Acta Derm Venereol* 2020;100:341-348.
- [7] Jiang MZ, Tsukahara H, Ohshima Y, Sato S, Todoroki Y, Hiraoka M et al. Effects of Antioxidant and Nitric Oxide on Chemokine Production in TNF- α -stimulated Human Dermal Microvascular Endothelial Cells. *Life Sci* 2004;75:1159-1170.
- [8] Devadasan S, Sarkar R, Barman KD, Kaushik S. Role of Serum Melatonin and Oxidative Stress in Childhood Atopic Dermatitis: A Prospective Study. *Indian Dermatol Online J* 2020;11:925-929.
- [9] Maintz L, Novak N. Modifications of the innate immune system in atopic dermatitis. *J Innate Immun* 2011;3:131-141.
- [10] Sivaranjani N, Venkata RAO S, Rajeev G. Role of Reactive Oxygen Species and Antioxidants in Atopic Dermatitis. *J Clin Diagn Res* 2013;7:2683-2685.
- [11] Lorenz RT, Cysewski GR. Commercial potential for Haematococcus microalgae as a natural source of astaxanthin. *Trends Biotechnol* 2000;18:160-167.
- [12] Guerin M, Huntley ME, Olaizola M. Haematococcus astaxanthin: applications for human health and nutrition. *Trends Biotechnol* 2003;21:210-216.
- [13] Lee YS, Jeon SH, Ham HJ, Lee HP, Song MJ, Hong JT. Improved Anti-Inflammatory Effects of Liposomal Astaxanthin on a Phthalic Anhydride-Induced Atopic Dermatitis Model. *Front Immunol* 2020;11:565285.
- [14] Naguib Y, Gazella KA. Nature's Super Antioxidant. *Total Health* 2000;22:36-37.
- [15] Nakajima Y, Inokuchi Y, Shimazawa M, Otsubo K, Ishibashi T, Hara H. Astaxanthin, a dietary carotenoid, protects retinal cells against oxidative stress in-vitro and in mice in-vivo. *J Pharm Pharmacol* 2008; 60:1365-1374.
- [16] Yoshihisa Y, Andoh T, Matsunaga K, Ur Rehman M, Maoka T, Shimizu T. Efficacy of astaxanthin for the treatment of atopic dermatitis in a murine model. *PLoS ONE* 2016;11:e0152288.
- [17] Meephanan J, Trakanwittayarak S, Pootongkam S, Thaiwat S. Astaxanthin effect on the elicitation of allergic contact dermatitis to hair dye containing p-phenylenediamine. *J Dermatol Nurses Assoc* 2020;12:2.
- [18] Choo WT, Teoh ML, Phang SM, Convey P, Yap WH, Goh BH, Beardall J. Microalgae as Potential Anti-Inflammatory Natural Product Against Human Inflammatory Skin Diseases. *Front Pharmacol* 2020;11:1086.
- [19] Park JH, Yeo IJ, Han JH, Suh JW, Lee HB, Hong JT. Anti-inflammatory effect of astaxanthin in phthalic anhydride induced atopic dermatitis animal model. *Exp Dermatol* 2018;27:378-385.
- [20] Lee YS, Lee CH, Bae JT, Nam KT, Moon DB, Hwang OK et al. Inhibition of skin carcinogenesis by suppression of NF- κ B dependent ITGAV and TIMP-1 expression in IL-32 γ overexpressed condition. *J Exp Clin Cancer Res* 2018;37:293.
- [21] Na CH, Baghoomian W, Simpson EL. A Therapeutic Renaissance - Emerging Treatments for Atopic Dermatitis. *Acta Derm Venereol* 2020;100:367-379.
- [22] Grobe W, Bieber T, Novak N. Pathophysiology of atopic dermatitis. *J German Soc Dermatol* 2019;17:433-440.
- [23] Kim JE, Kim HS. Microbiome of the skin and gut in atopic dermatitis (Ad): Understanding the pathophysiology and finding novel management

- strategies. *J Clin Med* 2019;8:444.
- [24] Khan SMA, Sethi B, Malik N, Anwar I. Awareness regarding protective measures against side effects following long term corticosteroid therapy. *Pakistan J Surg* 2019;35:44-48.
- [25] Rotaru M, Iancu GM, Matran IM. Importance of food in the control of inflammation in atopic dermatitis. *Exp Ther Med* 2020;20:206.
- [26] Kwon CY, Lee BR, Kim SR, Lee JS, Park MJ, Kim NK. Effectiveness and Safety of Herbal Medicine for Atopic Dermatitis: An Overview of Systematic Reviews. *Evid Based Complement Alternat Med* 2020;2020:4140692.
- [27] Chawla A, Nguyen KD, Goh YPS. Macrophage -mediated inflammation in metabolic disease. *Nat Rev Immun* 2011;11:738-749.
- [28] Kidd P. Astaxanthin, Cell Membrane Nutrient with Diverse Clinical Benefits and Anti-Aging Potential. *Altern Med Rev* 2011;16:355-364.
- [29] Aruoma OI, Grootveld M, Bahorun T. Free Radicals in Biology and Medicine: From Inflammation to Biotechnology. *Biofactors* 2006;27:1-3.
- [30] Rivest S. Activation of the nuclear factor kappa B (NF- kB) and cyclooxygenase-2 (COX-2) genes in cerebral blood vessels in response to systemic inflammation. *Mol Psychiatry* 1999;4:500
- [31] Bickers DR, Athar M. Oxidative stress in the pathogenesis of skin disease. *J Invest Dermatol* 2006;126:2565-2575.
- [32] Nakanishi M, Rosenberg D. Multifaceted roles of PGE in inflammation and cancer. *Semin Immunopathol* 2013;35:123-137.
- [33] Cherian DA, Peter T, Narayanan A, Madhavan SS, Achammada S, Vynat GP. Malondialdehyde as a Marker of Oxidative Stress in Periodontitis Patients. *J Pharm Bioallied Sci* 2019;11:S297-S300.
- [34] Kabel AM. Free radicals and antioxidants: role of enzymes and nutrition. *World J Nutr Health* 2014;2:3538.