

Campomelic dysplasia: A review of a rare lethal genetic disorder

Young A Kim

Department of Pediatrics, Pusan National University Children's Hospital, Yangsan, Korea

Campomelic dysplasia (CD) is a rare genetic disorder characterized by multiple skeletal anomalies and the abnormal development of male reproductive organs. To date, the *SOX9* gene is the only known causal gene for CD, and approximately 90 causative mutations in *SOX9* have been identified worldwide. CD is diagnosed based on clinical characteristics of skeletal dysplasia (e.g., short bowed long bones, kyphoscoliosis, bell-shaped thoracic cage with 11 pairs of ribs, and hypoplastic scapulars), typical facial features of Pierre Robin sequence with cleft palate, and gonadal dysgenesis in 46,XY individuals. Most patients with CD exhibit life-threatening respiratory failure owing to laryngotracheomalacia and hypoplastic thorax during the neonatal period. Although fatal complications decrease after infancy, several medical conditions continue to require proper management. A better understanding of this rare but lethal condition may lead to more appropriate treatments for patients.

Key words: Campomelic dysplasia, *SOX9*, Osteochondrodysplasias, Gonadal dysgenesis

REVIEW ARTICLE

Received: August 4, 2021
Revised: September 15, 2021
Accepted: September 27, 2021

Correspondence to: Young A Kim
Department of Pediatrics, Pusan National University Children's Hospital, 20 Geumo-ro, Mulgeum-eup, Yangsan 50612, Korea
Tel: +82-55-360-3516
E-mail: youngflo@hanmail.net

ORCID
Young A Kim: <https://orcid.org/0000-0002-8332-5200>

Copyright © 2021, Interdisciplinary Society of Genetic & Genomic Medicine

This is an Open Access article distributed under the terms of the Creative Commons Attribution Non-Commercial License (<https://creativecommons.org/licenses/by-nc/4.0>) which permits unrestricted non-commercial use, distribution, and reproduction in any medium, provided the original work is properly cited.

INTRODUCTION

Campomelic dysplasia (CD; OMIM #114290), a rare genetic disorder characterized by skeletal abnormalities and male to female sex reversal, was first described by Maroteaux *et al.* in 1971 [1]. Due to the skeletal anomalies in the airway and thoracic cage, patients with CD often present with life-threatening respiratory failure, particularly during neonatal periods [2]. The incidence rate of CD has been reported at approximately 0.05-0.09 per 10,000 live births [3], and no reliable data exists on the prevalence which is currently estimated as 1:40,000 to 1:80,000 [2]. Data have been reported across case reports and small series, and three Korean cases have been published [4-6]. The *SOX9* (17q 24.3-q25.1) gene is the only known causal gene for CD [7-9]. To date, approximately 90 causative mutations have been identified in *SOX9*, which are listed on the Human Gene Mutation Database (HGMD; <http://www.hgmd.org>). Most mutations are sporadic and familial CD is rarely found, although CD is inherited in an autosomal dominant manner.

The term “campomelic” comes from the Greek for “bent limb”, but this characteristic is neither specific to CD nor a mandatory finding for diagnosis. Bowing of the long bone is present in many other skeletal dysplasias (e.g., osteoporosis imperfecta), and is absent in about 10% of cases of CD, a condition called acampomelic CD, which shares the same OMIM number as CD [2].

CLINICAL CHARACTERISTICS

A wide spectrum of pathologic clinical features involving multiple organs is observed in CD, not only skeletal anomalies but also dysmorphic facial features and male sex reversal (Table 1). Skeletal dysplasia, which is the most representative

Table 1. Common clinical and radiographic features of campomelic dysplasia

System	Clinical features	Radiographic features
Head	Relatively large head Dolichocephaly	Ventriculomegaly
Face	High forehead Midface hypoplasia Flattened nasal bridge Long philtrum Cleft palate Micrognathia and microglossia Low-set ears	
Neck	Cervical spine instability Laryngotracheomalacia	Cervical spine dislocation
Thorax	Bell-shaped thorax Scoliosis (kyphoscoliosis)	Scapular hypoplasia Hypoplastic vertebral pedicles Eleven pairs of ribs
Pelvis and genitalia	Ambiguous genitalia or female external genitalia in 46,XY individuals	Narrow vertical iliac bodies Subluxation of hip joints
Extremities	Short, bowed limbs (occasionally upper limb) Pretibial skin dimples Brachydactyly Clubfoot	Bowed femora and tibiae

characteristic of CD, includes bowing and shortening of long bones, hip dislocation, clubfoot, and pretibial skin dimples due to bowing of the lower legs [2]. Skeletal radiographs of patients with CD typically show spine anomalies, scoliosis, hypoplastic scapulae, bell-shaped thorax with 11 pairs of ribs, and vertically oriented narrow iliac wings (Fig. 1).

Patients with CD also exhibit dysmorphic facial features known as the Pierre-Robin sequence (PRS) with cleft palate, including high forehead, midface hypoplasia, hypertelorism, long philtrum, micrognathia, and low-set ears. Another specific characteristic of CD is male to female sex reversal that results from the abnormal development of male reproductive organs. Approximately 75% of 46,XY patients have ambiguous or complete female genitals [2]. Sensorineural and conductive hearing impairment and laryngotracheomalacia are common, and ventriculomegaly, which is usually of the communicating type, is also found in patients with CD. Some patients have reported minor congenital heart defects, such as an atrioseptal defect [4,5].

DIAGNOSIS

There is no consensus on the diagnostic criteria for CD, but clinical diagnosis can be established based on clinical features

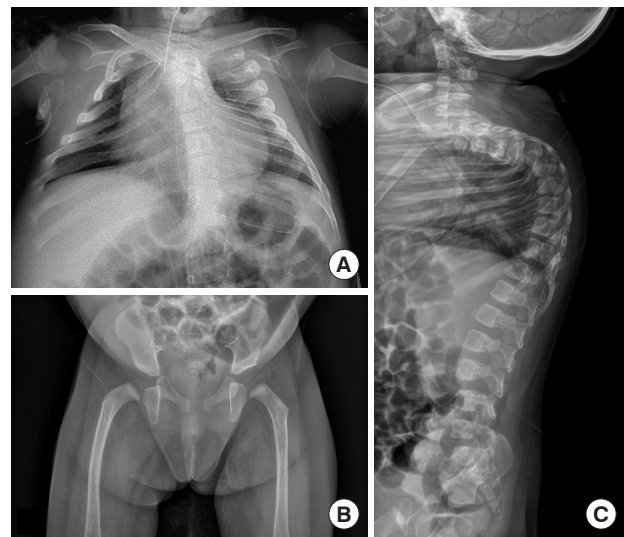


Fig. 1. Radiographs of a 7-month-old girl with campomelic dysplasia showing (A) a bell-shaped thoracic cage, 11 pairs of ribs, scapular hypoplasia, (B) vertical ischia, bowing of the right proximal femur, and (C) thoracic kyphosis.

and radiographic interpretation [2]. In particular, radiographic findings, including short bent limbs, bell-shaped thoracic cages with 11 pairs of ribs, or hypoplastic scapulars, are consistent and reliable diagnostic cues for CD.

Similar clinical manifestations between CD and some diseases should be considered during differential diagnosis. For example, patients with spondyloepiphyseal dysplasia congenita, one of the type 2 collagen disorders caused by *COL2A1* mutations, present a dysmorphic faces with cleft palate and short limbs [10]. Also, patients with Stickler syndrome, a mild form of type 2 collagen disorder, have similar facial features to CD. Bowing long bones suggest a rare but fatal skeletal disorders not only in CD but also in other conditions. In a study by Tonni *et al.* [11] molecular and histopathological investigations revealed that four fetuses presented bowing limbs on prenatal ultrasound and were diagnosed with CD with a *de novo* mutation in *SOX9*, osteogenesis imperfecta type II, Cumming syndrome, and femoral-facial syndrome.

SOX9 is the only known causative gene of CD, and the presence of a heterozygous pathogenic variant in *SOX9* can confirm the diagnosis of CD [2]. Sequence analysis of *SOX9* allows the detection of the majority of pathogenic variants. Using chromosomal microarray analysis, large deletions and duplications that cannot be detected by sequence analysis can be identified. Rarely, a reciprocal translocation that involves the *SOX9* locus but does not result in *SOX9* copy number changes can be found through a karyotype [12].

GENES AND MOLECULAR PATHOGENICITY

The *SOX9* gene codes for a high mobility group (HMG) DNA-binding domain-containing transcription factor that plays an important role in multiple organ development, especially in chondrogenesis and sex determination. In 1994, Foster *et al.* established a high resolution map across a 20 Mb region of chromosome 17q24.1-q25.1 that was previously revealed to contain the locus that is responsible for CD [7-9].

SOX9 is a master regulator of chondrogenesis [13]. *SOX9* is expressed in prechondrocytes and chondrocytes during embryogenic development, and is an essential transcription factor that controls chondrocyte differentiation and cartilage formation. *SOX9* is co-expressed with *COL2A1*, which encodes type II collagen, the major cartilage matrix protein, and *SOX9* protein binds to sequences in *COL2A1* and activates chondrocyte-specific enhancers in nonchondrocytic cells [14,15]. As *COL2A1* expression is directly regulated by the *SOX9* protein, mutations in *SOX9* lead to decreased *COL2A1* expression, resulting in skeletal dysplasia.

Moreover, *SOX9* expression is also detected in non-chondrogenic tissues, such as the neural crest, gonad, otic vesicle, lung, notochord, neural tube, pancreas, and cardiac cushions during embryonic development in vertebrates [14,16,17]. These results suggest that *SOX9* mutations are related to deformities that include multiple organs not only skeletal systems in CD. Embryonically, the expression of *SOX9* is closely correlated with the formation of neural crest cells, a group of cells unique to vertebrates that contribute to the development of the craniofacial complex [18]. *SOX9* acts as a craniofacial regulatory element and is associated with large deletions or translocations found in non-syndromic PRS [19]. This can be the basis for explaining the formation of cleft palate and the typical facial features of CD.

In mammalian male development, the *SRY* (sex-determining region on the Y chromosome) gene is fundamental and initiates testis differentiation of the undetermined male gonads [20]. *SOX9* (SRY-related HMG-box gene 9) is another key gene involved in a cascade for testicular formation. Shortly after *SRY* activation, *SOX9* is activated and involved in the male sex development process at various stages, including glycogenesis in pre-Sertoli cells, coelomic epithelium proliferation, mesonephric migration, vasculogenesis, and testicular cord formation [21]. However, *SOX9* gene mutations do not cause sex reversal in all male patients. Approximately 25% of male patients with CD do not exhibit sex reversal [2], as seen in the patient with a normal male phenotype of the two 46,XY karyotypes of Korean patients (Table 2). The cooperative dimerization of *SOX9* with other genes is essential for chondrogenesis but not for gonadal development [22]. In sex development, *SOX9* proteins act as monomers and bind sex-determining genes, such as *SF1*, which might explain why CD is not always accompanied by sex reversal.

GENOTYPE-PHENOTYPE CORRELATIONS

To date, 140 *SOX9* gene mutations have been reported on the HGMD, among which only 87 have been identified as CD-causing mutations. Of these 87 mutations, almost all of them were detected using a sequence analysis of *SOX9*: 39 missense/nonsense mutations, 16 small insertions, nine small deletions, three splicing mutations, one small indel mutation, and one regulatory abnormality. Ten large deletion mutations and eight complex rearrangements have been also reported. In three Korean patients with CD, three different novel heterozygous mutations in the *SOX9* gene have been reported; two were small deletions [4,6] and one was a nonsense mutation [5].

In CD, there is no clear genotypic phenotype correlation re-

Table 2. Summary of *SOX9* gene mutations and the clinical characteristics in three Korean patients with campomelic dysplasia

Patients	Type	Exon	Mutation	Karyotype	Sex phenotype	Medical conditions	Clinical course
1 [4]	Small deletion	3	c.1372del (p.Gln458ArgfsX12)	46,XY	Male	Laryngomalacia Atrial septal defect Recurrent pneumonia	Death at 4 months
2 [5]	Nonsense	3	c.1105C>T (p.Gln369*)	46,XX	Female	Ventriculomegaly Laryngotracheomalacia Atrial septal defect Gastroesophageal reflux	Alive at 40 months Global developmental delay
3 [6]	Small deletion	1	c.235delC (p.Gln79Argfs*31)	46,XY	Female	Tracheal ring Tracheomalacia Dysphagia Hearing impairment	Alive at 2 years Home ventilator Global developmental delay

garding mutation type or location and clinical severity [23]. However, some degree of correlation is observed in some cases. The farther the translocation breakpoint is from *SOX9*, the milder the phenotype, including its impact on male genitalia and skeletal anomalies [24]. This property was observed in a family with acampomelic CD which was transmitted through several generations [25]. Moreover, several cases with isolated disorders of sex development were identified with duplications or deletions involving a region located approximately 600 kb upstream of *SOX9* [26]. Notably, among the 53 mutations not related to CD out of 140 *SOX9* mutations, more than half have been classified as isolated disorders of sex development (n=29), and other phenotypes of PRS with or without minor skeletal anomalies (n=17). Most of these mutations are associated with large deletions, large insertions/duplications, and chromosomal rearrangements. These types of *SOX9* mutations appear to be associated with mild phenotypes that do not involve multiple organs.

MANAGEMENT OF MANIFESTATIONS

During the neonatal period, CD is a life-threatening condition primarily because it causes respiratory failure. Fatal respiratory failure is associated with tracheobronchomalacia or cervical instability, rather than with a hypoplastic thoracic cage [2]. Many of the surviving patients require a tracheostomy to relieve laryngotracheomalacia, and home mechanical ventilator support is needed because of the restrictive lung condition caused by hypoplastic thoracic cage, scoliosis, and tracheobronchomalacia. All three Korean patients with CD needed tracheostomy for laryngotracheomalacia. One patient died of respiratory failure at 4 months of age [4]. Of the two surviving patients, one was able to discontinue mechanical ventilation after a closure operation of the atrioseptal defect [5], while the other patient required home ventilator support [6].

Although fatal complications decrease after infancy, mental retardation, global developmental delay, feeding problems, scoliosis, and respiratory complications will continue to need medical intervention. For patients with medical conditions such as cleft palate, cervical instability, hip subluxation, and clubfoot, proper management is required. Hearing aids are needed in patients with hearing impairments. Regular radiographic examinations of the spinal curvature are necessary to determine the progression of scoliosis. For cervical instability and progressive kyphoscoliosis that compromises lung function, surgical treatment is required, whereas bracing is usually

not helpful [27]. Patients that are 46,XY phenotypic females mostly have internal male genital organs. Gonadectomy is recommended because of the increased risk of malignant changes, as reported in a phenotypic female who developed gonadoblastoma at age 3 [28].

FAMILY COUNSELING

Most reported *SOX9* mutations are *de novo* mutations found in sporadic cases. However, due to the autosomal dominant inheritance manner of CD, a genetic approach to the proband's parents and siblings is also required. As some families with mosaicism have been reported [29], prenatal evaluation and diagnosis are recommended for future pregnancies as there is a risk of recurrence in these families. For fetuses at risk of CD, fetal ultrasound allows the detection of clues, such as increased nuchal transparency, micrognathia, short bowed limbs, and hypoplastic scapulae [30]. Molecular genetic testing through DNA analysis or chromosomal analysis from amniocentesis is confirmative.

CONCLUSION

CD is a very rare genetic disorder, but it is lethal in affected patients, especially during the neonatal period. This review focused on the clinical and genetic characteristics of patients with CD. A better understanding of patients with CD will allow clinicians to provide more appropriate care to patients. Early diagnosis and management of the associated complications in affected patients can prevent deterioration of their clinical conditions and improve their quality of life.

CONFLICTS OF INTEREST

No potential conflict of interest relevant to this article was reported.

ACKNOWLEDGMENTS

This work was supported by a 2019 clinical research grant from the Interdisciplinary Society of Genetic & Genomic Medicine.

REFERENCES

1. Maroteaux P, Spranger J, Opitz JM, Kucera J, Lowry RB, Schimke

- RN, et al. The campomelic syndrome. *Presse Med* 1971;79:1157-62.
2. Unger S, Scherer G, Superti-Furga A. Campomelic Dysplasia. *GeneReviews*[®] [Internet]. Seattle: University of Washington; 2008 (Updated on 2021 Mar 18). <https://www.ncbi.nlm.nih.gov/books/NBK1760/>
 3. Stoll C, Dott B, Roth MP, Alembik Y. Birth prevalence rates of skeletal dysplasias. *Clin Genet* 1989;35:88-92.
 4. Kim HY, Yoon CH, Kim GH, Yoo HW, Lee BS, Kim KS, et al. A case of campomelic dysplasia without sex reversal. *J Korean Med Sci* 2011;26:143-5.
 5. Ko JM, Hah JH, Kim SW, Cho TJ, Kim GH, Yoo HW. A Korean girl with campomelic dysplasia caused by a novel nonsense mutation within the SOX9 Gene. *J Genet Med* 2012;9:89-92.
 6. Lee HN, Kim CY, Jung E, Lee BH, Lee BS, Kim EAR, et al. Campomelic dysplasia with sex reversal harboring a novel frameshift mutation. *Neonatal Med* 2020;27:197-201.
 7. Tommerup N, Schempp W, Meinecke P, Pedersen S, Bolund L, Brandt C, et al. Assignment of an autosomal sex reversal locus (SRA1) and campomelic dysplasia (CMPD1) to 17q24.3-q25.1. *Nat Genet* 1993;4:170-4.
 8. Wagner T, Wirth J, Meyer J, Zabel B, Held M, Zimmer J, et al. Autosomal sex reversal and campomelic dysplasia are caused by mutations in and around the SRY-related gene SOX9. *Cell* 1994; 79:1111-20.
 9. Foster JW, Dominguez-Steglich MA, Guioli S, Kwok C, Weller PA, Stevanovic M, et al. Campomelic dysplasia and autosomal sex reversal caused by mutations in an SRY-related gene. *Nature* 1994;372:525-30.
 10. Gregersen PA, Savarirayan R. Type II Collagen Disorders Overview. *GeneReviews*[®] [Internet]. Seattle: University of Washington; 2019. <https://www.ncbi.nlm.nih.gov/books/NBK540447/>
 11. Tonni G, Palmisano M, Lituania M, Grisolia G, Baffico AM, Bonasoni MP, et al. Skeletal dysplasia with bowing long bones: proposed flowchart for prenatal diagnosis with case demonstration. *Taiwan J Obstet Gynecol* 2016;55:771-6.
 12. Ninomiya S, Isomura M, Narahara K, Seino Y, Nakamura Y. Isolation of a testis-specific cDNA on chromosome 17q from a region adjacent to the breakpoint of t(12;17) observed in a patient with acampomelic campomelic dysplasia and sex reversal. *Hum Mol Genet* 1996;5:69-72.
 13. Bi W, Deng JM, Zhang Z, Behringer RR, de Crombrughe B. Sox9 is required for cartilage formation. *Nat Genet* 1999;22:85-9.
 14. Ng LJ, Wheatley S, Muscat GE, Conway-Campbell J, Bowles J, Wright E, et al. SOX9 binds DNA, activates transcription, and coexpresses with type II collagen during chondrogenesis in the mouse. *Dev Biol* 1997;183:108-21.
 15. Bell DM, Leung KK, Wheatley SC, Ng LJ, Zhou S, Ling KW, et al. SOX9 directly regulates the type-II collagen gene. *Nat Genet* 1997; 16:174-8.
 16. Chiang EF, Pai CI, Wyatt M, Yan YL, Postlethwait J, Chung B. Two SOX9 genes on duplicated zebrafish chromosomes: expression of similar transcription activators in distinct sites. *Dev Biol* 2001; 231:149-63.
 17. Spokony RF, Aoki Y, Saint-Germain N, Magner-Fink E, Saint-Jeanet JP. The transcription factor Sox9 is required for cranial neural crest development in *Xenopus*. *Development* 2002;129:421-32.
 18. Roellig D, Tan-Cabugao J, Esaian S, Bronner ME. Dynamic transcriptional signature and cell fate analysis reveals plasticity of individual neural plate border cells. *Elife* 2017;6:e21620.
 19. Gordon CT, Attanasio C, Bhatia S, Benko S, Ansari M, Tan TY, et al. Identification of novel craniofacial regulatory domains located far upstream of SOX9 and disrupted in Pierre Robin sequence. *Hum Mutat* 2014;35:1011-20.
 20. Koopman P, Gubbay J, Vivian N, Goodfellow P, Lovell-Badge R. Male development of chromosomally female mice transgenic for Sry. *Nature* 1991;351:117-21.
 21. Kanai Y, Hiramatsu R, Matoba S, Kidokoro T. From SRY to SOX9: mammalian testis differentiation. *J Biochem* 2005;138:13-9.
 22. Bernard P, Tang P, Liu S, Dewing P, Harley VR, Vilain E. Dimerization of SOX9 is required for chondrogenesis, but not for sex determination. *Hum Mol Genet* 2003;12:1755-65.
 23. Meyer J, Sudbeck P, Held M, Wagner T, Schmitz ML, Bricarelli FD, et al. Mutational analysis of the SOX9 gene in campomelic dysplasia and autosomal sex reversal: lack of genotype/phenotype correlations. *Hum Mol Genet* 1997;6:91-8.
 24. Leipoldt M, Erdel M, Bien-Willner GA, Smyk M, Theurl M, Yatsenko SA, et al. Two novel translocation breakpoints upstream of SOX9 define borders of the proximal and distal breakpoint cluster region in campomelic dysplasia. *Clin Genet* 2007;71:67-75.
 25. Hill-Harfe KL, Kaplan L, Stalker HJ, Zori RT, Pop R, Scherer G, et al. Fine mapping of chromosome 17 translocation breakpoints > or = 900 Kb upstream of SOX9 in acampomelic campomelic dysplasia and a mild, familial skeletal dysplasia. *Am J Hum Genet* 2005;76:663-71.
 26. Hyon C, Chantot-Bastarud S, Harbuz R, Bhourri R, Perrot N, Peycelon M, et al. Refining the regulatory region upstream of SOX9 associated with 46,XX testicular disorders of Sex Development (DSD). *Am J Med Genet A* 2015;167A:1851-8.
 27. Thomas S, Winter RB, Lonstein JE. The treatment of progressive kyphoscoliosis in campomelic dysplasia. *Spine (Phila Pa 1976)* 1997;22:1330-7.
 28. Hong JR, Barber M, Scott CI, Guttenberg M, Wolfson PJ. 3-Year-old phenotypic female with campomelic dysplasia and bilateral gonadoblastoma. *J Pediatr Surg* 1995;30:1735-7.
 29. Smyk M, Obersztyn E, Nowakowska B, Bocian E, Cheung SW, Mazurczak T, et al. Recurrent SOX9 deletion campomelic dysplasia due to somatic mosaicism in the father. *Am J Med Genet A* 2007;143A:866-70.
 30. Gentilin B, Forzano F, Bedeschi MF, Rizzuti T, Faravelli F, Izzi C, et al. Phenotype of five cases of prenatally diagnosed campomelic dysplasia harboring novel mutations of the SOX9 gene. *Ultrasound Obstet Gynecol* 2010;36:315-23.