

Case Report



OPEN ACCESS

Received: Jun 15, 2021

Revised: Jul 29, 2021

Accepted: Aug 8, 2021

Correspondence to

Toshikatsu Okumura

Division of Metabolism, Biosystemic Science,
Gastroenterology and Hematology/Oncology,
Department of Medicine, Asahikawa Medical
University, Midorigaoka Higashi 2-1-1-1,
Asahikawa 078-8510, Japan.
E-mail: okumurat@asahikawa-med.ac.jp

Copyright © 2021. Korean Gastric Cancer
Association

This is an Open Access article distributed
under the terms of the Creative Commons
Attribution Non-Commercial License ([https://
creativecommons.org/licenses/by-nc/4.0](https://creativecommons.org/licenses/by-nc/4.0))
which permits unrestricted noncommercial
use, distribution, and reproduction in any
medium, provided the original work is properly
cited.

ORCID iDs

Toshikatsu Okumura
<https://orcid.org/0000-0003-1810-007X>

Author Contributions

Conceptualization: M.M.; Data curation:
N.H., I.K., T.S., Y.M., M.M., Y.N.; Formal
analysis: N.H., I.K.; Investigation: M.M.;
Methodology: M.M.; Project administration:
M.M.; Resources: M.M.; Supervision: O.T.;
Validation: N.H., I.K.; Visualization: N.H., I.K.;
Writing - original draft: M.M., O.T.; Writing -
review & editing: M.M., O.T.

Conflict of Interest

No potential conflict of interest relevant to this
article was reported.

<https://jgc-online.org>

Successful Treatment of Advanced Gastric Cancer with Brain Metastases through an Abscopal Effect by Radiation and Immune Checkpoint Inhibitor Therapy

Momotaro Muto¹, Hiroataka Nakata¹, Kenichi Ishigaki¹, Shion Tachibana¹,
Moe Yoshida¹, Mizue Muto¹, Nobuyuki Yanagawa¹, Toshikatsu Okumura ²

¹Department of Internal Medicine, Engaru Kosei General Hospital, Engaru, Japan

²Division of Metabolism, Systemic Bioscience, Gastroenterology and Hematology/Oncology, Department of
Medicine, Asahikawa Medical University, Asahikawa, Japan

ABSTRACT

The abscopal effect refers to the phenomenon in which local radiotherapy is associated with the regression of metastatic cancer that is distantly located from the irradiated site. Here, we present a case of a patient with advanced gastric cancer and brain metastases who was successfully treated with brain radiotherapy and anti-programmed death-1 (PD-1) therapy-induced abscopal effect. Although anti-PD-1 therapy alone could not prevent disease progression, the metastatic lesions in the brain and also in the abdominal lymph node showed a drastic response after brain radiotherapy and anti-PD-1 therapy. To our knowledge, this is the first reported case of successful treatment of advanced gastric cancer with multiple brain and abdominal lymph node metastases, possibly through anti-PD-1 therapy combined with brain radiotherapy-induced abscopal effect. We suggest that the combination of brain radiotherapy and anti-PD-1 therapy may be considered as a therapeutic option for advanced gastric cancer, especially when there is brain metastasis.

Keywords: Gastric cancer; Abscopal effect; Immune checkpoint inhibitor; Brain metastasis; Radiation

INTRODUCTION

The combination of radiation therapy and immune checkpoint inhibitors has been reported to improve clinical outcomes in multiple metastatic cancers. An abscopal effect occurs when localized radiotherapy causes the regression of tumors distant from the irradiated site. In 2012, Postow et al. [1] published for the first time a case of the abscopal effect in a patient with melanoma treated with ipilimumab, an immune checkpoint inhibitor, and radiotherapy in the New England Journal of Medicine. In metastatic melanoma, potential radiation-induced abscopal responses have also been reported with the use of immune checkpoint inhibitors, such as cytotoxic T-lymphocyte-associated antigen 4 blockade [2,3]. In recent years, several studies [4-8] have detailed the characteristics and results of clinical cases after stereotactic brain radiation therapy and anti-programmed death-1 (PD-1)/programmed death

ligand-1 (PD-L1) combination treatment, including melanoma, retroperitoneal sarcoma, head and neck squamous cell carcinoma, and lung cancer.

According to a recent review [9], the abscopal effect phenomenon in radiation and anti-PD1/PD-L1 combination therapy involves a series of chain reactions. First, radiation induces the breakage of the deoxyribonucleic acid's double strands, which damages the tumor cells. The damaged cells then release large amounts of tumor-associated antigen (TAA) fragments into the blood within a short time for antigen-presenting cells. During this process, inflammatory cytokine cascades are simultaneously secreted and activated. Subsequently, these TAA fragments and inflammatory cytokines are recognized and engulfed by dendritic cells, leading to an immune response that deliberately attacks the tumor cells outside the irradiated field. In particular, the cascade immune reactions originating from the TAA fragments support the participation of other immune checkpoint inhibitors [10-12]. It has also been suggested that irradiation can upregulate PD-L1 expression in cancer cells, macrophages, and dendritic cells [9]. Therefore, anti-PD1/PD-L1 antibodies could theoretically enhance the anti-tumor immune modulation of radiation and synergistically achieve better outcomes. Here, we present for the first time a case in which immune checkpoint inhibitors and radiotherapy for the brain induced an abscopal effect in gastric cancer, leading to the complete remission of the brain and abdominal lymph node metastases recurrence.

CASE REPORT

A 65-year-old male patient presented to our hospital for adjuvant therapy for gastric cancer. **Figure 1** shows the clinical course of the patient. He had been diagnosed with advanced

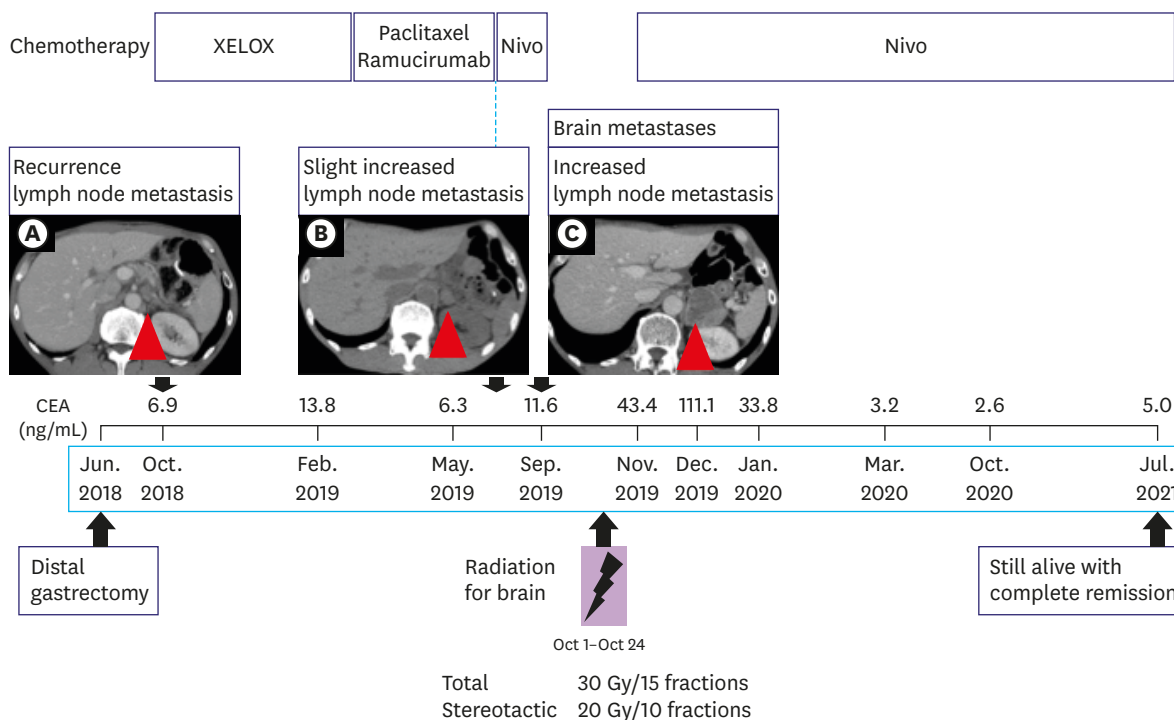
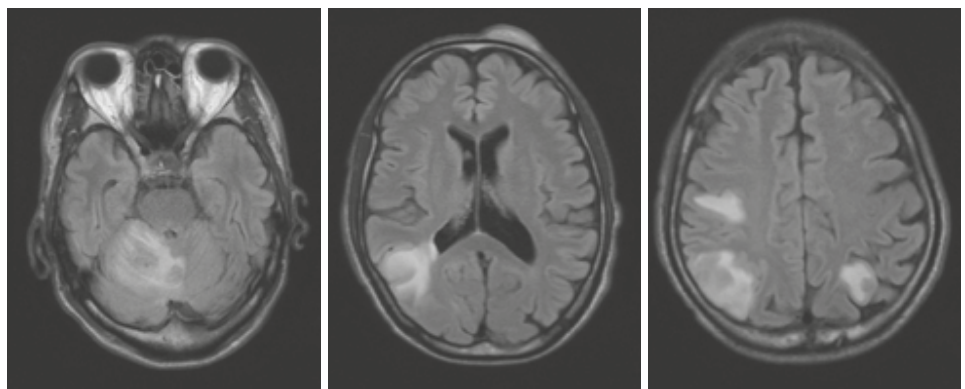


Fig. 1. Clinical course of the case. Each red arrow in A, B and C indicates a metastasis in the abdominal lymph node. XELOX = capecitabine/oxaliplatin; Nivo = nivolumab.

gastric adenocarcinoma with bulky lymph node metastasis and had undergone distal gastrectomy with Roux-en-Y reconstruction in June 2018 after one cycle of S-1 plus cisplatin chemotherapy and two cycles of capecitabine plus cisplatin plus trastuzumab chemotherapy. HER2 was positive, and the pathological stage was pT3N3aM0 (pStage IIIB). Four months after the operation (October 2018), computed tomography (CT) revealed a lymph node metastasis, measuring 14 mm in diameter, in the blind-ended remnant stomach (**Fig. 1A**). After the detection of recurrence, he received two cycles of capecitabine/oxaliplatin chemotherapy and three cycles of ramucirumab plus paclitaxel. Since slightly increased abdominal lymph nodes were observed (**Fig. 1B**) and severe anorexia and numbness developed when ramucirumab + paclitaxel therapy was performed, we modified the treatment to nivolumab, which was conducted every 2 weeks for 2 cycles, as shown in **Fig. 1**. During the second cycle of nivolumab (September 2019), he could not speak clearly, felt muscle weakness, and experienced impaired walking. He was then transferred by ambulance due to clonic spasms. Brain CT and magnetic resonance imaging (MRI) showed four solid lesions with a maximum diameter of 5 cm in the right cerebellum, temporal lobe, and parietal lobe (**Fig. 2**), suggesting metastasis to the brain from the gastric cancer. Whole-brain radiotherapy (30 Gy in 15 fractions) and additional stereotactic radiotherapy (20 Gy in 10 fractions) were performed for the brain metastases. Although his dysarthria and neurological symptoms markedly improved after radiotherapy, the size of the metastatic lymph node in the abdomen increased to 38 mm in diameter (September 2019), as shown in **Fig. 1C**. Nivolumab was resumed, as insisted by the patient. The follow-up CT and MRI at 3 months after the re-administration of nivolumab (**Fig. 3**) showed a dramatic reduction in the brain and lymph node metastases (February 2020), indicating that the metastatic lesions responded satisfactorily to radiotherapy and nivolumab. As shown in **Fig. 3**, the brain and abdominal lesions almost had completely disappeared in October 2020. The time-course changes in the carcinoembryonic antigen (CEA) levels (**Fig. 1**) supported the clinical course. Thus far, the patient has been able to maintain a good quality of life while continuously receiving nivolumab therapy. Even at present (July 2021), after 44 cycles of nivolumab, a complete response is ongoing. The patient maintained excellent performance status and is still currently alive 22 months after the initial diagnosis of the brain metastases.

The patient provided informed consent to publish the included information.



Sep. 2019

Fig. 2. Magnetic resonance imaging during 3rd-line chemotherapy showed four solid masses, with a maximum diameter of 5 cm, in the right cerebellum, temporal lobe, and parietal lobe, indicating brain metastases from gastric cancer.

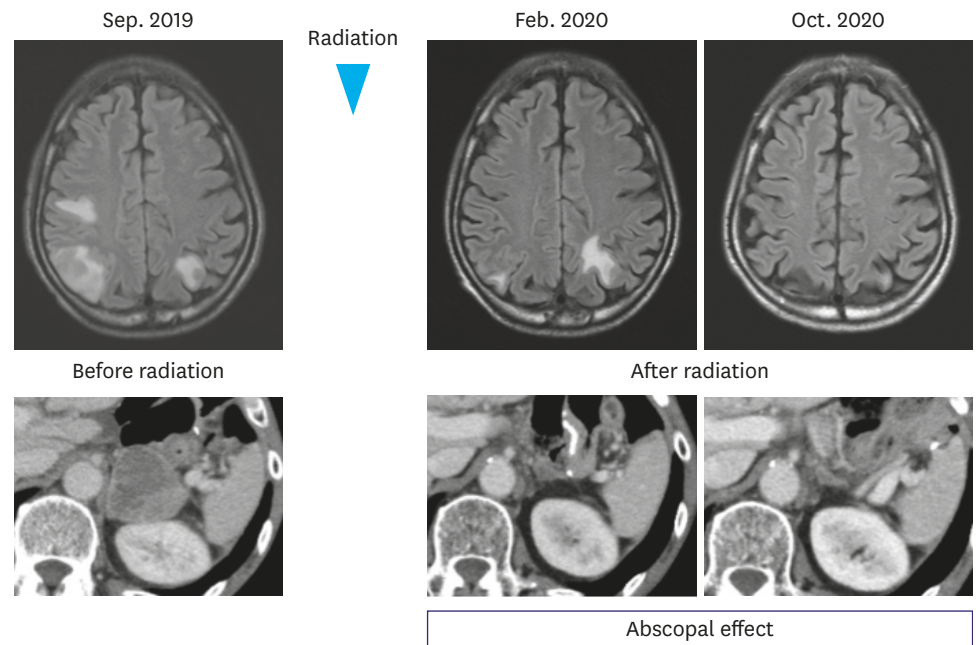


Fig. 3. Time-course changes of the brain metastases (magnetic resonance imaging) and the abdominal lymph node metastasis (computed tomography) are shown.

DISCUSSION

The clinical observation of partial responses in unirradiated lesions after radiotherapy, termed the abscopal effect, has gradually attracted a lot of attention and has inspired oncologists to combine stereotactic radiotherapy with immunotherapy, such as immune checkpoint inhibitors, to improve clinical outcomes. The abscopal effect should be distinguished from the immunotherapy effect alone during combination therapy, especially when immunotherapy and radiotherapy are used sequentially or at the same time. If the unirradiated tumor was relieved before radiation therapy, this phenomenon cannot be attributable to the abscopal effect as it was probably induced by immunotherapy alone. Meanwhile, the “real” abscopal effect is observed if the patients had stable or progressive conditions during immunotherapy, and the local and the abscopal lesions were relieved after radiotherapy. In the present study, gastric cancer recurrence developed even after anti-PD-1 therapy in the abdominal lymph nodes and in the brain. However, an unirradiated tumor in the abdominal lymph node was completely relieved after radiotherapy for brain metastasis, followed by anti-PD-1 therapy. Therefore, we concluded that the real abscopal effect was induced by the combination of radiotherapy and anti-PD-1 therapy. However, we could not exclude the possibility that complete response in brain metastasis after radiotherapy and anti-PD-1 therapy might have occurred due to nivolumab or radiation therapy alone. Despite two cycles of nivolumab, the metastatic lesions in the brain and abdominal lymph node seemed to progress further, along with the increasing CEA levels, although we could not completely exclude the possibility of pseudo-progression. However, the progressive lymph node metastasis in the abdomen disappeared after radiation for the brain and PD-1 therapy but not with PD-1 alone, suggesting that the subsequent radiation and anti-PD-1 therapy may have induced an abscopal effect. Therefore, we should consider that the abscopal effect may have been a major factor in the complete remission of the multiple brain metastases. It has been reported that stereotactic brain radiation therapy and anti-PD-1/PD-L1 combination

treatment could induce an abscopal effect in melanoma, retroperitoneal sarcoma, head and neck squamous cell carcinoma, or lung cancer [1-8]. To our knowledge, this was the first case in which subsequent immune checkpoint inhibitors and radiotherapy-induced an abscopal effect in gastric cancer. As such, we suggest that combination therapy with immune checkpoint inhibitors and radiation should be considered as a therapeutic strategy for advanced gastric cancer.

Stereotactic radiosurgery has become the main therapy for metastatic brain tumors [13]. However, the response to treatment is poor in patients with gastric cancer and brain metastases. Most brain metastases from gastric cancer are detected in the advanced stages of the disease [14-16], with a mean survival period of 1.3 to 2.4 months [17]. Considering the nature of brain metastases from gastric cancer as described above, it is surprising that the present case with four metastatic lesions in the brain has survived for more than 22 months since the brain metastases were first observed. The unexpected favorable outcome further supports our speculation that radiotherapy plus anti-PD-1 antibody was capable of inducing an abscopal effect in this case, thereby inducing a drastic response in the brain metastases from gastric cancer.

REFERENCES

1. Postow MA, Callahan MK, Barker CA, Yamada Y, Yuan J, Kitano S, et al. Immunologic correlates of the abscopal effect in a patient with melanoma. *N Engl J Med* 2012;366:925-931.
[PUBMED](#) | [CROSSREF](#)
2. Stamell EF, Wolchok JD, Gnjjatic S, Lee NY, Brownell I. The abscopal effect associated with a systemic anti-melanoma immune response. *Int J Radiat Oncol Biol Phys* 2013;85:293-295.
[PUBMED](#) | [CROSSREF](#)
3. Hiniker SM, Chen DS, Reddy S, Chang DT, Jones JC, Mollick JA, et al. A systemic complete response of metastatic melanoma to local radiation and immunotherapy. *Transl Oncol* 2012;5:404-407.
[PUBMED](#) | [CROSSREF](#)
4. Grimaldi AM, Simeone E, Giannarelli D, Muto P, Falivene S, Borzillo V, et al. Abscopal effects of radiotherapy on advanced melanoma patients who progressed after ipilimumab immunotherapy. *OncoImmunology* 2014;3:e28780.
[PUBMED](#) | [CROSSREF](#)
5. Levy A, Massard C, Soria JC, Deutsch E. Concurrent irradiation with the anti-programmed cell death ligand-1 immune checkpoint blocker durvalumab: single centre subset analysis from a phase 1/2 trial. *Eur J Cancer* 2016;68:156-162.
[PUBMED](#) | [CROSSREF](#)
6. Brennenman RJ, Sharifai N, Fischer-Valuck B, Hassanzadeh C, Guzelian J, Chrisinger JS, et al. Abscopal effect following proton beam radiotherapy in a patient with inoperable metastatic retroperitoneal sarcoma. *Front Oncol* 2019;9:922.
[PUBMED](#) | [CROSSREF](#)
7. Choi JS, Sansoni ER, Lovin BD, Lindquist NR, Phan J, Mayo LL, et al. Abscopal effect following immunotherapy and combined stereotactic body radiation therapy in recurrent metastatic head and neck squamous cell carcinoma: a report of two cases and literature review. *Ann Otol Rhinol Laryngol* 2019;129:517-522.
[PUBMED](#) | [CROSSREF](#)
8. Garelli E, Rittmeyer A, Putora PM, Glatzer M, Dressel R, Andreas S. Abscopal effect in lung cancer: three case reports and a concise review. *Immunotherapy* 2019;11:1445-1461.
[PUBMED](#) | [CROSSREF](#)
9. D'Souza NM, Fang P, Logan J, Yang J, Jiang W, Li J. Combining radiation therapy with immune checkpoint blockade for central nervous system malignancies. *Front Oncol* 2016;6:212.
[PUBMED](#) | [CROSSREF](#)
10. Choi CW, Jeong MH, Park YS, Son CH, Lee HR, Koh EK. Combination treatment of stereotactic body radiation therapy and immature dendritic cell vaccination for augmentation of local and systemic effects. *Cancer Res Treat* 2019;51:464-473.
[PUBMED](#) | [CROSSREF](#)

11. Galon J, Bruni D. Approaches to treat immune hot, altered and cold tumours with combination immunotherapies. *Nat Rev Drug Discov* 2019;18:197-218.
[PUBMED](#) | [CROSSREF](#)
12. Schumacher TN, Schreiber RD. Neoantigens in cancer immunotherapy. *Science* 2015;348:69-74.
[PUBMED](#) | [CROSSREF](#)
13. McDermott MW, Sneed PK. Radiosurgery in metastatic brain cancer. *Neurosurgery* 2005;57:S45-S53.
[PUBMED](#) | [CROSSREF](#)
14. Kasakura Y, Fujii M, Mochizuki F, Suzuki T, Takahashi T. Clinicopathological study of brain metastasis in gastric cancer patients. *Surg Today* 2000;30:485-490.
[PUBMED](#) | [CROSSREF](#)
15. Han JH, Kim DG, Chung HT, Kim CY, Park CK, Chung YS, et al. Radiosurgery for brain metastasis from advanced gastric cancer. *Acta Neurochir (Wien)* 2010;152:605-10.
[PUBMED](#) | [CROSSREF](#)
16. York JE, Stringer J, Ajani JA, Wildrick DM, Gokaslan ZL. Gastric cancer and metastasis to the brain. *Ann Surg Oncol* 1999;6:771-776.
[PUBMED](#) | [CROSSREF](#)
17. Kraszkievicz M, Wydmanski J. Brain metastases from stomach cancer - The role of different treatment modalities and efficacy of palliative radiotherapy. *Rep Pract Oncol Radiother* 2014;20:32-37.
[PUBMED](#) | [CROSSREF](#)