



Video-Assisted Thoracic Surgery Thymectomy: Transpleural Approach

In Kyu Park, M.D., Ph.D.

Department of Thoracic and Cardiovascular Surgery, Seoul National University Hospital, Seoul National University College of Medicine, Seoul, Korea

ARTICLE INFO

Received June 1, 2021

Revised July 15, 2021

Accepted July 16, 2021

Corresponding author

In Kyu Park

Tel 82-2-2072-2342

Fax 82-2-764-3664

E-mail ikpark@snu.ac.kr

ORCID

<https://orcid.org/0000-0003-3550-5554>

There are several types of minimally invasive approaches for thymectomy, of which the transpleural approach by video-assisted thoracoscopic surgery is particularly useful. In this approach, thymectomy is performed from either side of the thoracic cage. Thoracic surgeons should be familiar with the principles of the procedure, the anatomy of the region, and surgical strategies for successful thymectomy. The details of transpleural thymectomy are discussed herein.

Keywords: Thymectomy, Video-assisted thoracic surgery, Myasthenia gravis, Thymus neoplasms

Introduction

Thymectomy is performed for the treatment of a wide range of thymic diseases, such as benign tumors, malignant tumors, and myasthenia gravis. The extent of thymectomy is tailored according to the disease condition. Total thymectomy is recommended for malignant tumors [1]. Partial thymectomy can be considered for benign tumors and early-stage thymoma in highly selected patients [2]. Extended thymectomy, which includes the radical removal of ectopic thymic tissue, is recommended in myasthenia gravis [3].

The lateral approach using video-assisted thoracoscopic surgery (VATS) is a useful method for thymectomy. Surgeons can choose a unilateral approach on either side or a bilateral approach to accomplish the surgical and oncologic goals. Additional cervical incision, upper partial sternotomy, or subxiphoid incision can be helpful in specific situations.

There is a global consensus on the principles that apply to surgical resection in general, as well as minimally invasive surgery for thymic neoplasms [4,5]. Surgeons should familiarize themselves with these guidelines prior to performing VATS thymectomy.

Procedures and techniques

Anesthesia

General anesthesia with double-lumen endotracheal intubation is used in general. Selective ventilation with CO₂ insufflation provides an excellent operative view and space. Single-lumen endotracheal tube intubation and controlled ventilation can also be used in combination with CO₂ insufflation. Nonintubated general anesthesia with or without a laryngeal mask under deep sedation can be applied for simple procedures [6].

Position of the patient and surgery team

The most popular patient position is the semi-supine position up to 30°. The patient is placed in the supine position with a roll placed under the ipsilateral chest [7,8]. The ipsilateral arm is abducted or dropped below the chest to expose the axillary area. The contralateral arm is also positioned in the same way if the bilateral approach has been planned. The arms should not interfere with the course of the instruments, especially those inserted through the axillary area. Care should be taken to not overextend the shoulder.

The operator and the assistant stand on the ipsilateral



side of the patients, while the scrub nurse stands on the contralateral side (Fig. 1). The lateral decubitus position, as in conventional lung surgery, can also be used.

Instruments

Endoscopic instruments and 5-mm, 30° video thoracoscopy are used. Energy-based vessel sealing devices are more convenient than electrocautery for the dissection of mediastinal tissue and the division of small vessels. Endoscopic clips or staplers are necessary depending on the situation.

Port placement

The number of ports to use is a matter of preference. Single-port surgery, double-port surgery, and triple-port surgery can be performed safely and effectively [7,9]. In multiport surgical procedures, only 3-mm or 5-mm ports are added compared with single-port surgery, and this does not increase clinically significant tissue damage or postoperative pain.

When performing triple-port surgery, the main procedure can be performed via three 5-mm ports, and the specimen can be removed through 1 of the ports after appropriate extension of the wound. In the bilateral approach, the preceding unilateral procedure is performed with three 5-mm ports on the ipsilateral side, and the specimen is removed via the contralateral side.

The first port is created in the fifth or sixth intercostal space in the mid-axillary line. After creating pneumothorax with single-lung ventilation and ambient air, a 5-mm trocar is introduced into the thoracic cavity. The thoracic

cavity is inspected with a thoracoscope for potential adhesion, and CO₂ insufflation is started using a pressure limit of 8 mm Hg. Under thoracoscopic guidance, trocars for additional ports are introduced into the third or fourth intercostal space in the anterior axillary line and into the fifth or sixth intercostal space along the midclavicular line. Any instrument can be inserted into any port according to the surgeon's preference and the situation. Usually, the scope is inserted through lower ports (Fig. 2). In the left-side approach, the trocar in the superior port is inserted first to avoid cardiac injury. One incision is expanded at the end of the procedure according to the size of the specimen to be removed. In the case of single-port surgery, a 2- to 3-cm window is made in the fourth or fifth intercostal space in the anterior axillary line [9,10]. An additional port is made in the third intercostal space in the anterior axillary line for double-port surgery.

Port placement should be adjusted for each case, considering the extent of thymectomy and the patients' individual anatomical characteristics.

Thymectomy

Surgeons should have their own strategy for every step of thymectomy. The first step for thymectomy is identifying the anatomical landmarks and pathology of the thymus and making a plan for the case. The important landmarks of the anterior mediastinum in the lateral approach are the sternum ventrally, internal thoracic vein cranially, phrenic nerve dorsally, and diaphragm caudally. The mediastinal pleura is opened along with these structures. Dissection is usually carried out from the caudal to cranial direction. The main procedure starts with dissection of the subster-

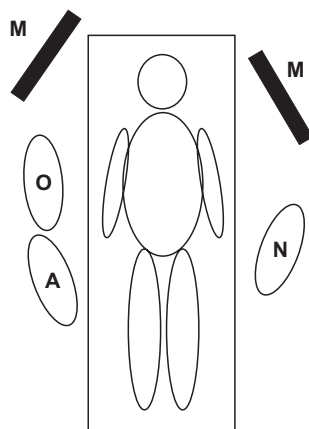


Fig. 1. Position of personnel and monitors in the right side approach. O, operator; A, assistant; N, scrub nurse; M, video monitor.




Fig. 2. Port placement in triple-port surgery. Three ports were made in the fourth and sixth intercostal spaces with 5-mm trocars. Any instrument can be inserted via any port depending on the surgeon's preferences and the situation. The ipsilateral arm is dropped below the chest.

nal area to maximize the space. Care should be taken to protect the phrenic nerve while removing as much perithymic adipose tissue as possible, especially in myasthenia gravis patients. The innominate veins can be identified without difficulty by guidance of the internal thoracic veins (Fig. 3). The internal thoracic veins can be divided to facilitate exposure of the upper poles. The thymic veins should be dissected in full circumference, and the left brachiocephalic vein on the far side should be identified before division, especially when using energy-based vessel sealing devices, to avoid detrimental injuries to the left brachiocephalic vein. Only the upper part of the contralateral phrenic nerve can be identified from either side (Fig. 4). A complete dissection of contralateral diaphragmatic

adipose tissue is impossible with the lateral approach. Thus, a bilateral approach should be performed for extended thymectomy in myasthenia gravis. In the bilateral approach, it is preferential to start with the right-side approach with triple 5-mm ports. Dissection proceeds to the contralateral diaphragm as much as possible during the right-side operation, as dissection of the left diaphragmatic adipose tissue is relatively difficult due to the lower diaphragm position and left heart.

Whenever dense adhesion of the tumor to adjacent structures is encountered, *en bloc* resection should be attempted. Resection of the lung, pericardium, or phrenic nerves can be performed safely without difficulty. However, resection of other structures, such as great vessels and

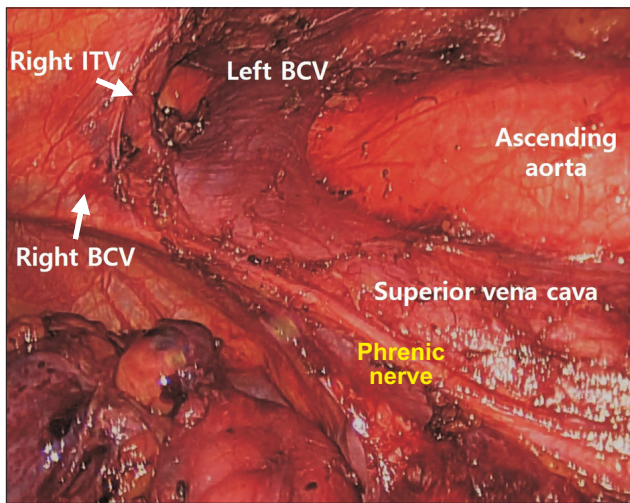


Fig. 3. Important anatomical structures in the right-side approach. ITV, internal thoracic vein; BCV, brachiocephalic vein.

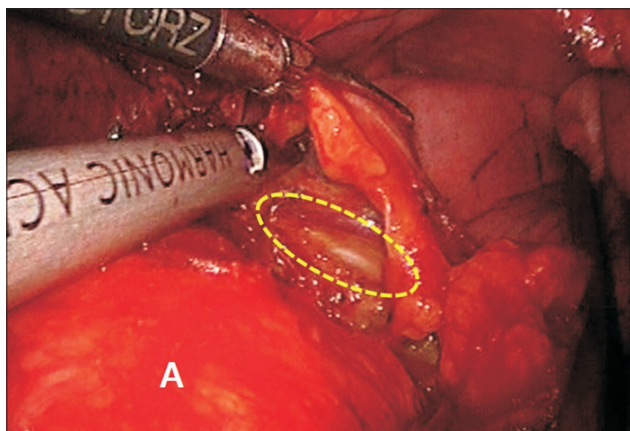


Fig. 4. The upper part of the left phrenic nerve (yellow-dotted area) can be identified during the right-side approach beyond the ascending aorta upon lifting the left mediastinal pleura. A, ascending aorta.

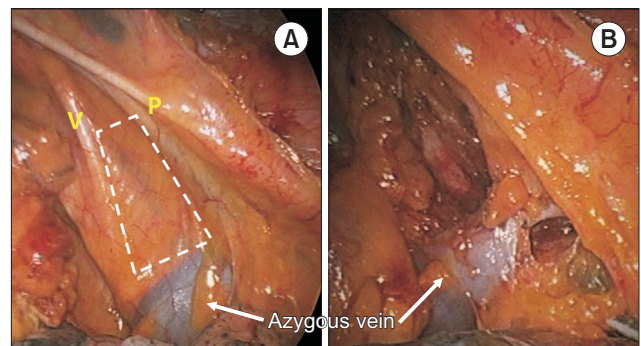


Fig. 5. (A) The right paratracheal area (white dotted area) is accessible in the right-side approach. (B) Right paratracheal node dissection can be performed above and below the azygous vein. V, vagus nerve; P, phrenic nerve.

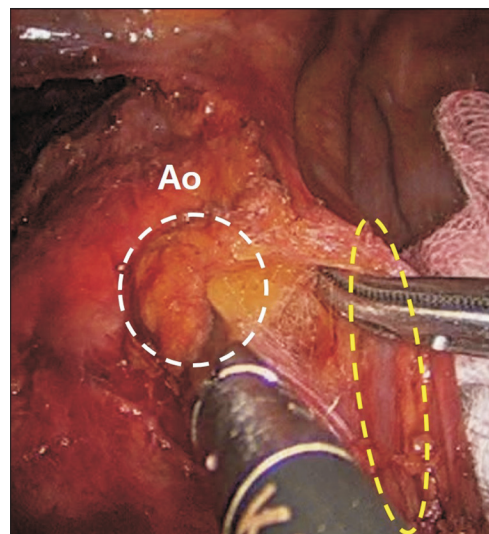


Fig. 6. The paraaortic node (white dotted area) is pooled out beneath the left pericardiophrenic neurovascular bundle (yellow dotted area). Ao, aortic arch.

the chest wall, is not possible by VATS. A surgeon should be prepared for conversion to open surgery if the possibility of such involvement exists.

Lymph node dissection is recommended in thymic malignancies [5]. The perithymic, prevascular, and supradiaphragmatic nodes should be dissected routinely. The paratracheal (right-side approach) (Fig. 5) or paraaortic nodes (left-side approach) (Fig. 6) should be dissected in tumors invading other structures ($\geq T2$) [11].

After completion of thymectomy, a small-bore drain is inserted through 1 port. If no bleeding is expected, placement of a drain can be omitted. Usually, 1 drain through the final side is sufficient in the bilateral approach.

Handling of specimens

It is important to mark specific areas during resection on both the specimen side and in the patient. This allows a much more accurate interpretation of the specimen regarding the orientation and potential areas of concern. Marking in the patient facilitates communication with a radiation oncologist about specific areas of concern that may need to be addressed. Clear communication with pathologists about the orientation of the specimen is needed to accurately define resection margins and areas to target with adjuvant radiation [5].

Conclusion

Familiarity with the principles of the procedure, a precise preoperative evaluation, definitive surgical planning, and careful operation are required for successful VATS thymectomy.

Conflict of interest

No potential conflict of interest relevant to this article was reported.

ORCID

In Kyu Park: <https://orcid.org/0000-0003-3550-5554>

References

1. Girard N, Ruffini E, Marx A, Faivre-Finn C, Peters S; ESMO Guidelines Committee. *Thymic epithelial tumours: ESMO clinical practice guidelines for diagnosis, treatment and follow-up*. *Ann Oncol* 2015; 26 Suppl 5:v40-55.
2. Narm KS, Lee CY, Do YW, et al. *Limited thymectomy as a potential alternative treatment option for early-stage thymoma: a multi-institutional propensity-matched study*. *Lung Cancer* 2016;101:22-7.
3. Jaretzki A 3rd. *Thymectomy for myasthenia gravis: analysis of controversies: patient management*. *Neurologist* 2003;9:77-92.
4. Toker A, Sonett J, Zielinski M, Rea F, Tomulescu V, Detterbeck FC. *Standard terms, definitions, and policies for minimally invasive resection of thymoma*. *J Thorac Oncol* 2011;6(7 Suppl 3):S1739-42.
5. Detterbeck FC, Moran C, Huang J, et al. *Which way is up?: policies and procedures for surgeons and pathologists regarding resection specimens of thymic malignancy*. *J Thorac Oncol* 2011;6(7 Suppl 3):S1730-8.
6. Liu Z, Yang R, Sun Y. *Nonintubated uniportal thoracoscopic thymectomy with laryngeal mask*. *Thorac Cardiovasc Surg* 2020;68:450-6.
7. Bleetman D, West D, Teh E, Internullo E. *Video-assisted thoracoscopic thymectomy*. *Ann Cardiothorac Surg* 2015;4:556-7.
8. Nakagiri T, Inoue M, Shintani Y, et al. *Improved procedures and comparative results for video-assisted thoracoscopic extended thymectomy for myasthenia gravis*. *Surg Endosc* 2015;29:2859-65.
9. Ooi A, Sibayan M. *Uniportal video assisted thoracoscopic surgery thymectomy (right approach)*. *J Vis Surg* 2016;2:13.
10. Ooi A, Qiang F. *Uniportal video assisted thoracoscopic surgery thymectomy (left approach)*. *J Vis Surg* 2016;2:12.
11. Hwang Y, Park IK, Park S, Kim ER, Kang CH, Kim YT. *Lymph node dissection in thymic malignancies: implication of the ITMIG lymph node map, TNM stage classification, and recommendations*. *J Thorac Oncol* 2016;11:108-14.