



# Diffuse cerebral microbleeds in a young adult with Down syndrome

Eun Hee Sohn, Ae Young Lee

Department of Neurology, Chungnam National University Hospital, Daejeon, Korea

**Key words:** Down syndrome; Cerebral amyloid angiopathy; Cerebral microbleed; Magnetic resonance imaging

**Received:** October 26, 2020

**Revised:** March 12, 2021

**Accepted:** March 20, 2021

## Correspondence to

### Eun Hee Sohn

Department of Neurology, Chungnam National University Hospital, 282 Munhwa-ro, Jung-gu, Daejeon 35015, Korea  
Tel: +82-42-280-7882  
Fax: +82-42-252-8654  
E-mail: seh337@daum.net

## ORCID

### Eun Hee Sohn

<https://orcid.org/0000-0001-5610-7606>

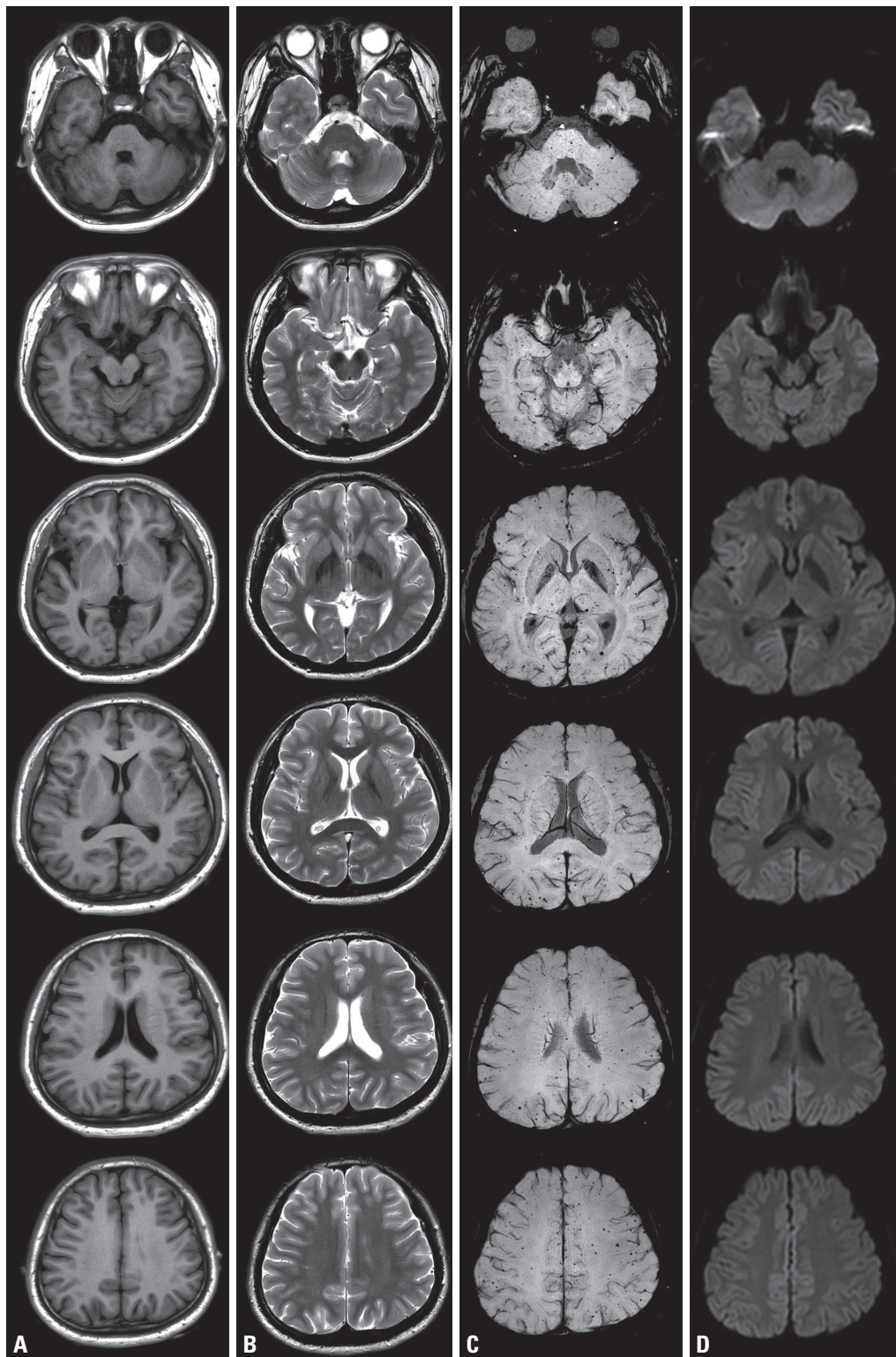
### Ae Young Lee

<https://orcid.org/0000-0001-9790-0838>

A 25-year-old male with Down syndrome (DS) [46, XY, der (13;14), +21] underwent brain magnetic resonance imaging (MRI) due to drop attacks. He had mental retardation from childhood (IQ < 50) but no subsequent cognitive decline. Consciousness was preserved during each attack and he could walk again 5 minutes later. Brain MRI showed numerous tiny microbleeds in the lobar area (n = 349), infratentorial area (n = 59), and deep regions (n = 28) without superficial hemosiderosis or white-matter lesions (Fig. 1), which would be related to cerebral amyloid angiopathy (CAA).

People with DS have a higher risk of developing Alzheimer's disease (AD), which is thought to be primarily due to the overexpression of amyloid precursor protein.<sup>1</sup> Trisomy of chromosome 21 also leads to increased cerebral  $\beta$ -amyloid accumulation that might manifest as CAA. CAA has been observed at significantly higher frequencies in patients with DS and AD (DSAD) than in those with sporadic AD and controls.<sup>1,2</sup> The number and distribution of microbleeds and CAA increased with age in DS.<sup>1,2</sup> However, these studies used pathological analyses to confirm CAA in autopsy cases, and the mean age of patients was around 50 years. Therefore, they are limited in their ability to assess younger patients with DS. Carmona-Iragui et al.<sup>3</sup> found CAA in 13% and 31% of patients with cognitively unimpaired DS (mean age = 39.6 years) and DSAD (mean age = 56.2 years), compared with 4% of healthy controls. Those authors used susceptibility-weighted imaging (SWI) to define CAA, but the subjects were older than the present case. Schoeppe et al.<sup>4</sup> reported early-onset CAA in 12 pediatric patients with DS (mean age = 5.0 years), however the maximum counts of microbleeds was less than 30.

The present patient was younger than those in previous reports<sup>1-3</sup> and showed more diffuse and numerous microbleeds.<sup>1-4</sup> Microbleeds could be more frequent than expected in younger patients with DS, and newer MRI techniques such as SWI can be useful to properly evaluate brain abnormalities in DS.



**Fig. 1.** Brain magnetic resonance imaging showed diffuse multiple microbleeds. There was no cortical or hippocampal atrophy on T1-weighted imaging (A) and no parenchymal lesion on T2-weighted imaging (B). Susceptibility-weighted imaging revealed multiple microbleeds in the cortical and cortical-subcortical areas (C). Diffusion restriction was not observed in these lesions (D).

### Conflicts of Interest

The authors declare no conflicts of interest relevant to this article.

### REFERENCES

1. Head E, Phelan MJ, Doran E, Kim RC, Poon WW, Schmitt FA, et al. Cerebrovascular pathology in Down syndrome and Alzheimer disease. *Acta Neuropathol Commun* 2017;5:93.
2. Helman AM, Siever M, McCarty KL, Lott IT, Doran E, Abner EL, et al. Microbleeds and cerebral amyloid angiopathy in the brains of people with Down syndrome with Alzheimer's disease. *J Alzheimers Dis* 2019;67:103-112.
3. Carmona-Iragui M, Balasa M, Benejam B, Alcolea D, Fernández S, Videla L, et al. Cerebral amyloid angiopathy in Down syndrome and sporadic and autosomal-dominant Alzheimer's disease. *Alzheimers Dement* 2017;13:1251-1260.
4. Schoeppe F, Rossi A, Levin J, Reiser M, Stoecklein S, Ertl-Wagner B. Increased cerebral microbleeds and cortical superficial siderosis in pediatric patients with Down syndrome. *Eur J Paediatr Neurol* 2019;23:158-164.