



# Surgical prevention of terminal neuroma and phantom limb pain: a literature review

Ronald N. Bogdasarian, Steven B. Cai, Bao Ngoc N. Tran, Ashley Ignatiuk, Edward S. Lee

*Division of Plastic and Reconstructive Surgery, Department of Surgery, Rutgers New Jersey Medical School, Newark, NJ, USA*

The incidence of extremity amputation is estimated at about 200,000 cases annually. Over 25% of patients suffer from terminal neuroma or phantom limb pain (TNPLP), resulting in pain, inability to wear a prosthetic device, and lost work. Once TNPLP develops, there is no definitive cure. Therefore, there has been an emerging focus on TNPLP prevention. We examined the current literature on TNPLP prevention in patients undergoing extremity amputation. A literature review was performed using Ovid Medline, Cochrane Collaboration Library, and Google Scholar to identify all original studies that addressed surgical prophylaxis against TNPLP. The search was conducted using both Medical Subject Headings and free-text using the terms "phantom limb pain," "amputation neuroma," and "surgical prevention of amputation neuroma." Fifteen studies met the inclusion criteria, including six prospective trials, two comprehensive literature reviews, four retrospective chart reviews, and three case series/technique reviews. Five techniques were identified, and each was incorporated into a target-based classification system. A small but growing body of literature exists regarding the surgical prevention of TNPLP. Targeted muscle reinnervation (TMR), a form of physiologic target reassignment, has the greatest momentum in the academic surgical community, with multiple recent prospective studies demonstrating superior prevention of TNPLP. Neurotomy and transposition with implantation are supported by less robust evidence, but merit future study as alternatives to TMR.

**Keywords** Terminal neuroma / Phantom limb pain / Surgical prevention of phantom limb pain / Targeted muscle reinnervation / Targeted nerve implantation

**Correspondence:** Edward S. Lee  
Division of Plastic Surgery, Rutgers  
New Jersey Medical School, 140  
Bergen Street, Suite E1620, Newark,  
NJ 07103, USA  
Tel: +1-973-972-5377  
Fax: +1-973-972-8268  
E-mail: leee9@njms.rutgers.edu

Received: October 27, 2020 • Revised: January 12, 2021 • Accepted: February 8, 2021  
pISSN: 2234-6163 • eISSN: 2234-6171 • <https://doi.org/10.5999/aps.2020.02180> • Arch Plast Surg 2021;48:310-322

## INTRODUCTION

The incidence of extremity amputation is estimated at 200,000 cases annually [1,2]. Of these, over 25% suffer from terminal neuroma or phantom limb pain (TNPLP), resulting in intractable pain, inability to wear a prosthetic device, and lost work [3,4]. Due to the significant disability generated by TNPLP, it is an area of growing scientific interest and investigation.

Despite a large body of literature on the management of estab-

lished TNPLP, treatment outcomes remain unpredictable [4-28]. A convincing body of neuroscience literature supports the concept of cortical reorganization and the imprinting of peripheral pain onto the central pain centers [29-47]. This central maladaptation may explain the unpredictability of peripheral treatment of established TNPLP. The clinical and basic science data support a transition in approach from the treatment of established TNPLP to its prevention.

Both non-surgical and surgical preventative approaches have

been explored. The results of pharmacological and physical therapy strategies for the prevention of TNPLP are unfortunately disappointing [27,48-65]. On the contrary, though small in number, TNPLP surgical prevention strategies have shown great success.

The purpose of this literature review is to evaluate the current body of literature on surgical techniques for the prevention of TNPLP in patients undergoing extremity amputation, and secondarily to propose a new target-based classification system for the surgical prevention of TNPLP.

## METHODS

### Search strategy

An online search was performed using Ovid Medline, Cochrane Collaboration Library, and Google Scholar to identify all original articles that addressed surgical prophylaxis against TNPLP. The following search terms were used: “phantom limb pain,” “amputation neuroma,” and “surgical prevention of amputation neuroma.” The search was limited to articles in English from inception to 2019. Studies regarding non-surgical strategies, animal studies, or surgical strategies for the treatment of established neuroma or phantom limb pain were excluded. After removal of all duplications, citations from all three search engines were subjected to title and abstract screening by two independent reviewers (RNB and SBC). The full-text articles of studies that met the inclusion criteria were subsequently obtained and reviewed independently by two reviewers. Disagreement in data collection was resolved by consensus with a third evaluator (BNNT).

### Data collection

The final list of studies was independently evaluated by two independent reviewers (RNB and SBC) and the following variables were extracted: article identifiers, technique category, purpose, design, sample size, analysis techniques, quantitative results, strengths, and limitations. The original two researchers independently reviewed each article and compiled their own tables. These were then combined and submitted to the principal investigator for final review.

### Classification of techniques

A recent literature review introduced a classification system for surgical prophylaxis against TNPLP, according to which techniques are divided into the categories of end closure, transposition with implantation, neurorrhaphy, and alternate target reinnervation [11]. We proposed the addition of a new category, preservation of continuity, and subsequently re-categorized these approaches based on the target condition to ensure con-

sistent terminology throughout the review. We opted to rename “alternate target reinnervation” as “targeted muscle reinnervation” due to the increasing prevalence of the latter term in the literature. The proposed target-based classification system, which is shown in Fig. 1 and demonstrated in Fig. 2, includes the target deficient, target reassignment, and target in continuity techniques.

### Target deficient

In this category, the severed nerve is not coapted to another nerve. Rather, the severed nerve ending is closed off or buried. Transposition with implantation is a common strategy in which terminal nerves are buried into muscle, bone, or fascia so that their nerve endings grow into stable, deep structures rather than exposed pain receptors in the skin [11]. The end closure technique refers to manipulation of the epineurium to enclose the nerve’s fascicles.

### Target reassignment

In target reassignment, a severed nerve is coapted to a new nerve to provide natural ingrowth within a nerve sheath. This can be physiologic or non-physiologic, as described below.

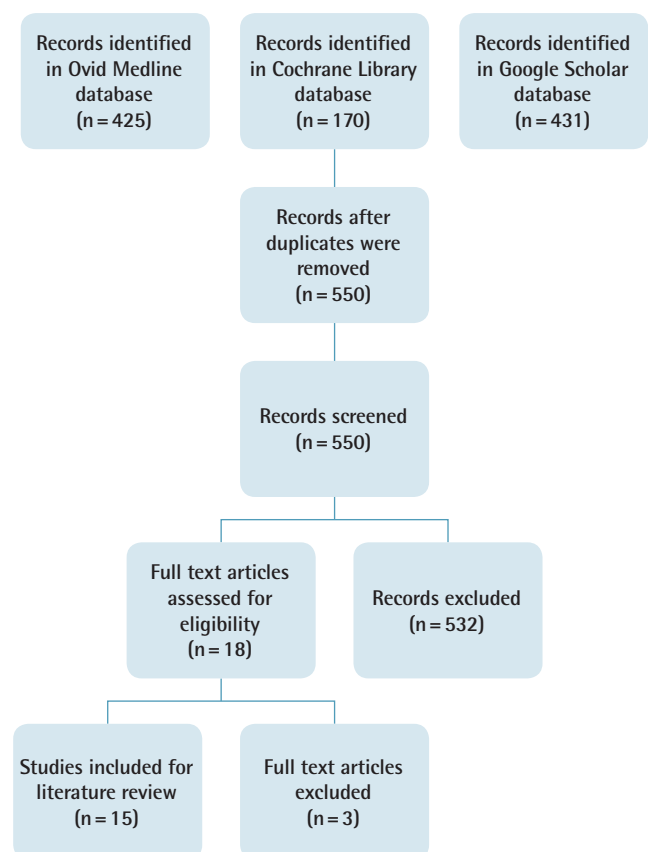
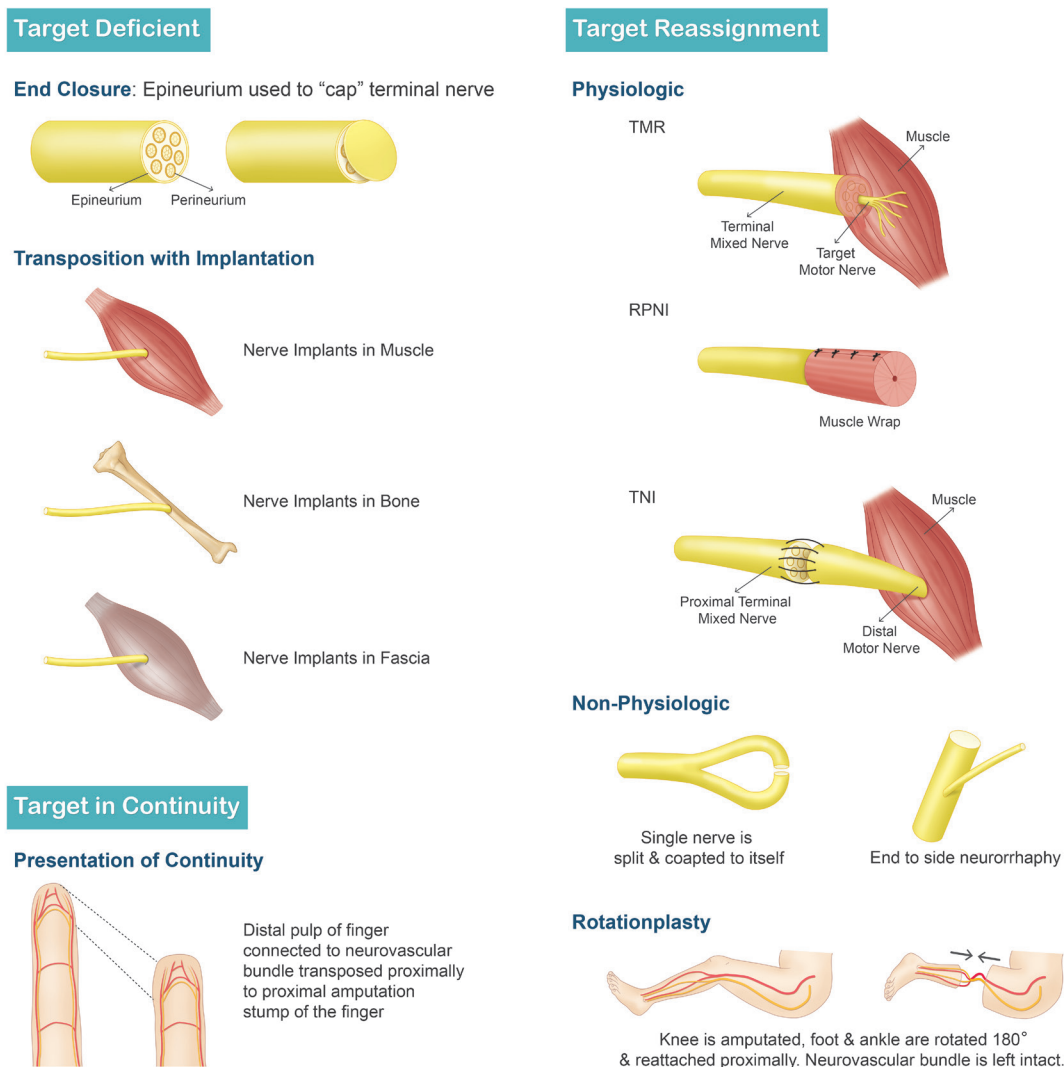


Fig. 1. Flow diagram.



**Fig. 2.** Schematic of techniques. TMR, targeted muscle reinnervation; RPNI, regenerative peripheral nerve interface; TNI, targeted nerve implantation.

In physiologic target reassignment, the proximal severed nerve is coapted to a distal nerve attached to an end organ with its normal peripheral nerve endings. This theoretically provides the severed nerve with a normal end organ to grow into, reducing the changes of TNPLP.

The most popular version of this technique is known as targeted muscle reinnervation (TMR). TMR is the coaptation of proximal, terminal mixed nerves to distal, end motor nerves, providing a distal target for regenerating terminal axons. Notably, the distal, end motor nerve, once transected, intrinsically leads into a denervated segment of muscle, which is posited to attract physiologic nerve ingrowth into the muscle. TMR was developed for the purpose of creating functional electromyogram signals for integrated, controllable prosthetic devices [6,28]. Similarly, targeted nerve implantation (TNI) is the coaptation of proximal, terminal mixed nerves into distal motor

nerves solely for the purpose of neuroma prevention [15].

An exception to the above definition is the regenerative peripheral nerve interface (RPNI) technique. In RPNI, a severed nerve is implanted directly into a non-vascularized muscle graft. This denervated muscle graft provides the severed nerve with an end organ to grow into in a physiologically natural way [21,66]. This theoretically reduces the risk of TNPLP. Like TMR, this reinnervation has been demonstrated by electromyogram signals.

In non-physiologic target reassignment, two proximal severed nerves are coapted, or a single nerve is split and coapted to itself. While these techniques provide a nerve sheath for axon ingrowth, they do not lead to a physiologic, distal end organ. These techniques are termed neurorrhaphy. Centro-central union (CCU) is an analogous term commonly found in the literature [5,67].

**Target in continuity**

These techniques can only be utilized when intermediate extremity components are amputated, while the proximal and distal tissues are preserved. Target in continuity techniques preserve the continuity of nerves and blood vessels to the terminal end organs, so that the amputation defect is reconstructed by the intact, distal parts. This category includes preservation of continuity, rotationplasty, and “spare parts” free tissue transfer.

Preservation of continuity is most frequently described for interphalangeal joint amputations of the digits. In this technique, the distal pulp, connected to the neurovascular bundles, is transposed proximally and sewn to the proximal amputation stump after removal of the intervening tissues. Thus, the wound is reconstructed with robust, vascularized, and innervated tissue. In this technique, the proper digital nerves are never severed; theoretically, there is no opportunity for neuroma formation [68,69].

Rotationplasty of the lower limb is a procedure in which the knee is amputated, and the foot and ankle are rotated 180° and reattached proximally. The tibia is fixated to the femur so that the reversed ankle joint acts as a pseudo-knee, allowing the transfer of power through a specialized prosthetic device.

Another strategy is the use of “spare parts,” or a fillet flap to cover an amputated part. This technique may be used in the setting of trauma, where only some of the distal tissues are viable and useful for reconstruction—usually to preserve the length of the traumatized extremity. The distal tissues are dissected, maintaining their connections to arteries and veins. This fillet flap is transferred to the wound and the blood vessels are then anastomosed. The nerves can be coapted surgically to prevent future neuropathic wounds and, theoretically, to prevent TNPLP.

**RESULTS**

The Ovid Medline search returned 425 PubMed-indexed articles, from which only 10 articles met the inclusion criteria. The Cochrane Library database search produced 170 articles. No Cochrane Reviews on the topic exist and none of the articles met the inclusion criteria. The Google Scholar search produced 431 articles, from which one article met the inclusion criteria. There were four other articles that were found by reference searching. A total of 15 articles met the inclusion criteria and are summarized in Table 1.

There was one study on the target deficient technique (end closure,  $n = 1$ ), 12 studies on target reassignment (physiologic TMR,  $n = 8$ ; RPNI,  $n = 1$ ; TNI,  $n = 0$ ; non-physiologic neuroorrhaphy/CCU,  $n = 3$ ), and two studies on target continuity (preservation of continuity,  $n = 2$ ; rotationplasty,  $n = 0$ ; fillet flap,  $n = 0$ ). There were six prospective trials, two comprehen-

sive literature reviews, four retrospective chart reviews, and three case series/technique reviews.

**Target deficient**

This literature review identified no studies evaluating the use of transposition with implantation in the prophylactic setting. A single article by Yuksel et al. [70] testing the end closure technique met the inclusion criteria. Yuksel et al. performed a prospective, randomized clinical trial including 23 patients and 48 nerves to compare epineural ligatures, flaps, and grafts for the prevention of amputation stump neuroma. The Tinel sign was used to elicit pain, which was recorded on a subjective 10-point visual analog scale for pain. The grafts, applied by excising a piece of epineurium and suturing it over the terminal nerve, demonstrated the greatest reduction in pain, with a pain score of 2.06 compared for 5.18 for ligatures and 4.25 for flaps ( $P < 0.05$ ). In summary, this study utilized the residual epineurium in three different ways and subjectively compared the prevention of neuroma formation. While grafts performed best, none of the techniques demonstrated excellent control [70]. This study had several limitations, including heterogeneous amputation causes, no clear statement of whether the study was blinded, the use of a subjective pain scale, and no histological confirmation of results.

**Target reassignment****Non-physiologic target reassignment**

This review identified three studies evaluating neuroorrhaphy or CCU in the preventative setting. A nonrandomized, nonblinded, noncomparative prospective cohort study by Gorkisch et al. [9] in 1984 examined the efficacy of CCU for the prevention of hand neuroma. This group reported strong, albeit subjective results of this technique, with only one of 30 patients returning with clinical neuroma over a 4-year follow-up period.

Belcher and Pandya (2002) [67] performed a prospective, randomized, double-blinded clinical trial comparing CCU to simple transection in digital nerves. While half of the patients were lost to follow-up, objective tenderness measures demonstrated significant superiority of CCU ( $P < 0.02$ ).

Economides et al. (2016) [71] performed a small, prospective pilot study comparing tibial and common peroneal neuroorrhaphy with collagen wrapping to nerve transection. This study demonstrated the superiority of CCU in multiple subjective and objective outcomes including the Tinel sign ( $P = 0.03$ ) and ambulation with a prosthetic device ( $P = 0.01$ ).

**Physiologic target reassignment**

There were nine articles on physiologic target reassignment techniques, with TMR being the most prominent area of study

**Table 1.** Summary of articles meeting the inclusion criteria on the surgical prevention of terminal neuroma and phantom limb pain

Author	Category/Technique	Purpose	Design	Sample size	Analysis techniques	Quantitative results	Strengths	Limitations
Yuksel 1997 [70]	Target deficient/End closure	To compare epineural ligatures, flaps and grafts for the prevention of amputation stump neuromas	Prospective, randomized clinical trial	23 Patients, 48 nerves	Tinel's sign used to elicit pain, recorded on a subjective 10-point VAS for pain. ANOVA	Pain scores 0-10: Ligatures 5.18 Flaps 4.25 Grafts 2.06 Grafts resulted in significantly less neuroma pain P < 0.05	Single surgeon, randomized, varied techniques in single patients. > 6 Months follow up	Heterogeneous amputation causes, unclear if blinded, subjective pain scale
Gorkisch 1984 [9]	Target reassignment: non-physiologic/Neurorrhaphy	To examine the efficacy of centro-central nerve union for the prevention of hand neuromas	Prospective, nonrandomized, nonblinded cohort	30 Patients	Physical examination, subjective reports	Only 1 of 30 patients returned with clinical neuroma over 4 years follow up.	Prospective	No statistical analysis or raw data presented. Selection bias, nonrandomized, nonblinded, assessor bias
Belcher 2000 [67]	Target reassignment: non-physiologic/Neurorrhaphy	To compare direct digital nerve CCU to simple nerve transection (control) in finger amputations	Prospective randomized double-blinded clinical trial	31 Digits (control: 16, CCU: 15)	Subjective questionnaire. Objective S2PD, Dolorimeter, grip strength. Students t-test, Mann-Whitney test	Subjective sensation better in control than CCU (P < 0.02). Objective tenderness better in CCU than control (P < 0.001). Grip strength equal.	Prospective, randomized, objective measures, double-blinded. 2 Years follow up	Transfer bias (half lost to follow up)
Economides 2016 [71]	Target reassignment: non-physiologic/Neurorrhaphy	To propose tibial and common peroneal nerve coaptation at the time of amputation as means to prevent TNPLP	Prospective cohort	Coaptation cohort: 6 Traction neurectomy control: 11	VAS, neuropathic pain medication use, neuroma formation, presence of phantom limb pain, prosthetic tolerance, and ambulatory status; 2-tailed, unpaired t-test and chi square test for data containing continuous and categorical variables	6 Months: VAS scores (0.75 vs. 5.6; P = 0.02) as well as neuroma (0% vs. 54.5%; P = 0.03) and phantom pain (0% vs. 63.6%; P = 0.01) remained lower among patients who underwent coaptation. At follow-up, 67% of coaptation patients were ambulating with a prosthesis vs. 9% of neurectomy patients (P = 0.01)	Prospective	No disclosure of randomization, blindness, patient demographics comparison or number of surgeons involved
Pet 2014 [15]	Target reassignment: physiologic/Targeted nerve implantation	To investigate if TNI prevents neuroma formation in acute traumatic amputation	Retrospective chart review	12 Patients	Chart review for palpable neuroma pain	11 of 12 patients were free of palpable neuroma pain	> 8 Months follow up	Retrospective, nonrandomized, subjective pain data, transfer bias, selection bias, assessor bias
Souza 2014 [19]	Target reassignment: physiologic/Targeted muscle reinnervation	To evaluate the effect of TMR on residual neuroma pain	Retrospective chart review	11 Without neuroma; 15 with established neuroma	Chart review for complete resolution of pain and fit with TMR-controlled prosthesis	None of the 11 patients who presented without neuroma developed a neuroma after TMR	> 6 Months follow up	Retrospective. Neuroma prevention not a primary objective of the study. TMR primarily performed for control of upper extremity prosthetics, not neuroma prevention. No objective pain scale

(Continued to the next page)

**Table 1.** Continued

Author	Category/ Technique	Purpose	Design	Sample size	Analysis techniques	Quantitative results	Strengths	Limitations
Bowen 2017 [6]	Target reassignment: physiologic/ Targeted muscle reinnervation	To show that TMR, alone and in conjunction with other methods, is a reliable treatment for terminal neuroma and phantom limb pain	Literature review and presentation of experience	20 Patients	Not disclosed	Not disclosed	Well organized, thorough	No disclosure of article selection protocol in primary publication, prevention of neuromas or phantom limb pain was not purpose of review
Ives 2017 [11]	Target reassignment: physiologic/ Targeted muscle reinnervation	To review the current literature on the treatment of terminal neuromas	Comprehensive literature review	98 Articles cited	4 Treatment categories formulated with report and interpretation of data	4 Categories include epineural closure; nerve transposition with implantation; neuroorrhaphy, and alternate target reinnervation. Minimal quantitative evidence regarding prevention given	Well organized, thorough review	No disclosure of article selection protocol in primary publication, prevention of neuromas or phantom limb pain was not purpose of review
Kuiken 2017 [72]	Target reassignment: physiologic/ Targeted muscle reinnervation	To present the technique of TMR in upper and lower extremity amputations	Technique presentation	100 Patients	Presentation of methods, experience and literature	1 of 100 patients who underwent TMR were re-explored to resect a neuroma.	Well organized, adhere to strong surgical principles	Neuroma presentation a secondary topic, no statistical analysis, minimal presentation of raw data, assessor bias
Alexander 2019 [73]	Target reassignment: physiologic/ Targeted muscle reinnervation	To assess TNPLP specifically in patients who undergo oncologic amputation	Single institution cohort study	27 Patients underwent oncologic amputation at a single institution and were compared to 58 patients treated at other institutions	PROMIS looking at pain intensity, pain behavior, and pain interference	Mean differences in PROMIS scores for TNPLP were 5.855 (P=0.15), 5.896 (P=0.033), 7.435 (P=0.011) for pain intensity, pain behavior and pain interference, respectively. Mean differences in PROMIS scores for residual limb pain were 5.477 (P=0.031), 6.195 (P=0.028), 6.816 (P=0.014) for pain intensity, pain behavior and pain interference, respectively.	Prospective, utilization of standardized pain related measures	Nonrandomized, nonblinded, multimodal approach to postoperative pain control could a confounder, of 27 patients who underwent TMR, only 15 had follow up greater than 1 year despite median follow-up of 16 months
Bowen 2019 [74]	Target reassignment: physiologic/ Targeted muscle reinnervation	To present results of TMR in BKA as a means of preventing TNPLP	Case series	22 Patients (18 primary, 4 secondary)	Physical exam, subjective patient reporting	72% of the primary TMR cohort experience phantom limb pain in the first month, with a decline to 19% at 3 months, and 13% at 6 months.	1 Year follow up	Nonrandomized, nonblinded, data specific to BKA

(Continued to the next page)

**Table 1.** Continued

Author	Category/ Technique	Purpose	Design	Sample size	Analysis techniques	Quantitative results	Strengths	Limitations
Valerio 2019 [75]	Target reassignment: physiologic/ Targeted muscle reinnervation	To assess if TMR at the time of amputation decreases incidence and severity of TNPLP	Multi-institutional cohort	51 Patients compared with 438 major limb amputees	11 NRS and PROMIS looking at pain, intensity, behavior, and interference	TMR showed lower median PROMIS t-scores for TNPLP with pain behavior ( $P < 0.001$ ), pain intensity ( $P < 0.001$ ) and pain interference ( $P < 0.001$ ). A similar pattern was seen with residual pain in regards to pain behavior ( $P < 0.001$ ), pain intensity ( $P < 0.001$ ) and pain interference ( $P < 0.001$ ).	Prospective, utilization of standardized pain related measures	Non-randomized, nonblinded, referrals for amputee group at discretion of surgical team performing amputation, 3-month minimum follow-up time
Kubiak 2019 [66]	Target reassignment: physiologic/ RPNI	To present results of creation of RPNI as a means of preventing TNPLP and neuromas	Retrospective	45 Patients underwent RPNI matched to 45 control patients selected from a pool of 178	Documentation of physical exam findings and patient reporting. Fischer exact test	No symptomatic neuromas noted in the intervention group (0% vs. 13.3%, $P = 0.026$ ). There was a reduced incidence of TNPLP in the intervention group (51.1% vs. 91.1%, $P < 0.0001$ ).	Long mean duration of follow-up on average of 1 year	Inconsistency chart documentation
De Smet 1996 [68]	Target in continuity/ Preservation of continuity	To present results of mid-finger amputation reconstructions with bi-neurovascular bundle pedicled volar pulp flaps	Case series	4 Patients	Personal experience and opinion	All 4 flaps survived with sensibility equal to preoperative	May be beneficial when indicated	Nonrandomized, nonblinded, small sample size, no comparison. minimal long-term follow-up, assessor bias
St-Laurent 1996 [69]	Target in continuity/ Preservation of continuity	To assess results of elective digital amputation with bipedicled neurovascular volar pulp flap	Case series	8 Patients, 9 amputations	Physical exam, patient reporting	7 Patients without painful neuroma, 1 patient with preoperative pain that did not improve postoperatively.	Prospective	Minimal long-term follow-up (range, 2–9 months), small sample size

ANOVA, analysis of variance; BKA, below-knee amputation; CCU, centro-central union (the direct union of two nerve endings, or the splitting and union of a single nerve ending); NRS, numerical rating scale; PROMIS, Patient-Reported Outcomes Measurement Information System; RPNI, regenerative peripheral nerve interface (reinnervated, non-vascularized muscle grafts); TMR, targeted muscle reinnervation (the coaptation of mixed nerves into terminal motor nerves for the purpose of creating functional electromyographic signals); TNI, targeted nerve implantation (coaptation of nerves solely for the purpose of neuroma prevention); TNPLP, terminal neuroma or phantom limb pain; S2PD, static two-point discrimination; VAS, visual analog scale.

( $n = 7$ ), followed by RPNI ( $n = 1$ ) and TNI ( $n = 1$ ).

Souza et al. (2014) [19] performed a retrospective chart review evaluating the effect of TMR on 11 patients without terminal neuroma and 15 patients with established terminal neuroma. None of the 11 patients who presented without neuroma developed a neuroma after TMR.

Bowen et al. (2017) [6] performed a comprehensive literature review and presentation of their experience with TMR as a reli-

able treatment for TNPLP. In a further prospective study in 2019 by Bowen et al. [74], 22 patients underwent TMR at the time of below-knee amputation and none of the patients reported neuroma pain postoperatively. While no numerical measures were provided, the authors disclosed that a clinical trial underway at their institution showed encouraging results of TMR for the prevention of TNPLP.

Ives et al. (2017) [11] performed a comprehensive literature

review on the treatment of terminal neuroma. These authors developed the categorization system that was modified for use in this review. Their study investigated TMR and RPNI. Both techniques were described as promising procedures to reduce the incidence of terminal neuroma.

Kuiken et al. (2017) [72] presented methods, experiences and a review of the literature on TMR in upper and lower extremity amputation. One hundred patients were analyzed, and only one was re-explored for neuroma resection. While neuroma prevention was a secondary topic and no statistical analysis was presented, the authors mentioned TMR as a promising, albeit experimental, technique for prevention of terminal neuroma.

Alexander et al. (2019) [73] performed a prospective study assessing TNPLP among patients who specifically underwent TMR with concurrent oncologic amputations. The study measured post-amputation pain using the Patient-Reported Outcomes Measurement Information System (PROMIS) and evaluated pain intensity, pain behavior, and pain interference. Although the article did not include specific surgical techniques, the authors referenced prior works [76-78]. The authors demonstrated that patients who underwent concurrent TMR had lower incidence rates of TNPLP and residual limb pain than patients who did not undergo concurrent TMR. The mean differences in PROMIS scores for TNPLP were 5.855 ( $P=0.15$ ), 5.896 ( $P=0.033$ ), and 7.435 ( $P=0.011$ ) for pain intensity, pain behavior, and pain interference, respectively. Meanwhile, the mean differences in PROMIS scores for residual limb pain were 5.477 ( $P=0.031$ ), 6.195 ( $P=0.028$ ), 6.816 ( $P=0.014$ ) for pain intensity, pain behavior, and pain interference, respectively.

Similarly, Valerio et al. (2019) [75] performed a prospective study assessing TNPLP in patients who underwent TMR at the time of amputation versus those who only had amputation using the PROMIS scoring system. Their study demonstrated that those who underwent concurrent TMR had significantly lower median PROMIS t-scores ( $P<0.001$ ) for TNPLP with regard to pain behavior, pain intensity, and pain interference. Likewise, a similar pattern was seen with residual pain in regard to pain behavior, pain intensity, and pain interference.

The only study examining the prevention of TNPLP using RPNI at the time of amputation was that by Kubiak et al. in 2019 [66]. The authors reported a significantly lower incidence of postoperative TNPLP and symptomatic neuroma in this retrospective study. Specifically, the authors found that six control patients developed symptomatic neuroma, while the TMR group had no symptomatic neuroma cases ( $P=0.026$ ). Furthermore, 41 control patients reported TNPLP, whereas only 23 patients in the TMR group did so ( $P<0.0001$ ).

Pet et al. (2014) [15] performed a retrospective chart review

to investigate whether TNI prevents neuroma formation in acute traumatic amputation. Eleven of 12 patients were free of palpable neuroma pain. Despite the retrospective nature of this study, the authors concluded that TNI is a promising technique for the prevention of terminal neuroma.

### Target in continuity

There were only two older studies (published in 1996) addressing the efficacy of preservation of continuity in TNPLP prevention [68,69]. The indications for this technique are limited to pathology that necessitates segmental amputation of a limb, but spares intervening neurovascular tissues. When the intermediate extremity is amputated and the proximal and distal ends are reattached with their neurovascular connections intact, the intact nerves should provide no opportunity for the development of TNPLP.

A case series of four patients who underwent neurovascular bundle pedicled volar pulp flaps for mid-finger amputation was presented by De Smet in 1996 [68]. All four flaps survived with sensibility equal to the preoperative status and no neuroma formation.

In the same year, St-Laurent and Duclos [69] presented a case series of eight patients who underwent the same procedure. Seven of those eight patients did not develop painful neuroma. The patient who reported pain suffered from preoperative pain that did not improve after surgery. We have termed this technique “preservation of continuity.”

## DISCUSSION

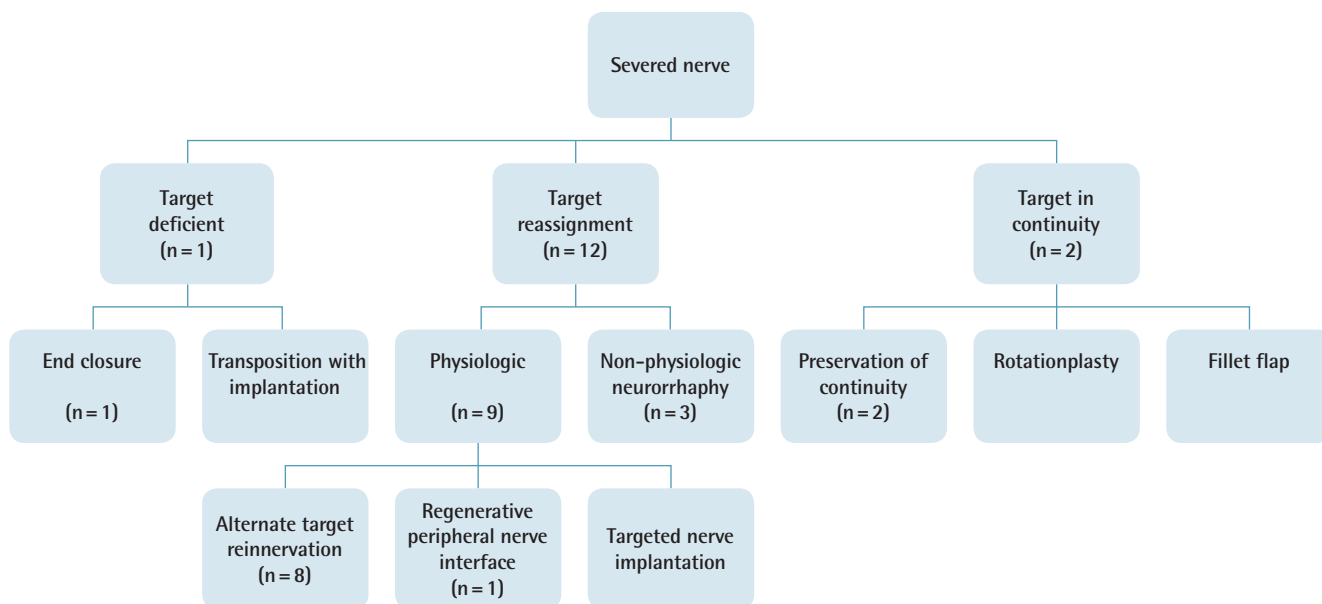
Post-amputation TNPLP results in significant patient disability and an economic burden on the healthcare system. Although a myriad of treatment strategies, both non-surgical and surgical, have been studied and implemented, their success has been limited. In contrast, the surgical prevention of TNPLP at the time of primary amputation, although it has not been well defined in the literature, has shown the greatest potential for reducing the incidence of this debilitating condition.

To our knowledge, this is the first literature review of the surgical prevention of TNPLP and the first attempt at formulating a target-based algorithm to describe the current trends (Fig. 3). Despite the paucity of high-quality literature on the surgical prevention of TNPLP, all studies have shown promising results and affirmed the need for a more vigorous investigation of this paradigm.

### Target deficient

End closure may provide a simpler technique; however, it does





**Fig. 3.** A target-based algorithm for terminal neuroma and phantom limb pain surgical prevention terminology.

not follow the theoretical trends towards providing an end organ for nerve ingrowth and does not have strong support from the literature. Transposition with implantation into bone, muscle, or fascia is a well described and widely utilized method for the treatment of established neuroma [7,79-83]. Surprisingly, this literature review identified no studies evaluating the use of transposition and implantation in the primary, preventative setting. Future studies on transposition with implantation would be a logical step towards the pursuit of an efficient, effective strategy to prevent TNPLP.

### Physiologic target reassignment

Within the last 6 years, a rapid proliferation in information on TMR, TNI, and RPNI reflects momentum in this area, especially TMR. Multiple high-quality respective cohort studies utilizing standardized pain scales (NRS [numerical rating scale] and PROMIS) have demonstrated statistically significant superiority of TMR and TNI for surgical prophylaxis against TNPLP over no nerve interventions [73-75].

### Non-physiologic target reassignment

According to our review, neurorrhaphy has demonstrated good outcomes and should be considered in most cases when more complex techniques are unable to be performed. While this technique has a moderate learning curve, it can be performed under loupe magnification and, once routine, may be performed quickly. Future prospective trials may confirm the results of the current, low-powered studies [9,67,71].

### Target in continuity

This review did not identify any studies evaluating the incidence of TNPLP after rotationplasty or fillet flap, both of which have been shown to improve quality of life, prosthetic usage, functional outcome, and emotional well-being in oncologic patients [84-95].

Our 15 studies spanned 3 decades, indicating plastic surgeons' early recognition of the debilitating impact of TNPLP on patient quality of life and, consequently, the need for prevention. Earlier studies emphasized end closure, preservation of continuity, and neurorrhaphy/CCU, whereas TMR has been the mainstay of interventions in the past 5 years. As expected, early studies were mainly case series, technique reviews, and retrospective reviews of single-surgeon experiences, whereas later studies were prospective trials involving multiple surgeons and sometimes institutions. The later trials also employed more standardized data reporting tools, as well as validated patient-centered variables such as the PROMIS score.

Our algorithm maintains previous terminology and organizes each strategy into target-based categories. This may help to guide future academic and clinical analyses of the topic. This target-based algorithm may also guide treatment based on each patient's individual anatomy and the nerve targets that the patient offers.

## CONCLUSIONS

In conclusion, this literature review demonstrates a small, yet growing body of literature on the surgical prophylaxis of TN-

PLP. The strongest body of literature favors the physiologic target reassignment techniques of TMR and TNI. Neuroorrhaphy and transposition with implantation are supported by less robust evidence, but merit future study as simpler alternatives.

## NOTES

### Conflict of interest

No potential conflict of interest relevant to this article was reported.

### Author contribution

Conceptualization: RN Bogdasarian, SB Cai, A Ignatiuk, ES Lee. Data curation: RN Bogdasarian, BNN Tran. Formal analysis: RN Bogdasarian, SB Cai, BNN Tran. Methodology: RN Bogdasarian, SB Cai, A Ignatiuk, ES Lee. Project administration: RN Bogdasarian, SB Cai. Visualization: RN Bogdasarian, SB Cai, BNN Tran. Writing - original draft: RN Bogdasarian. Writing - review & editing: RN Bogdasarian, BNN Tran.

### ORCID

Steven B. Cai <https://orcid.org/0000-0002-2522-3337>

Bao Ngoc N. Tran <https://orcid.org/0000-0003-4301-1407>

## REFERENCES

- Narres M, Kvitkina T, Claessen H, et al. Incidence of lower extremity amputations in the diabetic compared with the non-diabetic population: a systematic review. *PLoS One* 2017;12:e0182081.
- Bosmans JC, Geertzen JH, Post WJ, et al. Factors associated with phantom limb pain: a 31/2-year prospective study. *Clin Rehabil* 2010;24:444-53.
- Hanley MA, Jensen MP, Smith DG, et al. Preamputation pain and acute pain predict chronic pain after lower extremity amputation. *J Pain* 2007;8:102-9.
- Chen MC, Lee SS, Hsieh YL, et al. Influencing factors of outcome after lower-limb amputation: a five-year review in a plastic surgical department. *Ann Plast Surg* 2008;61:314-8.
- Barbera J, Albert-Pamplo R. Centrocetral anastomosis of the proximal nerve stump in the treatment of painful amputation neuromas of major nerves. *J Neurosurg* 1993;79:331-4.
- Bowen JB, Wee CE, Kalik J, et al. Targeted muscle reinnervation to improve pain, prosthetic tolerance, and bioprosthetic outcomes in the amputee. *Adv Wound Care (New Rochelle)* 2017;6:261-7.
- Dellon AL, Mackinnon SE, Pestronk A. Implantation of sensory nerve into muscle: preliminary clinical and experimental observations on neuroma formation. *Ann Plast Surg* 1984;12:30-40.
- Ducic I, Mesbahi AN, Attinger CE, et al. The role of peripheral nerve surgery in the treatment of chronic pain associated with amputation stumps. *Plast Reconstr Surg* 2008;121:908-14.
- Gorkisch K, Boese-Landgraf J, Vaubel E. Treatment and prevention of amputation neuromas in hand surgery. *Plast Reconstr Surg* 1984;73:293-9.
- Halbert J, Crotty M, Cameron ID. Evidence for the optimal management of acute and chronic phantom pain: a systematic review. *Clin J Pain* 2002;18:84-92.
- Ives GC, Kung TA, Nghiem BT, et al. Current state of the surgical treatment of terminal neuromas. *Neurosurgery* 2018;83:354-64.
- Martins RS, Siqueira MG, Heise CO, et al. Interdigital direct neuroorrhaphy for treatment of painful neuroma due to finger amputation. *Acta Neurochir (Wien)* 2015;157:667-71.
- Moesker AA, Karl HW, Trescot AM. Treatment of phantom limb pain by cryoneurolysis of the amputated nerve. *Pain Pract* 2014;14:52-6.
- Patrick J, Frank W, Theodora M, et al. The pedicled serratus anterior muscle wrap-around flap: a treatment option in the management of posttraumatic axillary neuroma and neuropathic pain. *Ann Plast Surg* 2010;65:170-3.
- Pet MA, Ko JH, Friedly JL, et al. Does targeted nerve implantation reduce neuroma pain in amputees? *Clin Orthop Relat Res* 2014;472:2991-3001.
- Pet MA, Ko JH, Friedly JL, et al. Traction neurectomy for treatment of painful residual limb neuroma in lower extremity amputees. *J Orthop Trauma* 2015;29:e321-5.
- Prantl L, Schreml S, Heine N, et al. Surgical treatment of chronic phantom limb sensation and limb pain after lower limb amputation. *Plast Reconstr Surg* 2006;118:1562-72.
- Slooff AC. Microsurgical possibilities in the treatment of peripheral pain. *Clin Neurol Neurosurg* 1977;80:107-11.
- Souza JM, Cheesborough JE, Ko JH, et al. Targeted muscle reinnervation: a novel approach to postamputation neuroma pain. *Clin Orthop Relat Res* 2014;472:2984-90.
- Swanson AB, Boeve NR, Lumsden RM. The prevention and treatment of amputation neuromata by silicone capping. *J Hand Surg Am* 1977;2:70-8.
- Woo SL, Kung TA, Brown DL, et al. Regenerative peripheral nerve interfaces for the treatment of postamputation neuroma pain: a pilot study. *Plast Reconstr Surg Glob Open* 2016;4:e1038.

22. Wood MR, Hunter GA, Millstein SG. The value of revision surgery after initial amputation of an upper or lower limb. *Prosthet Orthot Int* 1987;11:17-20.
23. Wood VE, Mudge MK. Treatment of neuromas about a major amputation stump. *J Hand Surg Am* 1987;12:302-6.
24. Goldstein SA, Sturim HS. Intraosseous nerve transposition for treatment of painful neuromas. *J Hand Surg Am* 1985; 10:270-4.
25. Jensen TS, Krebs B, Nielsen J, et al. Phantom limb, phantom pain and stump pain in amputees during the first 6 months following limb amputation. *Pain* 1983;17:243-56.
26. Jensen TS, Krebs B, Nielsen J, et al. Immediate and long-term phantom limb pain in amputees: incidence, clinical characteristics and relationship to pre-amputation limb pain. *Pain* 1985;21:267-78.
27. Nikolajsen L, Ilkjaer S, Jensen TS. Effect of preoperative extradural bupivacaine and morphine on stump sensation in lower limb amputees. *Br J Anaesth* 1998;81:348-54.
28. Mioton LM, Dumanian GA. Targeted muscle reinnervation and prosthetic rehabilitation after limb loss. *J Surg Oncol* 2018;118:807-14.
29. Andoh J, Milde C, Tsao JW, et al. Cortical plasticity as a basis of phantom limb pain: fact or fiction? *Neuroscience* 2018;387:85-91.
30. Dettmers C, Adler T, Rzanny R, et al. Increased excitability in the primary motor cortex and supplementary motor area in patients with phantom limb pain after upper limb amputation. *Neurosci Lett* 2001;307:109-12.
31. Flor H. Phantom-limb pain: characteristics, causes, and treatment. *Lancet Neurol* 2002;1:182-9.
32. Flor H. Cortical reorganisation and chronic pain: implications for rehabilitation. *J Rehabil Med* 2003;(41 Suppl): 66-72.
33. Flor H. Maladaptive plasticity, memory for pain and phantom limb pain: review and suggestions for new therapies. *Expert Rev Neurother* 2008;8:809-18.
34. Flor H, Birbaumer N. Phantom limb pain: cortical plasticity and novel therapeutic approaches. *Curr Opin Anaesthesiol* 2000;13:561-4.
35. Flor H, Diers M, Andoh J. The neural basis of phantom limb pain. *Trends Cogn Sci* 2013;17:307-8.
36. Flor H, Nikolajsen L, Staehelin Jensen T. Phantom limb pain: a case of maladaptive CNS plasticity? *Nat Rev Neurosci* 2006;7:873-81.
37. Foell J, Andoh J, Bekrater-Bodmann R, et al. Peripheral origin of phantom limb pain: is it all resolved? *Pain* 2014;155: 2205-6.
38. Grusser SM, Winter C, Muhlneckel W, et al. The relationship of perceptual phenomena and cortical reorganization in upper extremity amputees. *Neuroscience* 2001;102:263-72.
39. Karl A, Birbaumer N, Lutzenberger W, et al. Reorganization of motor and somatosensory cortex in upper extremity amputees with phantom limb pain. *J Neurosci* 2001;21:3609-18.
40. Knecht S, Henningsen H, Elbert T, et al. Cortical reorganization in human amputees and mislocalization of painful stimuli to the phantom limb. *Neurosci Lett* 1995;201:262-4.
41. Makin TR, Scholz J, Henderson Slater D, et al. Reassessing cortical reorganization in the primary sensorimotor cortex following arm amputation. *Brain* 2015;138(Pt 8):2140-6.
42. Montoya P, Ritter K, Huse E, et al. The cortical somatotopic map and phantom phenomena in subjects with congenital limb atrophy and traumatic amputees with phantom limb pain. *Eur J Neurosci* 1998;10:1095-102.
43. Oouchida Y, Sudo T, Inamura T, et al. Maladaptive change of body representation in the brain after damage to central or peripheral nervous system. *Neurosci Res* 2016;104:38-43.
44. Raffin E, Richard N, Giroux P, et al. Primary motor cortex changes after amputation correlate with phantom limb pain and the ability to move the phantom limb. *Neuroimage* 2016;130:134-44.
45. Reilly KT, Sirigu A. The motor cortex and its role in phantom limb phenomena. *Neuroscientist* 2008;14:195-202.
46. Wu CW, Kaas JH. The effects of long-standing limb loss on anatomical reorganization of the somatosensory afferents in the brainstem and spinal cord. *Somatosens Mot Res* 2002; 19:153-63.
47. Yanagisawa T, Fukuma R, Seymour B, et al. Induced sensorimotor brain plasticity controls pain in phantom limb patients. *Nat Commun* 2016;7:13209.
48. Andrae MH, Andrae DA. Local anaesthetics and regional anaesthesia for preventing chronic pain after surgery. *Cochrane Database Syst Rev* 2012;10:CD007105.
49. Borghi B, D'Addabbo M, White PF, et al. The use of prolonged peripheral neural blockade after lower extremity amputation: the effect on symptoms associated with phantom limb syndrome. *Anesth Analg* 2010;111:1308-15.
50. Enneking FK, Scarborough MT, Radson EA. Local anesthetic infusion through nerve sheath catheters for analgesia following upper extremity amputation. Clinical report. *Reg Anesth* 1997;22:351-6.
51. Finsen V, Persen L, Lovlien M, et al. Transcutaneous electrical nerve stimulation after major amputation. *J Bone Joint*

- Surg Br 1988;70:109-12.
52. Fisher A, Meller Y. Continuous postoperative regional analgesia by nerve sheath block for amputation surgery: a pilot study. *Anesth Analg* 1991;72:300-3.
  53. Grant AJ, Wood C. The effect of intra-neural local anaesthetic infusion on pain following major lower limb amputation. *Scott Med J* 2008;53:4-6.
  54. Hanling SR, Wallace SC, Hollenbeck KJ, et al. Preamputation mirror therapy may prevent development of phantom limb pain: a case series. *Anesth Analg* 2010;110:611-4.
  55. Hayes C, Armstrong-Brown A, Burstal R. Perioperative intravenous ketamine infusion for the prevention of persistent post-amputation pain: a randomized, controlled trial. *Anaesth Intensive Care* 2004;32:330-8.
  56. Jahangiri M, Jayatunga AP, Bradley JW, et al. Prevention of phantom pain after major lower limb amputation by epidural infusion of diamorphine, clonidine and bupivacaine. *Ann R Coll Surg Engl* 1994;76:324-6.
  57. Lambert Aw, Dashfield Ak, Cosgrove C, et al. Randomized prospective study comparing preoperative epidural and intraoperative perineural analgesia for the prevention of postoperative stump and phantom limb pain following major amputation. *Reg Anesth Pain Med* 2001;26:316-21.
  58. Madabhushi L, Reuben SS, Steinberg RB, et al. The efficacy of postoperative perineural infusion of bupivacaine and clonidine after lower extremity amputation in preventing phantom limb and stump pain. *J Clin Anesth* 2007;19:226-9.
  59. Morey TE, Giannoni J, Duncan E, et al. Nerve sheath catheter analgesia after amputation. *Clin Orthop Relat Res* 2002;(397):281-9.
  60. Mulvey MR, Bagnall AM, Johnson MI, et al. Transcutaneous electrical nerve stimulation (TENS) for phantom pain and stump pain following amputation in adults. *Cochrane Database Syst Rev* 2010;(5):CD007264.
  61. Ong BY, Arneja A, Ong EW. Effects of anesthesia on pain after lower-limb amputation. *J Clin Anesth* 2006;18:600-4.
  62. Pavy TJ, Doyle DL. Prevention of phantom limb pain by infusion of local anaesthetic into the sciatic nerve. *Anaesth Intensive Care* 1996;24:599-600.
  63. Pinzur MS, Garla PG, Pluth T, et al. Continuous postoperative infusion of a regional anesthetic after an amputation of the lower extremity. A randomized clinical trial. *J Bone Joint Surg Am* 1996;78:1501-5.
  64. Wilson JA, Nimmo AF, Fleetwood-Walker SM, et al. A randomised double blind trial of the effect of pre-emptive epidural ketamine on persistent pain after lower limb amputation. *Pain* 2008;135:108-18.
  65. Wu CL, Tella P, Staats PS, et al. Analgesic effects of intravenous lidocaine and morphine on postamputation pain: a randomized double-blind, active placebo-controlled, crossover trial. *Anesthesiology* 2002;96:841-8.
  66. Kubiak CA, Kemp SWP, Cederna PS, et al. Prophylactic regenerative peripheral nerve interfaces to prevent postamputation pain. *Plast Reconstr Surg* 2019;144:421e-430e.
  67. Belcher HJ, Pandya AN. Centro-central union for the prevention of neuroma formation after finger amputation. *J Hand Surg Br* 2000;25:154-9.
  68. De Smet L. Preventing neuroma formation in finger amputation. *Acta Orthop Belg* 1996;62:69-70.
  69. St-Laurent JY, Duclos L. Prevention of neuroma in elective digital amputations by utilization of neurovascular island flap. *Ann Chir Main Memb Super* 1996;15:50-4.
  70. Yuksel F, Kislaoglu E, Durak N, et al. Prevention of painful neuromas by epineural ligatures, flaps and grafts. *Br J Plast Surg* 1997;50:182-5.
  71. Economides JM, DeFazio MV, Attinger CE, et al. Prevention of painful neuroma and phantom limb pain after transfemoral amputations through concomitant nerve coaptation and collagen nerve wrapping. *Neurosurgery* 2016;79:508-13.
  72. Kuiken TA, Barlow AK, Hargrove L, et al. Targeted muscle reinnervation for the upper and lower extremity. *Tech Orthop* 2017;32:109-16.
  73. Alexander JH, Jordan SW, West JM, et al. Targeted muscle reinnervation in oncologic amputees: early experience of a novel institutional protocol. *J Surg Oncol* 2019;120:348-58.
  74. Bowen JB, Ruter D, Wee C, et al. Targeted muscle reinnervation technique in below-knee amputation. *Plast Reconstr Surg* 2019;143:309-12.
  75. Valerio IL, Dumanian GA, Jordan SW, et al. Preemptive treatment of phantom and residual limb pain with targeted muscle reinnervation at the time of major limb amputation. *J Am Coll Surg* 2019;228:217-26.
  76. Agnew SP, Schultz AE, Dumanian GA, et al. Targeted reinnervation in the transfemoral amputee: a preliminary study of surgical technique. *Plast Reconstr Surg* 2012;129:187-94.
  77. Gart MS, Souza JM, Dumanian GA. Targeted muscle reinnervation in the upper extremity amputee: a technical roadmap. *J Hand Surg Am* 2015;40:1877-88.
  78. Morgan EN, Kyle Potter B, Souza JM, et al. Targeted muscle reinnervation for transradial amputation: description of operative technique. *Tech Hand Up Extrem Surg* 2016;20:166-71.
  79. Prasetyono TO, Permatasari E, Soetrisno E. Implantation of nerve stump inside a vein and a muscle: comparing neuro-

- ma formation in rat. *Int Surg* 2014;99:807-11.
80. Lewin-Kowalik J, Marcol W, Kotulska K, et al. Prevention and management of painful neuroma. *Neurol Med Chir (Tokyo)* 2006;46:62-7.
  81. Low CK, Chew SH, Song IC, et al. Implantation of a nerve ending into a vein. *Clin Orthop Relat Res* 2000;(379):242-6.
  82. Otfinowski J, Pawelec A, Kaluza J. Implantation of peripheral neural stump into muscle and its effect on the development of posttraumatic neuroma. *Pol J Pathol* 1994;45:195-202.
  83. Zhang B, Guo Y, Liang Y. Experimental study on prevention and treatment of neuroma by implanting nerve stump into muscle. *Zhongguo Xiu Fu Chong Jian Wai Ke Za Zhi* 1997; 11:325-7.
  84. Kim PS, Ko JH, O'Shaughnessy KK, et al. The effects of targeted muscle reinnervation on neuromas in a rabbit rectus abdominis flap model. *J Hand Surg Am* 2012;37:1609-16.
  85. Ko JH, Kim PS, Smith DG. Targeted muscle reinnervation as a strategy for neuroma prevention. In: Kuiken TA, Schultz Feuser AE, Barlow AK, editors. *Targeted muscle reinnervation: a neural interface for artificial limbs (Series in Medical Physics and Biomedical Engineering)*. Boca Raton: Taylor & Francis; 2013. p. 45-66.
  86. Chen A, Yao J, Kuiken T, et al. Cortical motor activity and reorganization following upper-limb amputation and subsequent targeted reinnervation. *Neuroimage Clin* 2013;3:498-506.
  87. Gradl G, Postl LK, Lenze U, et al. Long-term functional outcome and quality of life following rotationplasty for treatment of malignant tumors. *BMC Musculoskelet Disord* 2015;16:262.
  88. Forni C, Gaudenzi N, Zoli M, et al. Living with rotationplasty: quality of life in rotationplasty patients from childhood to adulthood. *J Surg Oncol* 2012;105:331-6.
  89. Fuchs B, Kotajarvi BR, Kaufman KR, et al. Functional outcome of patients with rotationplasty about the knee. *Clin Orthop Relat Res* 2003;(415):52-8.
  90. Furtado S, Grimer RJ, Cool P, et al. Physical functioning, pain and quality of life after amputation for musculoskeletal tumours: a national survey. *Bone Joint J* 2015;97-B:1284-90.
  91. Hanlon M, Krajbich JI. Rotationplasty in skeletally immature patients: long-term followup results. *Clin Orthop Relat Res* 1999;(358):75-82.
  92. Mayerson JL. Living with rotationplasty: quality of life in rotationplasty patients from childhood to adulthood. *J Surg Oncol* 2012;105:743-4.
  93. Rodl RW, Pohlmann U, Gosheger G, et al. Rotationplasty: quality of life after 10 years in 22 patients. *Acta Orthop Scand* 2002;73:85-8.
  94. Veenstra KM, Sprangers MA, van der Eyken JW, et al. Quality of life in survivors with a Van Ness-Borggreve rotationplasty after bone tumour resection. *J Surg Oncol* 2000;73: 192-7.
  95. Ackman J, Altiok H, Flanagan A, et al. Long-term follow-up of Van Nes rotationplasty in patients with congenital proximal focal femoral deficiency. *Bone Joint J* 2013;95-B:192-8.