



# Effect of Saline Flush on the Enhancement of Vascular and Liver via Saphenous Vein for Abdominal CT in Dogs

Song Yeon Kim<sup>†</sup>  
Tae Sung Hwang<sup>†</sup>  
Soyon An  
Gunha Hwang  
Woohyun Go  
Jong Bong Lee  
Hee Chun Lee\*

Institute of Animal Medicine, College of Veterinary Medicine, Gyeongsang National University, Jinju 52828, Korea

<sup>†</sup>Song Yeon Kim and Tae Sung Hwang contributed equally to this work.

\*Correspondence: [lhc@gnu.ac.kr](mailto:lhc@gnu.ac.kr)

## ORCID

Song Yeon Kim:  
<https://orcid.org/0000-0002-2465-9008>  
Tae Sung Hwang:  
<https://orcid.org/0000-0001-6730-6061>  
Soyon An:  
<https://orcid.org/0000-0002-9994-8760>  
Gunha Hwang:  
<https://orcid.org/0000-0002-1805-9137>  
Woohyun Go:  
<https://orcid.org/0000-0002-5119-6707>  
Jong Bong Lee:  
<https://orcid.org/0000-0003-4614-2752>  
Hee Chun Lee:  
<https://orcid.org/0000-0001-5936-9118>

Copyright © The Korean Society of Veterinary Clinics

**Abstract** The aim of this study was to evaluate the contrast effect if a saline flush following low-volume contrast medium bolus improves vascular and parenchymal enhancement using a saphenous vein in abdominal CT for small animals. Six clinically healthy beagle dogs underwent abdominal contrast-enhanced CT. They were divided into nine groups (each group, n = 6), according to the volume of contrast medium 1, 2, and 3 mL/kg, and volume of the saline solution 0, 5, and 10 mL. Dynamic CT scanning was performed at the hepatic hilum level. The maximum contrast enhancement, time to maximum enhancement, and time to equilibrium phase were calculated from the time attenuation curves. Mean attenuation values for all groups were measured in the aorta, portal vein, and liver. After contrast enhancement, grading of image quality regarding surrounding artifacts and evaluation of the hepatic hilum structures was performed. For comparison of the effect of the contrast material and saline solution doses, differences in mean attenuation values between the contrast medium 2 mL/kg without saline flush group and the remaining groups, and between contrast medium 3 mL/kg without saline flush group and the remaining groups, were analyzed for statistical significance. There were no significant differences between with and without saline flushing at the same contrast medium dose groups. There were no significant differences in peak values between the 3 mL/kg dose of contrast medium alone and the 2 mL/kg dose of contrast medium with saline solution flush. However, there was a significant difference in peak values between the 3 mL/kg dose of the contrast medium without the saline flush group and the 2 mL/kg dose of the contrast medium alone group. Grades of the artifacts were not significantly different in the saline flush regardless of the dose of the contrast medium. Using 2 mL/kg of contrast medium with saline solution flush resulted in similar liver parenchyma attenuation, compared with using 3 mL/kg of contrast medium without saline solution flush. In CT evaluation of hepatic parenchymal diseases, using 2 mL/kg of contrast medium with saline solution flush may yield decreased risk of contrast nephropathy and cost-saving.

**Key words** saphenous vein, saline flush, computed tomography, dog.

Received February 9, 2021 / Revised April 5, 2021 / Accepted May 28, 2021



This is an open access article distributed under the terms of the Creative Commons Attribution Non-Commercial License (<http://creativecommons.org/licenses/by-nc/4.0>) which permits unrestricted non-commercial use, distribution, and reproduction in any medium, provided the original work is properly cited.

## Introduction

It is generally agreed that bolus injection of intravenous contrast medium is advantageous with respect to increasing the visibility of hypervascular and hypovascular tumors, by maximizing the difference in enhancement between the organ parenchymal and tumor (3,4). Non-ionic contrast medium is preferable, because it is better tolerated by patients (10); also, extravasation of nonionic contrast material tends to cause less serious complications (5). Although routinely used non-ionic contrast medium have optimized contrast enhancement and scanning protocols, and their high cost forces the radiologists to search for ways further to reduce the contrast medium dose (20). Dose reduction is also advantageous in patients with renal insufficiency (20). However, a decrease of contrast medium dose in abdominal contrast-enhanced CT (CECT) results in a reduction of hepatic enhancement, which potentially reduces the detection of hypervascular or hypovascular hepatic diseases (8,16). Saline flushing avoids the pooling of contrast medium in the injection vein (18). Saline flushing reduces streak artifact, and theoretically decreases the total dose required to achieve satisfactory systemic vascular enhancement (18).

The cephalic vein is the commonly used and preferred the venous access site for the intravenous contrast material administration with saline solution (6). In some institutions, saphenous vein injection of contrast material has been tried to diminish the perivenous artifacts for CT of the thorax in humans (9). However, abdominal CECT using saphenous vein is not often used, because it can cause beam hardening and streak artifacts. When cephalic veins cannot be used due to forelimb trauma or other unavoidable circumstances, abdominal CECT using saphenous vein is sometimes necessary.

Since no studies have investigated the effect of saphenous vein on contrast enhancement with saline solution in dogs, the purpose of this study was to evaluate the contrast effect if a saline flush following low-volume contrast medium bolus improved vascular and parenchymal enhancement and reduced streak artifact using saphenous vein in abdominal CECT for dogs.

## Materials and Methods

### Animals

Study was carried out in a crossover method with the same six healthy dogs; four males and two females, 6-7 years old, and 9-16 kg. All experiments were approved by the Institutional Animal Care and Use Committee of Gyeongsang National University (GNU-150804-D0036). The dogs had a

withdrawal period of at least two weeks.

A 22 gauge intravenous catheter was placed into the saphenous vein immediately before injecting contrast medium in all examinations. A three-way stopcock was equipped to provide a system for automatic delivery and a saline solution flush syringe with an extension tube (tube volume, 8.72 mL; tube length, 1,200 mm).

Animals were premedicated with glycopyrrolate (Mobinul inj<sup>®</sup>, Myungmoon Pharm. Co., Ltd., Seoul, Korea; 0.01 mg/kg, subcutaneously). Anesthesia was induced with intravenous propofol (Provive inj<sup>®</sup>, Myungmoon Pharm. Co., Ltd., Seoul, Korea; 6 mg/kg, intravenously). General anesthesia was maintained with isoflurane (Ifran<sup>®</sup>, Hana Pharm. Co., Ltd., Kyonggi-Do, Korea) in oxygen (2 L/min) via endotracheal intubation.

### Injection protocols of contrast medium

The syringe filled with contrast material (Omnipaque 300<sup>®</sup>, 300 mgI/mL; GE Healthcare, Ireland) was mounted on an automated injector (CT 9000<sup>™</sup> ADV injector, Mallinckrodt, Germany), and another syringe filled with saline solution was mounted on hand with a 22-gauge intravenous catheter inserted into the saphenous vein. Contrast material flow rate was set at 1 mL/s. Immediately after completion of the non-ionic contrast medium injection, sterile isotonic 0.9% saline solution was injected at a bolus by hand. For each experiment, unwanted mixing of the two components was avoided. Contrast injection protocols were divided into 9 groups based on the combinations of 3 different volumes 1, 2, and 3 mL/kg of contrast dose and 3 different saline solution 0, 5, and 10 mL; S0 (contrast material 1 mL/kg, saline 0 mL), S5 (1 mL/kg, 5 mL), S10 (1 mL/kg, 10 mL), M0 (2 mL/kg, 0 mL), M5 (2 mL/kg, 5 mL), M10 (2 mL/kg, 10 mL), L0 (3 mL/kg, 0 mL), L5 (3 mL/kg, 5 mL), and L10 (3 mL/kg, 10 mL).

### CT protocol

All CT scans were obtained with a 2-channel multidetector CT (Somatom Emotion<sup>®</sup>; SIEMENS Medical Systems, Erlangen, Germany) using a 1 s gantry rotation period, an x-ray tube voltage of 110 kV, and a current of 50 mA. Fifty-four dynamic CT scans were obtained with dogs positioned in dorsal recumbency under general anesthesia. On transverse scout images of the upper abdomen, a level was determined at which the aorta, portal vein, and liver were clearly visualized. Single-level dynamic scanning was performed at 2 sec intervals from the start of contrast material injection to 100 sec. A total of 50 post-contrast images were obtained per CT scan. Six helical CT scans to determine the saline flush volume were performed 60 seconds after injection.

## Image analysis

### Determination of saline flush volume

The saphenous vein of dogs flows into the femoral vein and external iliac vein to the caudal vena cava (CVC). Residual volume was measured from the saphenous vein to external iliac vein using CECT images.

Each data was transferred to a workstation (Lucion, Infinitt Technology, Seoul, Korea), and the residual volume was measured using a threshold-based method.

### Quantitative analysis

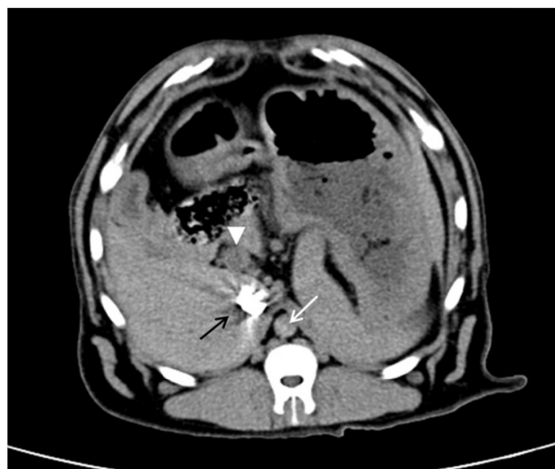CECT images were displayed on a workstation with OsiriX (Pixmeo, Geneva, Switzerland), and region of interest (ROI) measurements were performed for all groups in the aorta, portal vein, and liver. The ROI settings in liver were placed in areas that showed visually homogeneous contrast enhancement with the exclusion of visible vascular structures. When a section had too many artifacts (motion or beam hardening artifacts), attenuation values from this section were not taken into account, to avoid entering erroneous values of enhancement. Enhancement parameters calculated for each image of scans included maximum aortic, portal, and hepatic enhancement ( $I_{\max}$  A,  $I_{\max}$  P, and  $I_{\max}$  L), the time from the start of the contrast material injection to maximum aortic, portal, and hepatic enhancement ( $T_{\max}$  A,  $T_{\max}$  P, and  $T_{\max}$  L), the time from the start of the contrast material injection to onset of the equilibrium phase ( $T_{\text{eq}}$ ), and the time between aortic peak enhancement and onset of equilibrium phase ( $T-A_{\text{eq}}$ ). The equilibrium phase proposed by Foley et al. (7) represents the period when aortic and hepatic enhancements undergo gradual decline in parallel.

### Qualitative analysis

Fig. 1 shows the grading criteria for hepatic hilum depiction and perivenous image artifacts. Distinct anatomical details were scored; excellent (score 0), distinct anatomic detail and streak; good (score 1), anatomic detail clear and hypoattenuation band or streak; fair (score 2), and obscured anatomic detail and severe radiolucent halo; poor (score 3). A qualitative evaluation was performed on all images (50 images) to determine the artifact degree of the aorta, portal vein, and liver.

### Data analysis

Statistical tests were performed using commercially available statistical analysis software (SPSS 14.0, SPSS Inc., Chicago, IL, USA). All data are expressed as means  $\pm$  standard deviation for each injection protocol.



**Fig. 1.** Grading scheme for hepatic hilum depiction and image artifacts. Distinct anatomic detail; score 0, distinct anatomic detail and streak; score 1 (white arrow), anatomic detail clear and hypoattenuation band or streak; score 2 (arrowhead), obscured anatomic detail and severe radiolucent halo; score 3 (black arrow).

### Determination of saline flush volume

The measurement was performed three times, and the mean value was calculated.

### Quantitative analysis

For comparison of the effect of the contrast material doses and saline solution doses, differences in mean attenuation values between the contrast material 2 mL/kg without saline flush group and the remaining groups, and between the contrast material 3 mL/kg without saline flush group and the remaining groups, were analyzed for statistical significance by use of the Kruskal–Wallis test. When the differences were statistically significant, *post hoc* analysis was performed using the Mann–Whitney U test. A p-value of less than 0.05 was considered to indicate a statistically significant difference.

### Qualitative analysis

Artifact scores were categorized according to the injection regimen. Analysis of variance with the Kruskal–Wallis test was used to evaluate the statistical significance of the differences between with and without saline flushing at the same contrast medium dose in the artifact degree of the aorta, portal vein, and liver. When the differences were statistically significant, *post hoc* analysis was performed using the Mann–Whitney U test. A value of less than 0.05 was considered to indicate significant difference. The SPSS software was used for the statistical evaluations.

## Results

The mean vascular volume from the site where the saphenous vein flows into the external iliac vein to the CVC was 8.98 ± 1.83 mL (n = 6).

### Quantitative analysis

For a different volume of contrast material 1, 2, and 3 mL/kg and dose of saline solution 0, 5, and 10 mL, there was considerable variation in each of the enhancement parameters measured (Table 1).

#### Comparison of the contrast effects between M0 group and the other groups

In comparison with the M0 group (2 mL/kg, 0 mL), the peak enhancement of the portal ( $I_{max}$  P) in the L5 (3 mL/kg, 5 mL) group and L10 (3 mL/kg, 10 mL) group was significantly higher (Fig. 2). The S0 group showed a lower mean peak value of portal vein than the M0 group. The peak enhancement of the liver ( $I_{max}$  L) in the L0 (3 mL/kg, 0 mL), L5 (3 mL/kg, 5 mL), and L10 (3 mL/kg, 10 mL) groups were significantly higher than in the M0 group (Fig. 2). No significant differences were observed in the peak enhancement of the aorta ( $I_{max}$  A) between M0 and the other groups. A comparison of the other groups with the M0 group showed that there were no significant differences in time to peak enhancement in the aorta, portal vein, and liver ( $T_{max}$  A, P, L) ( $p < 0.05$ ). There were no significant differences in  $T_{eq}$  and  $T-A_{eq}$  between M0 and the other groups ( $p < 0.05$ ).

#### Comparison of contrast effects between L0 group and the other groups

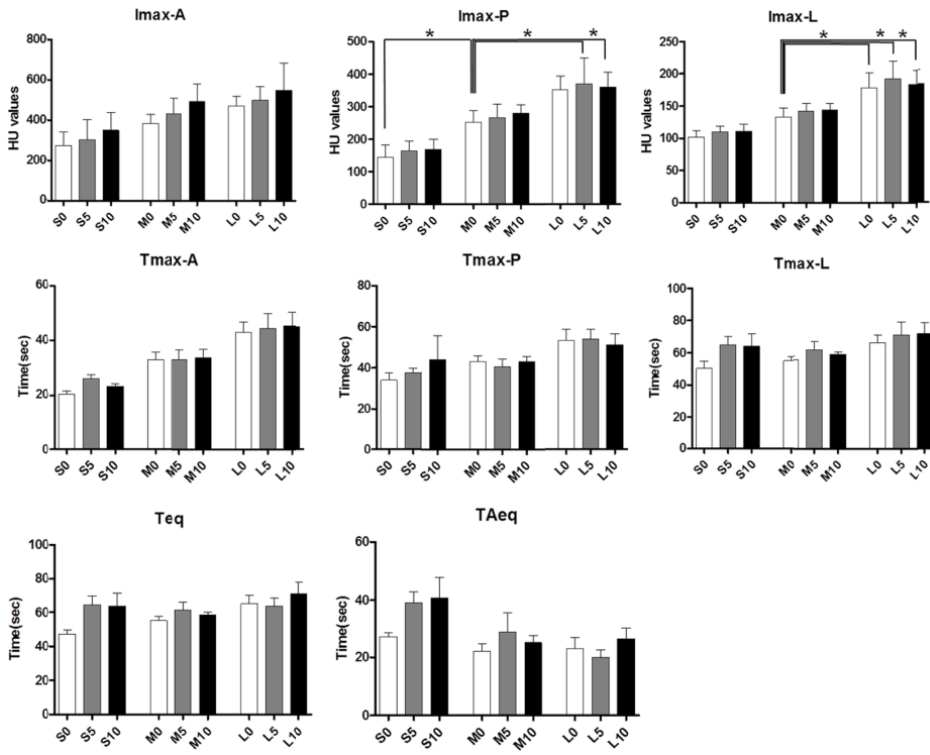
In comparison with the L0 group (3 mL/kg, 0 mL), the peak enhancement of the portal ( $I_{max}$  P) in the S0 (1 mL/kg, 0 mL), S5 (1 mL/kg, 5 mL), and S10 (1 mL/kg, 10 mL) groups was significantly lower than in the L0 group (Fig. 3). The peak enhancement of the liver ( $I_{max}$  L) in the S0 (1 mL/kg, 0 mL), S5 (1 mL/kg, 5 mL), S10 (1 mL/kg, 10 mL), and M0 (2 mL/kg, 0 mL) groups was significantly lower than in the L0 group (Fig. 3). No significant differences were observed in the peak enhancement of the aorta ( $I_{max}$  A) between L0 and the other groups. A comparison of the other groups with the L0 group showed that there were no significant differences in time to peak enhancement in the aorta, portal vein, and liver ( $T_{max}$  A, P, L), except for the S0 group in the aorta ( $p < 0.05$ ). The S0 group had significantly shorter time to peak enhancement in the aorta, than the L0 group. There were no significant differences in  $T_{eq}$  and  $T-A_{eq}$  between L0 and the other groups ( $p < 0.05$ ).

**Table 1.** Enhancement parameters of aorta, portal vein, and liver according to contrast injection protocols (Each value represents the mean ± SD)

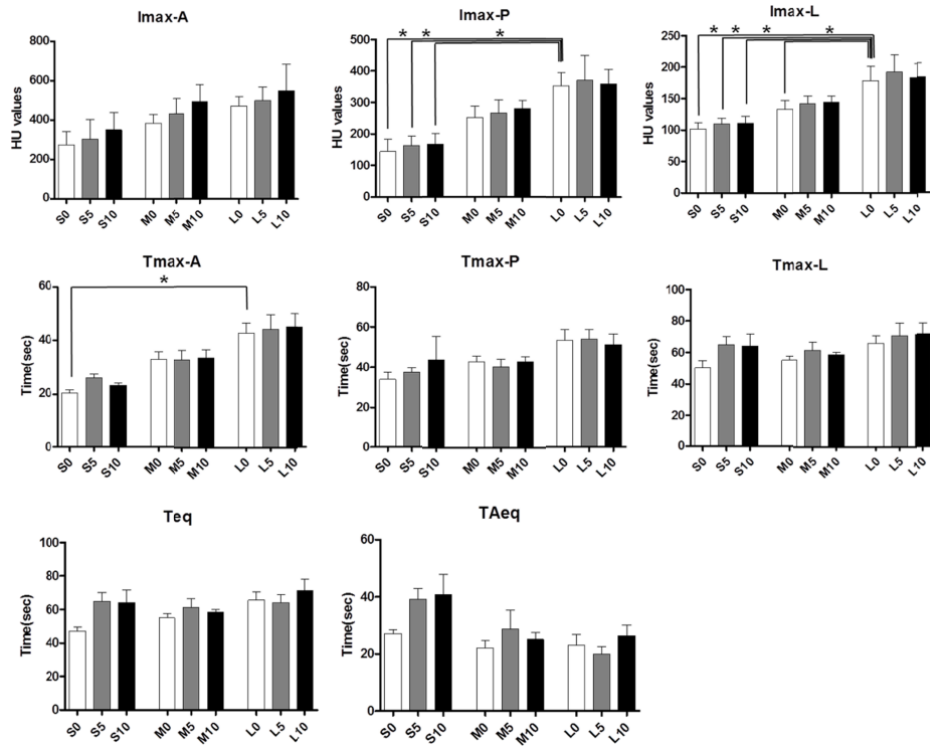
	S0 (1 mL/kg, 0 mL)	S5 (1 mL/kg, 5 mL)	S10 (1 mL/kg, 10 mL)	M0 (2 mL/kg, 0 mL)	M5 (2 mL/kg, 5 mL)	M10 (2 mL/kg, 10 mL)	L0 (3 mL/kg, 0 mL)	L5 (3 mL/kg, 5 mL)	L10 (3 mL/kg, 10 mL)
$I_{max}$ A	274.1 ± 68.1	303.5 ± 99.8	349.8 ± 87.4	383.5 ± 44.8	432.6 ± 76.8	491.4 ± 45.8	471.8 ± 68.5	499.2 ± 134.8	549.6 ± 118.6
$I_{max}$ P	144.4 ± 38.3* <sup>†</sup>	163.5 ± 30.2 <sup>†</sup>	167.7 ± 32.8 <sup>†</sup>	252.8 ± 35.1	266.2 ± 42.4	280.8 ± 24.9	352.5 ± 41.8	370.3 ± 79.9*	359.4 ± 45.2*
$I_{max}$ L	101.9 ± 9.3 <sup>†</sup>	109.9 ± 8.9 <sup>†</sup>	110.7 ± 11.0 <sup>†</sup>	133.1 ± 14.0 <sup>†</sup>	142.2 ± 11.8	144.0 ± 10.5	179.0 ± 23.0*	192.1 ± 27.4*	183.6 ± 22.4*
$T_{max}$ A	20.3 ± 3.0 <sup>†</sup>	26.0 ± 3.7	23.3 ± 2.3	33.0 ± 6.9	32.7 ± 8.6	33.3 ± 7.4	42.7 ± 9.3	44.0 ± 13.4	45.0 ± 12.2
$T_{max}$ P	34.0 ± 8.6	37.7 ± 5.1	43.7 ± 28.1	42.7 ± 6.8	40.0 ± 9.1	42.7 ± 6.5	53.3 ± 13.3	54.0 ± 11.2	51.3 ± 12.8
$T_{max}$ L	50.3 ± 10.9	65.0 ± 12.2	64.0 ± 18.6	55.0 ± 5.9	61.3 ± 12.3	58.3 ± 4.5	65.7 ± 12.3	70.7 ± 19.2	71.3 ± 16.4
$T_{eq}$	47.3 ± 4.9	65.0 ± 12.2	64.0 ± 18.6	55.0 ± 5.9	61.3 ± 12.3	58.3 ± 4.5	65.7 ± 12.3	64.0 ± 12.3	71.3 ± 16.4
$T-A_{eq}$	27.0 ± 3.7	39.0 ± 9.4	40.7 ± 17.4	22.0 ± 6.3	28.7 ± 16.1	25.0 ± 6.0	23.0 ± 9.5	20.0 ± 6.3	26.3 ± 9.2

\*Comparison of contrast effects between 2 mL/kg volume of contrast material group without saline flush (M0) and other groups.

<sup>†</sup>Comparison of contrast effects between 3 mL/kg volume of contrast material group without saline flush (L0) and other groups.



**Fig. 2.** Comparison of contrast effects between the 2 mL/kg volume of contrast material group without saline flush and other groups (\* $p < 0.05$ ).



**Fig. 3.** Comparison of contrast effects between the 3 mL/kg volume of contrast material group without saline flush and other groups (\* $p < 0.05$ ).

### Qualitative analysis

There was no significant difference between with and

without saline flushing at the same contrast material dose in the artifact score for the aorta, portal vein, and liver ( $p > 0.05$ ) (Table 2).

**Table 2.** Score of aorta, portal vein, and liver in volume of 1, 2, and 3 mL/kg of contrast medium with and without saline solution flush of 5 and 10 mL

Volume	Aorta	Portal vein	Liver
S0 (1 mL/kg, 0 mL)	1.6 ± 1.5	1.5 ± 0.5	7.8 ± 3.6
S5 (1 mL/kg, 5 mL)	2.1 ± 2.3	2.8 ± 1.6	6.0 ± 5.9
S10 (1 mL/kg, 10 mL)	3.2 ± 1.6	2.2 ± 0.8	3.8 ± 3.6
M0 (2 mL/kg, 0 mL)	3.6 ± 1.6	6.1 ± 1.6	12.5 ± 6.0
M5 (2 mL/kg, 5 mL)	5.3 ± 2.8	4.8 ± 2.6	12.1 ± 6.1
M10 (2 mL/kg, 10 mL)	6.0 ± 1.7	5.3 ± 1.5	12.1 ± 8.3
L0 (3 mL/kg, 0 mL)	7.5 ± 3.2	12.3 ± 4.8	26.3 ± 7.7
L5 (3 mL/kg, 5 mL)	8.1 ± 4.6	13.1 ± 4.8	27.6 ± 4.9
L10 (3 mL/kg, 10 mL)	7.6 ± 2.6	11.0 ± 4.5	27.1 ± 9.7

Each value represents the mean ± SD.

## Discussion

Many researchers have studied saline solution flush techniques to decrease the dose of contrast medium during a shorter scan time. These techniques allow a substantial reduction of contrast medium dose with vascular attenuation that is comparable to that obtained with a larger dose of contrast medium (9,11,12). Saline solution flush avoids pooling of contrast medium in the injection vein and in the injection system, leading to better utilization of the contrast medium bolus (18). Several researchers have claimed that saline solution flush could result in greater liver enhancement, and allow a reduction in the volume of contrast medium injected (1,20). Additional advantages of a saline solution flush include increased hydration to reduce contrast nephropathy, improved bolus geometry due to reduced intravascular contrast material dispersion, and reduced streak artifact from dense contrast material in the venous access site (1,9,11). To the best of our knowledge, no study has investigated the saline solution flush using the saphenous vein in abdominal CECT in a small-breed dog. The aim of our study was to evaluate whether a saline flush following a low-dose contrast medium improves the vascular and parenchymal enhancement during abdominal CECT.

Saline solution flush of 20 to 30 mL may be sufficient in humans; the injection of larger quantity might not further improve contrast enhancement (1). However, a few studies have investigated the dose of saline solution for the saline flush in abdominal CECT in dogs. We first sought to establish the dose of saline adequate for the beagles used in our study. Next, we compared the dose of contrast material and saline flush on contrast effects. We investigated the effect of saline solution flush following contrast medium injection in the same dog population.

In this study, the 3 mL/kg dose of contrast medium caused slightly greater liver attenuation than 2 mL/kg of contrast material with a 5 and 10 mL saline solution flush. However, there was no significant difference in the peak values between the 3 mL/kg dose of the contrast medium alone group, and the 2 mL/kg dose of contrast medium with saline solution flush group. There was a significantly different peak value between the 3 mL/kg dose of the contrast medium without saline flush group, and the 2 mL/kg dose of the contrast medium alone group. We consider that the decrease of hepatic enhancement resulting from contrast medium dose reduction could partly be compensated by flushing with saline solution (20). The peak enhancement of the portal vein in the 3 mL/kg volume of contrast medium with saline flush groups was significantly higher than in the 2 mL/kg volume of the contrast medium alone group. However, there was no significant difference in peak value between the 3 mL/kg dose of contrast medium without saline flush group, and the 2 mL/kg dose of the contrast medium alone group. This result also represents that saline flush results in greater efficiency of the administered contrast material, by avoiding the accumulation of the contrast material in the venous system between the injection site and the right heart (17,19). In comparison with the 3 mL/kg group without saline flush, the peak enhancements of the portal and liver in the 1 mL/kg groups with and without saline flush were significantly lower than in the 3 mL/kg group without saline flush. A too-aggressive reduction of contrast material using a saline solution flush may result in poor enhancement of the vascular system and liver, particularly when using a small total amount of contrast material (1). There were no significant differences in the time from the start of the contrast material injection to the onset of the equilibrium phase, and the time between aortic peak enhancement and the onset of equilibrium phase between with and without saline flush in all groups of 1, 2, and 3 mL/kg. It was not possible to verify which factor (with and without saline solution flush) had more significant influence on the optimal temporal window.

A saline solution flush improves the efficiency of contrast material utilization by pushing the under-utilized contrast material within the injection tubing and peripheral veins into the CVC, and contributing to a higher contrast enhancement during abdominal contrast-enhanced CT (1,19). An increased aortic peak enhancement may improve the detection of thrombotic material, atherosclerotic soft plaques, and dissection flaps in the abdominal aorta and its branches (20). However, in the same contrast medium dose groups, there was no significant difference between the conditions with and without saline flush in the peak enhancement for aorta,

portal vein, and liver. One possible cause of this statistically nonsignificant difference seems to be the influence of different intravenous access sites on the contrast effects using cephalic vein and saphenous vein.

Saline solution flush will add the contrast medium that might have been retained in the catheter and peripheral venous space to the volume that reaches the central vessels (19). Using a saline solution flush diminishes the contrast pooling in the vessel into which it is injected (18). This will reduce streak and beam hardening artifact, and would theoretically decrease the total volume required to achieve satisfactory vascular enhancement (18). However, in our study, no statistically significant differences in the grades of artifact were seen regarding the hepatic hilar depiction between with and without saline solution flush. One possible cause of this statistically nonsignificant difference seems to be the small number of beagles. Also, the difference in injection rate and a low dose of saline solution flush did not allow statistical analyses comparing artifact scores of the hepatic hilar depiction for all groups.

There were some limitations to the present study. The first was that we did not use a different injection rate for the saline solution. The saline solution flush may be injected at rates different from the contrast material to modify the enhancement level during the late phase of contrast enhancement. Prolonged lower enhancement with a slower saline injection or higher enhancement with a faster saline injection would be achieved (2,13,15). Since in humans, thorax CT angiography is performed at a saline solution injection rate of 2-7 mL/s (9,12,13), in veterinary medicine, the injection speed was set to be identical to that of the contrast medium (40.0 mg/kg/s of iodine; iodine dose 600 mg/kg, injection time 15 s) (14). Second, we used a saline solution volume of 5.0 and 10.0 mL, which was the mean volume calculated for the six beagles; however, the standard deviation was relatively large (1.83 mL). In the previous study, there was a positive correlation between body weight and vascular volume (14). For more accurate comparison, individual dose settings should have been used. Finally, in other previous studies, the saline flush technique was performed using a double power injector (9,11,12).

In conclusion, the results of our study demonstrated that saline solution flush following 2 mL/kg contrast-material bolus similar resulted in liver parenchyma attenuation, compared to using 3 mL/kg of contrast medium without saline solution flush. If a saline flush is used in abdominal CECT scanning, a potential decrease in contrast nephropathy can be anticipated. An additional benefit of decreased contrast medium usage may be cost savings.

## References

1. Bae KT. Intravenous contrast medium administration and scan timing at CT: considerations and approaches. *Radiology* 2010; 256: 32-61.
2. Behrendt FF, Bruners P, Keil S, Plumhans C, Mahnken AH, Das M, et al. Effect of different saline chaser volumes and flow rates on intravascular contrast enhancement in CT using a circulation phantom. *Eur J Radiol* 2010; 73: 688-693.
3. Chambers TP, Baron RL, Lush RM. Hepatic CT enhancement. Part I. Alterations in the volume of contrast material within the same patients. *Radiology* 1994; 193: 513-517.
4. Chambers TP, Baron RL, Lush RM. Hepatic CT enhancement. Part II. Alterations in contrast material volume and rate of injection within the same patients. *Radiology* 1994; 193: 518-522.
5. Cohan RH, Dunnick NR, Leder RA, Baker ME. Extravasation of nonionic radiologic contrast media: efficacy of conservative treatment. *Radiology* 1990; 176: 65-67.
6. Fields EL, Robertson ID, Brown JC Jr. Optimization of contrast-enhanced multidetector abdominal computed tomography in sedated canine patients. *Vet Radiol Ultrasound* 2012; 53: 507-512.
7. Foley WD, Hoffmann RG, Quiroz FA, Kahn CE Jr, Perret RS. Hepatic helical CT: contrast material injection protocol. *Radiology* 1994; 192: 367-371.
8. Freeny PC, Gardner JC, vonIngersleben G, Heyano S, Nghiem HV, Winter TC. Hepatic helical CT: effect of reduction of iodine dose of intravenous contrast material on hepatic contrast enhancement. *Radiology* 1995; 197: 89-93.
9. Haage P, Schmitz-Rode T, Hübner D, Piroth W, Günther RW. Reduction of contrast material dose and artifacts by a saline flush using a double power injector in helical CT of the thorax. *AJR Am J Roentgenol* 2000; 174: 1049-1053.
10. Hopper KD. With helical CT, is nonionic contrast a better choice than ionic contrast for rapid and large IV bolus injections? *AJR Am J Roentgenol* 1996; 166: 715.
11. Hopper KD, Mosher TJ, Kasales CJ, TenHave TR, Tully DA, Weaver JS. Thoracic spiral CT: delivery of contrast material pushed with injectable saline solution in a power injector. *Radiology* 1997; 205: 269-271.
12. Irie T, Kajitani M, Yamaguchi M, Itai Y. Contrast-enhanced CT with saline flush technique using two automated injectors: how much contrast medium does it save? *J Comput Assist Tomogr* 2002; 26: 287-291.
13. Kim DJ, Kim TH, Kim SJ, Kim DP, Oh CS, Ryu YH, et al. Saline flush effect for enhancement of aorta and coronary arteries at multidetector CT coronary angiography. *Radiology* 2008; 246: 110-115.
14. Kishimoto M, Doi S, Shimizu J, Lee KJ, Iwasaki T, Miyake Y, et al. Influence of osmolarity of contrast medium and saline flush on computed tomography angiography: comparison of monomeric

- and dimeric iodinated contrast media with different iodine concentrations at an identical iodine delivery rate. *Eur J Radiol* 2010; 76: 135-139.
15. Lee CH, Goo JM, Bae KT, Lee HJ, Kim KG, Chun EJ, et al. CTA contrast enhancement of the aorta and pulmonary artery: the effect of saline chase injected at two different rates in a canine experimental model. *Invest Radiol* 2007; 42: 486-490.
  16. Megibow AJ, Jacob G, Heiken JP, Paulson EK, Hopper KD, Sica G, et al. Quantitative and qualitative evaluation of volume of low osmolality contrast medium needed for routine helical abdominal CT. *AJR Am J Roentgenol* 2001; 176: 583-589.
  17. Orlandini F, Boini S, Iochum-Duchamps S, Batch T, Zhu X, Blum A. Assessment of the use of a saline chaser to reduce the volume of contrast medium in abdominal CT. *AJR Am J Roentgenol* 2006; 187: 511-515.
  18. Pollard R, Puchalski S. CT Contrast media and applications. In: Schwarz T, Saunders J, editors. *Veterinary computed tomography*. Chichester: Wiley-Blackwell. 2011: 57-66.
  19. Schoellnast H, Tillich M, Deutschmann HA, Stessel U, Deutschmann MJ, Schaffler GJ, et al. Improvement of parenchymal and vascular enhancement using saline flush and power injection for multiple-detector-row abdominal CT. *Eur Radiol* 2004; 14: 659-664.
  20. Schoellnast H, Tillich M, Deutschmann MJ, Deutschmann HA, Schaffler GJ, Portugaller HR. Aortoiliac enhancement during computed tomography angiography with reduced contrast material dose and saline solution flush: influence on magnitude and uniformity of the contrast column. *Invest Radiol* 2004; 39: 20-26.