



2021 Korean Thyroid Imaging Reporting and Data System and Imaging-Based Management of Thyroid Nodules: Korean Society of Thyroid Radiology Consensus Statement and Recommendations

Eun Ju Ha^{1*}, Sae Rom Chung^{2*}, Dong Gyu Na³, Hye Shin Ahn⁴, Jin Chung⁵, Ji Ye Lee⁶, Jeong Seon Park⁷, Roh-Eul Yoo⁶, Jung Hwan Baek², Sun Mi Baek⁸, Seong Whi Cho⁹, Yoon Jung Choi¹⁰, Soo Yeon Hahn¹¹, So Lyung Jung¹², Ji-hoon Kim⁶, Seul Kee Kim¹³, Soo Jin Kim¹⁴, Chang Yoon Lee¹⁵, Ho Kyu Lee¹⁶, Jeong Hyun Lee², Young Hen Lee¹⁷, Hyun Kyung Lim¹⁸, Jung Hee Shin¹¹, Jung Suk Sim¹⁹, Jin Young Sung²⁰, Jung Hyun Yoon²¹, Miyoung Choi²²

¹Department of Radiology, Ajou University School of Medicine, Suwon, Korea; ²Department of Radiology and Research Institute of Radiology, Asan Medical Center, University of Ulsan College of Medicine, Seoul, Korea; ³Department of Radiology, GangNeung Asan Hospital, University of Ulsan College of Medicine, Gangneung, Korea; ⁴Department of Radiology, Chung-Ang University Hospital, Chung-Ang University College of Medicine, Seoul, Korea; ⁵Department of Radiology, Ewha Womans University School of Medicine, Seoul, Korea; ⁶Department of Radiology, Seoul National University Hospital, Seoul National University College of Medicine, Seoul, Korea; ⁷Department of Radiology, Hanyang University College of Medicine, Hanyang University Hospital, Seoul, Korea; ⁸Department of Radiology, Haeundae Sharing and Happiness Hospital, Busan, Korea; ⁹Department of Radiology, Kangwon National University Hospital, Chuncheon, Korea; ¹⁰Department of Radiology, Kangbuk Samsung Hospital, Sungkyunkwan University School of Medicine, Seoul, Korea; ¹¹Department of Radiology and Center for Imaging Science, Samsung Medical Center, Sungkyunkwan University School of Medicine, Seoul, Korea; ¹²Department of Radiology, Yeouido St. Mary's Hospital, College of Medicine, The Catholic University of Korea, Seoul, Korea; ¹³Department of Radiology, Chonnam National University Hwasun Hospital, Chonnam National University Medical School, Hwasun, Korea; ¹⁴Department of Radiology, New Korea Hospital, Gimpo, Korea; ¹⁵Department of Radiology, Research Institute and Hospital, National Cancer Center, Goyang, Korea; ¹⁶Department of Radiology, Jeju National University, Jeju, Korea; ¹⁷Department of Radiology, Ansan Hospital, Korea University College of Medicine, Ansan, Korea; ¹⁸Department of Radiology, Soonchunhyang University Seoul Hospital, Seoul, Korea; ¹⁹Department of Radiology, Withsim Clinic, Seongnam, Korea; ²⁰Department of Radiology and Thyroid Center, Daerim St. Mary's Hospital, Seoul, Korea; ²¹Department of Radiology, Research Institute of Radiological Science, Yonsei University College of Medicine, Seoul, Korea; ²²Division for Healthcare Technology Assessment Research, National Evidence-based Healthcare Collaborating Agency, Seoul, Korea

Incidental thyroid nodules are commonly detected on ultrasonography (US). This has contributed to the rapidly rising incidence of low-risk papillary thyroid carcinoma over the last 20 years. The appropriate diagnosis and management of these patients is based on the risk factors related to the patients as well as the thyroid nodules. The Korean Society of Thyroid Radiology (KSThR) published consensus recommendations for US-based management of thyroid nodules in 2011 and revised them in 2016. These guidelines have been used as the standard guidelines in Korea. However, recent advances in the diagnosis and management of thyroid nodules have necessitated the revision of the original recommendations. The task force of the KSThR has revised the Korean Thyroid Imaging Reporting and Data System and recommendations for US lexicon, biopsy criteria, US criteria of extrathyroidal extension, optimal thyroid computed tomography protocol, and US follow-up of thyroid nodules before and after biopsy. The biopsy criteria were revised to reduce unnecessary biopsies for benign nodules while maintaining an appropriate sensitivity for the detection of malignant tumors in small (1–2 cm) thyroid nodules. The goal of these recommendations is to provide the optimal scientific evidence and expert opinion consensus regarding US-based diagnosis and management of thyroid nodules.

Keywords: *Thyroid nodule; Thyroid neoplasm; Lymph nodes; Ultrasonography; Computed tomography; Fine needle aspiration*

Received: September 9, 2021 **Accepted:** September 10, 2021

*These authors contributed equally to this work.

Corresponding author: Dong Gyu Na, MD, PhD, Department of Radiology, GangNeung Asan Hospital, University of Ulsan College of Medicine, 38 Bangdong-gil, Sacheon-myeon, Gangneung 25440, Korea.

• E-mail: nndgna@gmail.com

This is an Open Access article distributed under the terms of the Creative Commons Attribution Non-Commercial License (<https://creativecommons.org/licenses/by-nc/4.0>) which permits unrestricted non-commercial use, distribution, and reproduction in any medium, provided the original work is properly cited.

INTRODUCTION

The management of thyroid nodules is controversial because of the high detection rate of thyroid nodules and the increasing incidence of thyroid cancer. Although the prevalence of palpable thyroid nodules is low (3%–4%) [1,2], incidental thyroid nodules are detected at a rate of 17%–67% with ultrasonography (US) [3–6], 16%–17% with neck computed tomography (CT) or magnetic resonance imaging (MRI) scans [7,8], 1%–2% with 18F-fluorodeoxyglucose (FDG)-positron emission tomography (PET)/CT scans [9,10], and 60% in autopsy specimens [11]. Thyroid malignancy was detected in 5% of patients with palpable thyroid nodules [12], in 8%–12% of non-palpable nodules evaluated using fine-needle aspiration (FNA) [13,14], and in 36% of the evaluated autopsy specimens [15]. Although the incidence of all sizes and stages of thyroid cancer, as well as thyroid cancer-related mortality, has increased [16,17], early detection of low-risk small papillary thyroid carcinomas (PTCs) by US has contributed to the increased incidence of thyroid cancer over the last 20 years. Increased detection of low-risk small PTC is associated with overdiagnosis and overtreatment [18–20]. Therefore, the risk profiles of patients and thyroid nodules should be taken into consideration in the diagnosis and management of thyroid cancer.

US is the primary imaging modality for the evaluation of thyroid nodules [21]. US-based risk stratification systems (RSSs) or Thyroid Imaging Reporting and Data System (TIRADS) can be used to assess the malignancy risk in nodules, identify poor prognostic factors in cancer, select patients for biopsy, and determine the optimal management plan for patients with thyroid nodules. In 2011, the Korean Society of Thyroid Radiology (KSThR) published consensus recommendations and an RSS for the US-based management of thyroid nodules [22]. The Korean-TIRADS (K-TIRADS), a US-based RSS for thyroid nodules, was endorsed by the KSThR and Korean Thyroid Association in 2016 [23]. However, recent advances in the diagnosis and management of thyroid nodules have necessitated a revision of the K-TIRADS, as well as the previous recommendations [24–28]. For this purpose, the KSThR organized a taskforce in January 2021. This taskforce recommended major revisions to the US lexicon, biopsy criteria used for the K-TIRADS, US criteria for extrathyroidal extension (ETE), thyroid CT protocol, and recommendations for US follow-up before and after biopsy of thyroid nodules. The aim of these recommendations is

to present the best scientific evidence and expert opinion consensus regarding US-based diagnosis and management of thyroid nodules.

Methodology

Two authors searched MEDLINE via PubMed for articles published between January 2015 and December 2020, using keywords provided by the taskforce members. The members reviewed the retrieved articles and suggested modifications to previous recommendations based on these articles. The updated relevant articles continued to be searched and reviewed through July 2021. Frequent online communications and a few in-person meetings were conducted during the revision process due to the pandemic. The modified Delphi method was used to reach consensus, especially regarding the benefits (median value ≥ 7 : significant net benefits) and harm (median value ≤ 3 : harms outweigh benefits). Fifteen panels comprising an expert committee in thyroid radiology discussed the recommendations. A coefficient of variation of less than 0.5 indicated a reasonable internal agreement. The revision process was discussed and validated by a methodology specialist.

US Lexicon for Thyroid Nodules

The US lexicon should be simple, easy to use in clinical practice, objective with high interobserver agreement, and useful for the risk stratification and determination of the optimal management thyroid of nodules. Despite differences in US lexicons between various guidelines by professional societies, interobserver agreement is fair to moderate for most US features used for risk stratification of thyroid nodules [29–32]. The US features highly predictive of malignant nodules (punctate echogenic foci [microcalcifications], nonparallel orientation [taller-than-wide], irregular margin) or benign nodules (isoechoic or hyperechoic spongiform, intracystic echogenic foci with comet-tail artifact, pure cyst) should be strictly determined only when these features are clearly found in nodules. This will increase the specificity and interobserver agreement of these US features. Table 1 summarizes the major US lexicons, descriptors, and definitions.

Composition

Nodules are categorized based on the ratio of cystic to solid portion into solid (no obvious cystic content),

Table 1. Recommended Terminology and Definitions of the Major US Lexicon for Thyroid Nodules

US Lexicon	Descriptor	Definition	Synonym
Composition			
	Solid	No obvious cystic component	
	Predominantly solid	Cystic portion ≤ 50%	
	Predominantly cystic	Cystic portion > 50%	
	Cystic	No obvious solid component	Pure cyst
	Spongiform	Microcystic changes > 50% of solid component	Honeycomb
Echogenicity			
	Marked hypoechogenicity	hypoechoic or similar echogenicity relative to the anterior neck muscles	
	Mild hypoechogenicity	hypoechoic relative to the normal thyroid parenchyma and hyperechoic relative to the anterior neck muscles	
	Isoechogenicity	Same echogenicity as that of the normal thyroid parenchyma	
	Hyperechogenicity	Hyperechoic relative to the normal thyroid parenchyma	
Orientation (shape)			
	Parallel	Anteroposterior diameter ≤ transverse diameter in the transverse plane	
	Nonparallel	Anteroposterior diameter > transverse diameter in the transverse plane	Taller-than-wide shape
Margin			
	Smooth	Obviously discernible smooth edges	Regular, circumscribed
	Irregular	Obviously discernible, but non-smooth edges with spiculations or microlobulations	Infiltrative, non-smooth, jagged edges, lobulated
	Ill-defined	Poorly demarcated margins, which cannot be obviously differentiated from the adjacent thyroid tissue	Indistinct
Echogenic foci (calcifications)			
	Punctate echogenic foci (microcalcifications)	Punctate (≤ 1 mm) hyperechoic foci within the solid component of a nodule	
	Macrocalcifications	Large (> 1 mm) hyperechoic foci with posterior acoustic shadowing	Coarse calcifications
	Rim calcification	Peripheral curvilinear hyperechoic line surrounding the nodule margin with or without posterior shadowing (complete or incomplete)	Peripheral, egg shell calcification
	Intracystic echogenic foci with comet-tail artifact	Intracystic echogenic foci showing comet-like echogenic tail	

US = ultrasonography

predominantly solid (cystic portion ≤ 50% of nodule), predominantly cystic (cystic portion > 50% of nodule), and cystic (no obvious solid content). Nodules without obvious anechoic cystic portions were categorized as solid. Nodules with minimal cystic changes (< 10%) are categorized as predominantly solid because their malignancy risk is similar to that of nodules with cystic changes (≥ 10%) (Fig. 1) [33]. The solid composition of a nodule is an independent predictor for malignancy (sensitivity: 78.7%–95.1%; specificity: 27.0%–53.8%; positive predictive value [PPV]: 12.9%–35.4%) [34–39].

The spongiform appearance of a nodule is defined as

the aggregation of multiple nodular or linear microcystic components greater than 50% of the solid component in the partially cystic nodule (Supplementary Fig. 1). In the K-TIRADS, a spongiform nodule defined as an isoechoic or hyperechoic partially cystic nodule with a spongiform appearance is classified as benign, with a malignancy risk of < 1% [40–42]. Spongiform appearance is found exclusively in benign nodules [43,44]. This appearance may rarely be found in cystic papillary carcinomas [45]. Additionally, the malignancy risk may be increased in a hypoechoic nodule with a spongiform appearance [40,42].

Echogenicity

The echogenicity of the nodules is determined as compared to that of reference structures (normal thyroid parenchyma and anterior neck muscles, including the strap and sternocleidomastoid muscles). The strap muscle is relatively thin and frequently has an increased echogenicity due to reverberation artifacts. Conversely, the sternocleidomastoid muscle is relatively thick and less affected by artifacts. Thyroid nodules are categorized based on the echogenicity of their non-calcified solid components into markedly hypoechoic (hypoechoic or similar echogenicity relative to the anterior neck muscles), mildly hypoechoic (hypoechoic relative to the normal thyroid parenchyma and hyperechoic relative to the anterior neck muscles), isoechoic (same echogenicity as that of the normal thyroid parenchyma), or hyperechoic (hyperechoic relative to the normal thyroid parenchyma) (Fig. 2). For nodules with heterogeneous or mixed echogenicity of

the solid component, the predominant echogenicity is used to categorize the nodules and stratify the risk of malignancy [46]. In cases of abnormal thyroid parenchyma hypoechoogenicity due to diffuse thyroid diseases, nodule echogenicity should be determined relative to the anterior neck muscle and presumed normal thyroid echogenicity (instead of the surrounding parenchymal echogenicity) to avoid misclassification.

The malignancy risk is similar between nodules with decreased echogenicity and nodules with similar echogenicity relative to the anterior neck muscles, and nodules with marked hypoechoogenicity have a greater malignancy risk than nodules with mild hypoechoogenicity [46]. Hypoechoogenicity of nodules is an independent predictor of malignancy (sensitivity: 74.7%–94.0%; specificity: 56.7%–74.2%; PPV: 16.7%–52.7%) [35–39].

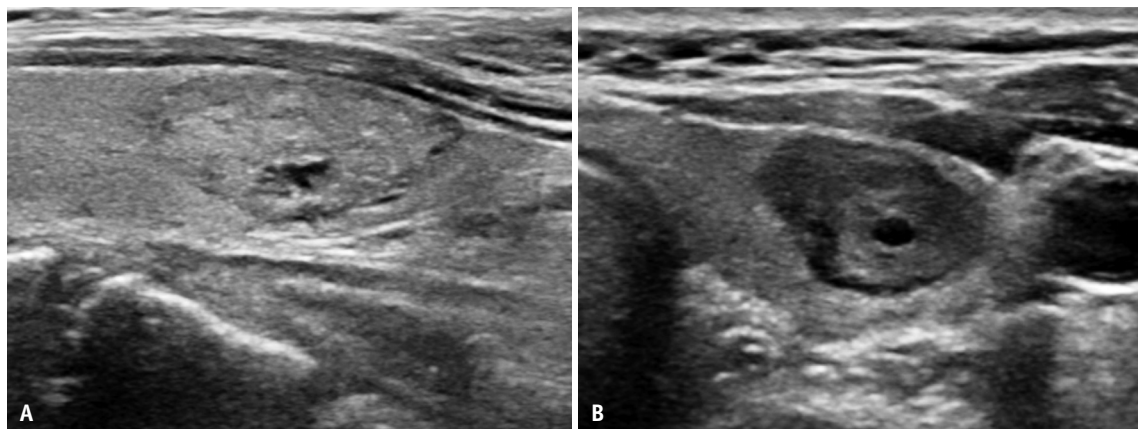


Fig. 1. Nodules with minimal cystic changes.

A. Predominantly solid and isoechoic nodule with focal minimal cystic changes (K-TIRADS 3, low suspicion). Diagnosis: benign follicular nodule. **B.** Predominantly solid and mildly hypoechoic nodule with focal minimal cystic change (K-TIRADS 3, low suspicion). Diagnosis: benign follicular nodule. K-TIRADS = Korean Thyroid Imaging Reporting and Data System

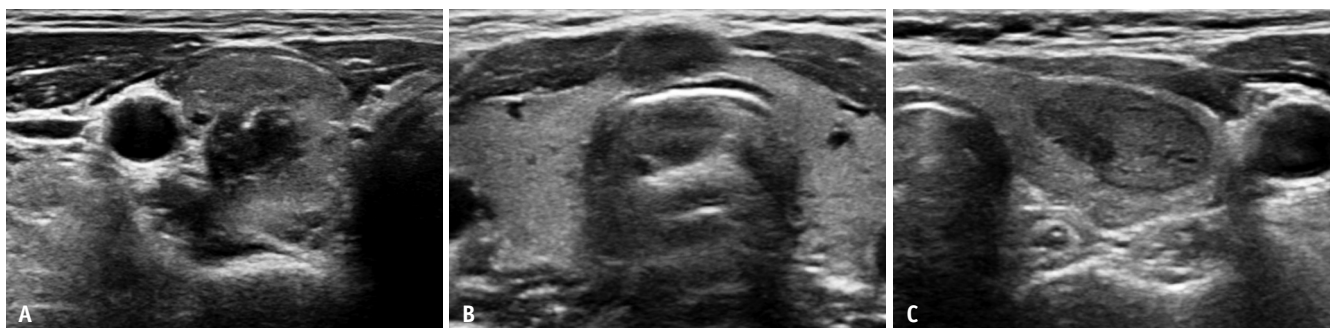

Fig. 2. Nodules with marked and mild hypoechoogenicity.

A. Solid nodule with marked hypoechoogenicity, which is hypoechoic relative to the anterior neck muscles, and punctate echogenic foci (K-TIRADS 5, high suspicion). Diagnosis: papillary carcinoma. **B.** Solid nodule with marked hypoechoogenicity, similar to the anterior neck muscles (K-TIRADS 4, intermediate suspicion). Diagnosis: papillary carcinoma. **C.** Solid nodule with mild hypoechoogenicity (K-TIRADS 4, intermediate suspicion). Diagnosis: benign follicular nodule. K-TIRADS = Korean Thyroid Imaging Reporting and Data System

Orientation (Shape)

The orientation of the thyroid nodules is determined by their direction of growth. The nonparallel orientation is the same US feature as the “taller-than-wide shape” [47,48]. The orientation of nodules in the transverse plane is categorized as parallel (anteroposterior diameter \leq transverse diameter) or nonparallel (anteroposterior diameter $>$ transverse diameter). The committee selected the transverse plane as a reference for the nodule orientation because there was no difference in the diagnostic performance of RSSs between US image planes (transverse plane vs. either transverse or longitudinal plane) [49]. However, the use of the transverse plane is simpler and may be associated with less interobserver variability.

The nonparallel orientation (taller-than-wide shape) of nodules is an independent predictor of malignancy (sensitivity: 15.2%–53.0%; specificity: 88.2%–98.7%; PPV: 47.3%–77.5%) [34–38,40]. The malignancy risk of nodules with a nonparallel orientation depends on their composition and echogenicity [35,36]. The malignancy risk of nonparallel orientation is higher in solid hypoechoic nodules (77.0%–87.7%) than in partially cystic or iso-/hyperechoic nodules (10.5%–31.3%) [35,36,49].

Nodules may be round to ovoid or irregular, irrespective of their orientation. However, these US features were not included in the lexicon used for risk stratification of the nodules. Although nodules with round to ovoid shapes are frequently benign, these features are not specific for benign nodules and may be found in follicular carcinomas or the follicular variants of PTCs [50–52]. Irregular shapes are not specific for benign or malignant nodules [40,53,54].

Margin

Although the definition of a nodule margin is controversial, current guidelines for the US lexicon have used similar categories and definitions of margins [23,47,48,55]. Nodule margins can be categorized as smooth, irregular, or ill-defined. Obviously discernible margins are categorized as either smooth (obviously discernible smooth edges) or irregular (obviously discernible, but non-smooth edges with spiculations or microlobulations). Poorly demarcated margins that cannot be clearly differentiated from adjacent thyroid tissue are categorized as ill-defined.

Spiculated or microlobulated margins were categorized as irregular. Nodules without irregular margins, but with mixed smooth and ill-defined margins, were categorized based

on the dominant feature. A smooth margin is commonly found in hypoechoic or hyperechoic nodules, isoechoic nodules with hypoechoic halos, and cystic or partially cystic nodules. An irregular margin is commonly found in infiltrating malignant tumors, mostly in hypoechoic nodules or rarely in isoechoic nodules with a partly hypoechoic portion or irregular hypoechoic rim. Additionally, ill-defined margins are commonly found in isoechoic hyperplastic nodules without encapsulation [54] and in some hypoechoic nodules including focal thyroiditis [56,57] and infiltrative malignant tumors.

Smooth or ill-defined margins do not increase the risk of malignancy [40,54]. However, irregular margins are an independent predictor for malignancy (sensitivity: 29.0%–71.4%; specificity: 87.1%–98.6%; PPV: 32.1%–86.7%) [35–39]. The malignancy risk of nodules with irregular margins is less dependent on the US pattern of composition or echogenicity [35,36]. The malignancy risk for irregular margins in solid hypoechoic nodules (80.0%–86.6%) is similar to or higher than that for partially cystic nodules that are isoechoic or hyperechoic (47.8%–88.9%) [35–37].

The hypoechoic halo around a thyroid nodule is composed of the capsule or pseudocapsule of the surrounding capsular vessels, fibrous connective tissue, compressed thyroid parenchyma, and chronic inflammatory infiltrates [58,59]. A hypoechoic halo is more commonly found around benign nodules. The absence of a halo is associated with an increased risk of malignancy [60,61]. However, the presence or absence of a hypoechoic halo is not specific for benign [54,62–64] or malignant [61,65] nodules, respectively. The hypoechoic halo is also frequently found in follicular neoplasms (FNs) [50,66,67]. A thick halo may be associated with an increased risk of follicular carcinoma [67].

Echogenic Foci (Calcifications)

Echogenic foci (calcifications) are defined as focal regions that are hyperechoic to the rest of the nodule and the surrounding normal thyroid parenchyma. They are categorized as punctuate echogenic foci (PEF, microcalcifications; echogenic foci \leq 1 mm within the solid component), macrocalcifications (echogenic foci $>$ 1 mm with posterior shadowing), or as complete or incomplete rim calcification (peripheral curvilinear hyperechoic line surrounding the nodule margin with or without posterior shadowing).

PEF have the same US features as those described for microcalcifications. The committee recommends using

the descriptor 'PEF' because it may also correspond to other pathologic entities, such as inspissated colloid, as well as psammomatous or coarse microcalcifications [68]. PEF usually indicate psammomatous calcifications in PTC. However, PEF are also common in benign nodules, which rarely contain psammomatous calcifications (Supplementary Fig. 2). The majority of PEF do not show posterior acoustic artifacts, however PEF rarely show posterior acoustic shadowing or comet-tail artifacts in PTC (Fig. 3). PEF are an independent predictor for malignancy (sensitivity: 36.9%–59.6%; specificity: 78.6%–94.6%; PPV: 25.8%–68.3%) [35–40]. The malignancy risk of PEF depends on their composition and echogenicity [35,36]. The malignancy risk of PEF is substantially higher for solid hypoechoic nodules (60.7%–81.3%) compared to partially cystic or iso-/hyperechoic nodules (11.6%–25.9%) [35–37].

Intracystic echogenic foci with comet-tail artifacts

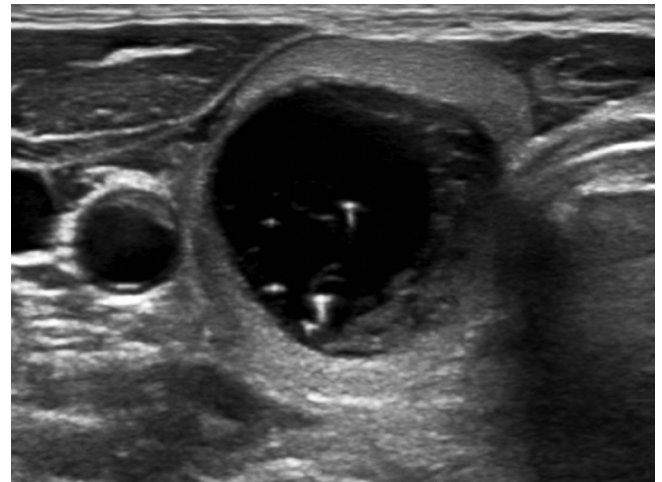


Fig. 4. Nodule with intracystic echogenic foci and comet-tail artifact. Predominantly cystic and mildly hypoechoic nodule with intracystic echogenic foci showing comet-tail artifacts (Korean Thyroid Imaging Reporting and Data System 2, benign). Diagnosis: benign follicular nodule.

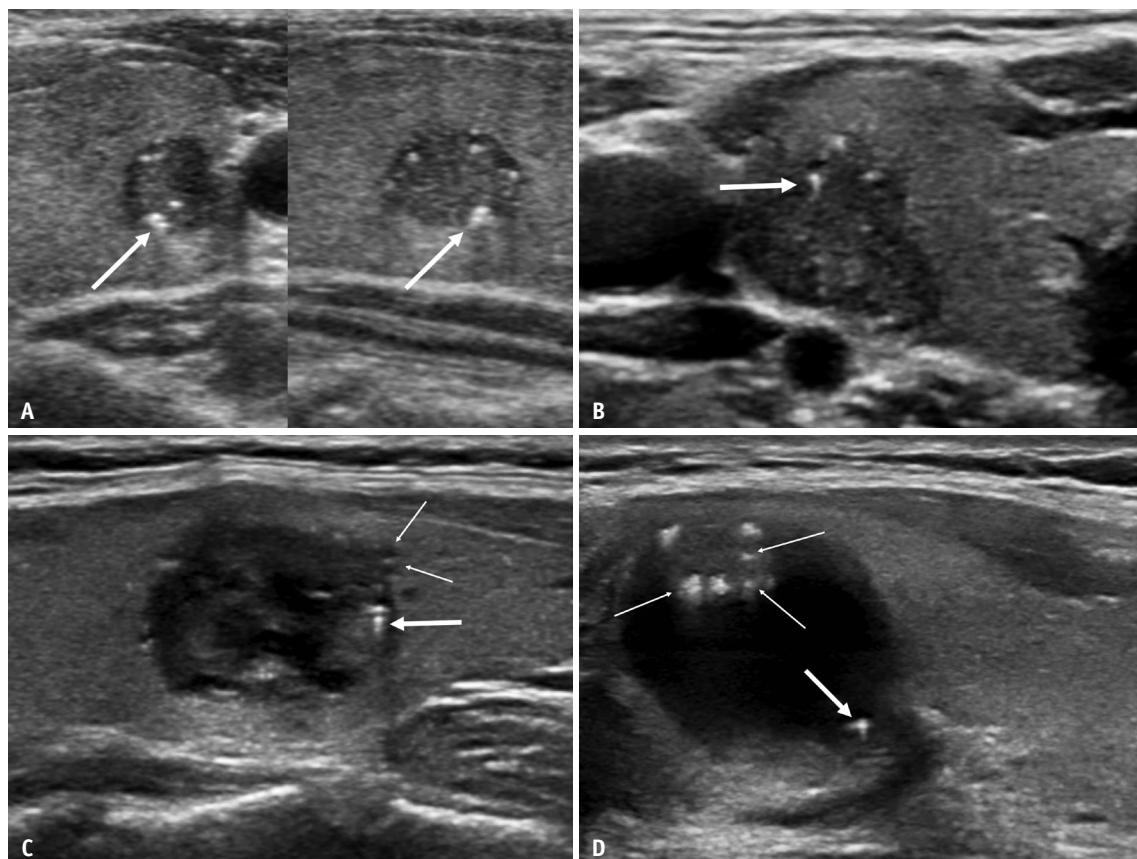


Fig. 3. Papillary carcinomas with echogenic foci and posterior acoustic artifacts.

A. Solid and mildly hypoechoic nodule with punctate echogenic foci (K-TIRADS 5, high suspicion). Punctate echogenic foci with posterior acoustic shadowing are observed in the lower part of the nodule (arrows). **B.** Solid and markedly hypoechoic nodule with punctate echogenic foci accompanying the comet-tail artifact (arrow) (K-TIRADS 5, high suspicion). **C.** Predominantly solid and markedly hypoechoic nodule with punctate echogenic foci accompanying the comet-tail artifact (thick arrow) (K-TIRADS 4, intermediate suspicion). US image shows irregular nodule margins (thin arrows). **D.** Predominantly cystic and mildly hypoechoic nodule with echogenic foci accompanying the comet-tail artifact at the margin of the cystic component (thick arrow) (K-TIRADS 4, intermediate suspicion). US image shows punctate and large echogenic foci within the solid component of the nodule (thin arrows). K-TIRADS = Korean Thyroid Imaging Reporting and Data System, US = ultrasonography

are most commonly found in benign cystic nodules and reliably predict the benign nature of nodules (malignancy risk < 1%–2%) (Fig. 4) [35,69–72]. Although echogenic foci with comet-tail artifacts at the margin of the cystic component are commonly found in benign nodules [69,73], they are not specific for benign nodules (Fig. 3) [73]. Notably, echogenic foci with comet-tail artifacts within the solid component or at the margin of the cystic component should not be considered as US features of benign nodules [72–75]. Intracystic echogenic foci with comet-tail artifacts are strongly correlated with the colloid content of benign nodules [70]. However, it is unclear whether intrasolid echogenic foci with comet-tail artifacts are a result of inspissated colloid or psammomatous calcifications in PTC [74,76,77].

Macrocalcifications were defined as large (> 1 mm) echogenic foci with posterior acoustic shadowing in a nodule. They include centrally located curvilinear calcifications or non-curvilinear macrocalcifications at the nodule margin. Entirely calcified nodules (isolated macrocalcifications) are rare (1.2%) and are defined as calcified nodules with posterior acoustic shadowing in which any soft tissue component is not identified due to the dense posterior acoustic shadowing on US [78]. The majority of entirely calcified nodules found on US were complete or partial coarse macrocalcifications and some were dense rim calcifications on CT scans [79]. The malignancy risk of entirely calcified nodules (≥ 1 cm) is 18.4%–23.3%. All malignant tumors reported with entirely calcified nodules were PTCs and the majority exhibited aggressive behavior [78]. Many previous studies have reported an increased risk of malignancy with macrocalcifications [35,37,40,80]. However, it is uncertain whether this association represents an independent risk of malignancy [35,37,40]. Rim calcifications are peripheral curvilinear hyperechoic lines that surround the nodule margin with or without posterior shadowing. Several studies [39,80–82] have reported that rim calcification increases the risk of malignancy in thyroid nodules. However, other studies reported conflicting results [37,40,54,83]. Therefore, it is uncertain whether rim calcification is a reliable predictor of malignancy.

Nodule Size and Growth

The size of clinically significant nodules should be measured in three dimensions. Nodule growth should be estimated using the maximal nodule size or volume. The committee adopted the American Thyroid Association (ATA)

criteria for nodule growth to define significant nodule growth, which requires an increase in size > 20% in at least two dimensions and an increase > 2 mm, or a change in volume > 50% [84]. Accurate estimation of nodule growth is essential for active surveillance and management of suspected or proven papillary thyroid microcarcinoma (PTMC), especially during follow-up.

It is uncertain whether nodule size predicts malignancy risk [85–91]. A recent study [92] reported that significant nodule growth, based on the ATA criteria, occurred in 14% of benign nodules and 25% of malignant nodules. Although some studies have suggested that the rate of nodule growth may predict the malignancy risk [92,93], it remains controversial. This is because many malignant nodules may not significantly grow [92] and some benign nodules grow slowly or rapidly [94–96]. However, rapid growth of a solid nodule may be a clinical manifestation of a high-grade malignancy, such as anaplastic thyroid carcinoma or lymphoma.

Vascularity

Color or power Doppler US can be used to evaluate nodule vascularity, which is categorized into pattern types 1–4 (type 1: no vascularity; type 2: perinodular vascularity only [circumferential vascularity at the nodule margin]; type 3: mild intranodular vascularity with or without perinodular vascularity (vascularity < 50%); type 4, marked intranodular vascularity with or without perinodular vascularity [vascularity \geq 50%]) [23]. Intranodular vascularity was observed in 16.7%–91.7% of malignant nodules and 30.7%–65.3% of benign nodules [13,64,97–101]. Although intranodular vascularity may predict malignancy risk, no consistent associations have been reported for vascularity patterns with malignancy risk [101–103]. Several studies have reported that intranodular vascularity did not predict malignancy risk and was not superior to gray-scale US alone for the prediction of malignancy risk in all thyroid nodules [35,101]. A meta-analysis reported that the use of color Doppler US may not predict the malignancy risk of thyroid nodules [104]. Various US techniques for detecting vascular flow have been developed for use in clinical practice. However, their use as complementary imaging modalities for the diagnosis of thyroid malignancies has not yet been established. Higher resistive or pulsatile index values of spectral Doppler US may predict malignancy risk [102,105]. Contrast-enhanced US or superb microvascular imaging is an emerging technique. Hypoenhancement and heterogeneous

enhancement of thyroid nodules on contrast-enhanced US may predict an increased malignancy risk [106]. Superb microvascular imaging may be more accurate than color or power Doppler US for the assessment of malignant thyroid nodules [107].

Elastography

US elastography is a technique that measures tissue elasticity. Cancer tissue is usually harder and firmer than normal thyroid parenchyma or benign nodules. Two representative elastography techniques are used to quantify tissue strain. "Strain elastography" evaluates the degree of tissue deformation induced by compression or acoustic forces. "Shear wave" speed measurement, measures the speed of shear waves that propagate orthogonally to the direction of tissue displacement. The propagation speed is generally higher in malignant thyroid nodules than in benign nodules [108,109]. Early clinical studies [110,111] reported that US elastography had a similar or better performance than gray-scale US. However, recent studies have reported that elastography is not superior to gray-scale US for use alone or as a complementary imaging modality for the diagnosis of thyroid malignancy [112,113]. Several studies have reported a potential diagnostic role for US elastography in the diagnosis of thyroid nodules with indeterminate or non-diagnostic cytology [114-116] or indeterminate US features [117]. Further studies are required to establish the complementary role of US elastography in the risk stratification of thyroid nodules.

US Assessment of Extrathyroidal Tumor Extension

ETE, defined as the direct extension of primary thyroid

cancer into the perithyroidal structures [118], occurs in 11.5%–30% of differentiated thyroid carcinomas. It increases the risk of locoregional recurrence and disease-specific mortality [119,120]. The eighth edition of the American Joint Committee on Cancer staging system categorizes ETE as minor (identified by histological examination) and gross (identified preoperatively or intraoperatively) [118]. Minor ETE to perithyroidal soft tissue no longer constitutes a T category, and gross ETE to strap muscles constitutes category T3b, while ETE to major neck structures constitutes category T4. Therefore, the identification of minor and gross ETE on US is important for accurate preoperative staging of thyroid cancer. The recommended US criteria for minor and gross ETEs are summarized in Table 2.

For thyroid cancer that is in contact with the anterolateral thyroid capsule, US features that predict ETE include capsular abutment, disruption, protrusion, and replacement of strap muscles [121-130]. Capsular abutment is defined as a lack of intervening tissue between the cancer and capsule [125]. This is graded by the perimeter ratio (abutment perimeter/nodule perimeter × 100%) [123,126] or diameter ratio (abutting diameter/whole tumor diameter × 100%) [127]. Capsular disruption is defined as a loss of the anterolateral perithyroidal echogenic line at the site of contact with the cancer [123,125]. Capsular protrusion is defined as a bulge in adjacent structures with or without capsular disruption [128-130]. Replacement of the strap muscle by thyroid cancer is identified as protrusion of cancer into the strap muscle, with indistinct strap muscle margins [129]. Because US can overestimate the extent of ETE, US features with the highest PPV for ETE to the anterolateral thyroid capsule may be suitable for clinical application. The most predictive US feature for

Table 2. Recommended US Criteria for the Diagnosis of ETE of Thyroid Cancer

Category	US Feature	Description
Minor ETE		
Anterolateral	Capsular disruption	Loss of the perithyroidal echogenic line at the site of contact with the thyroid cancer
Posterior	Protrusion	Bulging across the expected margin of thyroid gland, and bulging into the perithyroidal soft tissue
Gross ETE to strap muscle	Replacement of strap muscle	Thyroid cancer protruding into the strap muscle, with indistinct strap muscle margins
Gross ETE to RLN	Protrusion into TEG	Protrusion of thyroid cancer into the TEG, beyond the expected margin of normal thyroid gland
Gross ETE to trachea	Obtuse angle	Obtuse angle formed by the surfaces of thyroid cancer and tracheal cartilage

ETE = extrathyroidal extension, RLN = recurrent laryngeal nerve, TEG = tracheoesophageal groove, US = ultrasonography

minor ETE to the anterolateral thyroid capsule was capsular disruption (sensitivity: 61.6%; specificity: 87.1%; PPV: 58.5%; negative predictive value [NPV]: 88.5%; accuracy: 81.3%) and that for gross ETE to the strap muscle is replacement of strap muscles by thyroid cancer (sensitivity: 45.4%; specificity: 99.1%; PPV: 75.9%; NPV: 96.7%; accuracy: 96.0%), respectively (Fig. 5) [129]. US features that suggest minor ETE to posterior perithyroidal soft tissues have not been determined. However, the possibility of minor ETE to posterior perithyroidal soft tissue should be considered if the cancer abuts and protrudes beyond the expected posterior margin of the thyroid gland.

If thyroid cancer extends into the lumen of the trachea, tracheal invasion can be definitively diagnosed. However, tracheal invasion is difficult to diagnose if the cancer only abuts the tracheal wall. For thyroid cancers that abut the tracheal wall, tracheal invasion by thyroid cancer can be assessed based on the angle formed by the surfaces of the cancer and trachea. An obtuse angle between the cancer and trachea showed the highest sensitivity, NPV, and accuracy for the prediction of tracheal invasion (sensitivity: 85.7%; specificity: 98.9%; PPV: 40.0%; NPV: 99.9%; accuracy: 98.8%) (Fig. 6) [129]. Similar findings have been reported for PTMC [129,131]. The risk of recurrent laryngeal nerve (RLN) invasion can be assessed based on the presence or absence of a normal rim of the thyroid between the tracheoesophageal groove (TEG) and cancer and protrusion of the cancer into the TEG. Protrusion of cancer into the TEG showed the highest accuracy for the prediction of RLN invasion compared to other US features (sensitivity: 83.3%; specificity: 96.5%; PPV: 25.6%; NPV: 99.8%; accuracy: 96.3%) (Fig. 7) [129]. The US-based diagnostic criteria for

ETE remain controversial. Well-organized prospective studies are required to validate the diagnostic performance of the US criteria for ETE.

Diagnosis of Cervical Metastatic Lymph Nodes on US

Classification of the Cervical Lymph Nodes on US According to the Risk of Nodal Metastasis

The frequency of metastasis to the cervical lymph nodes (LNs) in PTC is as high as 60%–70% [132,133]. LN metastases are associated with greater locoregional recurrence, rather than disease-specific mortality [134,135].

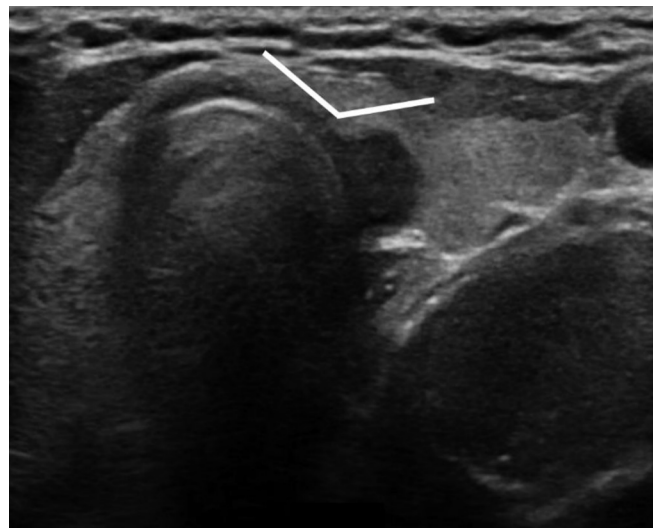


Fig. 6. Ultrasonography feature of extrathyroidal extension of thyroid cancer to the trachea. An obtuse angle (white line) was formed between the surfaces of the trachea and thyroid cancer. Diagnosis: gross extrathyroidal extension to the tracheal wall. Adapted from Chung et al. Korean J Radiol 2020;21:1187-1195 [129].

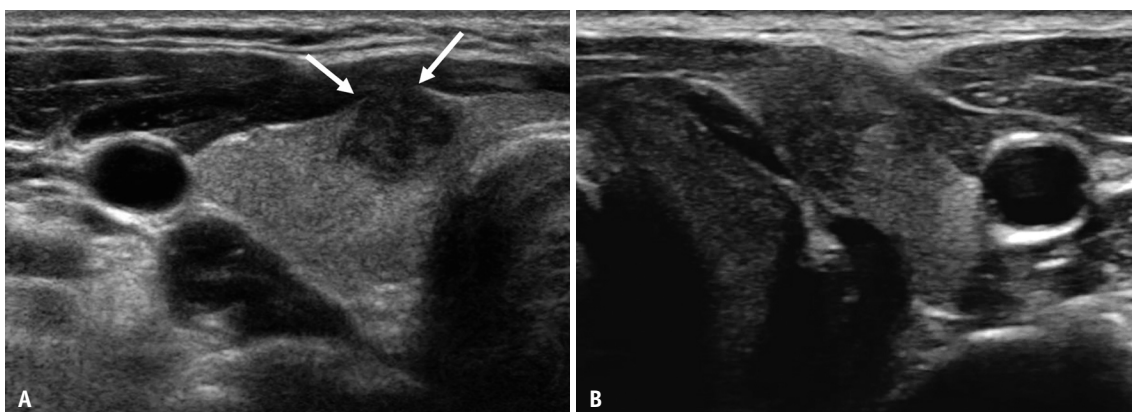


Fig. 5. Ultrasonography features of extrathyroidal extension of thyroid cancer beyond the anterolateral thyroid capsule.
A. Loss of the perithyroidal echogenic line (arrows) at the site of contact with the thyroid cancer. Diagnosis: minor extrathyroidal extension.
B. Thyroid cancer protruding into the strap muscle, with indistinct strap muscle margins. Diagnosis: gross extrathyroidal extension to the strap muscle. Adapted from Chung et al. Korean J Radiol 2020;21:1187-1195 [129].

US is the established primary imaging modality for the assessment of LNs in patients with thyroid nodules or cancer.

With regard to the risk of LN metastasis, cervical

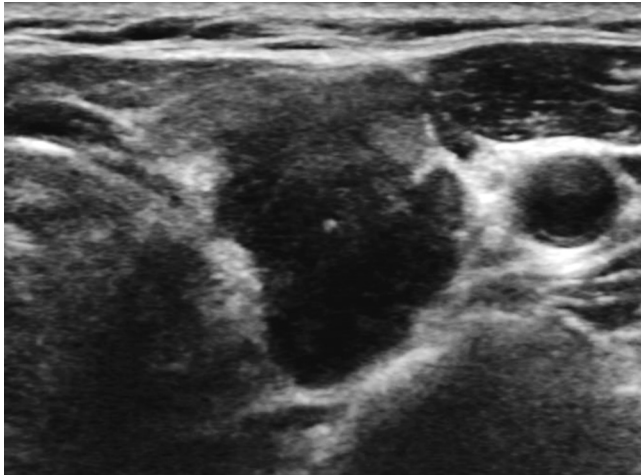


Fig. 7. Ultrasonography feature of extrathyroidal extension of the thyroid cancer to the recurrent laryngeal nerve. Protrusion of thyroid cancer into the tracheoesophageal groove. Diagnosis: gross extrathyroidal extension to the recurrent laryngeal nerve. Adapted from Chung et al. Korean J Radiol 2020;21:1187-1195 [129].

Table 3. US-Based Risk Stratification for Cervical Lymph Node Metastasis in Patients with Possible or Proven Thyroid Carcinomas

Category	US	Malignancy Risk (%) [§]
Suspicious*	Any of four suspicious features	73–88
	Cystic change	97–100
	Echogenic foci (calcifications)	86–100
	Cortical hyperechogenicity (focal/diffuse)	79–96
	Abnormal vascularity (peripheral/diffuse)	77–84
Indeterminate [†]	Loss of echogenic hilum and hilar vascularity	20
Probably benign [‡]	Echogenic hilum Hilar vascularity	< 3

*Lymph nodes with suspicious imaging features are included in this category, regardless of the presence of imaging features of probably benign or indeterminate lymph nodes, [†]Lymph nodes not included in suspicious or probably benign categories, [‡]Lymph nodes with any imaging feature of echogenic hilum or hilar vascularity are considered probably benign, if there are no suspicious imaging features, [§]Estimates based on previous studies [127,137-140]. US = ultrasonography

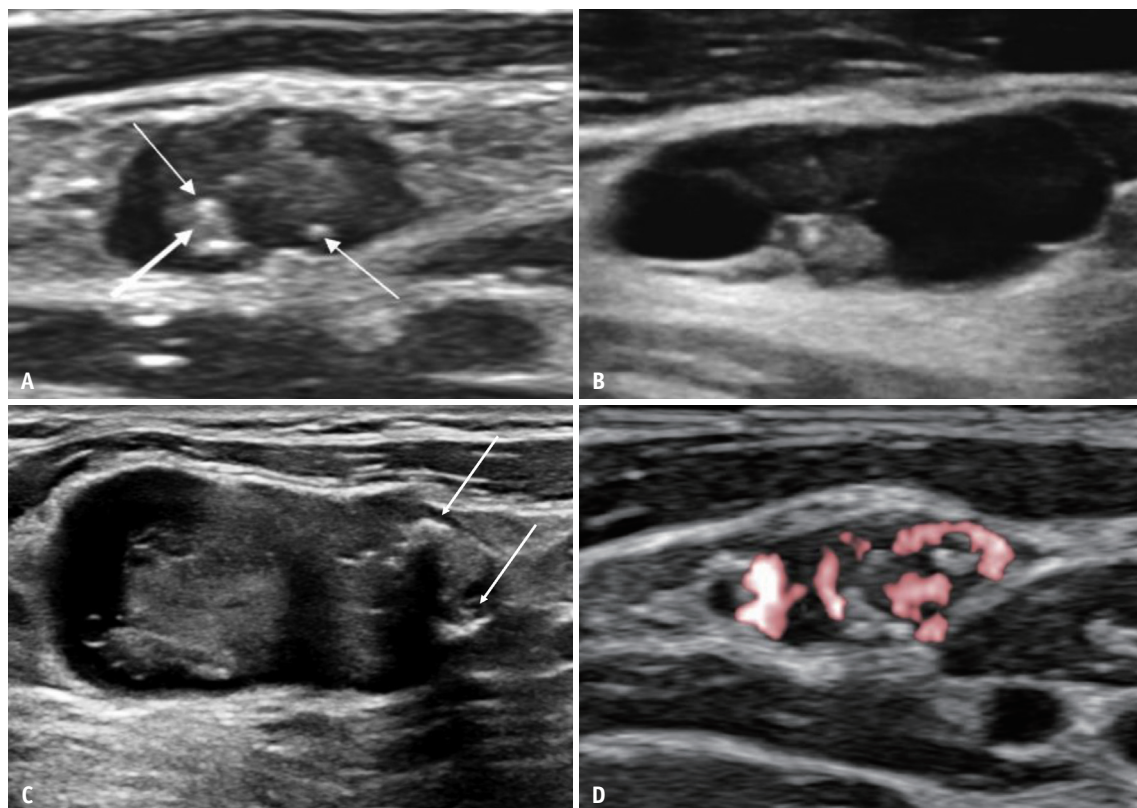


Fig. 8. Ultrasonography features of suspicious lymph nodes.

A. Focal cortical hyperechogenicity (thick arrow) and punctate echogenic foci (microcalcifications) (thin arrows) in a metastatic lymph node. **B.** Multifocal cystic changes in a metastatic lymph node. **C.** Large echogenic foci with posterior shadowing (macrocalcifications) (arrows) in a metastatic lymph node. **D.** Abnormal vascularity in a metastatic lymph node. Diagnosis: metastatic papillary carcinoma (A-D).

LN can be classified as suspicious, indeterminate, and probably benign based on their US features (Table 3, Fig. 8, Supplementary Figs. 3, 4) [23,136]. LNs with any of the following features are regarded as suspicious: cystic changes, echogenic foci (calcifications), cortical hyperechogenicity (focal/diffuse), or abnormal vascularity (peripheral/diffuse). These features were reported to be highly specific and predictive of LN metastases (approximately 73%–88%) in node-by-node correlation studies (Table 3) [127,137–140]. Probably benign LNs are defined as those that do not have any imaging features of suspicious LNs and display typical imaging features of either an echogenic hilum or radiating hilar vascularity. Indeterminate LNs are those that have no imaging features of suspicious or probably benign LNs. They include LNs of any shape (ovoid or round) that have a loss of echogenic hilum and hilar vascularity on US. However, these imaging features for indeterminate LNs are not specific to metastatic nodes [136,140]. In a recent node-by-node correlation study of preoperative thyroid cancer patients, the malignancy risk of indeterminate LNs (19.5%) was significantly higher than that of probably benign LNs (2.8%); however, it was lower than that of suspicious LNs (78.4%) (Table 3) [137]. There were no significant differences in the short and long diameters and in the size ratios between benign and metastatic among the indeterminate LNs classified by US [137].

Although US is useful for the evaluation of cervical LN metastasis in patients with thyroid cancer, it has a relatively low sensitivity for the detection of metastatic LNs in the central compartment [132,141–143]. The sensitivity may be low because of the overlying thyroid gland in the central neck and poor visualization of nodal micrometastases (diameter \leq 2 mm). Nodes with macroscopic metastases have a high risk of postoperative recurrence. Conversely, micrometastatic nodes are not associated with an increased risk of disease recurrence and have a recurrence rate like that of pathologically negative nodes [134,144–148]. Therefore, preoperatively identified macroscopic metastatic LNs have prognostic significance and are regarded as clinically apparent metastatic LNs, whereas most micrometastatic nodes that are undetected by imaging have little clinical significance [134]. Recent studies have investigated the roles of advanced US imaging modalities, such as US elastography [149–153], contrast-enhanced US [154–157], and US microvascular imaging [158]. However, there are insufficient data on their clinical utility.

Indications for FNA of the Cervical Lymph Nodes

The role of US in the preoperative evaluation of cervical LNs is to detect clinically apparent and macroscopic metastatic LNs, which are the targets of surgery. Therefore, accurate preoperative imaging is crucial for the complete surgical removal of macroscopic metastatic LNs in patients with thyroid cancer. Inadequate preoperative assessment of cervical LNs can lead to persistent or recurrent disease in the neck. Therefore, we recommend FNA of suspicious LNs with a short diameter $>$ 3–5 mm, and indeterminate LNs with a short diameter $>$ 5 mm in preoperative patients with possible or proven thyroid cancer (Table 4). When FNA is performed for LNs, measurement of tissue-washout thyroglobulin is recommended for LNs in the lateral neck and selectively in the central neck.

Recent studies have reported that postoperative suspicious metastatic lesions in the thyroid bed or lateral neck usually remain stable and have a low potential for structural disease progression [159,160]. Surgical resection was successful at the time of structural disease progression. There was no evidence of local invasion or distant metastases. These data suggest that appropriately selected patients can be closely monitored with serial serum thyroglobulin measurements and neck US. The decision regarding whether and when to perform US-guided FNA for suspicious recurrent lesions in postoperative patients with thyroid cancer should be based on the location of the LN or suspicious lesion and the management plan (re-operation, non-surgical ablation therapy, or active surveillance). Considering the high risk of postoperative complications following repeat surgery, FNA may be deferred for small indeterminate or suspicious LNs $<$ 8–10 mm (short diameter on US and CT images) at the operative bed in postoperative patients if US surveillance is considered instead of re-

Table 4. Recommended FNA Indications for Cervical Lymph Nodes in Patients with Possible or Proven Thyroid Carcinomas

- 1) Suspicious lymph node: size $>$ 3–5 mm (short diameter on US or CT images)*[†]
- 2) Indeterminate lymph node: size $>$ 5 mm (short diameter on US or CT images)*[†]

*Measurement of tissue-washout thyroglobulin is recommended for lymph nodes in lateral neck and selectively in central neck, [†]If US surveillance is considered instead of re-operation or ablation therapy for suspicious recurrent lesion at operative bed in postoperative patients, FNA may be deferred for small indeterminate or suspicious lymph nodes $<$ 8–10 mm (short diameter on US and CT images). FNA = fine-needle aspiration, US = ultrasonography

operation or ablation therapy for suspicious recurrent lesions (Table 4).

US-Based Risk Stratification and the Revised 2021 Korean Thyroid Imaging Reporting and Data System

Structure of the 2021 K-TIRADS

The 2021 K-TIRADS uses a pattern-based system that stratifies the malignancy risk of a nodule using a combination of composition, echogenicity, and suspicious US features [23]. The malignancy risk of a nodule cannot be accurately estimated using a single US predictor. Therefore, a combination of several US features should be used [161]. The predictability of suspicious US features (PEF, irregular margins, and nonparallel orientation) for malignancy heterogeneously

depends on nodule composition and echogenicity [35,161]. The aforementioned data form the basis of the K-TIRADS structure. Compared to the 2016 K-TIRADS, the 2021 K-TIRADS has minimal differences in structure and suggested malignancy risk (Table 5, Fig. 9). Thyroid nodules are classified on the basis of their malignancy risk, based on US patterns, into those with high suspicion (K-TIRADS 5), intermediate suspicion (K-TIRADS 4), low suspicion (K-TIRADS 3), and benign categories (K-TIRADS 2). K-TIRADS 1 indicates no nodules in the thyroid gland. The 2021 K-TIRADS categorizes entirely calcified nodules as K-TIRADS 4 [78,162]. Extensive parenchymal PEF (microcalcifications) without discrete nodules (suspicious for diffuse sclerosing variant of PTC), and diffusely infiltrative lesions (suspicious for infiltrative malignancy, such as metastasis or lymphoma) are categorized as K-TIRADS 4. Nodules with US patterns of K-TIRADS

Table 5. US Pattern and Malignancy Risk of Thyroid Nodules and Biopsy Size Thresholds in the 2021 K-TIRADS

Category	US Patterns	Suggested Malignancy Risk (%)	Nodule Size Threshold for Biopsy [§]
High suspicion (K-TIRADS 5)	Solid hypoechoic nodule with any of the three suspicious US features (punctate echogenic foci, nonparallel orientation, and irregular margins)	> 60	> 1.0 cm
Intermediate suspicion (K-TIRADS 4)*	1) Solid hypoechoic nodules without any of the three suspicious US features or 2) Partially cystic or iso-/hyperechoic nodule with any of the three suspicious US features 3) Entirely calcified nodules [†]	10–40	> 1.0–1.5 cm [¶]
Low suspicion (K-TIRADS 3)	Partially cystic or iso-/hyperechoic nodule without any of the three suspicious US features	3–10	> 2.0 cm
Benign (K-TIRADS 2) [‡]	1) Iso-/hyperechoic spongiform 2) Partially cystic nodule with intracystic echogenic foci and comet-tail artifact 3) Pure cyst	< 3	Not indicated**
No nodule (K-TIRADS 1)	-	-	-

*Extensive parenchymal punctate echogenic foci (microcalcifications) without discrete nodules (suspicious for diffuse sclerosing variant of PTC) and diffusely infiltrative lesions (suspicious for infiltrative malignancy, such as metastasis or lymphoma) are considered to be intermediate suspicion (K-TIRADS 4) nodules, [†]Entirely calcified nodules with complete posterior acoustic shadowing, with no soft tissue component identified due to dense shadowing on US (isolated macrocalcification), [‡]Regardless of coexisting suspicious US features (punctate echogenic foci, nonparallel orientation, or irregular margin), [§]In cases with poor prognostic risk factors, including suspected cervical lymph node metastases, obvious extrathyroidal extension to adjacent structures (trachea, larynx, pharynx, recurrent laryngeal nerve, or perithyroidal vessels), confirmed distant metastases, or suspected medullary thyroid cancer, biopsy of the most suspicious nodule should be performed, regardless of the nodule size, ^{||}Biopsy is recommended for small (> 0.5 cm and ≤ 1 cm) high suspicion (K-TIRADS 5) nodules with high-risk features, including attachment of nodules to the trachea or posteromedial capsule along the course of the recurrent laryngeal nerve considering the potentials of high-risk microcarcinomas requiring immediate surgery. Biopsy may be considered for small (> 0.5 cm and ≤ 1 cm) K-TIRADS 5 nodules without high-risk features to decide the management plan in adults. In children, biopsy should be considered for small K-TIRADS 5 nodules (> 0.5 cm and ≤ 1 cm) to decide the management plan considering the clinical context, [¶]Cutoff size for biopsy should be determined within the range of 1 and 1.5 cm, based on the ultrasound features, nodule location, clinical risk factors, and patient factors (age, co-morbidities, and preferences), **Although biopsy is not routinely indicated, it may be performed for nodules that demonstrate continuous and significant growth or for nodules prior to ablation therapy or surgery. K-TIRADS = Korean Thyroid Imaging Reporting and Data System, PTC = papillary thyroid carcinoma, US = ultrasonography

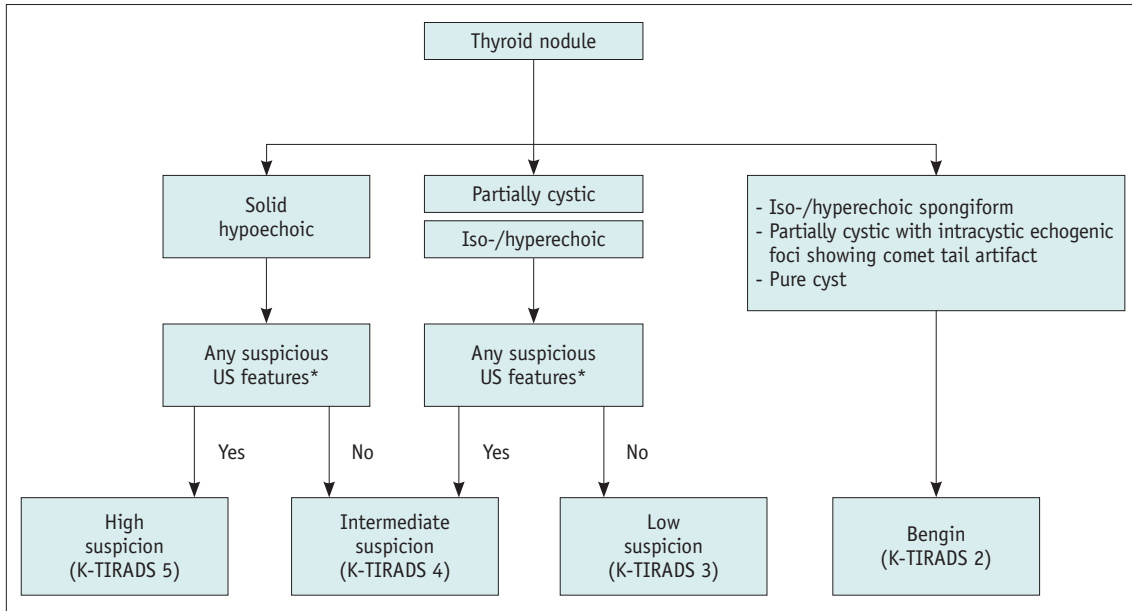


Fig. 9. Algorithm of the 2021 K-TIRADS for malignancy risk stratification based on the nodule composition and echogenicity, and suspicious US features. *Punctate echogenic foci (microcalcifications), nonparallel orientation (taller than wide shape), and irregular margins. K-TIRADS = Korean Thyroid Imaging Reporting and Data System, US = ultrasonography

2 were classified as K-TIRADS 2 regardless of coexisting suspicious US features (these nodules were classified as K-TIRADS 4 in the 2016 K-TIRADS). The modifications made to the malignancy risks of K-TIRADS 3 and 4 were based on two recent large cohort studies [163,164].

Selection of Patients for US-Guided Biopsy

Table 5 summarizes the biopsy size cutoff values and malignancy risks corresponding to the nodule categories in the 2021 K-TIRADS. Recent comparative studies reported that US-based FNA criteria of the 2016 K-TIRADS had the highest sensitivity for thyroid cancers and the highest rate of unnecessary FNA for benign nodules among the RSSs in thyroid nodules ≥ 1 cm [25-27,165,166]. The differences in diagnostic performance are attributed mainly to differences in the size threshold for biopsy rather than differences in the structure (pattern-based or point-based system) or US criteria for nodule classification [28]. The diagnostic performance of various RSSs was similar for the same size cutoff value for biopsy in simulation studies [27,28]. The diagnostic performance estimated by each classification category was comparable among the RSSs [167].

US-based RSSs require an appropriate sensitivity for the detection of malignant tumors in nodules > 1.0 cm, while reducing unnecessary biopsies for benign nodules. However, determining the diagnostic performance of US-based RSSs for thyroid malignancy remains controversial. Because tumor

size is closely related to prognosis [168-171], the diagnostic performance of RSSs should be stratified according to nodule size. The risk of distant metastasis increases for tumors > 2 cm, and the risks of local tumor invasion, nodal metastasis, and distant metastasis increase with tumor size [170,171]. Therefore, a strategy to increase the sensitivity at the expense of a higher rate of unnecessary biopsies may be appropriate for large nodules (> 2 cm). This is considering the higher risk of aggressive behavior and low predictability of the current RSS for non-PTC malignant tumors, such as encapsulated follicular variant PTC or follicular thyroid cancer [172-174]. The strategy to reduce unnecessary biopsies at the expense of decreased sensitivity may be appropriate for small nodules (1–2 cm) without aggressive sonographic features, considering the slow growth rate of most low-risk thyroid cancers. Unnecessary biopsies of small nodules (1–2 cm) place a significant burden on the healthcare system, leading to considerable anxiety in patients and unnecessary diagnostic surgical procedures due to indeterminate FNA results.

Based on the aforementioned evidence, the 2021 K-TIRADS recommends biopsy for nodules > 1 cm in size for K-TIRADS 5, > 1 –1.5 cm for K-TIRADS 4, and > 2 cm for K-TIRADS 3. The 2021 K-TIRADS recommends a cutoff size range (1–1.5 cm) for biopsy of K-TIRADS 4 nodules to allow feasible clinical application. If there are no particular risk factors, the 2021 K-TIRADS recommends biopsy for

nodules > 1.5 cm for K-TIRADS 4. However, within this range (1–1.5 cm), the decision for biopsy should be determined based on the ultrasound features, nodule location, clinical risk factors (FDG avid on PET scan, familial cancers, worrisome symptoms, such as dysphonia, etc.), and patient characteristics (age, comorbidities, and preference). Biopsy is not routinely indicated for K-TIRADS 2 nodules. However, it may be performed for nodules that demonstrate continuous and significant growth or for nodules prior to ablation therapy or surgery.

Biopsy should be performed regardless of the size of the most suspicious nodule in cases with poor prognostic factors, including suspected cervical LN metastases, obvious ETE to adjacent structures (trachea, larynx, pharynx, RLN, or perithyroidal vessels), confirmed distant metastases, or suspected medullary thyroid cancer. Biopsy is recommended for small (> 5 mm and ≤ 1 cm) K-TIRADS 5 nodules with high-risk features, including adherence of nodules to the trachea or posteromedial capsule along the course of RLN. This is considering the possibility of high-risk microcarcinomas that require immediate surgery [175]. In adults, biopsy can be considered for small (> 5 mm and ≤ 1 cm) K-TIRADS 5 nodules without high-risk features to determine the management plan. In children, biopsy should be considered for small K-TIRADS 5 nodules (> 5 mm and ≤ 1 cm) to determine the management plan considering the clinical context [176].

Diagnostic Performance of the 2021 K-TIRADS Biopsy Criteria

A recent multicenter retrospective study of 5708 thyroid nodules (malignancy rate, 19.5%) reported that the 2021 K-TIRADS 4 biopsy cutoff size of 1.5 cm had a sensitivity of 76.1%, specificity of 50.2%, and unnecessary biopsy rate for benign nodules of 40.1% [163]. A K-TIRADS 4 biopsy cutoff size of 1.0 cm had a sensitivity of 91.0%, specificity of 39.7%, and unnecessary biopsy rate for benign nodules of 48.6%. Using the biopsy cutoff size of the 2016 K-TIRADS, the sensitivity was 94.9%, specificity was 24.4%, and unnecessary biopsy rate for benign nodules was 60.9%. Compared to the 2016 K-TIRADS, the 2021 K-TIRADS significantly reduced the rate of unnecessary biopsies by 19.2%–32.8% in small nodules (≤ 2 cm) while maintaining a very high sensitivity (98.0%) for detecting large malignant tumors (> 2 cm) [163].

The unnecessary biopsy rate of small nodules (≤ 2.0 cm) with the use of the 2021 K-TIRADS 4 biopsy cutoff size

(1.5 cm) was significantly lower (17.6%) than those of the American Association of Clinical Endocrinologists/American College of Endocrinology/Associazione Medici Endocrinologi medical guidelines, the European-TIRADS, and the American College of Radiology (ACR) TIRADS (18.6%–28.1%). Additionally, the 2021 K-TIRADS afforded a significantly higher sensitivity for the detection of large malignant tumors (> 2 cm) compared to the ACR TIRADS (98.0% and 89.7%, respectively) [177].

Follow-Up for Nodules that Do not Meet the Biopsy Criteria

The optimal strategy for US follow-up of nodules that do not meet the biopsy criteria has not yet been established. The committee recommends that US follow-up of these nodules should be based on the K-TIRADS category, with frequent follow-ups for nodules with a higher K-TIRADS category. In accordance with the active surveillance strategy for PTMC, we recommend US scans every 6 months for 1–2 years for K-TIRADS 5 nodules, followed by once every year, if there is no growth on US [175,178]. For K-TIRADS 3 or 4 nodules, US follow-up should be performed at 1, 3, and 5 years. If there is no change in nodule size at 5 years, US may be performed every 3–5 years for K-TIRADS 4 nodules and in 5 years for K-TIRADS 3 nodules. For K-TIRADS 2 nodules, the first US follow-up may be performed at 2–5 years depending on the nodule size, considering their very low malignancy risk (< 3%), which is similar to the malignancy risk of biopsy-proven benign nodules. For biopsy-proven benign nodules, the interval of US follow-up can be extended to more than 2 years [94,179,180]. No studies have evaluated the criteria for discontinuation of US follow-up for thyroid nodules. However, the growth rate does not reliably distinguish between benign and malignant nodules [92,93,181]. If there is no growth in nodule size in 5 years, US follow-up may be deferred and clinical follow-up may be performed for K-TIRAD 2 or 3 nodules. Frequent US or clinical follow-up may be performed for large K-TIRAD 2 or 3 nodules that demonstrate symptomatic growth. Follow-up may be delayed or discontinued for these nodules < 1 cm.

Regardless of the K-TIRADS category, there are common considerations during follow-up. For nodules that enlarged significantly during follow-up but remained below the biopsy size threshold for their K-TIRADS category, continued US follow-up is warranted. If the K-TIRADS category changes during follow-up, follow-up or biopsy should be

performed according to the new K-TIRADS category, except for nodules with a significantly decreased size. If the nodule size significantly decreases during follow-up, US follow-up can be delayed or discontinued. For patients with compressive symptoms or neck bulge due to an increase in nodule size, US should be performed and biopsy can be considered regardless of the initial K-TIRADS category. The US follow-up strategy can be modified based on clinical judgment after considering the clinical risk factors and patient preferences.

US-Based Management of Thyroid Nodules after FNA

Management of nodules after FNA should be based on US and clinical features, as well as the FNA results. The combined use of US-based risk stratification and the Bethesda system may allow early detection of thyroid cancer and assist in making optimal management decisions after FNA (Table 6) [84,182-184].

Non-Diagnostic or Unsatisfactory Cytology

The estimated malignancy rate for nodules with non-diagnostic FNA is 5%–10% [182]. A meta-analysis reported

a malignancy rate of 2.7% for all nodules with non-diagnostic FNA and 16.8% for surgically resected nodules [185]. The malignancy risk of nodules with non-diagnostic FNA increases with an increase in the K-TIRADS score [184]. Although the malignancy rate of nodules with non-diagnostic FNA is low (but not negligible), FNA should be repeated with US guidance for nodules in this category if there is no decrease in nodule size after FNA [84,182,183]. Core needle biopsy (CNB) can be performed by an experienced operator to achieve higher diagnostic adequacy for nodules with initial or repeated non-diagnostic cytological results [186-189]. Thyroid nodules with high suspicion US patterns should be followed with a repeat biopsy within 6 months of the initial FNA. Intermediate or low suspicion US patterns may be followed with a repeat biopsy within 12 months. The timing of repeat FNA should be decided based on nodule size, clinical features, patient preferences, and US features. It is not necessary to delay a repeat biopsy for 3 months [190-192].

Benign Cytology

Although the estimated malignancy rate for FNA-proven benign nodules is low (0%–3%) [182], the follow-up strategy for these nodules should be determined by US-

Table 6. Management of Thyroid Nodules Based on FNA Results and US Patterns

FNA Diagnosis	US Pattern (K-TIRADS)	Management
Nondiagnostic	High suspicion	Repeat FNA or CNB* within 6 months [†]
	Intermediate or low suspicion	Repeat FNA or CNB* within 12 months [†]
Benign	High suspicion	Repeat FNA within 12 months
	Intermediate or low suspicion	US follow-up at 24 months
AUS/FLUS	High suspicion	Repeat FNA or CNB* within 6 months [†]
	Intermediate or low suspicion	Repeat FNA or CNB* within 12 months [†] US surveillance [‡] or molecular test
FN/SFN	All nodules	Diagnostic surgery (lobectomy) [§] US surveillance [§] or molecular test
	Suspicious for malignancy	High or intermediate suspicion Surgery Low suspicion Repeat FNA or surgery Active surveillance
Malignant	All nodules	Surgery Active surveillance

*CNB may be considered instead of a repeat FNA if an experienced operator is available, [†]The optimal timing of repeat FNA or CNB should be determined based on nodule size, presence of poor prognostic factors (such as suspected nodal metastasis or gross extrathyroidal extension), clinical factors, and US features, [‡]US follow-up may be considered, depending on the nodule size, US features, cytological features, clinical features, patient preferences, and, if possible, molecular test results. If the repeat FNA cytology findings are inconclusive, frequent US follow-up or diagnostic surgery may be considered, [§]US follow-up, instead of immediate surgery, may be considered in selected patients, depending on the nodule size, US features, clinical features, patient preferences, and, if possible, molecular test results, ^{||}Active surveillance instead of immediate surgery can be considered for adults with probable or proven low-risk papillary microcarcinoma. AUS/FLUS = atypia/follicular lesions of undetermined significance, CNB = core needle biopsy, FN/SFN = follicular neoplasm/suspicious for follicular neoplasm, FNA = fine-needle aspiration, K-TIRADS = Korean Thyroid Imaging Reporting and Data System, US = ultrasonography

based risk stratification [184,193-196]. A meta-analysis reported that the estimated malignancy rate of nodules with benign cytological results was 3.7% in surgical specimens [185], and 1%–3.2% determined by repeat FNA or long-term follow-up [184,194,196,197]. Whether false-negative FNA rates are higher [86,198-200] or similar [85,201-203] for large nodules compared to small nodules is controversial. However, the false negative rates of FNA are relatively high (3.1%–18.2%) for high suspicion thyroid nodules [184,194-196]. Therefore, we recommend that thyroid nodules with high suspicion US patterns should undergo repeat FNA within 12 months of the initial FNA, unless there is a decrease in nodule size. Thyroid nodules with intermediate or low suspicion US patterns should undergo the initial follow-up US evaluation 24 months after FNA, repeated every 2–4 years [179,204]. Repeat FNA is not routinely recommended for nodules with benign FNA results that increase in size because of the low malignancy risk of these nodules. However, it can be selectively performed based on US features, nodule size, and clinical features [181,197].

Atypia/Follicular Lesions of Undetermined Significance Cytology

The malignancy risk for thyroid nodules with atypia/follicular lesions of undetermined significance (AUS/FLUS) on cytology is estimated to be 6%–30% [182]. The reported malignancy rates for AUS/FLUS nodules are variable. A meta-analysis estimated the malignancy rate to be 15.9% [185], whereas other studies have reported a range of 26.6%–37.8% [205]. Although limited use is recommended for this diagnostic category (< 10%) [182], AUS/FLUS are diagnosed in 0.8%–27.2% of all thyroid FNA samples [185].

For the AUS/FLUS nodules, current guidelines [84,182,183] recommend a repeat FNA, which leads to a definitive diagnosis and avoids the need for diagnostic surgery [185,206]. However, a repeat FNA may be controversial because of the high rates (up to 65.4%) of repeatedly inconclusive results [207-209]. The CNB method may lead to more conclusive results for AUS/FLUS nodules compared to a repeat FNA [189]. Previous studies [187,210-212] have consistently reported lower rates of inconclusive results (categories I and III) with CNB compared to FNA for nodules initially diagnosed as AUS/FLUS (repeat FNA: 34.9%–63%; CNB: 1.0%–40.9%).

In accordance with the RSSs and TIRADS, the malignancy risk of AUS/FLUS nodules with high suspicion US features is much higher (25%–70.7%) than in those without high

suspicion US features [184,213,214]. The malignancy risk of the AUS/FLUS nodules may vary according to their subcategory. Nodules with nuclear atypia have a higher malignancy risk than those with architectural or other atypia [205,213,215,216]. Management decisions should be based on the cytological subcategory and US features of the nodules [213,217-220]. We recommend that FNA or CNB should be repeated within 6 months for thyroid nodules with high suspicion US patterns. FNA or CNB should be repeated within 12 months for those with intermediate-or low-suspicion US patterns, instead of immediate surgery. If the repeat biopsy results are inconclusive, US surveillance or diagnostic surgery can be performed after considering the estimated malignancy risk based on the US pattern and cytopathologic features, nodule size, clinical features, and patient preferences. US surveillance, instead of diagnostic surgery, may be considered for small nodules with low suspicion US patterns and cytologic features of architectural atypia, if there are no clinical risk factors. Molecular testing is not routinely recommended. It can be considered in select cases to stratify the malignancy risk [221-223].

Follicular Neoplasm or Suspicious for Follicular Neoplasm Cytology

The US features of follicular adenomas and carcinomas overlap substantially. The RSSs are not accurate and have limited ability to stratify the malignancy risk of nodules diagnosed as FN or suspicious for FN (FN/SFN) [172,184,214,224]. Although large thyroid nodules may have a higher risk of follicular thyroid cancer [85,91,225], it is uncertain whether nodule size predicts malignancy risk in FN/SFN nodules [224,226,227]. FN/SFN nodules that exhibit growth may have a higher risk of malignancy [181]. However, the growth rates were similar for benign and malignant FN/SFN nodules [224].

Diagnostic surgery is generally recommended for FN/SFN nodules [84,182,183]. Molecular tests may be used to supplement the malignancy risk assessment, instead of directly proceeding to surgery [84,223]. Newer versions of commercial molecular tests show promising diagnostic accuracy for the prediction of malignancy and for determining the optimal management of FN/SFN nodules [228,229]. Molecular tests are increasingly being used and have gained widespread acceptance for determining the need for diagnostic surgery in FN/SFN nodules [84,223]. However, the added clinical value of molecular tests may be controversial for the management of indeterminate nodules

[230,231]. US surveillance instead of immediate surgery can be considered if molecular tests suggest that the nodule is benign. In the absence of clinical, pathological, or US risk factors, US surveillance may also be considered for selected small (≤ 2 cm) nodules after consideration of clinical features and patient preferences [170,172].

Suspicious for Malignancy Cytology

Surgery is recommended for nodules with cytology suspicious for malignancy [84,182,183]. If a nodule has a low suspicion or benign US pattern, repeat FNA may be considered before surgery to exclude the possibility of false-positive cytology results in nodules without suspicious US features [232].

Malignant Cytology

Surgery is recommended for nodules with malignant cytology. Active surveillance with follow-up US should be considered as an alternative to immediate surgery for adults with low-risk PTMC without high-risk features such as LN or distant metastasis, suspected gross ETE to the trachea or RLN, worrisome tumor locations (such as attachment to the trachea or posteromedial capsule along the course of RLN), or high-grade malignancy [175,178]. Frequent US follow-up may be preferable to immediate surgery in patients with a high surgical risk due to comorbidities or a short life expectancy.

Role of CT in Thyroid Cancer Diagnosis

Thyroid CT Protocol

CT with an optimized dedicated protocol should be performed to diagnose thyroid cancer. The recommended protocol is summarized in Table 7. In patients with thyroid cancer, pre- and post-contrast CT scans are preferred. Pre-contrast CT scans are useful for the detection of calcifications and ectopic thyroid tissues and for differentiating tumor recurrence from remnant thyroid tissue after thyroidectomy [21,233]. A contrast-enhanced CT is mandatory to assess LN metastases, which are seen as areas of strong or heterogeneous enhancement and cystic changes [21,234]. Based on studies of iodine retention, contrast media is not contraindicated in patients with thyroid cancer. Recent studies have suggested that delaying radioactive iodine therapy after contrast-enhanced CT scans is not necessary [235] because the iodine clears within 4–8 weeks. Body iodine content is not essential for radioactive

Table 7. Recommended CT Protocol for Patients with Thyroid Cancer*

Items	Parameters
kVp, mAs	Manufacturer's recommended settings
Collimation, mm	64 x 0.5–0.625
Section thickness/increment, mm	0.5–1/0.5–1 (no overlap)
Scan range	Skull base to AP window
Scan direction	Craniocaudal direction
IV route	Right arm preferred [†]
Scan delay, sec	25–40 (using fixed scan delay)
Injection rate of contrast media, mL/sec	3.0–3.5
Concentration of contrast media, mg/mL	300
Amount of contrast media, mL	75–90
Volume of saline used for flushing, mL	Approximately 30
Reconstruction parameters	
Slice thickness, mm	2–3
dFOV, mm	220–230
Matrix	512 x 512
Kernel (filter/algorithm)	Manufacturer's recommended settings (usually standard or smooth Kernel)

*This protocol is for multidetector CT scanners with 64 or more channels, [†]Right arm is preferred for IV access to avoid venous reflux of contrast media due to possible physiological compression of the left innominate vein. AP = aortopulmonary, dFOV = display field of view, IV = intravenous

iodine therapy [236,237]. The CT scan range should extend from the skull base to the superior mediastinum in the anteroposterior window to evaluate upper mediastinal LNs and anatomic variations such as the aberrant right subclavian artery [21,234,238].

Acquisition of enhanced scans at an accurate time point is essential to appreciate the hypervascular LN metastasis seen in most thyroid cancers. Compared to venous phase scans, early (arterial) phase scans (25–40-second delay) depict early strong enhancement of metastatic LNs [239–241], when the contrast is injected at a rate of 3.0–3.5 mL/sec (total contrast: 75–90 mL). It accurately differentiates them from benign LNs [239,240,242]. Thin reconstruction (slice thickness: 2–3 mm) is recommended for patients with thyroid cancer. Image reconstruction should include unenhanced axial, enhanced axial, and coronal reformatted images. Sagittal reconstruction can be used to evaluate nodules in the isthmus or pyramidal

Table 8. CT-Based Risk Stratification for Cervical Lymph Node Metastasis in Patients with Thyroid Carcinomas

Category	Imaging Features
Suspicious*	Any of the three suspicious features Cystic change Calcification Strong (focal/diffuse) or heterogeneous enhancement
Indeterminate [†]	Loss of hilar fat and vessel enhancement, with no suspicious CT features
Probably benign [‡]	Presence of hilar fat or vessel enhancement and no suspicious CT features

*Lymph nodes with any suspicious imaging feature are included in this category, regardless of the presence of any imaging feature of probably benign or indeterminate lymph nodes, [†]Lymph nodes that are not included in suspicious or probably benign categories, [‡]Lymph nodes with imaging features of hilar fat or vessel are considered probably benign, if there are no suspicious imaging features. US = ultrasonography

lobe, LNs located anterior to the common carotid artery or internal jugular vein, and Delphian LNs.

CT image quality in the lower neck is frequently reduced by noise and streak artifacts from the shoulder girdle and stagnated contrast media in the subclavian vein. In patients with thyroid cancer, several strategies can be used to minimize noise and artifacts, including the shoulder-down position [243-245], flushing with sufficient amounts of saline [239,246,247], scanning in a craniocaudal direction, use of automatic tube current modulation [243], and iterative reconstruction [248].

Risk Stratification of Cervical Lymph Nodes on CT Scans

Cervical LNs are classified into three categories based on their malignancy risk: suspicious, indeterminate, and probably benign (Table 8). Suspicious LNs are defined as LNs that show cystic changes, calcifications, strong (focal/

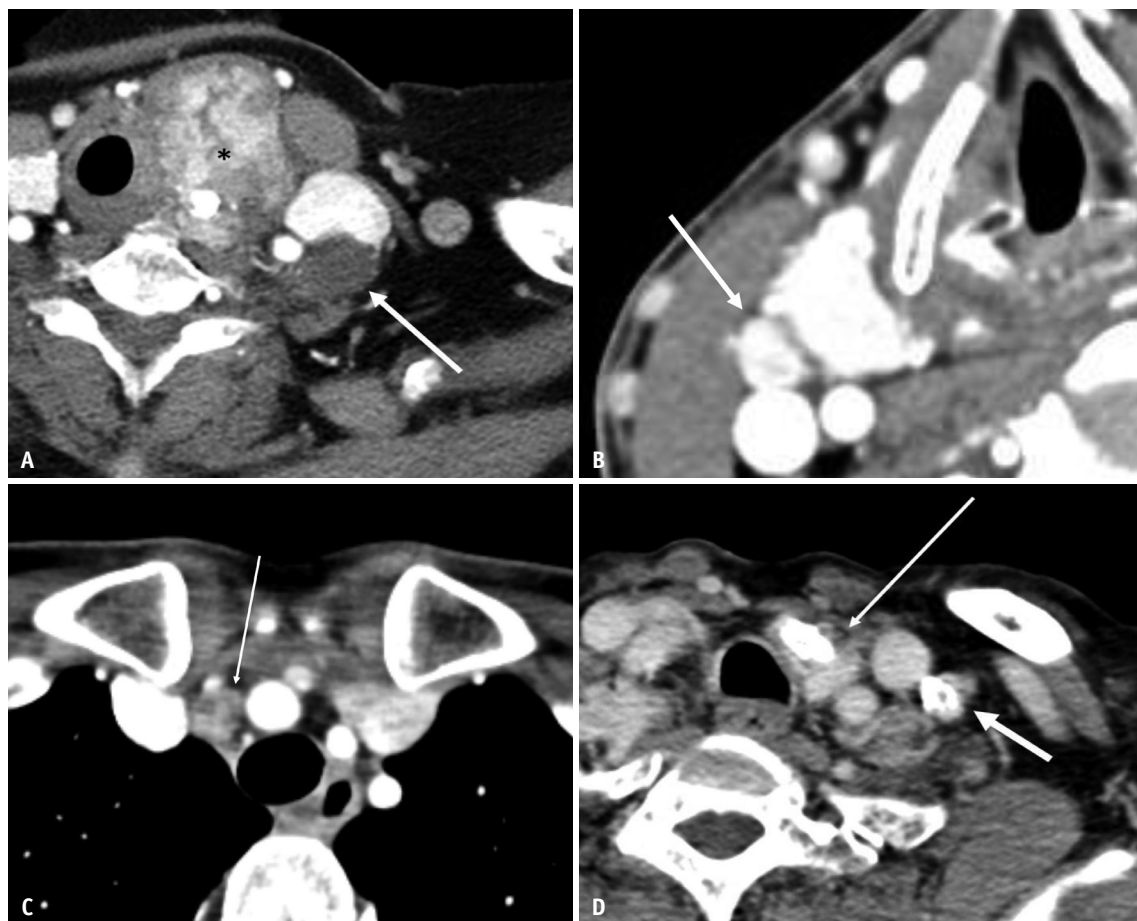


Fig. 10. Suspicious lymph nodes on CT.

A. Non-enhancing cystic lymph node (arrow). Primary cancer demonstrating heterogeneous enhancement and calcifications, seen in the left thyroid gland (asterisk). **B.** Diffuse strong enhancement of the lymph node (arrow). **C.** Heterogeneous, mild enhancement of lymph node (arrow). **D.** Calcification in an enhancing lymph node (short arrow). Primary cancer with macrocalcifications is seen in the left thyroid gland (long arrow). Diagnosis: metastatic papillary thyroid carcinomas (**A-D**).

diffuse), or heterogeneous enhancement (Fig. 10). The CT criteria for suspicious LNs have a high specificity (70%–90%) and PPV (70%–82%) for the diagnosis of metastasis [241,249,250]. Probably benign LNs are defined as LNs that do not have imaging features of suspicious LNs and show CT features typical of benign nodes. This includes hilar fat or vessel enhancement, regardless of their eccentricity (Supplementary Fig. 5). Indeterminate LNs are defined as LNs that do not have imaging features of suspicious or benign LNs (Supplementary Fig. 6).

Several studies have reported that the addition of CT scans to US improves the detection of LN metastasis in both the central and lateral neck compartments [241,249–253]. CT scans also identify metastasis in LNs that appear indeterminate or benign on US [254]. Additionally, CT scans can detect LN metastasis in compartments missed by US (e.g., in the mediastinum or retropharyngeal area), and may affect decisions regarding patient management, even in small thyroid cancers [241,255,256].

Preoperative Evaluation of Invasive Thyroid Cancer

Invasive cancer occurs in 13%–15% of patients with differentiated thyroid cancers [257]. For these patients, CT can assist in accurately delineating the extent of involvement of the aerodigestive tract and vessels [84,234,258]. MRI may have a similar degree of accuracy in the evaluation of invasive thyroid cancers [259–261]. However, MRI requires a relatively long time to perform, and the image quality may be degraded due to motion artifacts in the lower neck associated with respiration, swallowing, and pulsation. Therefore, MRI may be considered a second-line imaging modality. It is appropriate for patients with contraindications to the use of iodine-based contrast media or ionizing radiation and for some patients with advanced thyroid cancers.

Postoperative Evaluation of Recurrent Thyroid Cancer

CT may be useful in cases of suspected recurrent disease that are not delineated on US, or when the suspected recurrent disease involves the aerodigestive tract. CT may also be used in cases where US may not adequately visualize disease recurrence, especially in those patients with high serum Tg or Tg antibodies and negative US [21,84,234]. A recent study demonstrated the added value of CT to US for the detection of thyroid cancer recurrence [262]. Before revision surgery or image-guided intervention, target lesions should be accurately identified using both US and CT [21].

Future Perspectives

K-TIRADS is a pattern-based RSS that has the advantage of easy categorization of nodules during real-time US examination. In the revised 2021 K-TIRADS, the US lexicon, risk stratification, and imaging-based management of thyroid nodules have been updated for easy clinical use. The cutoff size for biopsy in the 2021 K-TIRADS was revised to reduce unnecessary biopsies while maintaining adequate sensitivity for the detection of malignancy according to the nodule size. Future studies should evaluate the interobserver variability of US features and classified risk categories defined by the 2021 K-TIRADS, and investigate the potential use of artificial intelligence for the risk stratification of nodules. We plan to revise the K-TIRADS and imaging-based recommendations for the management of thyroid nodules periodically. This revision will be based on new evidence and the results of international collaborative work.

Supplement

The Supplement is available with this article at <https://doi.org/10.3348/kjr.2021.0713>.

Availability of Data and Material

Data sharing does not apply to this article as no datasets were generated or analyzed during the current study.

Conflicts of Interest

Dong Gyu Na, Jung Hwan Baek, Ji-hoon Kim, Jeong Hyun Lee, Jung Hee Shin who is on the editorial board of the *Korean Journal of Radiology* was not involved in the editorial evaluation or decision to publish this article. All remaining authors have declared no conflicts of interest.

Author Contributions

Conceptualization: all authors. Data curation: all authors. Formal analysis: Eun Ju Ha, Sae Rom Chung, Dong Gyu Na. Funding acquisition: Dong Gyu Na. Methodology: Eun Ju Ha, Sae Rom Chung, Dong Gyu Na, Miyoung Choi. Writing—original draft: Eun Ju Ha, Sae Rom Chung, Dong Gyu Na, Jin Chung, Jeong Seon Park, Roh-Eul Yoo, Hye Shin Ahn, Ji Ye Lee. Writing—review & editing: all authors.

ORCID iDs

Eun Ju Ha

<https://orcid.org/0000-0002-1234-2919>

Sae Rom Chung
<https://orcid.org/0000-0003-4219-7166>
 Dong Gyu Na
<https://orcid.org/0000-0001-6422-1652>
 Hye Shin Ahn
<https://orcid.org/0000-0001-7260-7467>
 Jin Chung
<https://orcid.org/0000-0001-9990-3768>
 Ji Ye Lee
<https://orcid.org/0000-0002-3929-6254>
 Jeong Seon Park
<https://orcid.org/0000-0002-5550-6645>
 Roh-Eul Yoo
<https://orcid.org/0000-0002-5625-5921>
 Jung Hwan Baek
<https://orcid.org/0000-0003-0480-4754>
 Sun Mi Baek
<https://orcid.org/0000-0001-8075-0730>
 Seong Whi Cho
<https://orcid.org/0000-0001-5844-0584>
 Yoon Jung Choi
<https://orcid.org/0000-0001-7223-5421>
 Soo Yeon Hahn
<https://orcid.org/0000-0002-4099-1617>
 So Lyung Jung
<https://orcid.org/0000-0002-3267-8399>
 Ji-hoon Kim
<https://orcid.org/0000-0002-6349-6950>
 Seul Kee Kim
<https://orcid.org/0000-0002-1508-5057>
 Soo Jin Kim
<https://orcid.org/0000-0001-8233-1388>
 Chang Yoon Lee
<https://orcid.org/0000-0001-8645-3569>
 Ho Kyu Lee
<https://orcid.org/0000-0002-0173-2137>
 Jeong Hyun Lee
<https://orcid.org/0000-0002-0021-4477>
 Young Hen Lee
<https://orcid.org/0000-0001-7739-4173>
 Hyun Kyung Lim
<https://orcid.org/0000-0003-2319-3135>
 Jung Hee Shin
<https://orcid.org/0000-0001-6435-7357>
 Jung Suk Sim
<https://orcid.org/0000-0001-6803-3544>

Jin Young Sung
<https://orcid.org/0000-0002-8163-4624>
 Jung Hyun Yoon
<https://orcid.org/0000-0002-2100-3513>
 Miyoung Choi
<https://orcid.org/0000-0002-2424-9965>

Funding Statement

This study was supported by a grant by 2021 Clinical Practice Guideline Research Fund by Korean Society of Radiology & Korean Society of Thyroid Radiology.

REFERENCES

1. Vander JB, Gaston EA, Dawber TR. The significance of nontoxic thyroid nodules. Final report of a 15-year study of the incidence of thyroid malignancy. *Ann Intern Med* 1968;69:537-540
2. Tunbridge WM, Evered DC, Hall R, Appleton D, Brewis M, Clark F, et al. The spectrum of thyroid disease in a community: the Whickham survey. *Clin Endocrinol (Oxf)* 1977;7:481-493
3. Brander A, Viikinkoski P, Nickels J, Kivisaari L. Thyroid gland: US screening in a random adult population. *Radiology* 1991;181:683-687
4. Ezzat S, Sarti DA, Cain DR, Braunstein GD. Thyroid incidentalomas. Prevalence by palpation and ultrasonography. *Arch Intern Med* 1994;154:1838-1840
5. Tomimori E, Pedrinola F, Cavaliere H, Knobel M, Medeiros-Neto G. Prevalence of incidental thyroid disease in a relatively low iodine intake area. *Thyroid* 1995;5:273-276
6. Gnarni VL, Brigante G, Della Valle E, Diazi C, Madeo B, Carani C, et al. Very high prevalence of ultrasound thyroid scan abnormalities in healthy volunteers in Modena, Italy. *J Endocrinol Invest* 2013;36:722-728
7. Youserm DM, Huang T, Loevner LA, Langlotz CP. Clinical and economic impact of incidental thyroid lesions found with CT and MR. *AJNR Am J Neuroradiol* 1997;18:1423-1428
8. Yoon DY, Chang SK, Choi CS, Yun EJ, Seo YL, Nam ES, et al. The prevalence and significance of incidental thyroid nodules identified on computed tomography. *J Comput Assist Tomogr* 2008;32:810-815
9. Shie P, Cardarelli R, Sprawls K, Fulda KG, Taur A. Systematic review: prevalence of malignant incidental thyroid nodules identified on fluorine-18 fluorodeoxyglucose positron emission tomography. *Nucl Med Commun* 2009;30:742-748
10. Soelberg KK, Bonnema SJ, Brix TH, Hegedüs L. Risk of malignancy in thyroid incidentalomas detected by 18F-fluorodeoxyglucose positron emission tomography: a systematic review. *Thyroid* 2012;22:918-925
11. Furmanchuk AW, Roussak N, Ruchti C. Occult thyroid carcinomas in the region of Minsk, Belarus. An autopsy

- study of 215 patients. *Histopathology* 1993;23:319-325
12. Belfiore A, La Rosa GL, La Porta GA, Giuffrida D, Milazzo G, Lupo L, et al. Cancer risk in patients with cold thyroid nodules: relevance of iodine intake, sex, age, and multinodularity. *Am J Med* 1992;93:363-369
 13. Papini E, Guglielmi R, Bianchini A, Crescenzi A, Taccogna S, Nardi F, et al. Risk of malignancy in nonpalpable thyroid nodules: predictive value of ultrasound and color-Doppler features. *J Clin Endocrinol Metab* 2002;87:1941-1946
 14. Nam-Goong IS, Kim HY, Gong G, Lee HK, Hong SJ, Kim WB, et al. Ultrasonography-guided fine-needle aspiration of thyroid incidentaloma: correlation with pathological findings. *Clin Endocrinol (Oxf)* 2004;60:21-28
 15. Harach HR, Franssila KO, Wasenius VM. Occult papillary carcinoma of the thyroid. A "normal" finding in Finland. A systematic autopsy study. *Cancer* 1985;56:531-538
 16. Enewold L, Zhu K, Ron E, Marrogi AJ, Stojadinovic A, Peoples GE, et al. Rising thyroid cancer incidence in the United States by demographic and tumor characteristics, 1980-2005. *Cancer Epidemiol Biomarkers Prev* 2009;18:784-791
 17. Lim H, Devesa SS, Sosa JA, Check D, Kitahara CM. Trends in thyroid cancer incidence and mortality in the United States, 1974-2013. *JAMA* 2017;317:1338-1348
 18. Ahn HS, Kim HJ, Welch HG. Korea's thyroid-cancer "epidemic"--screening and overdiagnosis. *N Engl J Med* 2014;371:1765-1767
 19. Vaccarella S, Franceschi S, Bray F, Wild CP, Plummer M, Dal Maso L. Worldwide thyroid-cancer epidemic? The increasing impact of overdiagnosis. *N Engl J Med* 2016;375:614-617
 20. Seib CD, Sosa JA. Evolving understanding of the epidemiology of thyroid cancer. *Endocrinol Metab Clin North Am* 2019;48:23-35
 21. Lee JY, Baek JH, Ha EJ, Sung JY, Shin JH, Kim JH, et al. 2020 imaging guidelines for thyroid nodules and differentiated thyroid cancer: Korean Society of Thyroid Radiology. *Korean J Radiol* 2021;22:840-860
 22. Moon WJ, Baek JH, Jung SL, Kim DW, Kim EK, Kim JY, et al. Ultrasonography and the ultrasound-based management of thyroid nodules: consensus statement and recommendations. *Korean J Radiol* 2011;12:1-14
 23. Shin JH, Baek JH, Chung J, Ha EJ, Kim JH, Lee YH, et al. Ultrasonography diagnosis and imaging-based management of thyroid nodules: revised Korean Society of Thyroid Radiology consensus statement and recommendations. *Korean J Radiol* 2016;17:370-395
 24. Ha EJ, Na DG, Baek JH. Korean thyroid imaging reporting and data system: current status, challenges, and future perspectives. *Korean J Radiol* 2021;22:1569-1578
 25. Ha EJ, Na DG, Baek JH, Sung JY, Kim JH, Kang SY. US fine-needle aspiration biopsy for thyroid malignancy: diagnostic performance of seven society guidelines applied to 2000 thyroid nodules. *Radiology* 2018;287:893-900
 26. Ha EJ, Na DG, Moon WJ, Lee YH, Choi N. Diagnostic performance of ultrasound-based risk-stratification systems for thyroid nodules: comparison of the 2015 American Thyroid Association guidelines with the 2016 Korean Thyroid Association/Korean Society of Thyroid Radiology and 2017 American College of Radiology guidelines. *Thyroid* 2018;28:1532-1537
 27. Ha SM, Baek JH, Na DG, Suh CH, Chung SR, Choi YJ, et al. Diagnostic performance of practice guidelines for thyroid nodules: thyroid nodule size versus biopsy rates. *Radiology* 2019;291:92-99
 28. Yim Y, Na DG, Ha EJ, Baek JH, Sung JY, Kim JH, et al. Concordance of three international guidelines for thyroid nodules classified by ultrasonography and diagnostic performance of biopsy criteria. *Korean J Radiol* 2020;21:108-116
 29. Kim SH, Park CS, Jung SL, Kang BJ, Kim JY, Choi JJ, et al. Observer variability and the performance between faculties and residents: US criteria for benign and malignant thyroid nodules. *Korean J Radiol* 2010;11:149-155
 30. Choi SH, Kim EK, Kwak JY, Kim MJ, Son EJ. Interobserver and intraobserver variations in ultrasound assessment of thyroid nodules. *Thyroid* 2010;20:167-172
 31. Hoang JK, Middleton WD, Farjat AE, Teefey SA, Abinanti N, Boschini FJ, et al. Interobserver variability of sonographic features used in the American College of Radiology thyroid imaging reporting and data system. *AJR Am J Roentgenol* 2018;211:162-167
 32. Persichetti A, Di Stasio E, Coccaro C, Graziano F, Bianchini A, Di Donna V, et al. Inter- and intraobserver agreement in the assessment of thyroid nodule ultrasound features and classification systems: a blinded multicenter study. *Thyroid* 2020;30:237-242
 33. Na DG, Kim JH, Kim DS, Kim SJ. Thyroid nodules with minimal cystic changes have a low risk of malignancy. *Ultrasonography* 2016;35:153-158
 34. Kwak JY, Han KH, Yoon JH, Moon HJ, Son EJ, Park SH, et al. Thyroid imaging reporting and data system for US features of nodules: a step in establishing better stratification of cancer risk. *Radiology* 2011;260:892-899
 35. Na DG, Baek JH, Sung JY, Kim JH, Kim JK, Choi YJ, et al. Thyroid imaging reporting and data system risk stratification of thyroid nodules: categorization based on solidity and echogenicity. *Thyroid* 2016;26:562-572
 36. Ha EJ, Moon WJ, Na DG, Lee YH, Choi N, Kim SJ, et al. A multicenter prospective validation study for the Korean thyroid imaging reporting and data system in patients with thyroid nodules. *Korean J Radiol* 2016;17:811-821
 37. Shin HS, Na DG, Paik W, Yoon SJ, Gwon HY, Noh BJ, et al. Malignancy risk stratification of thyroid nodules with macrocalcification and rim calcification based on ultrasound patterns. *Korean J Radiol* 2021;22:663-671
 38. Yoon JH, Lee HS, Kim EK, Moon HJ, Kwak JY. Malignancy risk stratification of thyroid nodules: comparison between the thyroid imaging reporting and data system and the

- 2014 American Thyroid Association management guidelines. *Radiology* 2016;278:917-924
39. Middleton WD, Teefey SA, Reading CC, Langer JE, Beland MD, Szabunio MM, et al. Multiinstitutional analysis of thyroid nodule risk stratification using the American College of Radiology thyroid imaging reporting and data system. *AJR Am J Roentgenol* 2017;208:1331-1341
 40. Moon WJ, Jung SL, Lee JH, Na DG, Baek JH, Lee YH, et al. Benign and malignant thyroid nodules: US differentiation--multicenter retrospective study. *Radiology* 2008;247:762-770
 41. Moon WJ, Kwag HJ, Na DG. Are there any specific ultrasound findings of nodular hyperplasia ("leave me alone" lesion) to differentiate it from follicular adenoma? *Acta Radiol* 2009;50:383-388
 42. Kim JY, Jung SL, Kim MK, Kim TJ, Byun JY. Differentiation of benign and malignant thyroid nodules based on the proportion of sponge-like areas on ultrasonography: imaging-pathologic correlation. *Ultrasonography* 2015;34:304-311
 43. Bonavita JA, Mayo J, Babb J, Bennett G, Oweity T, Macari M, et al. Pattern recognition of benign nodules at ultrasound of the thyroid: which nodules can be left alone? *AJR Am J Roentgenol* 2009;193:207-213
 44. Aydoğan Bİ, Ceyhan K, Şahin M, Çorapçioğlu D. Are thyroid nodules with spongiform morphology always benign? *Cytopathology* 2019;30:46-50
 45. Kobayashi K, Hirokawa M, Yabuta T, Fukushima M, Kihara M, Takamura Y, et al. Papillary thyroid carcinoma with honeycomb-like multiple small cysts: characteristic features on ultrasonography. *Eur Thyroid J* 2013;2:270-274
 46. Lee JY, Na DG, Yoon SJ, Gwon HY, Paik W, Kim T, et al. Ultrasound malignancy risk stratification of thyroid nodules based on the degree of hypoechoogenicity and echotexture. *Eur Radiol* 2020;30:1653-1663
 47. Grant EG, Tessler FN, Hoang JK, Langer JE, Beland MD, Berland LL, et al. Thyroid ultrasound reporting lexicon: white paper of the ACR thyroid imaging, reporting and data system (TIRADS) committee. *J Am Coll Radiol* 2015;12:1272-1279
 48. Russ G, Bonnema SJ, Erdogan MF, Durante C, Ngu R, Leenhardt L. European Thyroid Association guidelines for ultrasound malignancy risk stratification of thyroid nodules in adults: the EU-TIRADS. *Eur Thyroid J* 2017;6:225-237
 49. Kim SY, Na DG, Paik W. Which ultrasound image plane is appropriate for evaluating the taller-than-wide sign in the risk stratification of thyroid nodules? *Eur Radiol* 2021;31:7605-7613
 50. Jeh SK, Jung SL, Kim BS, Lee YS. Evaluating the degree of conformity of papillary carcinoma and follicular carcinoma to the reported ultrasonographic findings of malignant thyroid tumor. *Korean J Radiol* 2007;8:192-197
 51. Yoon JH, Kim EK, Hong SW, Kwak JY, Kim MJ. Sonographic features of the follicular variant of papillary thyroid carcinoma. *J Ultrasound Med* 2008;27:1431-1437
 52. Kim DS, Kim JH, Na DG, Park SH, Kim E, Chang KH, et al. Sonographic features of follicular variant papillary thyroid carcinomas in comparison with conventional papillary thyroid carcinomas. *J Ultrasound Med* 2009;28:1685-1692
 53. Kwak JY, Jung I, Baek JH, Baek SM, Choi N, Choi YJ, et al. Image reporting and characterization system for ultrasound features of thyroid nodules: multicentric Korean retrospective study. *Korean J Radiol* 2013;14:110-117
 54. Seo H, Na DG, Kim JH, Kim KW, Yoon JW. Ultrasound-based risk stratification for malignancy in thyroid nodules: a four-tier categorization system. *Eur Radiol* 2015;25:2153-2162
 55. Zhou J, Yin L, Wei X, Zhang S, Song Y, Luo B, et al. 2020 Chinese guidelines for ultrasound malignancy risk stratification of thyroid nodules: the C-TIRADS. *Endocrine* 2020;70:256-279
 56. Langer JE, Khan A, Nisenbaum HL, Baloch ZW, Hori SC, Coleman BG, et al. Sonographic appearance of focal thyroiditis. *AJR Am J Roentgenol* 2001;176:751-754
 57. Frates MC, Marqusee E, Benson CB, Alexander EK. Subacute granulomatous (de Quervain) thyroiditis: grayscale and color Doppler sonographic characteristics. *J Ultrasound Med* 2013;32:505-511
 58. Propper RA, Skolnick ML, Weinstein BJ, Dekker A. The nonspecificity of the thyroid halo sign. *J Clin Ultrasound* 1980;8:129-132
 59. McIvor NP, Freeman JL, Salem S. Ultrasonography of the thyroid and parathyroid glands. *ORL J Otorhinolaryngol Relat Spec* 1993;55:303-308
 60. Campanella P, Ianni F, Rota CA, Corsello SM, Pontecorvi A. Quantification of cancer risk of each clinical and ultrasonographic suspicious feature of thyroid nodules: a systematic review and meta-analysis. *Eur J Endocrinol* 2014;170:R203-R211
 61. Remonti LR, Kramer CK, Leitão CB, Pinto LC, Gross JL. Thyroid ultrasound features and risk of carcinoma: a systematic review and meta-analysis of observational studies. *Thyroid* 2015;25:538-550
 62. Watters DA, Ahuja AT, Evans RM, Chick W, King WW, Metreweli C, et al. Role of ultrasound in the management of thyroid nodules. *Am J Surg* 1992;164:654-657
 63. Lu C, Chang TC, Hsiao YL, Kuo MS. Ultrasonographic findings of papillary thyroid carcinoma and their relation to pathologic changes. *J Formos Med Assoc* 1994;93:933-938
 64. Chan BK, Desser TS, McDougall IR, Weigel RJ, Jeffrey RB Jr. Common and uncommon sonographic features of papillary thyroid carcinoma. *J Ultrasound Med* 2003;22:1083-1090
 65. Brito JP, Gionfriddo MR, Al Nofal A, Boehmer KR, Leppin AL, Reading C, et al. The accuracy of thyroid nodule ultrasound to predict thyroid cancer: systematic review and meta-analysis. *J Clin Endocrinol Metab* 2014;99:1253-1263
 66. Seo HS, Lee DH, Park SH, Min HS, Na DG. Thyroid follicular neoplasms: can sonography distinguish between adenomas and carcinomas? *J Clin Ultrasound* 2009;37:493-500
 67. Zhang JZ, Hu B. Sonographic features of thyroid follicular carcinoma in comparison with thyroid follicular adenoma. *J*

- Ultrasound Med* 2014;33:221-227
68. Tahvildari AM, Pan L, Kong CS, Desser T. Sonographic-pathologic correlation for punctate echogenic reflectors in papillary thyroid carcinoma: what are they? *J Ultrasound Med* 2016;35:1645-1652
 69. Beland MD, Kwon L, Delellis RA, Cronan JJ, Grant EG. Nonshadowing echogenic foci in thyroid nodules: are certain appearances enough to avoid thyroid biopsy? *J Ultrasound Med* 2011;30:753-760
 70. Ahuja A, Chick W, King W, Metreweli C. Clinical significance of the comet-tail artifact in thyroid ultrasound. *J Clin Ultrasound* 1996;24:129-133
 71. Malhi H, Beland MD, Cen SY, Allgood E, Daley K, Martin SE, et al. Echogenic foci in thyroid nodules: significance of posterior acoustic artifacts. *AJR Am J Roentgenol* 2014;203:1310-1316
 72. Wu H, Zhang B, Li J, Liu Q, Zhao T. Echogenic foci with comet-tail artifact in resected thyroid nodules: not an absolute predictor of benign disease. *PLoS One* 2018;13:e0191505
 73. Sohn YM, Na DG, Paik W, Gwon HY, Noh BJ. Malignancy risk of thyroid nodules with nonshadowing echogenic foci. *Ultrasonography* 2021;40:115-125
 74. Klang K, Kamaya A, Tahvildari AM, Jeffrey RB, Desser TS. Atypical thyroid cancers on sonography. *Ultrasound Q* 2015;31:69-74
 75. Ha SM, Chung YJ, Ahn HS, Baek JH, Park SB. Echogenic foci in thyroid nodules: diagnostic performance with combination of TIRADS and echogenic foci. *BMC Med Imaging* 2019;19:28
 76. Ginat DT, Butani D, Giampoli EJ, Patel N, Dogra V. Pearls and pitfalls of thyroid nodule sonography and fine-needle aspiration. *Ultrasound Q* 2010;26:171-178
 77. Patel BN, Kamaya A, Desser TS. Pitfalls in sonographic evaluation of thyroid abnormalities. *Semin Ultrasound CT MR* 2013;34:226-235
 78. Gwon HY, Na DG, Noh BJ, Paik W, Yoon SJ, Choi SJ, et al. Thyroid nodules with isolated macrocalcifications: malignancy risk of isolated macrocalcifications and postoperative risk stratification of malignant tumors manifesting as isolated macrocalcifications. *Korean J Radiol* 2020;21:605-613
 79. Paik W, Na DG, Gwon HY, Kim J. CT features of thyroid nodules with isolated macrocalcifications detected by ultrasonography. *Ultrasonography* 2020;39:130-136
 80. Frates MC, Benson CB, Doubilet PM, Kunreuther E, Contreras M, Cibas ES, et al. Prevalence and distribution of carcinoma in patients with solitary and multiple thyroid nodules on sonography. *J Clin Endocrinol Metab* 2006;91:3411-3417
 81. Zheng Y, Xu S, Kang H, Zhan W. A single-center retrospective validation study of the American College of Radiology Thyroid Imaging Reporting and Data System. *Ultrasound Q* 2018;34:77-83
 82. Malhi HS, Velez E, Kazmierski B, Gulati M, Deurdulian C, Cen SY, et al. Peripheral thyroid nodule calcifications on sonography: evaluation of malignant potential. *AJR Am J Roentgenol* 2019;213:672-675
 83. Lu Z, Mu Y, Zhu H, Luo Y, Kong Q, Dou J, et al. Clinical value of using ultrasound to assess calcification patterns in thyroid nodules. *World J Surg* 2011;35:122-127
 84. Haugen BR, Alexander EK, Bible KC, Doherty GM, Mandel SJ, Nikiforov YE, et al. 2015 American Thyroid Association management guidelines for adult patients with thyroid nodules and differentiated thyroid cancer: the American Thyroid Association guidelines task force on thyroid nodules and differentiated thyroid cancer. *Thyroid* 2016;26:1-133
 85. Kamran SC, Marqusee E, Kim MI, Frates MC, Ritner J, Peters H, et al. Thyroid nodule size and prediction of cancer. *J Clin Endocrinol Metab* 2013;98:564-570
 86. Shin JJ, Caragacianu D, Randolph GW. Impact of thyroid nodule size on prevalence and post-test probability of malignancy: a systematic review. *Laryngoscope* 2015;125:263-272
 87. Hammad AY, Noureldine SI, Hu T, Ibrahim Y, Masoodi HM, Kandil E. A meta-analysis examining the independent association between thyroid nodule size and malignancy. *Gland Surg* 2016;5:312-317
 88. McHenry CR, Huh ES, Machezano RN. Is nodule size an independent predictor of thyroid malignancy? *Surgery* 2008;144:1062-1068; discussion 1068-1069
 89. Magister MJ, Chaikhoutdinov I, Schaefer E, Williams N, Saunders B, Goldenberg D. Association of thyroid nodule size and Bethesda class with rate of malignant disease. *JAMA Otolaryngol Head Neck Surg* 2015;141:1089-1095
 90. Cavallo A, Johnson DN, White MG, Siddiqui S, Antic T, Mathew M, et al. Thyroid nodule size at ultrasound as a predictor of malignancy and final pathologic size. *Thyroid* 2017;27:641-650
 91. Hong MJ, Na DG, Baek JH, Sung JY, Kim JH. Impact of nodule size on malignancy risk differs according to the ultrasonography pattern of thyroid nodules. *Korean J Radiol* 2018;19:534-541
 92. Angell TE, Vyas CM, Medici M, Wang Z, Barletta JA, Benson CB, et al. Differential growth rates of benign vs. malignant thyroid nodules. *J Clin Endocrinol Metab* 2017;102:4642-4647
 93. O'Connell K, Clark A, Hopman W, Lakoff J. Thyroid nodule growth as a predictor of malignancy. *Endocr Pract* 2019;25:1029-1034
 94. Durante C, Costante G, Lucisano G, Bruno R, Meringolo D, Paciaroni A, et al. The natural history of benign thyroid nodules. *JAMA* 2015;313:926-935
 95. Ajmal S, Rapoport S, Ramirez Battle H, Mazzaglia PJ. The natural history of the benign thyroid nodule: what is the appropriate follow-up strategy? *J Am Coll Surg* 2015;220:987-992
 96. Falch C, Axt S, Scuffi B, Koenigsrainer A, Kirschniak A, Muller S. Rapid thyroid nodule growth is not a marker for well-differentiated thyroid cancer. *World J Surg Oncol*

- 2015;13:338
97. Frates MC, Benson CB, Doubilet PM, Cibas ES, Marqusee E. Can color Doppler sonography aid in the prediction of malignancy of thyroid nodules? *J Ultrasound Med* 2003;22:127-131; quiz 132-134
 98. Rago T, Vitti P, Chiovato L, Mazzeo S, De Liperi A, Miccoli P, et al. Role of conventional ultrasonography and color flow-doppler sonography in predicting malignancy in 'cold' thyroid nodules. *Eur J Endocrinol* 1998;138:41-46
 99. Appetecchia M, Solivetti FM. The association of colour flow Doppler sonography and conventional ultrasonography improves the diagnosis of thyroid carcinoma. *Horm Res* 2006;66:249-256
 100. Ma JJ, Ding H, Xu BH, Xu C, Song LJ, Huang BJ, et al. Diagnostic performances of various gray-scale, color Doppler, and contrast-enhanced ultrasonography findings in predicting malignant thyroid nodules. *Thyroid* 2014;24:355-363
 101. Moon HJ, Kwak JY, Kim MJ, Son EJ, Kim EK. Can vascularity at power Doppler US help predict thyroid malignancy? *Radiology* 2010;255:260-269
 102. Chammas MC, Gerhard R, de Oliveira IR, Widman A, de Barros N, Durazzo M, et al. Thyroid nodules: evaluation with power Doppler and duplex Doppler ultrasound. *Otolaryngol Head Neck Surg* 2005;132:874-882
 103. Chung J, Lee YJ, Choi YJ, Ha EJ, Suh CH, Choi M, et al. Clinical applications of Doppler ultrasonography for thyroid disease: consensus statement by the Korean Society of Thyroid Radiology. *Ultrasonography* 2020;39:315-330
 104. Khadra H, Bakeer M, Hauch A, Hu T, Kandil E. Is vascular flow a predictor of malignant thyroid nodules? A meta-analysis. *Gland Surg* 2016;5:576-582
 105. Palaniappan MK, Aiyappan SK, Ranga U. Role of gray scale, color Doppler and spectral Doppler in differentiation between malignant and benign thyroid nodules. *J Clin Diagn Res* 2016;10:TC01-TC06
 106. Zhan J, Ding H. Application of contrast-enhanced ultrasound for evaluation of thyroid nodules. *Ultrasonography* 2018;37:288-297
 107. Kong J, Li JC, Wang HY, Wang YH, Zhao RN, Zhang Y, et al. Role of superb micro-vascular imaging in the preoperative evaluation of thyroid nodules: comparison with power Doppler flow imaging. *J Ultrasound Med* 2017;36:1329-1337
 108. Shiina T, Nightingale KR, Palmeri ML, Hall TJ, Bamber JC, Barr RG, et al. WFUMB guidelines and recommendations for clinical use of ultrasound elastography: part 1: basic principles and terminology. *Ultrason Med Biol* 2015;41:1126-1147
 109. Zhao CK, Xu HX. Ultrasound elastography of the thyroid: principles and current status. *Ultrasonography* 2019;38:106-124
 110. Rago T, Santini F, Scutari M, Pinchera A, Vitti P. Elastography: new developments in ultrasound for predicting malignancy in thyroid nodules. *J Clin Endocrinol Metab* 2007;92:2917-2922
 111. Asteria C, Giovanardi A, Pizzocaro A, Cozzaglio L, Morabito A, Somalvico F, et al. US-elastography in the differential diagnosis of benign and malignant thyroid nodules. *Thyroid* 2008;18:523-531
 112. Moon HJ, Sung JM, Kim EK, Yoon JH, Youk JH, Kwak JY. Diagnostic performance of gray-scale US and elastography in solid thyroid nodules. *Radiology* 2012;262:1002-1013
 113. Hahn SY, Shin JH, Ko EY, Bae JM, Choi JS, Park KW. Complementary role of elastography using carotid artery pulsation in the ultrasonographic assessment of thyroid nodules: a prospective study. *Korean J Radiol* 2018;19:992-999
 114. Cappelli C, Pirola I, Gandossi E, Agosti B, Cimino E, Casella C, et al. Real-time elastography: a useful tool for predicting malignancy in thyroid nodules with nondiagnostic cytologic findings. *J Ultrasound Med* 2012;31:1777-1782
 115. Nell S, Kist JW, Debray TP, de Keizer B, van Oostenbrugge TJ, Borel Rinkes IH, et al. Qualitative elastography can replace thyroid nodule fine-needle aspiration in patients with soft thyroid nodules. A systematic review and meta-analysis. *Eur J Radiol* 2015;84:652-661
 116. Rago T, Scutari M, Santini F, Loiacono V, Piaggi P, Di Coscio G, et al. Real-time elastosonography: useful tool for refining the presurgical diagnosis in thyroid nodules with indeterminate or nondiagnostic cytology. *J Clin Endocrinol Metab* 2010;95:5274-5280
 117. Choi WJ, Park JS, Koo HR, Kim SY, Chung MS, Tae K. Ultrasound elastography using carotid artery pulsation in the differential diagnosis of sonographically indeterminate thyroid nodules. *AJR Am J Roentgenol* 2015;204:396-401
 118. Amin MB, Edge SB, Greene FL, Byrd DR, Brookland RK, Washington MK, et al. *AJCC cancer staging manual*, 8th ed. New York: Springer International Publishing, 2017
 119. Andersen PE, Kinsella J, Loree TR, Shaha AR, Shah JP. Differentiated carcinoma of the thyroid with extrathyroidal extension. *Am J Surg* 1995;170:467-470
 120. Ito Y, Tomoda C, Urano T, Takamura Y, Miya A, Kobayashi K, et al. Prognostic significance of extrathyroid extension of papillary thyroid carcinoma: massive but not minimal extension affects the relapse-free survival. *World J Surg* 2006;30:780-786
 121. Kamaya A, Tahvildari AM, Patel BN, Willmann JK, Jeffrey RB, Desser TS. Sonographic detection of extracapsular extension in papillary thyroid cancer. *J Ultrasound Med* 2015;34:2225-2230
 122. Kim H, Kim JA, Son EJ, Youk JH, Chung TS, Park CS, et al. Preoperative prediction of the extrathyroidal extension of papillary thyroid carcinoma with ultrasonography versus MRI: a retrospective cohort study. *Int J Surg* 2014;12:544-548
 123. Kwak JY, Kim EK, Youk JH, Kim MJ, Son EJ, Choi SH, et al. Extrathyroid extension of well-differentiated papillary thyroid microcarcinoma on US. *Thyroid* 2008;18:609-614

124. Moon SJ, Kim DW, Kim SJ, Ha TK, Park HK, Jung SJ. Ultrasound assessment of degrees of extrathyroidal extension in papillary thyroid microcarcinoma. *Endocr Pract* 2014;20:1037-1043
125. Lee CY, Kim SJ, Ko KR, Chung KW, Lee JH. Predictive factors for extrathyroidal extension of papillary thyroid carcinoma based on preoperative sonography. *J Ultrasound Med* 2014;33:231-238
126. Choi JS, Chung WY, Kwak JY, Moon HJ, Kim MJ, Kim EK. Staging of papillary thyroid carcinoma with ultrasonography: performance in a large series. *Ann Surg Oncol* 2011;18:3572-3578
127. Park JS, Son KR, Na DG, Kim E, Kim S. Performance of preoperative sonographic staging of papillary thyroid carcinoma based on the sixth edition of the AJCC/UICC TNM classification system. *AJR Am J Roentgenol* 2009;192:66-72
128. Shimamoto K, Satake H, Sawaki A, Ishigaki T, Funahashi H, Imai T. Preoperative staging of thyroid papillary carcinoma with ultrasonography. *Eur J Radiol* 1998;29:4-10
129. Chung SR, Baek JH, Choi YJ, Sung TY, Song DE, Kim TY, et al. Sonographic assessment of the extent of extrathyroidal extension in thyroid cancer. *Korean J Radiol* 2020;21:1187-1195
130. Rim JH, Chong S, Ryu HS, Chung BM, Ahn HS. Feasibility study of ultrasonographic criteria for microscopic and macroscopic extra-thyroidal extension based on thyroid capsular continuity and tumor contour in patients with papillary thyroid carcinomas. *Ultrasound Med Biol* 2016;42:2391-2400
131. Ito Y, Miyauchi A, Oda H, Kobayashi K, Kihara M, Miya A. Revisiting low-risk thyroid papillary microcarcinomas resected without observation: was immediate surgery necessary? *World J Surg* 2016;40:523-528
132. Mulla M, Schulte KM. Central cervical lymph node metastases in papillary thyroid cancer: a systematic review of imaging-guided and prophylactic removal of the central compartment. *Clin Endocrinol (Oxf)* 2012;76:131-136
133. Rotstein L. The role of lymphadenectomy in the management of papillary carcinoma of the thyroid. *J Surg Oncol* 2009;99:186-188
134. Randolph GW, Duh QY, Heller KS, LiVolsi VA, Mandel SJ, Steward DL, et al. The prognostic significance of nodal metastases from papillary thyroid carcinoma can be stratified based on the size and number of metastatic lymph nodes, as well as the presence of extranodal extension. *Thyroid* 2012;22:1144-1152
135. Sivanandan R, Soo KC. Pattern of cervical lymph node metastases from papillary carcinoma of the thyroid. *Br J Surg* 2001;88:1241-1244
136. Leenhardt L, Erdogan MF, Hegedus L, Mandel SJ, Paschke R, Rago T, et al. 2013 European thyroid association guidelines for cervical ultrasound scan and ultrasound-guided techniques in the postoperative management of patients with thyroid cancer. *Eur Thyroid J* 2013;2:147-159
137. Yoo RE, Kim JH, Bae JM, Hwang I, Kang KM, Yun TJ, et al. Ultrasonographic indeterminate lymph nodes in preoperative thyroid cancer patients: malignancy risk and ultrasonographic findings predictive of malignancy. *Korean J Radiol* 2020;21:598-604
138. Sohn YM, Kwak JY, Kim EK, Moon HJ, Kim SJ, Kim MJ. Diagnostic approach for evaluation of lymph node metastasis from thyroid cancer using ultrasound and fine-needle aspiration biopsy. *AJR Am J Roentgenol* 2010;194:38-43
139. Rosário PW, de Faria S, Bicalho L, Alves MF, Borges MA, Purisch S, et al. Ultrasonographic differentiation between metastatic and benign lymph nodes in patients with papillary thyroid carcinoma. *J Ultrasound Med* 2005;24:1385-1389
140. Leboulleux S, Girard E, Rose M, Travagli JP, Sabbah N, Cailloou B, et al. Ultrasound criteria of malignancy for cervical lymph nodes in patients followed up for differentiated thyroid cancer. *J Clin Endocrinol Metab* 2007;92:3590-3594
141. Hwang HS, Orloff LA. Efficacy of preoperative neck ultrasound in the detection of cervical lymph node metastasis from thyroid cancer. *Laryngoscope* 2011;121:487-491
142. Ito Y, Jikuzono T, Higashiyama T, Asahi S, Tomoda C, Takamura Y, et al. Clinical significance of lymph node metastasis of thyroid papillary carcinoma located in one lobe. *World J Surg* 2006;30:1821-1828
143. Sywak M, Cornford L, Roach P, Stalberg P, Sidhu S, Delbridge L. Routine ipsilateral level VI lymphadenectomy reduces postoperative thyroglobulin levels in papillary thyroid cancer. *Surgery* 2006;140:1000-1005; discussion 1005-1007
144. Bardet S, Ciappuccini R, Quak E, Rame JP, Blanchard D, de Raucourt D, et al. Prognostic value of microscopic lymph node involvement in patients with papillary thyroid cancer. *J Clin Endocrinol Metab* 2015;100:132-140
145. Bardet S, Malville E, Rame JP, Babin E, Samama G, De Raucourt D, et al. Macroscopic lymph-node involvement and neck dissection predict lymph-node recurrence in papillary thyroid carcinoma. *Eur J Endocrinol* 2008;158:551-560
146. Cranshaw IM, Carnaille B. Micrometastases in thyroid cancer. An important finding? *Surg Oncol* 2008;17:253-258
147. Gemsjäger E, Perren A, Seifert B, Schüller G, Schweizer I, Heitz PU. Lymph node surgery in papillary thyroid carcinoma. *J Am Coll Surg* 2003;197:182-190
148. Ito Y, Tomoda C, Urano T, Takamura Y, Miya A, Kobayashi K, et al. Preoperative ultrasonographic examination for lymph node metastasis: usefulness when designing lymph node dissection for papillary microcarcinoma of the thyroid. *World J Surg* 2004;28:498-501
149. Aydoğan Bİ, Ünlütürk U, Ateş FSÖ, Erdoğan MF. Sonographic follow-up of patients with differentiated thyroid carcinoma: a comparison of the ultrasound elastography, power doppler ultrasound, and b-mode ultrasound features in detecting malignant lymph nodes. *Endocr Pract* 2019;25:1049-1055
150. Jiang W, Wei HY, Zhang HY, Zhuo QL. Value of contrast-

- enhanced ultrasound combined with elastography in evaluating cervical lymph node metastasis in papillary thyroid carcinoma. *World J Clin Cases* 2019;7:49-57
151. Jung WS, Kim JA, Son EJ, Youk JH, Park CS. Shear wave elastography in evaluation of cervical lymph node metastasis of papillary thyroid carcinoma: elasticity index as a prognostic implication. *Ann Surg Oncol* 2015;22:111-116
 152. Kim HJ, Choi IH, Jin SY, Park HK, Byun DW, Suh K, et al. Efficacy of shear-wave elastography for detecting postoperative cervical lymph node metastasis in papillary thyroid carcinoma. *Int J Endocrinol* 2018;2018:9382649
 153. Saadi R, LaRusso S, Vijay K, Goldenberg D. Elastography as a potential modality for screening cervical lymph nodes in patients with papillary thyroid cancer: a review of literature. *Ear Nose Throat J* 2018;97:31-39
 154. Chen L, Chen L, Liu J, Wang B, Zhang H. Value of qualitative and quantitative contrast-enhanced ultrasound analysis in preoperative diagnosis of cervical lymph node metastasis from papillary thyroid carcinoma. *J Ultrasound Med* 2020;39:73-81
 155. Hong YR, Luo ZY, Mo GQ, Wang P, Ye Q, Huang PT. Role of contrast-enhanced ultrasound in the pre-operative diagnosis of cervical lymph node metastasis in patients with papillary thyroid carcinoma. *Ultrasound Med Biol* 2017;43:2567-2575
 156. Tao L, Zhou W, Zhan W, Li W, Wang Y, Fan J. Preoperative prediction of cervical lymph node metastasis in papillary thyroid carcinoma via conventional and contrast-enhanced ultrasound. *J Ultrasound Med* 2020;39:2071-2080
 157. Zhang Y, Luo Y, Zhang M, Yang M, Zhang Y, Li J, et al. Value of contrast-enhanced ultrasound and conventional ultrasound in the diagnosis of papillary thyroid carcinoma with cervical lymph node metastases. *Zhongguo Yi Xue Ke Xue Yuan Xue Bao* 2017;39:177-182
 158. Lee S, Lee JY, Yoon RG, Kim JH, Hong HS. The value of microvascular imaging for triaging indeterminate cervical lymph nodes in patients with papillary thyroid carcinoma. *Cancers (Basel)* 2020;12:2839
 159. Robenshtok E, Fish S, Bach A, Domínguez JM, Shaha A, Tuttle RM. Suspicious cervical lymph nodes detected after thyroidectomy for papillary thyroid cancer usually remain stable over years in properly selected patients. *J Clin Endocrinol Metab* 2012;97:2706-2713
 160. Rondeau G, Fish S, Hann LE, Fagin JA, Tuttle RM. Ultrasonographically detected small thyroid bed nodules identified after total thyroidectomy for differentiated thyroid cancer seldom show clinically significant structural progression. *Thyroid* 2011;21:845-853
 161. Ha EJ, Baek JH, Na DG. Risk stratification of thyroid nodules on ultrasonography: current status and perspectives. *Thyroid* 2017;27:1463-1468
 162. Na DG, Kim DS, Kim SJ, Ryoo JW, Jung SL. Thyroid nodules with isolated macrocalcification: malignancy risk and diagnostic efficacy of fine-needle aspiration and core needle biopsy. *Ultrasonography* 2016;35:212-219
 163. Chung SR, Ahn HS, Choi YJ, Lee JY, Yoo RE, Lee YJ, et al. Diagnostic performance of the modified Korean thyroid imaging reporting and data system for thyroid malignancy: a multicenter validation study. *Korean J Radiol* 2021;22:1579-1586
 164. Na DG, Paik W, Cha J, Gwon HY, Kim SY, Yoo RE. Diagnostic performance of the modified Korean thyroid imaging reporting and data system for thyroid malignancy according to nodule size: a comparison with five society guidelines. *Ultrasonography* 2021;40:474-485
 165. Middleton WD, Teefey SA, Reading CC, Langer JE, Beland MD, Szabunio MM, et al. Comparison of performance characteristics of american college of radiology TI-RADS, Korean Society of thyroid radiology TIRADS, and American Thyroid Association guidelines. *AJR Am J Roentgenol* 2018;210:1148-1154
 166. Grani G, Lamartina L, Ascoli V, Bosco D, Biffoni M, Giacomelli L, et al. Reducing the number of unnecessary thyroid biopsies while improving diagnostic accuracy: toward the "right" TIRADS. *J Clin Endocrinol Metab* 2019;104:95-102
 167. Kim PH, Suh CH, Baek JH, Chung SR, Choi YJ, Lee JH. Diagnostic performance of four ultrasound risk stratification systems: a systematic review and meta-analysis. *Thyroid* 2020;30:1159-1168
 168. Hay ID. Papillary thyroid carcinoma. *Endocrinol Metab Clin North Am* 1990;19:545-576
 169. Mazzaferri EL, Jhiang SM. Long-term impact of initial surgical and medical therapy on papillary and follicular thyroid cancer. *Am J Med* 1994;97:418-428
 170. Machens A, Holzhausen HJ, Dralle H. The prognostic value of primary tumor size in papillary and follicular thyroid carcinoma. *Cancer* 2005;103:2269-2273
 171. Nguyen XV, Roy Choudhury K, Tessler FN, Hoang JK. Effect of tumor size on risk of metastatic disease and survival for thyroid cancer: implications for biopsy guidelines. *Thyroid* 2018;28:295-300
 172. Castellana M, Piccardo A, Virili C, Scappaticcio L, Grani G, Durante C, et al. Can ultrasound systems for risk stratification of thyroid nodules identify follicular carcinoma? *Cancer Cytopathol* 2020;128:250-259
 173. Hahn SY, Shin JH, Oh YL, Kim TH, Lim Y, Choi JS. Role of ultrasound in predicting tumor invasiveness in follicular variant of papillary thyroid carcinoma. *Thyroid* 2017;27:1177-1184
 174. Trimboli P, Castellana M, Piccardo A, Romanelli F, Grani G, Giovanella L, et al. The ultrasound risk stratification systems for thyroid nodule have been evaluated against papillary carcinoma. A meta-analysis. *Rev Endocr Metab Disord* 2021;22:453-460
 175. Sugitani I, Ito Y, Takeuchi D, Nakayama H, Masaki C, Shindo H, et al. Indications and strategy for active surveillance of adult low-risk papillary thyroid microcarcinoma: consensus statements from the Japan Association of Endocrine Surgery Task Force on management for papillary thyroid

- microcarcinoma. *Thyroid* 2021;31:183-192
176. Francis GL, Waguespack SG, Bauer AJ, Angelos P, Benvenega S, Cerutti JM, et al. Management guidelines for children with thyroid nodules and differentiated thyroid cancer. *Thyroid* 2015;25:716-759
 177. Ha EJ, Shin JH, Na DG, Jung SL, Lee YH, Paik W, et al. Comparison of the diagnostic performance of the modified Korean thyroid imaging reporting and data system for thyroid malignancy with three international guidelines. *Ultrasonography* 2021;40:594-601
 178. Brito JP, Ito Y, Miyauchi A, Tuttle RM. A clinical framework to facilitate risk stratification when considering an active surveillance alternative to immediate biopsy and surgery in papillary microcarcinoma. *Thyroid* 2016;26:144-149
 179. Medici M, Liu X, Kwong N, Angell TE, Marqusee E, Kim MI, et al. Long- versus short-interval follow-up of cytologically benign thyroid nodules: a prospective cohort study. *BMC Med* 2016;14:11
 180. Mohammadi M, Betel C, Burton KR, Higgins KM, Ghorab Z, Halperin IJ. Follow-up of benign thyroid nodules-can we do less? *Can Assoc Radiol J* 2019;70:62-67
 181. Nakamura H, Hirokawa M, Ota H, Kihara M, Miya A, Miyauchi A. Is an increase in thyroid nodule volume a risk factor for malignancy? *Thyroid* 2015;25:804-811
 182. Cibas ES, Ali SZ. The 2017 Bethesda system for reporting thyroid cytopathology. *Thyroid* 2017;27:1341-1346
 183. Gharib H, Papini E, Garber JR, Duick DS, Harrell RM, Hegedus L, et al. American Association of Clinical Endocrinologists, American College of Endocrinology, and Associazione Medici Endocrinologi medical guidelines for clinical practice for the diagnosis and management of thyroid nodules--2016 update. *Endocr Pract* 2016;22:622-639
 184. Hong MJ, Na DG, Baek JH, Sung JY, Kim JH. Cytology-ultrasonography risk-stratification scoring system based on fine-needle aspiration cytology and the Korean-thyroid imaging reporting and data system. *Thyroid* 2017;27:953-959
 185. Bongiovanni M, Spitale A, Faquin WC, Mazzucchelli L, Baloch ZW. The Bethesda system for reporting thyroid cytopathology: a meta-analysis. *Acta Cytol* 2012;56:333-339
 186. Samir AE, Vij A, Seale MK, Desai G, Halpern E, Faquin WC, et al. Ultrasound-guided percutaneous thyroid nodule core biopsy: clinical utility in patients with prior nondiagnostic fine-needle aspirate. *Thyroid* 2012;22:461-467
 187. Na DG, Kim JH, Sung JY, Baek JH, Jung KC, Lee H, et al. Core-needle biopsy is more useful than repeat fine-needle aspiration in thyroid nodules read as nondiagnostic or atypia of undetermined significance by the Bethesda system for reporting thyroid cytopathology. *Thyroid* 2012;22:468-475
 188. Choi SH, Baek JH, Lee JH, Choi YJ, Hong MJ, Song DE, et al. Thyroid nodules with initially non-diagnostic, fine-needle aspiration results: comparison of core-needle biopsy and repeated fine-needle aspiration. *Eur Radiol* 2014;24:2819-2826
 189. Na DG, Baek JH, Jung SL, Kim JH, Sung JY, Kim KS, et al. Core needle biopsy of the thyroid: 2016 consensus statement and recommendations from Korean Society of Thyroid Radiology. *Korean J Radiol* 2017;18:217-237
 190. Singh RS, Wang HH. Timing of repeat thyroid fine-needle aspiration in the management of thyroid nodules. *Acta Cytol* 2011;55:544-548
 191. Lubitz CC, Nagarkatti SS, Faquin WC, Samir AE, Hassan MC, Barbesino G, et al. Diagnostic yield of nondiagnostic thyroid nodules is not altered by timing of repeat biopsy. *Thyroid* 2012;22:590-594
 192. Deniwar A, Hammad AY, Ali DB, Alsaleh N, Lahlouh M, Sholl AB, et al. Optimal timing for a repeat fine-needle aspiration biopsy of thyroid nodule following an initial nondiagnostic fine-needle aspiration. *Am J Surg* 2017;213:433-437
 193. Ha EJ, Baek JH, Lee JH, Song DE, Kim JK, Shong YK, et al. Sonographically suspicious thyroid nodules with initially benign cytologic results: the role of a core needle biopsy. *Thyroid* 2013;23:703-708
 194. Kim SY, Han KH, Moon HJ, Kwak JY, Chung WY, Kim EK. Thyroid nodules with benign findings at cytologic examination: results of long-term follow-up with US. *Radiology* 2014;271:272-281
 195. Rosário PW, Calsolari MR. What is the best criterion for repetition of fine-needle aspiration in thyroid nodules with initially benign cytology? *Thyroid* 2015;25:1115-1120
 196. Maino F, Bufano A, Dalmazio G, Campanile M, Pilli T, Forleo R, et al. Validation of American Thyroid Association ultrasound risk-adapted approach for repeating cytology in benign thyroid nodules. *Thyroid* 2021;31:446-451
 197. Ng DL, van Zante A, Griffin A, Hills NK, Ljung BM. A large thyroid fine needle aspiration biopsy cohort with long-term population-based follow-up. *Thyroid* 2021;31:1086-1095
 198. Carrillo JF, Frias-Mendivil M, Ochoa-Carrillo FJ, Ibarra M. Accuracy of fine-needle aspiration biopsy of the thyroid combined with an evaluation of clinical and radiologic factors. *Otolaryngol Head Neck Surg* 2000;122:917-921
 199. Pinchot SN, Al-Wagih H, Schaefer S, Sippel R, Chen H. Accuracy of fine-needle aspiration biopsy for predicting neoplasm or carcinoma in thyroid nodules 4 cm or larger. *Arch Surg* 2009;144:649-655
 200. Albuja-Cruz MB, Goldfarb M, Gondek SS, Allan BJ, Lew JI. Reliability of fine-needle aspiration for thyroid nodules greater than or equal to 4 cm. *J Surg Res* 2013;181:6-10
 201. Yoon JH, Kwak JY, Moon HJ, Kim MJ, Kim EK. The diagnostic accuracy of ultrasound-guided fine-needle aspiration biopsy and the sonographic differences between benign and malignant thyroid nodules 3 cm or larger. *Thyroid* 2011;21:993-1000
 202. Shrestha M, Crothers BA, Burch HB. The impact of thyroid nodule size on the risk of malignancy and accuracy of fine-needle aspiration: a 10-year study from a single institution. *Thyroid* 2012;22:1251-1256
 203. Ahn HS, Na DG, Baek JH, Sung JY, Kim JH. False negative

- rate of fine-needle aspiration in thyroid nodules: impact of nodule size and ultrasound pattern. *Head Neck* 2019;41:967-973
204. Nou E, Kwong N, Alexander LK, Cibas ES, Marqusee E, Alexander EK. Determination of the optimal time interval for repeat evaluation after a benign thyroid nodule aspiration. *J Clin Endocrinol Metab* 2014;99:510-516
 205. Ho AS, Sarti EE, Jain KS, Wang H, Nixon IJ, Shaha AR, et al. Malignancy rate in thyroid nodules classified as Bethesda category III (AUS/FLUS). *Thyroid* 2014;24:832-839
 206. Faquin WC, Baloch ZW. Fine-needle aspiration of follicular patterned lesions of the thyroid: diagnosis, management, and follow-up according to National Cancer Institute (NCI) recommendations. *Diagn Cytopathol* 2010;38:731-739
 207. Sullivan PS, Hirschowitz SL, Fung PC, Apple SK. The impact of atypia/follicular lesion of undetermined significance and repeat fine-needle aspiration: 5 years before and after implementation of the Bethesda System. *Cancer Cytopathol* 2014;122:866-872
 208. Allen L, Al Afif A, Rigby MH, Bullock MJ, Trites J, Taylor SM, et al. The role of repeat fine needle aspiration in managing indeterminate thyroid nodules. *J Otolaryngol Head Neck Surg* 2019;48:16
 209. Evranos Ogmen B, Aydin C, Kilinc I, Aksoy Altinboga A, Ersoy R, Cakir B. Can repeat biopsies change the prognoses of AUS/FLUS nodule? *Eur Thyroid J* 2020;9:92-98
 210. Pyo JS, Sohn JH, Kang G. Core needle biopsy is a more conclusive follow-up method than repeat fine needle aspiration for thyroid nodules with initially inconclusive results: a systematic review and meta-analysis. *J Pathol Transl Med* 2016;50:217-224
 211. Choi YJ, Baek JH, Suh CH, Shim WH, Jeong B, Kim JK, et al. Core-needle biopsy versus repeat fine-needle aspiration for thyroid nodules initially read as atypia/follicular lesion of undetermined significance. *Head Neck* 2017;39:361-369
 212. Jung SM, Koo HR, Jang KS, Chung MS, Song CM, Ji YB, et al. Comparison of core-needle biopsy and repeat fine-needle aspiration for thyroid nodules with inconclusive initial cytology. *Eur Arch Otorhinolaryngol* 2021;278:3019-3025
 213. Larcher de Almeida AM, Delfim RLC, Vidal APA, Chaves MCD, Santiago ACL, Gianotti MF, et al. Combining the American Thyroid Association's ultrasound classification with cytological subcategorization improves the assessment of malignancy risk in indeterminate thyroid nodules. *Thyroid* 2021;31:922-932
 214. Słowińska-Klencka D, Wysocka-Konieczna K, Klencki M, Popowicz B. Diagnostic value of six thyroid imaging reporting and data systems (TIRADS) in cytologically equivocal thyroid nodules. *J Clin Med* 2020;9:2281
 215. Hyeon J, Ahn S, Shin JH, Oh YL. The prediction of malignant risk in the category "atypia of undetermined significance/follicular lesion of undetermined significance" of the Bethesda System for Reporting Thyroid Cytopathology using subcategorization and BRAF mutation results. *Cancer Cytopathol* 2014;122:368-376
 216. Wu HH, Inman A, Cramer HM. Subclassification of "atypia of undetermined significance" in thyroid fine-needle aspirates. *Diagn Cytopathol* 2014;42:23-29
 217. Rosario PW. Thyroid nodules with atypia or follicular lesions of undetermined significance (Bethesda Category III): importance of ultrasonography and cytological subcategory. *Thyroid* 2014;24:1115-1120
 218. Maia FF, Matos PS, Pavin EJ, Zantut-Wittmann DE. Thyroid imaging reporting and data system score combined with Bethesda system for malignancy risk stratification in thyroid nodules with indeterminate results on cytology. *Clin Endocrinol (Oxf)* 2015;82:439-444
 219. Yoon JH, Kwon HJ, Kim EK, Moon HJ, Kwak JY. Subcategorization of atypia of undetermined significance/follicular lesion of undetermined significance (AUS/FLUS): a study applying thyroid imaging reporting and data system (TIRADS). *Clin Endocrinol (Oxf)* 2016;85:275-282
 220. Baser H, Cakir B, Topaloglu O, Alkan A, Polat SB, Dogan HT, et al. Diagnostic accuracy of thyroid imaging reporting and data system in the prediction of malignancy in nodules with atypia and follicular lesion of undetermined significance cytologies. *Clin Endocrinol (Oxf)* 2017;86:584-590
 221. Bernet V, Hupart KH, Parangi S, Woeber KA. AACE/ACE disease state commentary: molecular diagnostic testing of thyroid nodules with indeterminate cytopathology. *Endocr Pract* 2014;20:360-363
 222. Ferris RL, Baloch Z, Bernet V, Chen A, Fahey TJ 3rd, Ganly I, et al. American Thyroid Association statement on surgical application of molecular profiling for thyroid nodules: current impact on perioperative decision making. *Thyroid* 2015;25:760-768
 223. NCCN. NCCN guidelines for patients. Thyroid cancer. NCCN.org Web site. <https://www.nccn.org/patients/guidelines/content/PDF/thyroid-patient.pdf>. Accessed September 1, 2021
 224. Kim M, Chung SR, Jeon MJ, Han M, Lee JH, Song DE, et al. Determining whether tumor volume doubling time and growth rate can predict malignancy after delayed diagnostic surgery of follicular neoplasm. *Thyroid* 2019;29:1418-1424
 225. Chung SR, Baek JH, Choi YJ, Sung TY, Song DE, Kim TY, et al. The relationship of thyroid nodule size on malignancy risk according to histological type of thyroid cancer. *Acta Radiol* 2020;61:620-628
 226. Tuttle RM, Lemar H, Burch HB. Clinical features associated with an increased risk of thyroid malignancy in patients with follicular neoplasia by fine-needle aspiration. *Thyroid* 1998;8:377-383
 227. Ibrahim Y, Mohamed SE, Deniwar A, Al-Qurayshi ZH, Khan AN, Moroz K, et al. The impact of thyroid nodule size on the risk of malignancy in follicular neoplasms. *Anticancer Res* 2015;35:1635-1639
 228. Nikiforova MN, Mercurio S, Wald AI, Barbi de Moura M, Callenberg K, Santana-Santos L, et al. Analytical

- performance of the ThyroSeq v3 genomic classifier for cancer diagnosis in thyroid nodules. *Cancer* 2018;124:1682-1690
229. Patel KN, Angell TE, Babiartz J, Barth NM, Blevins T, Duh QY, et al. Performance of a genomic sequencing classifier for the preoperative diagnosis of cytologically indeterminate thyroid nodules. *JAMA Surg* 2018;153:817-824
 230. Khan TM, Zeiger MA. Thyroid nodule molecular testing: is it ready for prime time? *Front Endocrinol (Lausanne)* 2020;11:590128
 231. Huang BL, Chabot JA, Lee JA, Kuo JH. A stepwise analysis of the diagnostic algorithm for the prediction of malignancy in thyroid nodules. *Surgery* 2020;167:28-33
 232. Kwak JY, Kim EK, Kim MJ, Hong SW, Choi SH, Son EJ, et al. The role of ultrasound in thyroid nodules with a cytology reading of "suspect for papillary thyroid carcinoma". *Thyroid* 2008;18:517-522
 233. Debnam JM, Guha-Thakurta N, Sun J, Wei W, Zafereo ME, Cabanillas ME, et al. Distinguishing recurrent thyroid cancer from residual nonmalignant thyroid tissue using multiphasic multidetector CT. *AJNR Am J Neuroradiol* 2020;41:844-851
 234. Expert Panel on Neurological Imaging; Hoang JK, Oldan JD, Mandel SJ, Policeni B, Agarwal V, Burns J, et al. ACR appropriateness criteria® thyroid disease. *J Am Coll Radiol* 2019;16:S300-S314
 235. Mishra A, Pradhan PK, Gambhir S, Sabaretnam M, Gupta A, Babu S. Preoperative contrast-enhanced computerized tomography should not delay radioiodine ablation in differentiated thyroid carcinoma patients. *J Surg Res* 2015;193:731-737
 236. Padovani RP, Kasamatsu TS, Nakabashi CC, Camacho CP, Andreoni DM, Malouf EZ, et al. One month is sufficient for urinary iodine to return to its baseline value after the use of water-soluble iodinated contrast agents in post-thyroidectomy patients requiring radioiodine therapy. *Thyroid* 2012;22:926-930
 237. Sohn SY, Choi JH, Kim NK, Joung JY, Cho YY, Park SM, et al. The impact of iodinated contrast agent administered during preoperative computed tomography scan on body iodine pool in patients with differentiated thyroid cancer preparing for radioactive iodine treatment. *Thyroid* 2014;24:872-877
 238. Yeh MW, Bauer AJ, Bernet VA, Ferris RL, Loevner LA, Mandel SJ, et al. American Thyroid Association statement on preoperative imaging for thyroid cancer surgery. *Thyroid* 2015;25:3-14
 239. Park JE, Lee JH, Ryu KH, Park HS, Chung MS, Kim HW, et al. Improved diagnostic accuracy using arterial phase CT for lateral cervical lymph node metastasis from papillary thyroid cancer. *AJNR Am J Neuroradiol* 2017;38:782-788
 240. Cho SJ, Suh CH, Baek JH, Chung SR, Choi YJ, Lee JH. Diagnostic performance of CT in detection of metastatic cervical lymph nodes in patients with thyroid cancer: a systematic review and meta-analysis. *Eur Radiol* 2019;29:4635-4647
 241. Lee Y, Kim JH, Baek JH, Jung SL, Park SW, Kim J, et al. Value of CT added to ultrasonography for the diagnosis of lymph node metastasis in patients with thyroid cancer. *Head Neck* 2018;40:2137-2148
 242. Kim HK, Ha EJ, Han M, Lee J, Soh EY. Reoperations for structurally persistent or recurrent disease after thyroidectomy: analysis via preoperative CT. *Sci Rep* 2020;10:12376
 243. Choi YJ, Lee JH, Yoon DH, Kim HJ, Seo KJ, Do KH, et al. Effect of an arm traction device on image quality and radiation exposure during neck CT: a prospective study. *AJNR Am J Neuroradiol* 2018;39:151-155
 244. Kranz PG, Wylie JD, Hoang JK, Kosinski AS. Effect of the CT table strap on radiation exposure and image quality during cervical spine CT. *AJNR Am J Neuroradiol* 2014;35:1870-1876
 245. Wirth S, Meindl T, Treitl M, Pfeifer KJ, Reiser M. Comparison of different patient positioning strategies to minimize shoulder girdle artifacts in head and neck CT. *Eur Radiol* 2006;16:1757-1762
 246. Takeyama N, Ohgiya Y, Hayashi T, Takahashi T, Takasu D, Nakashima J, et al. Comparison of different volumes of saline flush in the assessment of perivenous artefacts in the subclavian vein during cervical CT angiography. *Br J Radiol* 2011;84:427-434
 247. de Monyé C, Cademartiri F, de Weert TT, Siepmann DA, Dippel DW, van Der Lugt A. Sixteen-detector row CT angiography of carotid arteries: comparison of different volumes of contrast material with and without a bolus chaser. *Radiology* 2005;237:555-562
 248. Yeom JA, Roh J, Jeong YJ, Lee JC, Kim HY, Suh YJ, et al. Ultra-low-dose neck CT with low-dose contrast material for preoperative staging of thyroid cancer: image quality and diagnostic performance. *AJR Am J Roentgenol* 2019;212:748-754
 249. Ahn JE, Lee JH, Yi JS, Shong YK, Hong SJ, Lee DH, et al. Diagnostic accuracy of CT and ultrasonography for evaluating metastatic cervical lymph nodes in patients with thyroid cancer. *World J Surg* 2008;32:1552-1558
 250. Kim E, Park JS, Son KR, Kim JH, Jeon SJ, Na DG. Preoperative diagnosis of cervical metastatic lymph nodes in papillary thyroid carcinoma: comparison of ultrasound, computed tomography, and combined ultrasound with computed tomography. *Thyroid* 2008;18:411-418
 251. Suh CH, Baek JH, Choi YJ, Lee JH. Performance of CT in the preoperative diagnosis of cervical lymph node metastasis in patients with papillary thyroid cancer: a systematic review and meta-analysis. *AJNR Am J Neuroradiol* 2017;38:154-161
 252. Yang SY, Shin JH, Hahn SY, Lim Y, Hwang SY, Kim TH, et al. Comparison of ultrasonography and CT for preoperative nodal assessment of patients with papillary thyroid cancer: diagnostic performance according to primary tumor size. *Acta Radiol* 2020;61:21-27
 253. Lesnik D, Cunnane ME, Zurakowski D, Acar GO, Ecevit C, Mace A, et al. Papillary thyroid carcinoma nodal surgery directed by a preoperative radiographic map utilizing CT scan and

- ultrasound in all primary and reoperative patients. *Head Neck* 2014;36:191-202
254. Yoo RE, Kim JH, Hwang I, Kang KM, Yun TJ, Choi SH, et al. Added value of computed tomography to ultrasonography for assessing LN metastasis in preoperative patients with thyroid cancer: node-by-node correlation. *Cancers (Basel)* 2020;12:1190
 255. Bongers PJ, Verzijl R, Dzingala M, Vriens MR, Yu E, Pasternak JD, et al. Preoperative computed tomography changes surgical management for clinically low-risk well-differentiated thyroid cancer. *Ann Surg Oncol* 2019;26:4439-4444
 256. Lee DH, Kim YK, Yu HW, Choi JY, Park SY, Moon JH. Computed tomography for detecting cervical lymph node metastasis in patients who have papillary thyroid microcarcinoma with tumor characteristics appropriate for active surveillance. *Thyroid* 2019;29:1653-1659
 257. Shindo ML, Caruana SM, Kandil E, McCaffrey JC, Orloff LA, Porterfield JR, et al. Management of invasive well-differentiated thyroid cancer: an American Head and Neck Society consensus statement. AHNS consensus statement. *Head Neck* 2014;36:1379-1390
 258. Seo YL, Yoon DY, Lim KJ, Cha JH, Yun EJ, Choi CS, et al. Locally advanced thyroid cancer: can CT help in prediction of extrathyroidal invasion to adjacent structures? *AJR Am J Roentgenol* 2010;195:W240-W244
 259. Takashima S, Takayama F, Wang J, Kobayashi S, Kadoya M. Using MR imaging to predict invasion of the recurrent laryngeal nerve by thyroid carcinoma. *AJR Am J Roentgenol* 2003;180:837-842
 260. Wang J, Takashima S, Matsushita T, Takayama F, Kobayashi T, Kadoya M. Esophageal invasion by thyroid carcinomas: prediction using magnetic resonance imaging. *J Comput Assist Tomogr* 2003;27:18-25
 261. Wang JC, Takashima S, Takayama F, Kawakami S, Saito A, Matsushita T, et al. Tracheal invasion by thyroid carcinoma: prediction using MR imaging. *AJR Am J Roentgenol* 2001;177:929-936
 262. Hong EK, Kim JH, Lee J, Yoo RE, Kim SC, Kim MJ, et al. Diagnostic value of computed tomography combined with ultrasonography in detecting cervical recurrence in patients with thyroid cancer. *Head Neck* 2019;41:1206-1212