



Korean Thyroid Imaging Reporting and Data System: Current Status, Challenges, and Future Perspectives

Eun Ju Ha¹, Dong Gyu Na², Jung Hwan Baek³

¹Department of Radiology, Ajou University School of Medicine, Suwon, Korea; ²Department of Radiology, GangNeung Asan Hospital, University of Ulsan College of Medicine, Gangneung, Korea; ³Department of Radiology and Research Institute of Radiology, University of Ulsan College of Medicine, Asan Medical Center, Seoul, Korea

The Korean Thyroid Imaging Reporting and Data System (K-TIRADS) is an ultrasound-based risk stratification system for thyroid nodules that has been widely applied for the diagnosis and management of thyroid nodules since 2016. This review article provides an overview of the use of the K-TIRADS compared with other risk stratification systems. Moreover, this review describes the challenges in the clinical application of the K-TIRADS, as well as future development directions toward the personalized management of patients with thyroid nodules.

Keywords: *Fine-needle aspiration; Thyroid cancer; Thyroid imaging reporting and data system; Thyroid nodules; Ultrasonography*

INTRODUCTION

The Korean Thyroid Imaging Reporting and Data System (K-TIRADS) is an ultrasound (US)-based risk stratification system (RSS) for thyroid nodules that was endorsed by the Korean Society of Thyroid Radiology (KSThR) and Korean Thyroid Association (KTA) in 2016 [1,2]. The K-TIRADS is based on the initial recommendations by the KSThR in 2011 for the US-based diagnosis and management of thyroid nodules [3]. It was developed to provide a standardized guideline given the rapidly increasing numbers of US examinations and US-guided biopsies for thyroid nodules. The K-TIRADS uses a pattern-based system instead of an individual US feature-based system or a point-based system [4]. Compared with the individual US feature-based three-tier risk categorization system initially proposed by the

KSThR [3], the K-TIRADS reduces unnecessary biopsies of benign nodules and increases the diagnostic efficacy of biopsies of thyroid nodules [5]. The K-TIRADS and KSThR guidelines include terminologies, definitions, an image atlas for US lexicons, biopsy criteria for thyroid nodules, and expanded recommendations for the risk stratification of cervical lymph nodes and US-based management of thyroid nodules after biopsy.

Since its publication, many studies have investigated the diagnostic performance of the K-TIRADS for thyroid cancer compared with other RSSs and have reported on its clinical applications [6-12]. This review summarizes the current evidence for the clinical application of the K-TIRADS and highlights the challenging issues and future directions toward the personalized management of patients with thyroid nodules.

Clinical Role of a US-Based RSS or TIRADS

US-based RSSs or TIRADSs have become increasingly important for the diagnosis and management of thyroid nodules. The clinical roles of US-based RSSs have expanded from simply estimating the malignancy risk of a nodule to US-based management of patients with thyroid nodules. US-based RSSs have four major clinical roles: assessing the malignancy risk of nodules, assessing the US features

Received: February 2, 2021 **Revised:** April 28, 2021

Accepted: May 2, 2021

Corresponding author: Dong Gyu Na, MD, Department of Radiology, GangNeung Asan Hospital, University of Ulsan College of Medicine, 38 Bangdong-gil, Sacheon-myeon, Gangneung 25440, Korea.

• E-mail: nndgna@gmail.com

This is an Open Access article distributed under the terms of the Creative Commons Attribution Non-Commercial License (<https://creativecommons.org/licenses/by-nc/4.0>) which permits unrestricted non-commercial use, distribution, and reproduction in any medium, provided the original work is properly cited.

of aggressive thyroid cancer, selecting patients eligible for biopsy, and managing thyroid nodules before and after biopsy. However, a US-based RSS should include an assessment of cervical lymph node metastasis or gross extrathyroidal extension (ETE), which is crucial for detecting aggressive thyroid cancers requiring surgical treatment. In addition, US-based RSSs are clinically used to select patients eligible for biopsy and to rule out thyroid cancer. When used as a triage tool, US-based RSSs require an appropriate sensitivity for detecting thyroid cancer in patients with clinically significant thyroid nodules > 1 cm and contribute to reducing unnecessary biopsies of benign nodules [13]. This system also has an important role in the management of nodules that do not meet the biopsy criteria and nodules with benign or inconclusive biopsy results in clinical practice [1,14-16].

US Lexicons of K-TIRADS Compared with Other RSSs

Many international societies have proposed various US-based RSSs or TIRADSs. Among them, the KSThR/KTA [1], American College of Radiology (ACR) [16], and European Thyroid Association (EU) [17] proposed their own definitions of each US lexicon for describing the sonographic characteristics of thyroid nodules by dedicated radiologists, whereas the American Thyroid Association (ATA) [14] and American Association of Clinical Endocrinologists/American College of Endocrinology/Associazione Medici Endocrinologi (AACE/ACE/AME) [15] did not. Some differences exist in the definitions of US lexicons among the K-TIRADS [1], ACR-TIRADS [16], and EU-TIRADS [17]. These include definitions for composition, including spongiform appearance, echogenicity, and US image plane for a taller-than-wide shape (nonparallel orientation) (Table 1) [11]. According to the K-TIRADS, a nodule without any obvious cystic components is defined as a solid nodule and a nodule with minimal cystic change (< 10%) is categorized as a predominantly solid nodule. However, a nodule with minimal cystic change is categorized as a solid nodule according to the EU-TIRADS and may be categorized as a solid nodule according to the ACR-TIRADS [18]. A previous study showed that nodules with minimal cystic changes have a low risk of malignancy, similar to partially cystic nodules, regardless of echogenicity or the presence of suspicious US features [19]. According to the K-TIRADS, a spongiform nodule is defined as having microcystic changes (> 50%)

in the isoechoic soft-tissue component. This differs from the ACR-TIRADS in which spongiform nodules also include hypoechoic nodules and from the EU-TIRADS in which a spongiform nodule is more strictly defined as having tiny cystic spaces entirely separated by numerous isoechoic septa. In the K-TIRADS and ACR-TIRADS, the echogenicity of a nodule with both isohyperechoic and hypoechoic solid components is determined by the predominant echogenicity. However, the EU-TIRADS classifies nodules with any hypoechoic tissues as mildly hypoechoic. A recent study showed that the malignancy risk of predominantly hypoechoic nodules was similar to that of nodules with homogeneous hypoechoic and higher than that of predominantly isohyperechoic nodules [20]. This suggests that the predominant echogenicity is more predictive of the malignancy risk in nodules with mixed echogenicity. The presence of a nonparallel orientation (taller-than-wide shape) is defined in both the transverse and longitudinal imaging planes by the K-TIRADS but only in the transverse plane by the ACR-TIRADS. These differences in US lexicons and descriptors may be controversial and might affect the classification of nodules according to US-based RSSs. The appropriate definitions of US lexicons should be determined by their clinical utility for feasible clinical application, effective risk stratification, and enhancement of interobserver agreement.

Structure of K-TIRADS Compared with Other RSSs

The malignancy risk of a nodule cannot be accurately estimated by a single US predictor and should be assessed using a combination of several US features. The predictive ability of suspicious US features [microcalcification, spiculated or microlobulated margins, and nonparallel (taller-than-wide) orientation] with relatively high specificity for malignancy demonstrates a heterogeneous dependency on the composition and echogenicity of the nodules [4,5]. The presence of suspicious US features has been associated with a high malignancy risk (79%) in solid hypoechoic nodules but with an intermediate risk (25%) in partially cystic or isohyperechoic nodules [4,5]. These results provided a basis for the K-TIRADS, which has a pattern-based structure developed by stratifying the malignancy risk of a nodule using a combination of composition, echogenicity, and suspicious US features (Fig. 1). The widely used US-based RSSs at present are

Table 1. Differences in the Definitions of US Lexicons Used in the Risk Stratification Systems

Ultrasound Lexicons	ACR-TIRADS	EU-TIRADS	K-TIRADS
Composition			
Solid	Solid or almost completely solid	Solid with < 10% of cystic portion	Solid with no obvious cystic component
Spongiform	Composed predominantly (> 50%) of small cystic spaces (regardless of echogenicity)	Entirely tiny cystic spaces separated by numerous isoechoic septa	Microcystic changes > 50% in isoechoic soft-tissue component
Echogenicity			
Marked hypoechoogenicity	Decreased echogenicity relative to strap muscle	Hypoechoic relative to strap muscle	Hypoechoic relative to anterior neck muscle
Mixed echogenicity	Predominant echogenicity of the solid component	Presence of any hypoechoic tissue indicates mildly hypoechoic nodule	Predominant echogenicity of the solid component
Shape (orientation)			
Image plane for evaluation	Transverse	Transverse or longitudinal	Transverse or longitudinal
Margin			
Irregular	Lobulated or irregular	Irregular (spiculated, microlobulated)	Spiculated or microlobulated
Echogenic foci			
Microcalcification (punctate echogenic foci)	Punctate echogenic foci without posterior shadowing in solid components	Echogenic foci approximately 1 mm without posterior shadowing in the solid component	Echogenic foci of 1 mm or less in the solid component
Macrocalcification	Coarse echogenic foci accompanied by acoustic shadowing	> 1-mm coarse and large calcification with posterior acoustic shadowing	Echogenic foci > 1 mm with posterior acoustic shadowing
Isolated macrocalcification	Calcifications with strong acoustic shadowing that precludes or limits assessment of internal characteristics	Entirely calcified nodule	Entirely calcified nodule without an identified solid component
Intracystic echogenic foci with comet-tail artifacts	Large comet-tail artifacts (V-shaped, > 1 mm) in cystic component	Echogenic foci with comet like echogenic tails within cystic component	Intracystic echogenic foci with comet-tail artifacts

ACR-TIRADS = American College of Radiology TIRADS, EU-TIRADS = European TIRADS, K-TIRADS = Korean TIRADS, TIRADS = Thyroid Imaging Reporting and Data System, US = ultrasonography

categorized as pattern-based systems (K-TIRADS [1] and the ATA system [14]), combined US feature- and pattern-based systems (EU-TIRADS [17] and the AACE/ACE/AME system [15]), and point-based systems (ACR-TIRADS [16] and Chinese TIRADS [21]) (Table 2).

Among them, the K-TIRADS has several advantages for nodule risk stratification. First, it is intuitive for assessing the US pattern of a nodule and is a clinically feasible system that is simple to use. The pattern-based system is easily applied clinically for classifying nodules during real-time US examinations. Second, all thyroid nodules can be categorized by the K-TIRADS. Isoechoic nodules with suspicious US features (irregular margin, microcalcification,

and a taller-than-wide shape) are not categorized by the ATA system. An isolated macrocalcification is defined as an entirely calcified nodule with posterior acoustic shadowing in which no soft-tissue component is identified owing to dense shadowing on the US image and results mostly in central coarse macrocalcifications [22-24]. Such macrocalcifications are classified as intermediate suspicious nodules by the K-TIRADS [1] and as moderately suspicious nodules by the ACR-TIRADS [8,16], but are unclassified in other RSSs. Finally, the high suspicion category (category 5) of the K-TIRADS is highly predictive of malignancy [7] and is appropriate for determining the need for active surveillance in subcentimeter nodules.

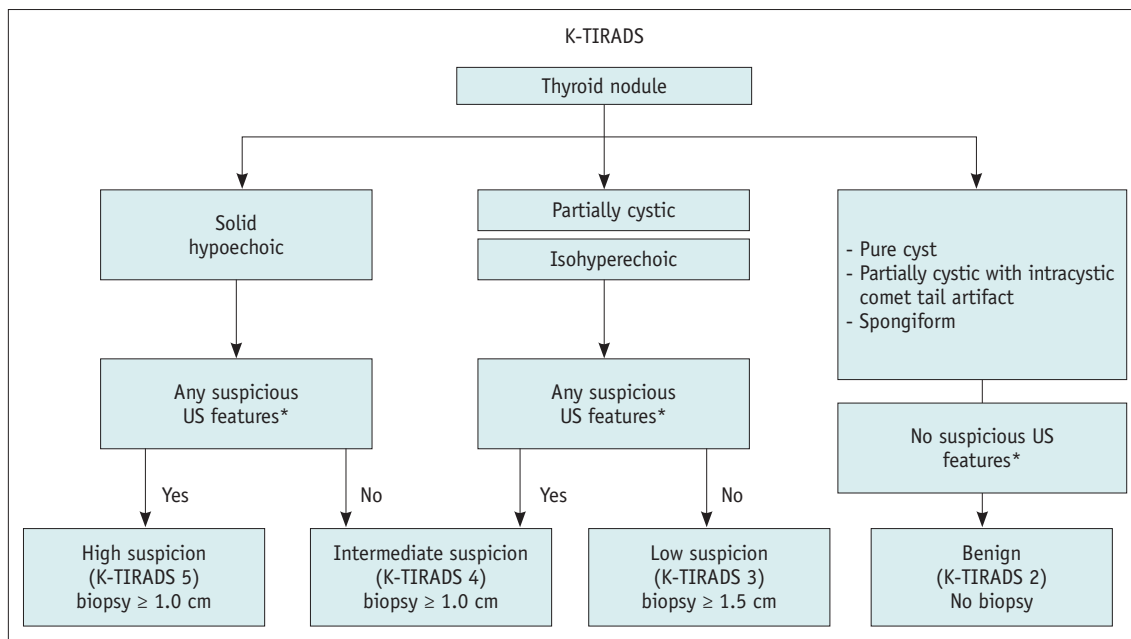


Fig. 1. Flowchart showing the categorization of nodules in the K-TIRADS. Although biopsy is not routinely recommended for subcentimeter K-TIRADS 5 nodules without features of aggressive thyroid cancer, biopsy may be selectively performed for subcentimeter K-TIRADS nodules > 5 mm in candidates for active surveillance, to avoid unnecessary active surveillance in patients with benign nodules. Biopsy is not routinely recommended for diagnostic purposes for K-TIRADS 2 nodules; however, biopsy may be necessary before ablation therapy or surgery. *Microcalcification, nonparallel orientation (taller than wide shape), spiculated/microlobulated margin. K-TIRADS = Korean Thyroid Imaging Reporting and Data System, US = ultrasonography

Diagnostic Performance of K-TIRADS Compared with Other RSSs

The biopsy size thresholds and suggested malignancy risks according to the categories of the RSSs are summarized in Table 2. Previous studies have estimated the malignancy risk of nodules categorized by the K-TIRADS [4,5,10-12]. The estimated malignancy risk was 0–2% for K-TIRADS category 2 (benign), 2.4–7.8% for category 3 (low suspicion), 13.4–33.7% for category 4 (intermediate suspicion), and 66.1–79.6% for category 5 (high suspicion) nodules. These values are consistent with the range of malignancy risks suggested by the K-TIRADS. The estimated malignancy risk may be influenced by the prevalence and histologic type of the malignant tumors, disease spectrum of a study population, and reference standards.

Recent comparative studies have consistently shown that the biopsy criteria of the K-TIRADS for nodules ≥ 1 cm had the highest sensitivity (91.7–100%) and lowest specificity (15.4–28.7%) for diagnosing malignant tumors, but the highest rate of unnecessary biopsy of benign nodules (71.3–84.6%), among the RSSs [6-12]. Meanwhile, the biopsy criteria of the ACR-TIRADS had the lowest sensitivity, highest specificity, and lowest rate of unnecessary biopsy of

benign nodules. The EU-TIRADS and AACE/ACE/AME system had intermediate sensitivity and specificity. The ATA system had a similar sensitivity and specificity to the K-TIRADS when unclassified nodules were categorized as intermediate suspicious nodules [25]. These results suggest the need for modifying the K-TIRADS to reduce the unnecessary biopsy rate while maintaining an appropriate sensitivity for diagnosing malignancy in small (1–2 cm) thyroid nodules. The differences in diagnostic performance among the RSSs are mainly attributed to differences in the size threshold for biopsy rather than to differences in the structure (pattern-based vs. point-based system) or US criteria for nodule classification [10,11,25]. The diagnostic performances of the different RSSs were similar at the same size threshold for biopsy in simulation studies [10,11,25], and the diagnostic performance estimated by each classification category was comparable among the RSSs [26].

What is the Optimal Sensitivity for Detecting Malignancy While Avoiding Unnecessary Biopsies?

The most desirable biopsy criteria in US-based RSSs should reduce unnecessary biopsies as much as possible

Table 2. US Features, Biopsy Size Thresholds and Malignancy Risk according to the Categories of the K-TIRADS and Other Risk Stratification Systems

Risk Stratification System	Sonographic Features	Suggested Risk of Malignancy (%)	Nodule Size Threshold for Biopsy
ACR-TIRADS			
Highly suspicious	7 points or more*	> 20	≥ 1.0 cm
Moderately suspicious	4 to 6 points*	5-20	≥ 1.5 cm
Mildly suspicious	3 points*	5	≥ 2.5 cm
Not suspicious	2 points*	< 2	Not indicated
Benign	0 points*	< 2	Not indicated
EU-TIRADS			
High-risk	At least 1 of the following features of high suspicion: irregular shape, irregular margins, microcalcifications, marked hypoechoogenicity (and solid)	26-87	> 1.0 cm
Intermediate-risk	Ovoid, smooth, mildly hypoechoic No features of high suspicion	6-27	> 1.5 cm
Low-risk	Ovoid, smooth, isoechoic/hyperechoic No features of high suspicion	2-4	> 2.0 cm
Benign	Pure cyst, entirely spongiform	0	Not indicated [†]
AACE/ACE/AME system			
High-risk	Nodules with at least 1 of the following features: marked hypoechoogenicity, spiculated or lobulated margins, microcalcifications, TTW shape, extrathyroidal growth	50-90	≥ 1.0 cm
Intermediate-risk	Slightly hypoechoic or isoechoic nodules, with ovoid-to-round shape, smooth or ill-defined margins	5-15	> 2.0 cm
Low-risk	Cysts, mostly cystic nodules with reverberating artifacts and not associated with suspicious US signs, isoechoic spongiform nodules	1	Not indicated [†]
ATA system			
High suspicion	Solid hypoechoic nodule or solid hypoechoic component of a partially cystic nodule with one or more of the following features: irregular margins (infiltrative, microlobulated), microcalcifications, the TTW shape, rim calcifications with small extrusive soft tissue component, evidence of ETE	> 70-90	≥ 1.0 cm
Intermediate suspicion	Hypoechoic solid nodule with smooth margins without microcalcifications, ETE, or TTW shape	10-20	≥ 1.0 cm
Low suspicion	Isoechoic or hyperechoic solid nodule, or partially cystic nodule with eccentric solid areas, without microcalcification, irregular margin or ETE, or TTW shape	5-10	≥ 1.5 cm
Very low suspicion	Spongiform or partially cystic nodules without any of the sonographic features described in low, intermediate, or high suspicion patterns	< 3	Consider FNA when diameter ≥ 2.0 cm
Benign	Purely cystic nodules (no solid component)	< 1	Not indicated
K-TIRADS			
High suspicion	Solid hypoechoic nodule with any of three suspicious US features (microcalcification, nonparallel orientation, spiculated/microlobulated margin)	> 60	≥ 1.0 cm
Intermediate suspicion	1) Solid hypoechoic nodule without any of three suspicious US features or 2) partially cystic or isohyperechoic nodule with any of three suspicious US features	15-50	≥ 1.0 cm
Low suspicion	Partially cystic or isohyperechoic nodule without any of three suspicious US features	3-15	≥ 1.5 cm
Benign	1) Spongiform, 2) partially cystic nodule with intracystic echogenic foci with comet tail artifact, 3) pure cyst	< 3	Not indicated [‡]

*Points are allotted for all ultrasonographic features of a nodule, with more suspicious features being awarded more points. [†]Unless compressive, [‡]Not routinely indicated except for nodules > 2 cm and increasing in size or associated with a risk history, as well as before thyroid surgery or minimally invasive ablation therapy. [§]Not routinely indicated, but may be selectively considered for a spongiform nodule when the nodule size is ≥ 2 cm and indicated for the therapeutic drainage of the cystic content as well as for diagnosis prior to ablation therapy. AACE/ACE/AME = American Association of Clinical Endocrinologists/American College of Endocrinology/Associazione Medici Endocrinologi, ACR = American College of Radiology, ATA = American Thyroid Association, ETE = extrathyroidal extension, EU-TIRADS = European TIRADS, FNA = fine-needle aspiration, K-TIRADS = Korean TIRADS, TIRADS = Thyroid Imaging Reporting and Data System, TTW = taller than wide, US = ultrasonography

while maintaining the appropriate sensitivity for detecting malignant tumors in nodules ≥ 1 cm. However, the determination of the appropriate diagnostic performance of US-based RSSs for thyroid malignancy is controversial. The diagnostic performance of RSSs needs to be stratified according to nodule size. Tumor size is an important prognostic factor in papillary thyroid carcinoma (PTC) and follicular thyroid carcinoma (FTC) [27,28]. The risk of distant metastasis is higher for tumors > 2 cm [29], and the risks of local tumor invasion, nodal metastasis, and distant metastasis increase with increasing tumor size [30]. Therefore, a strategy for reducing unnecessary biopsies at the cost of decreasing the sensitivity may be appropriate for small nodules (1–2 cm) without aggressive thyroid cancer features, considering the slow growth rate of most small low-risk thyroid cancers. Meanwhile, a strategy for increasing sensitivity at the cost of increasing the rate of unnecessary biopsy may be appropriate for large nodules (> 2 cm), considering the higher risk of aggressive behavior in large malignant tumors and the low predictive ability of the current RSSs for non-PTC malignant tumors, such as encapsulated follicular variant PTC (FVPTC) or FTC [31–33].

The appropriate sensitivity for detecting malignancy should be determined through a careful consideration of the risks and benefits to patients. False-negative results can increase the risks of morbidity and mortality due to failed detection of malignant tumors, including rare high-grade malignancies as well as PTC, which may be mitigated by US surveillance of small (1–2 cm) low-risk thyroid cancers. Meanwhile, false-positive results carry the risk of potential complications and increased costs due to increased number of biopsies, although US-guided biopsy is a safe procedure. Inconclusive biopsy results may lead to repeat biopsies or unnecessary diagnostic surgeries for some nodules. Although the ACR-TIRADS has adopted larger size thresholds for the biopsy and US monitoring of nodules not meeting the biopsy criteria, it is still uncertain whether US monitoring of nodule growth can effectively prevent the potential risk of nodal or distant metastases in nodules ≥ 1 cm. This is because no long-term active surveillance results are available for small (1–2 cm) low-risk PTCs and the safety of US monitoring without biopsy has not been validated in nodules ≥ 1 cm. Furthermore, no enlargement of the primary tumor was evident in 11 of 12 low-risk papillary thyroid microcarcinomas (PTMCs) (92%) showing novel lymph node metastasis during active surveillance in a previous study [34]. Therefore, although reducing unnecessary biopsies

of small (1–2 cm) nodules without aggressive malignant features is important, it is uncertain whether biopsy criteria with very low sensitivity for detecting malignancy will be beneficial or harmful to patients.

Clinical Applications of K-TIRADS

The selection of thyroid nodules for biopsy is determined by the estimated malignancy risk (K-TIRADS category), nodule size, and features of aggressive malignant tumors, including suspected nodal metastasis and gross ETE. Clinical risk factors (history of childhood radiation therapy, familial thyroid cancer, increased calcitonin level, and incidentalomas with ^{18}F -fluorodeoxyglucose uptake) and the patient's preference may influence the size criterion for biopsy of K-TIRADS 3 or 4 nodules, although it is uncertain whether clinical risk factors increase the malignancy risk estimated according to the US pattern [35]. Immediate biopsies may be deferred for older patients or patients with comorbid conditions if there are no risk factors requiring immediate surgery. Biopsy should be performed regardless of nodule size if nodal metastasis or gross ETE is suspected. Although biopsy is not routinely recommended for subcentimeter K-TIRADS 5 nodules without features indicating aggressive thyroid cancer, biopsy of candidate nodules (> 5 mm) may be selectively performed for active surveillance to avoid unnecessary long-term active surveillance in patients with benign nodules showing highly suspicious US patterns. US-guided biopsy is not routinely recommended for K-TIRADS 2 nodules for diagnostic purposes; however, biopsy may be necessary before ablation therapy or surgery.

Previous studies have shown that the US pattern of the K-TIRADS is predictive of the histologic type of thyroid cancers [31,32,36–38]. The most common US pattern of PTC is K-TIRADS 5, and 83% of PTC cases show the K-TIRADS 4 or 5 pattern [36]. Meanwhile, 82–92% of FTC cases show the K-TIRADS 3 or 4 pattern [31,37,39] and 94% of other thyroid cancer types show the K-TIRADS 4 or 5 pattern [13]. Although the most common US pattern of classic PTC is K-TIRADS 5, the most common US pattern of FVPTC is K-TIRADS 4 (48.7%). The K-TIRADS pattern of FVPTC differs according to the FVPTC subtype [32]. Most cases of noninvasive follicular thyroid neoplasms with papillary-like nuclear features and invasive encapsulated FVPTC show the K-TIRADS 3 or 4 pattern, and most infiltrative FVPTC cases show the K-TIRADS 5 pattern, similar to classic PTC [32].

The K-TIRADS is useful for stratifying the malignancy risk of nodules with benign or inconclusive [nondiagnostic and atypia/follicular lesion of undetermined significance (AUS/FLUS)] results on fine-needle aspiration biopsy (FNAB) [39], but not that of nodules suspicious for follicular neoplasm/follicular neoplasm and malignancy [39,40]. In nodules with nondiagnostic and AUS/FLUS FNAB results, the malignancy risk increases with increasing K-TIRADS risk score. A nondiagnostic FNAB result does not significantly affect the malignancy risk of the K-TIRADS patterns [39] and most such nodules require repeat biopsies. Although the appropriate management strategy is still controversial for nodules with AUS/FLUS FNAB results, first-line repeat biopsy or molecular investigation is a reasonable choice over immediate diagnostic surgery to avoid unnecessary surgery. In nodules with benign FNAB results, only the K-TIRADS 5 pattern has a significantly increased malignancy risk (12.5%) [39], and repeat biopsy is usually recommended for nodules with the K-TIRADS 5 pattern.

What is the Role of a US-Based RSS in Reducing Overdiagnosis and Overtreatment?

Cancer overdiagnosis is the detection and histologic confirmation of a cancer that is not expected to cause symptoms or death [41]. Epidemiologic population-based evidence has raised awareness about the overdiagnosis and overtreatment of various cancers [41]. The incidence of thyroid cancer, predominantly small PTMCs, has increased over the recent decades. This is a worldwide phenomenon but is especially prevalent in South Korea [42,43]. Although there may be a real increase in thyroid cancer, which is supported by the increased incidence of thyroid cancers of all sizes and stages and the increased incidence-based mortality [44,45], the increased incidence is mainly accounted for by small low-risk PTMCs detected early with US or other diagnostic imaging modalities. This has ultimately resulted in overdiagnosis and overtreatment [43,46].

Although reducing the diagnostic rate of indolent small thyroid cancers by reducing the number of incidental thyroid nodules detected by diagnostic workup may be a reasonable solution to overdiagnosis [47], incidentalomas detected by various diagnostic imaging procedures are inevitable in the current practice, and this strategy might result in potential harm by delaying the treatment of aggressive or advanced high-risk cancers [48]. Overdiagnosis can result in overtreatment in the form of unnecessary surgery of

indolent thyroid cancers. A strategy that minimizes the harm of potential overdiagnosis might be needed to reduce overtreatment through appropriate and individualized thyroid cancer treatment. For this strategy, the role of US-based RSSs is essential in predicting the individualized malignancy risk of nodules and their prognostic risk (indolent or aggressive cancer), which will guide the decision of whether to perform biopsy or immediate surgery for incidental small thyroid nodules.

The harm of overdiagnosis and overtreatment is mainly associated with small PTMCs. Active surveillance instead of immediate surgery is becoming increasingly adopted for low-risk PTMCs [49,50]. Although recent studies have suggested the potential application of active surveillance in relatively small (1–1.5 cm) low-risk PTCs [51,52], long-term results are needed to determine if active surveillance compared with immediate surgery is safe and effective in reducing the possibility of overtreatment.

Challenges and Future Perspectives of K-TIRADS

A primary role of the K-TIRADS is to standardize the reporting using the same language among US lexicons and risk categories and to guide the appropriate management of patients with thyroid nodules. Our experience with the clinical application of the K-TIRADS has raised several issues, indicating the need for updating the K-TIRADS to optimize patient management.

First, many studies [6–12] have suggested the need for modifying the biopsy size thresholds to reduce unnecessary biopsies, even if this decreases the sensitivity for detecting malignancy, in small (1–2 cm) thyroid nodules without features of aggressive thyroid cancers. When the biopsy size threshold for K-TIRADS 3 nodules increased from 1.5 to 2 cm, there was a significant decrease (14.1–16.2%) in the unnecessary biopsy rate of benign nodules and a minimal decrease (1.0–1.9%) in the sensitivity (91.6–94.7%) of malignant tumor detection, compared with the original FNAB criteria of the K-TIRADS (sensitivity, 93.5–95.7%) [10,11]. When the biopsy size threshold increased from 1 to 1.5 cm for K-TIRADS 4 nodules and from 1.5 to 2 cm for K-TIRADS 3 nodules, there was a more substantial decrease (27.0–28.9%) in the unnecessary biopsy rate of benign nodules and a further decrease (15.0–27.1%) in the sensitivity (66.4–80.7%) for detecting malignant tumors [10,11]. By increasing the biopsy size threshold of K-TIRADS 3 nodules and subcategorizing K-TIRADS 4

nodules, the modified K-TIRADS substantially decreased the unnecessary biopsy rate while maintaining high sensitivity for small malignant tumors and very high sensitivity for large malignant tumors [12].

Second, US lexicons need to be modified to make them simpler and clearer, as well as for training to improve the interobserver agreement in the interpretation of individual US features and in the classification of nodules according to the K-TIRADS. The interobserver agreement of single US features is relatively low and highly variable (from slight to substantial agreement) [53-55]. For the K-TIRADS, the interobserver agreement of US classification of nodules was substantial ($\kappa = 0.66$) and the interobserver agreement of biopsy indications was almost perfect ($\kappa = 0.91$) following training [54]. Although the interexamination agreement between real-time and retrospective static US image interpretation for nodule classification by the K-TIRADS was substantial ($\kappa = 0.75$) [56], there is a need for further studies on interobserver agreement via prospective assessments or the use of video clips of US images, rather than static images, to validate the reliability of US feature interpretation and improve the interobserver agreement of the K-TIRADS.

Third, although the K-TIRADS has recommendations for US risk stratification and biopsy criteria for cervical lymph nodes in patients with thyroid nodules, the specific US criteria for ETE (minor and gross) need to be further developed in this system. Although the presence of ETE is incorporated in the nodule risk stratification in some US-based RSSs [15,16], the US criteria for ETE have not been specified or validated. The presence of clinically significant gross ETE on US suggests a possibly aggressive thyroid cancer and will require biopsy to determine the need for surgical treatment [57].

Fourth, the K-TIRADS does not include recommendations for the US monitoring of nodules that do not meet the biopsy criteria. Appropriate recommendations for the management of these nodules are needed to reduce unnecessary US follow-ups and to enable the appropriate management of nodules based on their size and clinical features, such as associated symptoms, clinical risk factors, and patient factors, alongside their US-based malignancy risk.

CONCLUSION

The K-TIRADS is a pattern-based RSS that considers tumor composition, echogenicity, and suspicious US features. It

is feasible for clinical use owing to its intuitive and easy categorization of nodules during real-time US examinations. Although the current biopsy criteria of the K-TIRADS have the highest sensitivity for malignancy among the US-based RSSs, they are associated with a high rate of unnecessary biopsies of benign nodules. The nodule size threshold for biopsy should be revised to reduce unnecessary biopsies while maintaining the appropriate sensitivity for detecting malignancy according to the nodule size. Future directions include more specific recommendations for US assessment of aggressive cancer features (risk stratification of cervical lymph nodes and criteria for ETE) and recommendations for personalized management of patients before and after biopsy.

Conflicts of Interest

The authors have no potential conflicts of interest to disclose.

Author Contributions

Conceptualization: all authors. Supervision: Dong Gyu Na. Writing—original draft: Dong Gyu Na, Eun Ju Ha. Writing—review & editing: all authors.

ORCID iDs

Eun Ju Ha

<https://orcid.org/0000-0002-1234-2919>

Dong Gyu Na

<https://orcid.org/0000-0001-6422-1652>

Jung Hwan Baek

<https://orcid.org/0000-0003-0480-4754>

REFERENCES

1. Shin JH, Baek JH, Chung J, Ha EJ, Kim JH, Lee YH, et al. Ultrasonography diagnosis and imaging-based management of thyroid nodules: revised Korean Society of Thyroid Radiology consensus statement and recommendations. *Korean J Radiol* 2016;17:370-395
2. Yi KH, Lee EK, Kang HC, Koh Y, Kim SW, Kim IJ, et al. 2016 revised Korean thyroid association management guidelines for patients with thyroid nodules and thyroid cancer. *Int J Thyroidol* 2016;9:59-126
3. Moon WJ, Baek JH, Jung SL, Kim DW, Kim EK, Kim JY, et al. Ultrasonography and the ultrasound-based management of thyroid nodules: consensus statement and recommendations. *Korean J Radiol* 2011;12:1-14
4. Na DG, Baek JH, Sung JY, Kim JH, Kim JK, Choi YJ, et al. Thyroid imaging reporting and data system risk stratification

- of thyroid nodules: categorization based on solidity and echogenicity. *Thyroid* 2016;26:562-572
5. Ha EJ, Moon WJ, Na DG, Lee YH, Choi N, Kim SJ, et al. A multicenter prospective validation study for the Korean thyroid imaging reporting and data system in patients with thyroid nodules. *Korean J Radiol* 2016;17:811-821
 6. Ha EJ, Na DG, Baek JH, Sung JY, Kim JH, Kang SY. US fine-needle aspiration biopsy for thyroid malignancy: diagnostic performance of seven society guidelines applied to 2000 thyroid nodules. *Radiology* 2018;287:893-900
 7. Ha EJ, Na DG, Moon WJ, Lee YH, Choi N. Diagnostic performance of ultrasound-based risk-stratification systems for thyroid nodules: comparison of the 2015 American Thyroid Association Guidelines with the 2016 Korean Thyroid Association/Korean Society of Thyroid Radiology and 2017 American College of Radiology Guidelines. *Thyroid* 2018;28:1532-1537
 8. Middleton WD, Teefey SA, Reading CC, Langer JE, Beland MD, Szabunio MM, et al. Comparison of performance characteristics of american college of radiology TI-RADS, Korean Society of thyroid radiology TIRADS, and American Thyroid Association guidelines. *AJR Am J Roentgenol* 2018;210:1148-1154
 9. Grani G, Lamartina L, Ascoli V, Bosco D, Biffoni M, Giacomelli L, et al. Reducing the number of unnecessary thyroid biopsies while improving diagnostic accuracy: toward the "right" TIRADS. *J Clin Endocrinol Metab* 2019;104:95-102
 10. Ha SM, Baek JH, Na DG, Suh CH, Chung SR, Choi YJ, et al. Diagnostic performance of practice guidelines for thyroid nodules: thyroid nodule size versus biopsy rates. *Radiology* 2019;291:92-99
 11. Yoon SJ, Na DG, Gwon HY, Paik W, Kim WJ, Song JS, et al. Similarities and differences between thyroid imaging reporting and data systems. *AJR Am J Roentgenol* 2019;213:W76-W84
 12. Na DG, Paik W, Cha J, Gwon HY, Kim SY, Yoo RE. Diagnostic performance of the modified Korean Thyroid Imaging Reporting and Data System for thyroid malignancy according to nodule size: a comparison with five society guidelines. *Ultrasonography* 2020 Dec [Epub]. <https://doi.org/10.14366/usg.20148>
 13. Hayen A, Macaskill P, Irwig L, Bossuyt P. Appropriate statistical methods are required to assess diagnostic tests for replacement, add-on, and triage. *J Clin Epidemiol* 2010;63:883-891
 14. Haugen BR, Alexander EK, Bible KC, Doherty GM, Mandel SJ, Nikiforov YE, et al. 2015 American Thyroid Association management guidelines for adult patients with thyroid nodules and differentiated thyroid cancer: the American Thyroid Association guidelines task force on thyroid nodules and differentiated thyroid cancer. *Thyroid* 2016;26:1-133
 15. Gharib H, Papini E, Garber JR, Duick DS, Harrell RM, Hegedus L, et al. American Association of Clinical Endocrinologists, American College of Endocrinology, and Associazione Medici Endocrinologi Medical Guidelines for clinical practice for the diagnosis and management of thyroid nodules--2016 update. *Endocr Pract* 2016;22:622-639
 16. Tessler FN, Middleton WD, Grant EG, Hoang JK, Berland LL, Teefey SA, et al. ACR thyroid imaging, reporting and data system (TI-RADS): white paper of the ACR TI-RADS Committee. *J Am Coll Radiol* 2017;14:587-595
 17. Russ G, Bonnema SJ, Erdogan MF, Durante C, Ngu R, Leenhardt L. European Thyroid Association guidelines for ultrasound malignancy risk stratification of thyroid nodules in adults: the EU-TIRADS. *Eur Thyroid J* 2017;6:225-237
 18. Tessler FN, Middleton WD, Grant EG. Thyroid imaging reporting and data system (TI-RADS): a user's guide. *Radiology* 2018;287:1082
 19. Na DG, Kim JH, Kim DS, Kim SJ. Thyroid nodules with minimal cystic changes have a low risk of malignancy. *Ultrasonography* 2016;35:153-158
 20. Lee JY, Na DG, Yoon SJ, Gwon HY, Paik W, Kim T, et al. Ultrasound malignancy risk stratification of thyroid nodules based on the degree of hypoechoogenicity and echotexture. *Eur Radiol* 2020;30:1653-1663
 21. Zhou J, Yin L, Wei X, Zhang S, Song Y, Luo B, et al. 2020 Chinese guidelines for ultrasound malignancy risk stratification of thyroid nodules: the C-TIRADS. *Endocrine* 2020;70:256-279
 22. Na DG, Kim DS, Kim SJ, Ryoo JW, Jung SL. Thyroid nodules with isolated macrocalcification: malignancy risk and diagnostic efficacy of fine-needle aspiration and core needle biopsy. *Ultrasonography* 2016;35:212-219
 23. Gwon HY, Na DG, Noh BJ, Paik W, Yoon SJ, Choi SJ, et al. Thyroid nodules with isolated macrocalcifications: malignancy risk of isolated macrocalcifications and postoperative risk stratification of malignant tumors manifesting as isolated macrocalcifications. *Korean J Radiol* 2020;21:605-613
 24. Paik W, Na DG, Gwon HY, Kim J. CT features of thyroid nodules with isolated macrocalcifications detected by ultrasonography. *Ultrasonography* 2020;39:130-136
 25. Yim Y, Na DG, Ha EJ, Baek JH, Sung JY, Kim JH, et al. Concordance of three international guidelines for thyroid nodules classified by ultrasonography and diagnostic performance of biopsy criteria. *Korean J Radiol* 2020;21:108-116
 26. Kim PH, Suh CH, Baek JH, Chung SR, Choi YJ, Lee JH. Diagnostic performance of four ultrasound risk stratification systems: a systematic review and meta-analysis. *Thyroid* 2020;30:1159-1168
 27. Hay ID. Papillary thyroid carcinoma. *Endocrinol Metab Clin North Am* 1990;19:545-576
 28. Mazzaferri EL, Jhiang SM. Long-term impact of initial surgical and medical therapy on papillary and follicular thyroid cancer. *Am J Med* 1994;97:418-428
 29. Machens A, Holzhausen HJ, Dralle H. The prognostic value of primary tumor size in papillary and follicular thyroid carcinoma. *Cancer* 2005;103:2269-2273
 30. Nguyen XV, Roy Choudhury K, Tessler FN, Hoang JK. Effect of tumor size on risk of metastatic disease and survival for

- thyroid cancer: implications for biopsy guidelines. *Thyroid* 2018;28:295-300
31. Castellana M, Piccardo A, Virili C, Scappaticcio L, Grani G, Durante C, et al. Can ultrasound systems for risk stratification of thyroid nodules identify follicular carcinoma? *Cancer Cytopathol* 2020;128:250-259
 32. Hahn SY, Shin JH, Oh YL, Kim TH, Lim Y, Choi JS. Role of ultrasound in predicting tumor invasiveness in follicular variant of papillary thyroid carcinoma. *Thyroid* 2017;27:1177-1184
 33. Trimboli P, Castellana M, Piccardo A, Romanelli F, Grani G, Giovannella L, et al. The ultrasound risk stratification systems for thyroid nodule have been evaluated against papillary carcinoma. A meta-analysis. *Rev Endocr Metab Disord* 2021;22:453-460
 34. Ito Y, Miyauchi A, Oda H. Low-risk papillary microcarcinoma of the thyroid: a review of active surveillance trials. *Eur J Surg Oncol* 2018;44:307-315
 35. Chung SR, Choi YJ, Suh CH, Kim HJ, Lee JJ, Kim WG, et al. Thyroid incidentalomas detected on 18F-fluorodeoxyglucose positron emission tomography with computed tomography: malignant risk stratification and management plan. *Thyroid* 2018;28:762-768
 36. Hong MJ, Na DG, Baek JH, Sung JY, Kim JH. Impact of nodule size on malignancy risk differs according to the ultrasonography pattern of thyroid nodules. *Korean J Radiol* 2018;19:534-541
 37. Park JW, Kim DW, Kim D, Baek JW, Lee YJ, Baek HJ. Korean thyroid imaging reporting and data system features of follicular thyroid adenoma and carcinoma: a single-center study. *Ultrasonography* 2017;36:349-354
 38. Park KW, Shin JH, Hahn SY, Oh YL, Kim SW, Kim TH, et al. Ultrasound-guided fine-needle aspiration or core needle biopsy for diagnosing follicular thyroid carcinoma? *Clin Endocrinol (Oxf)* 2020;92:468-474
 39. Hong MJ, Na DG, Baek JH, Sung JY, Kim JH. Cytology-ultrasonography risk-stratification scoring system based on fine-needle aspiration cytology and the Korean-thyroid imaging reporting and data system. *Thyroid* 2017;27:953-959
 40. Yang W, Fananapazir G, LaRoy J, Wilson M, Campbell MJ. Can the American Thyroid Association, K-TIRADS and ACR-TIRADS ultrasound classification systems be used to predict malignancy in Bethesda category IV nodules? *Endocr Pract* 2020;26:945-952
 41. Welch HG, Black WC. Overdiagnosis in cancer. *J Natl Cancer Inst* 2010;102:605-613
 42. Vaccarella S, Franceschi S, Bray F, Wild CP, Plummer M, Dal Maso L. Worldwide thyroid-cancer epidemic? The increasing impact of overdiagnosis. *N Engl J Med* 2016;375:614-617
 43. Ahn HS, Kim HJ, Welch HG. Korea's thyroid-cancer "epidemic"-screening and overdiagnosis. *N Engl J Med* 2014;371:1765-1767
 44. Enewold L, Zhu K, Ron E, Marrogi AJ, Stojadinovic A, Peoples GE, et al. Rising thyroid cancer incidence in the United States by demographic and tumor characteristics, 1980-2005. *Cancer Epidemiol Biomarkers Prev* 2009;18:784-791
 45. Lim H, Devesa SS, Sosa JA, Check D, Kitahara CM. Trends in thyroid cancer incidence and mortality in the United States, 1974-2013. *JAMA* 2017;317:1338-1348
 46. Seib CD, Sosa JA. Evolving understanding of the epidemiology of thyroid cancer. *Endocrinol Metab Clin North Am* 2019;48:23-35
 47. Hoang JK, Nguyen XV, Davies L. Overdiagnosis of thyroid cancer: answers to five key questions. *Acad Radiol* 2015;22:1024-1029
 48. Malone MK, Zagzag J, Ogilvie JB, Patel KN, Heller KS. Thyroid cancers detected by imaging are not necessarily small or early stage. *Thyroid* 2014;24:314-318
 49. Brito JP, Ito Y, Miyauchi A, Tuttle RM. A clinical framework to facilitate risk stratification when considering an active surveillance alternative to immediate biopsy and surgery in papillary microcarcinoma. *Thyroid* 2016;26:144-149
 50. Sugitani I, Ito Y, Takeuchi D, Nakayama H, Masaki C, Shindo H, et al. Indications and strategy for active surveillance of adult low-risk papillary thyroid microcarcinoma: consensus statements from the Japan Association of Endocrine Surgery Task Force on management for papillary thyroid microcarcinoma. *Thyroid* 2021;31:183-192
 51. Tuttle RM, Fagin JA, Minkowitz G, Wong RJ, Roman B, Patel S, et al. Natural history and tumor volume kinetics of papillary thyroid cancers during active surveillance. *JAMA Otolaryngol Head Neck Surg* 2017;143:1015-1020
 52. Sakai T, Sugitani I, Ebina A, Fukuoka O, Toda K, Mitani H, et al. Active surveillance for T1bN0M0 papillary thyroid carcinoma. *Thyroid* 2019;29:59-63
 53. Moon WJ, Jung SL, Lee JH, Na DG, Baek JH, Lee YH, et al. Benign and malignant thyroid nodules: US differentiation--multicenter retrospective study. *Radiology* 2008;247:762-770
 54. Grani G, Lamartina L, Cantisani V, Maranghi M, Lucia P, Durante C. Interobserver agreement of various thyroid imaging reporting and data systems. *Endocr Connect* 2018;7:1-7
 55. Persichetti A, Di Stasio E, Coccaro C, Graziano F, Bianchini A, Di Donna V, et al. Inter-and intraobserver agreement in the assessment of thyroid nodule ultrasound features and classification systems: a blinded multicenter study. *Thyroid* 2020;30:237-242
 56. Bae JM, Hahn SY, Shin JH, Ko EY. Inter-exam agreement and diagnostic performance of the Korean thyroid imaging reporting and data system for thyroid nodule assessment: real-time versus static ultrasonography. *Eur J Radiol* 2018;98:14-19
 57. Chung SR, Baek JH, Choi YJ, Sung TY, Song DE, Kim TY, et al. Sonographic assessment of the extent of extrathyroidal extension in thyroid cancer. *Korean J Radiol* 2020;21:1187-1195