



Evaluation of Zone 2 Thoracic Endovascular Aortic Repair Performed with and without Prophylactic Embolization of the Left Subclavian Artery in Patients with Traumatic Aortic Injury

Miju Bae^{1, 2}, Chang Ho Jeon^{2, 3*}, Hoon Kwon^{2, 3}, Jin Hyeok Kim⁴, Seon Uoo Choi⁵, Seunghwan Song^{1, 2}

Departments of ¹Thoracic and Cardiovascular Surgery and ³Radiology, Pusan National University Hospital, Busan, Korea; ²Biomedical Research Institute, Pusan National University Hospital, Busan, Korea; ⁴Department of Radiology, Pusan National University Yangsan Hospital, Yangsan, Korea; ⁵Department of Thoracic and Cardiovascular Surgery, Kosin University Gospel Hospital, Kosin University College of Medicine, Busan, Korea

Objective: To report the authors' experience in performing thoracic endovascular aortic repair (TEVAR) for zone 2 lesions after traumatic aortic injury (TAI).

Materials and Methods: This retrospective review included 10 patients who underwent zone 2 TEVAR after identification of aortic isthmus injury by CT angiography (CTA) upon arrival at the emergency room of a regional trauma center from 2016 to 2019. Patients were classified into two groups: those who underwent left subclavian artery (LSA) embolization concurrently with the main TEVAR procedure, and those in whom LSA embolization was not performed during the main procedure, but was planned as a bailout treatment if type II endoleak was noted on follow-up CTA images. Pre-procedural and procedure-related factors and post-procedure prognosis were compared between the groups.

Results: There were no differences in pre-procedural factors, occurrence of endoleaks, and post-procedure prognosis (including mortality) between patients in the two groups. The duration of the procedure was shorter in the non-LSA embolization group (61 minutes vs. 27 minutes, $p = 0.012$). During follow-up, type II endoleak did not occur in either group.

Conclusion: Delaying preventative LSA embolization until stabilization of the patient would be desirable when performing zone 2 TEVAR for TAI, in the absence of endoleak on the completion aortography image taken after complete deployment of the stent graft.

Keywords: Thoracic endovascular aortic repair; Traumatic aortic injury; Left subclavian artery; Embolization; Type II endoleak

INTRODUCTION

Traumatic aortic injury (TAI) is the second most common

cause of blunt trauma-related death after intracranial hemorrhage [1, 2]. Treatments for TAI include open surgical repair and thoracic endovascular aortic repair (TEVAR). TEVAR is advantageous compared to open repair because it does not require open thoracotomy, single-lung ventilation, systemic heparinization, aortic cross-clamping, or multiple transfusions [3-5]. Furthermore, a meta-analysis conducted in 2019 reported that TEVAR yielded more favorable outcomes in patients with TAI based on median length of stay in the intensive care unit (9.0 days vs. 12.0 days, $p < 0.048$) and mortality (9.3% vs. 16.6%, $p < 0.015$) than surgical treatment [6]. Scalea et al. [6] stated that "endovascular repair is now the standard," given the current situation wherein approximately 70% of the patients received non-operative care.

Received: August 6, 2020 **Revised:** November 3, 2020

Accepted: November 10, 2020

Corresponding author: Chang Ho Jeon, MD, PhD, Department of Radiology, Biomedical Research Institute, Pusan National University Hospital, 179 Gudeok-ro, Seo-gu, Busan 49241, Korea.

• E-mail: changho.jeon@gmail.com

*Current affiliation: Department of Radiology, Eunpyeong St. Mary's Hospital, College of Medicine, The Catholic University of Korea, Seoul, Korea.

This is an Open Access article distributed under the terms of the Creative Commons Attribution Non-Commercial License (<https://creativecommons.org/licenses/by-nc/4.0>) which permits unrestricted non-commercial use, distribution, and reproduction in any medium, provided the original work is properly cited.

The TEVAR guidelines for TAI state that if the procedure is performed in zone 2, left subclavian artery (LSA) embolization must be performed to prevent type II endoleak, similar to the conventional TEVAR protocol for diseased aneurysmal changes in the thoracic aorta [7-11]. In the absence of other immediate problems during TEVAR of a diseased aneurysmal thoracic aorta, the correct approach would be to perform all procedures necessary to prevent potential complications that may occur subsequently. However, in patients who suffer severe trauma, the major procedures must be performed promptly and preventative procedures that are not primarily required may be delayed.

Therefore, in this study, the authors report their experience in performing zone 2 TEVAR for patients with TAI and accompanying multi-trauma, where the trauma surgeon is expected to complete the procedure rapidly and subsequently address other problems. In such situations, a different approach is required, as a part of "damage control," from the conventional approach for zone 2 TEVAR, which is performed for non-traumatic aneurysmal disease in the thoracic aorta. In particular, the authors would like to focus on management of the subclavian artery.

MATERIALS AND METHODS

This retrospective study was approved by the Institutional Review Board of Pusan National University Hospital (IRB No. H-2001-003-087). The requirement to obtain informed consent was waived.

Patients

A retrospective review was performed on patients who arrived at the emergency room (ER) of a regional trauma center from January 2016 to December 2019, and underwent zone 2 TEVAR after aortic isthmus injury was identified on CT angiography (CTA) images taken at the time of arrival. Specifically, patient demographics (including age), etiology, comorbidity (embolization in other organs), hemodynamic status, and patient outcome were examined. The injury severity score (ISS) was extracted from the Korean Trauma Data Bank. The mean age of the patients was 55.30 ± 11.80 years, and there were 7 male patients.

TAI Treatment Strategy

On arrival at the ER, patients with traumatic thoracic aortic injury were placed under close observation in case of grade I injury. TEVAR was performed within 2 hours of

arrival in patients with grade II or higher injury, if their vital signs were unstable. TEVAR was performed within 2 hours in the following patients, even if the vital signs were stable: patients requiring brain or abdominal surgery, those aged ≥ 65 years, and those with an ISS ≥ 40 . Open repair was performed within 24 hours in patients with grade III or higher injuries, if brain or abdominal surgery was not deemed necessary and the patient was < 65 years of age or had an ISS < 40 .

TEVAR Procedure

All emergent TEVAR procedures for TAI were conducted in a uniplanar angiography suite (AXIOM Artis Zee; SIEMENS; or Infinix-i, Canon Medical Systems Corporation).

The aortic diameter was measured on the CTA images obtained before the procedure and conventional aortography images acquired during the procedure, to select a stent graft with a diameter 25–30% greater than the aortic diameter. Considering that many of the patients were in hypovolemic shock, the largest diameter between the measurements obtained by the two imaging modalities was used as the reference.

With the exception of 2 patients who had undergone left common carotid artery (LCCA) to LSA bypass surgery under general anesthesia before TEVAR, all patients were locally anesthetized in the supine position, and 6-Fr sheaths (Radifocus Introducer II, Terumo) were inserted in the common femoral artery (CFA) bilaterally, under sonographic guidance.

A diagnostic catheter was inserted in the left CFA sheath and aortography was performed to determine the graft size, while the right CFA sheath insertion site was prepared for the "Preclose" technique using two Perclose ProGlide vascular closure devices (Abbott Vascular). After an extra-stiff Lunderquist guidewire (Cook Medical) was introduced up to the aortic arch, either a 22-Fr (< 32 mm) or 24-Fr (> 34 mm) stent graft was passed via sheathless delivery. The precise location of the stent graft was confirmed and secured using aortography. The procedure was completed after confirming the absence of endoleak surrounding the stent graft on post-procedural aortography images.

Valiant (Medtronic Vascular) stent grafts were used in all patients. Heparin was used only in patients who underwent LCCA to LSA bypass surgery, considering the high risk of bleeding due to multi-trauma in other intra-abdominal organs [12].

The fundamental goal of the TEVAR procedure was to

secure a safe proximal landing zone of ≥ 2 cm to cover the site of injury in the aortic arch. The distance between the aortic injury site and the LSA was < 2 cm in all patients; therefore, the LSA orifice was included within the landing zone in all cases.

LSA Embolization

The proximal portion of the LSA covered with a stent graft was accessed through a 5- or 6-Fr sheath and a 5-Fr diagnostic catheter introduced from the left radial artery.

Additionally, to proactively prevent type II endoleaks, proximal embolization was performed using fiber-coated microcoils (Tornado or Nester; Cook Medical), detachable microcoils (Concerto; ev3; or Interlock; Boston Scientific), or a vascular plug (Amplatzer Vascular Plug; AGA Medical Corporation).

Patients who underwent zone 2 TEVAR were divided into the concurrent LSA embolization (n = 5) and non-LSA embolization (n = 5) groups to compare the procedure duration and outcomes, including endoleaks.

Table 1. Concurrent LSA Embolization vs. Non-LSA Embolization: Clinical Results of Zone 2 TEVAR

	Overall (n = 10)	Concurrent LSA Embolization Group (n = 5)	Non-LSA Embolization Group (n = 5)	<i>P</i>
Pre-procedural factors				
Age, years	52.50 [47.75, 61.75]	63.00 [50.00, 69.00]	50.00 [47.00, 55.00]	0.344
Sex, male, n (%)	7 (70.00)	4 (80.00)	3 (60.00)	1.000
SBP at ER	90.00 [65.00, 105.00]	90.00 [90.00, 110.00]	80.00 [60.00, 90.00]	0.340
Time from ER visit to procedure (minutes)	268.50 [128.25, 544.00]	496.00 [144.00, 560.00]	149.00 [113.00, 388.00]	0.530
ISS	36.00 [30.00, 47.75]	41.00 [38.00, 50.00]	33.00 [29.00, 34.00]	0.243
TAI grade				
Grade 3	7	4	3	
Grade 4	3	1	2	
Procedure-related factors				
Proximal landing zone to LSA (cm)	0.00 [0.00, 0.00]	0.00 [0.00, 0.00]	0.00 [0.00, 1.00]	1.000
Graft size				
Proximal	28.00 [26.00, 30.00]	28.00 [26.00, 30.00]	28.00 [26.00, 30.00]	1.000
Distal	28.00 [24.50, 30.00]	28.00 [24.00, 30.00]	28.00 [26.00, 30.00]	0.833
Length	100.00 [100.00, 100.00]	100.00 [100.00, 150.00]	100.00 [100.00, 100.00]	0.177
Procedural time	36.50 [27.50, 60.00]	61.00 [57.00, 74.00]	27.00 [22.00, 29.00]	0.012
Post-procedural factors				
ICU stay (days)	15.50 [4.75, 30.50]	14.00 [13.00, 20.00]	17.00 [2.00, 50.00]	0.675
Hospital stay (days)	39.00 [22.00, 63.25]	44.00 [34.00, 58.00]	28.00 [20.00, 103.00]	1.000
Progression, n (%)				
Death	2 (20.00)	2 (40.00)	0 (0.00)	0.524
Rehabilitation	5 (50.00)	2 (40.00)	3 (60.00)	
Discharge	3 (30.00)	1 (20.00)	2 (40.00)	

Data are median [interquartile range] or n (%) values. ER = emergency room, ICU = intensive care unit, ISS = injury severity score, LSA = left subclavian artery, SBP = systolic blood pressure, TAI = traumatic aortic injury, TEVAR = thoracic endovascular aortic repair

Pre-Procedural LCCA to LSA Bypass

The LCCA to LSA bypass surgery was performed only when the left vertebral artery dominance was clear on CTA. Bypass surgery was performed just before the main TEVAR procedure in 2 patients. Heparin was used at a dose of 100 units per kg for the bypass surgery.

Statistical Analysis

Statistical testing was performed using the 2-tailed test in R version 3.6.2 (R Foundation for Statistical Computing). The significance level was set at 0.05. To compare the parameters between patients in the concurrent and non-LSA embolization groups, continuous variables were tested with the Wilcoxon rank-sum test and categorical variables were tested with the Fisher's exact test.

RESULTS

Supplementary Table 1 shows the characteristics of the 10 patients who underwent zone 2 TEVAR for management of TAI. The mean follow-up duration after zone 2 TEVAR was 568 ± 443 days.

Two deaths occurred (case nos. 8 and 10). The patient in case 8 had a grade IV aortic injury. Upon arrival at the ER, extracorporeal membrane oxygenation was initiated and TEVAR was performed immediately; however, the patient died soon after the procedure. In case 10, a type Ia

endoleak was found on the completion angiography after zone 2 TEVAR; however, the leak was not visible on the CTA image taken at the one week follow-up. On postoperative day 34, subdural hemorrhage and pneumonia occurred, following which the patient died.

Table 1 presents the comparisons between the groups. Inter-group differences in age, sex, vital signs at the time of ER arrival, ISS, and time from the ER visit to the procedure were not statistically significant. Furthermore, the occurrence of endoleaks, intensive care unit stay, hospital stay, and progression were not significantly different between the groups. Inter-group comparisons of the procedure-related factors, proximal landing zone, graft size, and TAI grade were not significantly different; however, the mean duration of the procedure was significantly shorter for patients in the non-LSA embolization group than in the concurrent LSA embolization group (27 minutes vs. 61 minutes, $p = 0.012$).

Endoleaks did not occur in patients in the non-LSA embolization group at any point during follow-up. Therefore, additional planned LSA embolization was not needed. None of the patients developed steal syndrome or neurological symptoms, including stroke.

Figure 1A and B show the images of a patient who underwent zone 2 TEVAR without prophylactic LSA embolization for a grade III aortic injury; endoleak did not occur in this patient. Follow-up CTA images show a thrombus

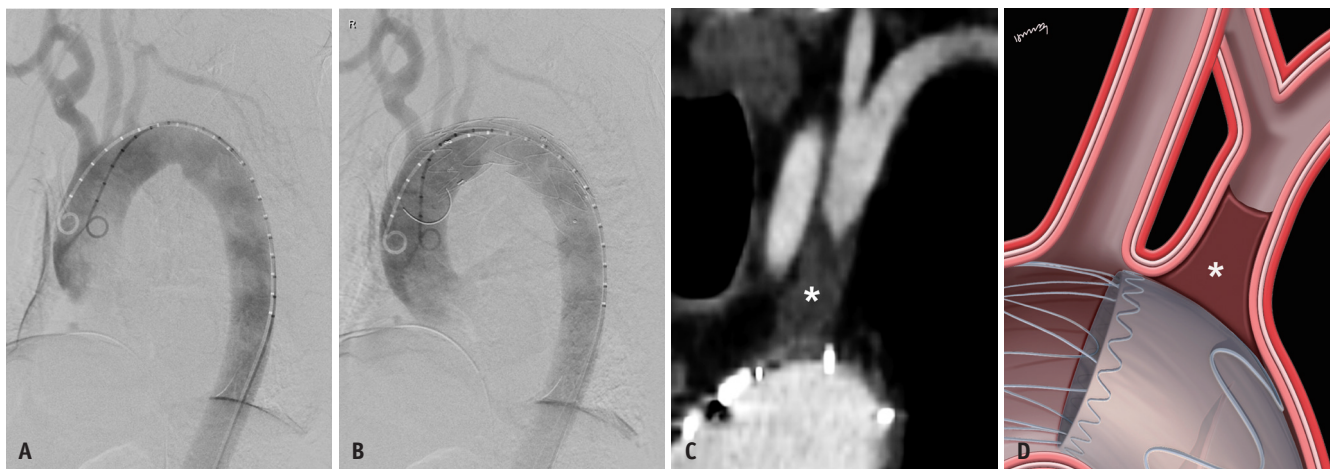

Fig. 1. Images of a 55-year-old man (patient in case 4) who presented with TAI after a traffic accident.

A. TAI is seen on the initial aortography image. The injury appears to be an aneurysmal dilatation protruding into the aortic arch (lesser curvature). A 34–34–100-mm Valiant (Medtronic Vascular) stent graft was deployed in zone 2. **B.** On the post-procedural final aortography image, the aneurysmal contour deformity is no longer visible, and the LSA can be confirmed from the location of the vertebral artery. **C.** There is no finding of endoleak surrounding the stent graft on the computed tomographic angiography image obtained at the 22-month follow-up. The proximal portion of the LSA is blocked by a thrombus (asterisk), and arterial flow through the vertebral artery to the subclavian artery is shown on the coronal image. **D.** These findings are consistent with those shown in the illustration (asterisk). LSA = left subclavian artery, TAI = traumatic aortic injury

plug emerging from the orifice of the LSA (Fig. 1C, D).

DISCUSSION

Damage control in trauma patients is performed

to prevent the “lethal triad of trauma” comprising hypothermia, coagulopathy, and acidosis caused by major bleeding. Resuscitative and abbreviated surgery is performed as quickly as possible to remove bleeding and contaminants, and definitive repair is deferred [13].

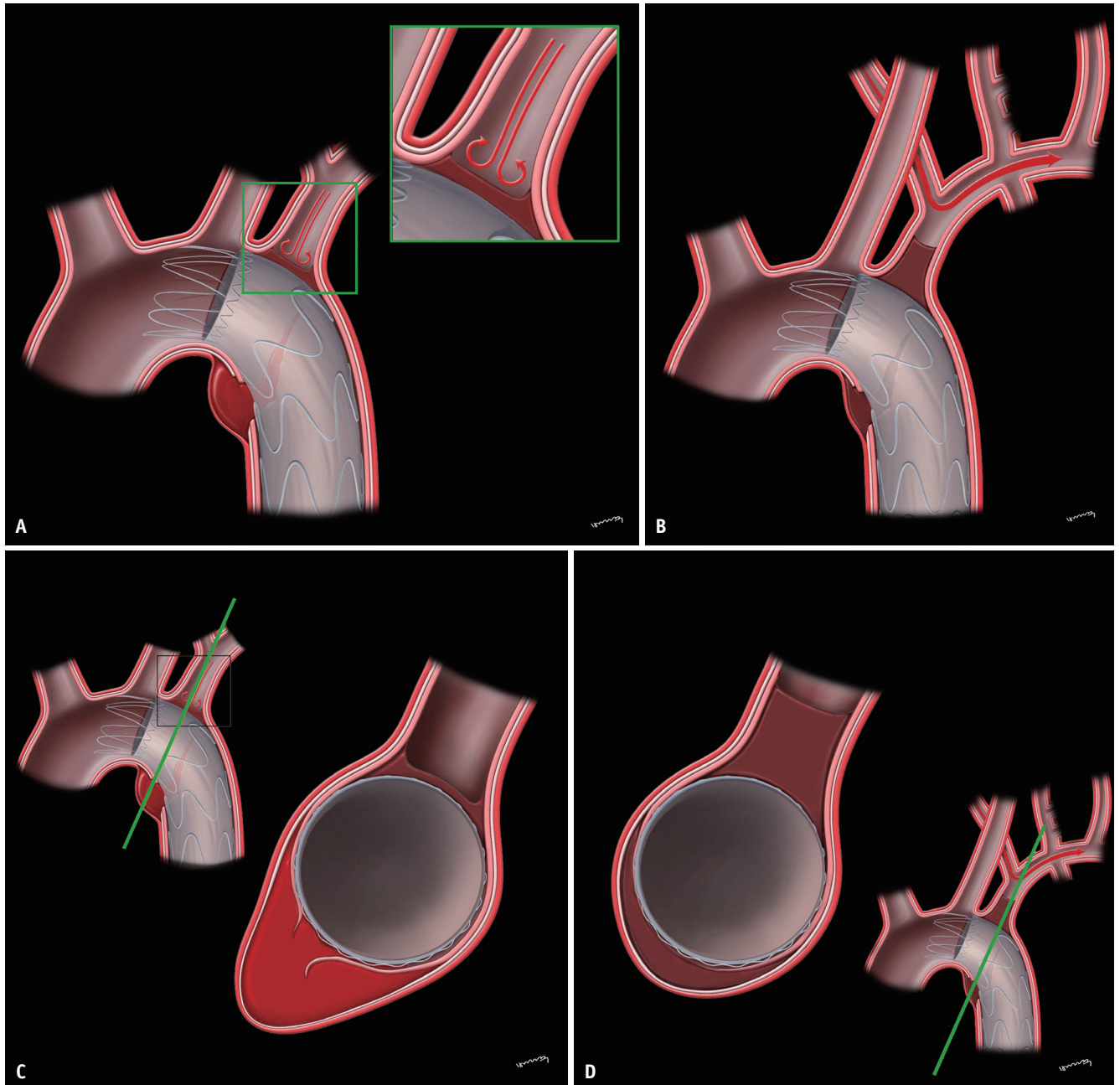


Fig. 2. Illustrations showing blunt aortic injury requiring zone 2 TEVAR. Considering that the distance between the site of injury and the LSA was less than 2 cm, it was necessary to cover the LSA to secure a sufficiently safe landing zone.

A. TEVAR performed immediately after the main procedure. A thin thrombus membrane can be seen forming in the orifice of the LSA after a TEVAR stent graft was inserted into the relatively healthy aorta, as there was no potential space for retrograde filling to occur in the LSA (magnification). **B.** The thrombus initially confined to the orifice has grown larger to safely prevent the occurrence of endoleak, and distal flow of the LSA is maintained by the vertebral artery. **C, D.** Illustrations show oblique coronal views of Fig. 2A, B images, respectively. The aorta sufficiently fits around the body of the TEVAR stent graft, denoting “no space, no endoleak.” LSA = left subclavian artery, TEVAR = thoracic endovascular aortic repair

Considering zone 2 TEVAR in patients with multiple traumas as a concept of “damage control” to prevent major bleeding, approximately 30 minutes (e.g., the time spent to perform prophylactic LSA embolization during zone 2 TEVAR to prevent type II endoleak) would be adequate to perform a subsequent procedure that could affect the outcomes of severely traumatized patients. Based on this concept, we postponed prophylactic LSA embolization, in cases where endoleak was not observed on the final aortography image on completion of TEVAR. The authors believe that this could be an effective paradigm shift, which would provide the trauma surgeon with more time to treat multi-trauma patients by resolving the TAI and promptly performing a subsequent procedure or surgery. When performing the zone 2 TEVAR procedure, not confirming the endoleak on final angiography was the most critical factor to decide regarding LSA embolization, and the intention was not to separate the two strategies from the beginning.

At first, prophylactic embolization of the subclavian artery was performed at our center. However, the preventative procedure is intentionally postponed in patients with severe trauma, who have limited time and urgently need the next surgery or management and in the absence of endoleak in the final angiography after TEVAR. A retrospective review showed that the number of patients with endoleaks on final angiography was small; therefore, statistical significance could not be demonstrated. However, in event of extension of the end of the aortic injury close to the LSA, a type II endoleak is likely to occur after zone 2 TEVAR. Additionally, in case of a pathologic aorta accompanied by an underlying aneurysmal change, endoleak could occur due to presence of a space not sealed by the stent graft after zone 2 TEVAR. In such a case, prophylactic LSA embolization would be necessary. However, even in such a case, it is impossible to predict the occurrence of endoleak in advance. Therefore, it is not necessary to initially decide regarding embolization of the LSA during the main TEVAR procedure.

In this study, endoleaks were not found on the follow-up CTA images of any patient in the non-LSA embolization group (0/5); therefore, additional intervention (LSA embolization) was not performed (0/5). Endoleak is caused by incomplete sealing of a partially covered potential space. Conventionally, endoleaks are categorized into five types, and type II endoleaks refer to retrograde, persistent filling or leakage from collateral vessels into the aneurysmal sac. It may be assumed that endoleaks would not occur after TEVAR if a stent graft is inserted into a relatively healthy

aorta (i.e., an ideally curved cylindrical aorta that is elastic and without aneurysmal changes or calcification) and the LSA orifice is completely sealed because there would be no potential space for retrograde filling. In other words, even in the presence of a collateral branch that could cause type II endoleak, the complication should not occur in the absence of a filling space or if the orifice is completely sealed by the stent graft (Fig. 2).

Unlike TEVAR performed for a typical aneurysm, the approach of not covering the LSA during the procedure by reducing the proximal landing zone (typically recommended as 2 cm) may be considered, if the aorta is relatively healthy in patients with TAI. However, this approach could be associated with the risk of a type I endoleak. In the event of a type I endoleak during zone 2 TEVAR due to an insufficiently deployed stent graft to cover the proximal landing zone, additional stent grafting or ballooning must be performed immediately. Accordingly, if the complication occurs in multi-trauma patients, critical issues may arise, including time loss in emergency management and increased medical costs.

This study has certain limitations. The sample size was small and non-parametric statistical tests were used. Thus, statistical errors related to a small sample size cannot be disregarded. The retrospective study design was also a limitation. Moreover, the hypothesis of “no space, no endoleak” should be further tested using animal models.

In conclusion, it would be desirable to delay prophylactic embolization of the LSA in patients undergoing zone 2 TEVAR for management of TAI in the absence of endoleak findings on the final aortography taken after complete stent graft deployment. The decision to perform prophylactic embolization of the LSA can be made based on follow-up CTA after the patient is stabilized.

Supplementary Materials

The Data Supplement is available with this article at <https://doi.org/10.3348/kjr.2020.0989>.

Conflicts of Interest

The authors have no potential conflicts of interest to disclose.

Acknowledgments

We thank the Department of Biostatistics, Biomedical Research Institute, Pusan National University Hospital.

Author Contributions

Conceptualization: Chang Ho Jeon. Data curation: Miju Bae, Chang Ho Jeon. Formal analysis: Miju Bae, Chang Ho Jeon. Investigation: Miju Bae, Chang Ho Jeon. Methodology: Miju Bae, Chang Ho Jeon. Resources: Miju Bae, Chang Ho Jeon. Supervision: Chang Ho Jeon. Validation: all authors. Visualization: Miju Bae, Chang Ho Jeon. Writing—original draft: Miju Bae, Chang Ho Jeon. Writing—review & editing: all authors.

ORCID iDs

Miju Bae

<https://orcid.org/0000-0003-1555-4113>

Chang Ho Jeon

<https://orcid.org/0000-0002-1762-5379>

Hoon Kwon

<https://orcid.org/0000-0003-4055-5863>

Jin Hyeok Kim

<https://orcid.org/0000-0001-6703-2419>

Seon Uoo Choi

<https://orcid.org/0000-0002-3438-0609>

Seunghwan Song

<https://orcid.org/0000-0002-7492-2097>

REFERENCES

- Smith RS, Chang FC. Traumatic rupture of the aorta: still a lethal injury. *Am J Surg* 1986;152:660-663
- Clancy TV, Gary Maxwell J, Covington DL, Brinker CC, Blackman D. A statewide analysis of level I and II trauma centers for patients with major injuries. *J Trauma* 2001;51:346-351
- Azizzadeh A, Keyhani K, Miller CC 3rd, Coogan SM, Safi HJ, Estrera AL. Blunt traumatic aortic injury: initial experience with endovascular repair. *J Vasc Surg* 2009;49:1403-1408
- Tang GL, Tehrani HY, Usman A, Katariya K, Otero C, Perez E, et al. Reduced mortality, paraplegia, and stroke with stent graft repair of blunt aortic transections: a modern meta-analysis. *J Vasc Surg* 2008;47:671-675
- Xenos ES, Abedi NN, Davenport DL, Minion DJ, Hamdallah O, Sorial EE, et al. Meta-analysis of endovascular vs open repair for traumatic descending thoracic aortic rupture. *J Vasc Surg* 2008;48:1343-1351
- Scalea TM, Feliciano DV, DuBose JJ, Ottochian M, O'Connor JV, Morrison JJ. Blunt thoracic aortic injury: endovascular repair is now the standard. *J Am Coll Surg* 2019;228:605-610
- Criado FJ, Barnatan MF, Rizk Y, Clark NS, Wang CF. Technical strategies to expand stent-graft applicability in the aortic arch and proximal descending thoracic aorta. *J Endovasc Ther* 2002;9 Suppl 2:II32-II38
- Nation DA, Wang GJ. TEVAR: endovascular repair of the thoracic aorta. *Semin Intervent Radiol* 2015;32:265-271
- Szeto WY, Bavaria JE, Bowen FW, Woo EY, Fairman RM, Pochettino A. The hybrid total arch repair: brachiocephalic bypass and concomitant endovascular aortic arch stent graft placement. *J Card Surg* 2007;22:97-102; discussion 103-104
- Zhou W, Reardon M, Peden EK, Lin PH, Lumsden AB. Hybrid approach to complex thoracic aortic aneurysms in high-risk patients: surgical challenges and clinical outcomes. *J Vasc Surg* 2006;44:688-693
- Bergeron P, Mangialardi N, Costa P, Coulon P, Douillez V, Serreo E, et al. Great vessel management for endovascular exclusion of aortic arch aneurysms and dissections. *Eur J Vasc Endovasc Surg* 2006;32:38-45
- Garcia-Toca M, Naughton PA, Matsumura JS, Morasch MD, Kibbe MR, Rodriguez HE, et al. Endovascular repair of blunt traumatic thoracic aortic injuries: seven-year single-center experience. *Arch Surg* 2010;145:679-683
- Hsu JM, Pham TN. Damage control in the injured patient. *Int J Crit Illn Inj Sci* 2011;1:66-72