








Transcatheter Removal of Bone Cement Embolism in the Right Atrium after Percutaneous Vertebroplasty: The Embolus Broke in Half and Migrated to the Right Pulmonary Artery Intraoperatively

경피적 척추성형 후 발생한 우심방 내 골 시멘트 색전의
도관경유제거술: 시술 중 두 동강나 우폐동맥으로
이동한 색전

Sunhyang Lee, MD¹ , Jae Woo Yeon, MD^{1*} , Jin-Tae Kwon, MD² ,
Hyuk Jung Kim, MD¹ , Suk Ki Jang, MD¹ 

Departments of ¹Radiology and ²Thoracic and Cardiovascular Surgery, Daejin Medical Center Bundang Jesaeng General Hospital, Seongnam, Korea

Bone cement embolism often occurs during percutaneous vertebroplasty. Bone cement pulmonary arterial embolism generally requires no treatment because of the small size and asymptomatic manifestation. Intracardiac bone cement embolisms are rare but associated with a risk of severe complications. Intracardiac bone cement embolisms are mainly removed through open heart surgery. To the best of our knowledge, only three cases of intracardiac bone cement embolisms removed with interventions have been reported. Here, we report another case of successful transcatheter retrieval of a 6-cm-long cement embolism in the right atrium after percutaneous vertebroplasty. The embolus broke in half and migrated to the right pulmonary artery intraoperatively. Using two snares and a filter retrieval device, we advanced from opposite directions. Further, we gently grasped and pulled the fragments of the right pulmonary artery and aligned them in a linear fashion directly into the sheath for uneventful removal.

Index terms Endovascular Procedures; Vertebroplasty; Bone Cements; Embolism; Right Atrium

Received August 20, 2020
Revised September 28, 2020
Accepted September 30, 2020






***Corresponding author**

Jae Woo Yeon, MD
Department of Radiology,
Daejin Medical Center
Bundang Jesaeng General
Hospital, 23 Hwangsaeng-ro
341beon-gil, Bundang-gu,
Seongnam 13590, Korea.

Tel 82-31-779-0000
Fax 82-31-779-0062
E-mail jwoyeon@dmc.or.kr

This is an Open Access article distributed under the terms of the Creative Commons Attribution Non-Commercial License (<https://creativecommons.org/licenses/by-nc/4.0>) which permits unrestricted non-commercial use, distribution, and reproduction in any medium, provided the original work is properly cited.

ORCID iDs

Sunhyang Lee 
[https://
orcid.org/0000-0002-4817-0231](https://orcid.org/0000-0002-4817-0231)
Jae Woo Yeon 
[https://
orcid.org/0000-0002-0516-1220](https://orcid.org/0000-0002-0516-1220)
Jin-Tae Kwon 
[https://
orcid.org/0000-0003-0134-8781](https://orcid.org/0000-0003-0134-8781)
Hyuk Jung Kim 
[https://
orcid.org/0000-0002-4629-4142](https://orcid.org/0000-0002-4629-4142)
Suk Ki Jang 
[https://
orcid.org/0000-0002-8625-7573](https://orcid.org/0000-0002-8625-7573)

INTRODUCTION

Percutaneous vertebroplasty (PVP) is a minimally invasive and safe procedure that is commonly used for patients with vertebral compression fracture (1). The most popular bone cement is polymethylmethacrylate-based acrylic bone cement, which is injected directly into the vertebral body. Although it is a relatively safe procedure, the rate of complications due to PVP may vary from 1% to 10%, with cement extravasation into the venous system in up to 24% of patients because bones are highly vascular structures (2). Cardiopulmonary cement embolism is often seen after PVP and is usually asymptomatic and conservatively treated (3).

Intracardiac cement embolism, however, is a very rare complication of PVP. Because it can lead to fatal outcomes, intracardiac cement embolism is generally removed through open heart surgery (4). Three case reports, however, reported removal of intracardiac embolism by an endovascular procedure, with a less invasive approach than surgery but the same favorable outcome (5-7). We report another successful case of endovascular removal of a bone cement embolism in the right atrium (RA). In the middle of the procedure, the embolus broke in half and migrated to the right pulmonary artery (RPA), but the fragments were safely removed by a bidirectional capture technique.

CASE REPORT

A 72-year-old male visited our hospital for removal of a foreign body in the RA without any symptoms. It was incidentally found on echocardiography to evaluate the cause of new-onset hypertension at another hospital, and a physician transferred the patient to our hospital. The patient had PVP on L1 and L2 for compression fractures a year ago. In addition, he had a bicycle accident and underwent open reduction and internal fixation for a right clavicle fracture a month ago. He was not taking any medication. On physical examination, the vital signs were within normal limits. Abnormal laboratory findings were not observed, with a normal range of cardiac troponins. The electrocardiogram was normal, except for mild left ventricular hypertrophy. Echocardiography revealed echogenic material in the RA (not shown), with no regional wall motion abnormalities, tricuspid valve regurgitation, and mildly increased systolic pulmonary artery pressure (35 mm Hg). Chest radiography (CXR) showed an opaque curvilinear lesion in the RA and bone cements in L1 and L2 with probably extravasating cement from L2 to the inferior vena cava (IVC) (Fig. 1A), which raised the suspicion of bone cement intracardiac embolism. A cardiac computed tomography (CT) scan displayed a bright curvilinear object with a pointed tip against the RA inferior wall (Fig. 1B). Based on the imaging findings, it was suspected to be a bone cement embolism from the previous PVP. This linear structure probably escaped into the IVC and then lodged in the RA. Since there was concern for possible wall injury of the right heart on the cardiac CT, we discussed retrieval of the bone cement embolism, and the patient was very interested in transcatheter retrieval. After reviewing the benefits, risks, and complications, informed consent was obtained for endovascular removal of the cement embolism.

The endovascular procedure was performed using local anesthesia around the puncture site without sedation of the patient. A 20-French sheath was positioned in the right internal

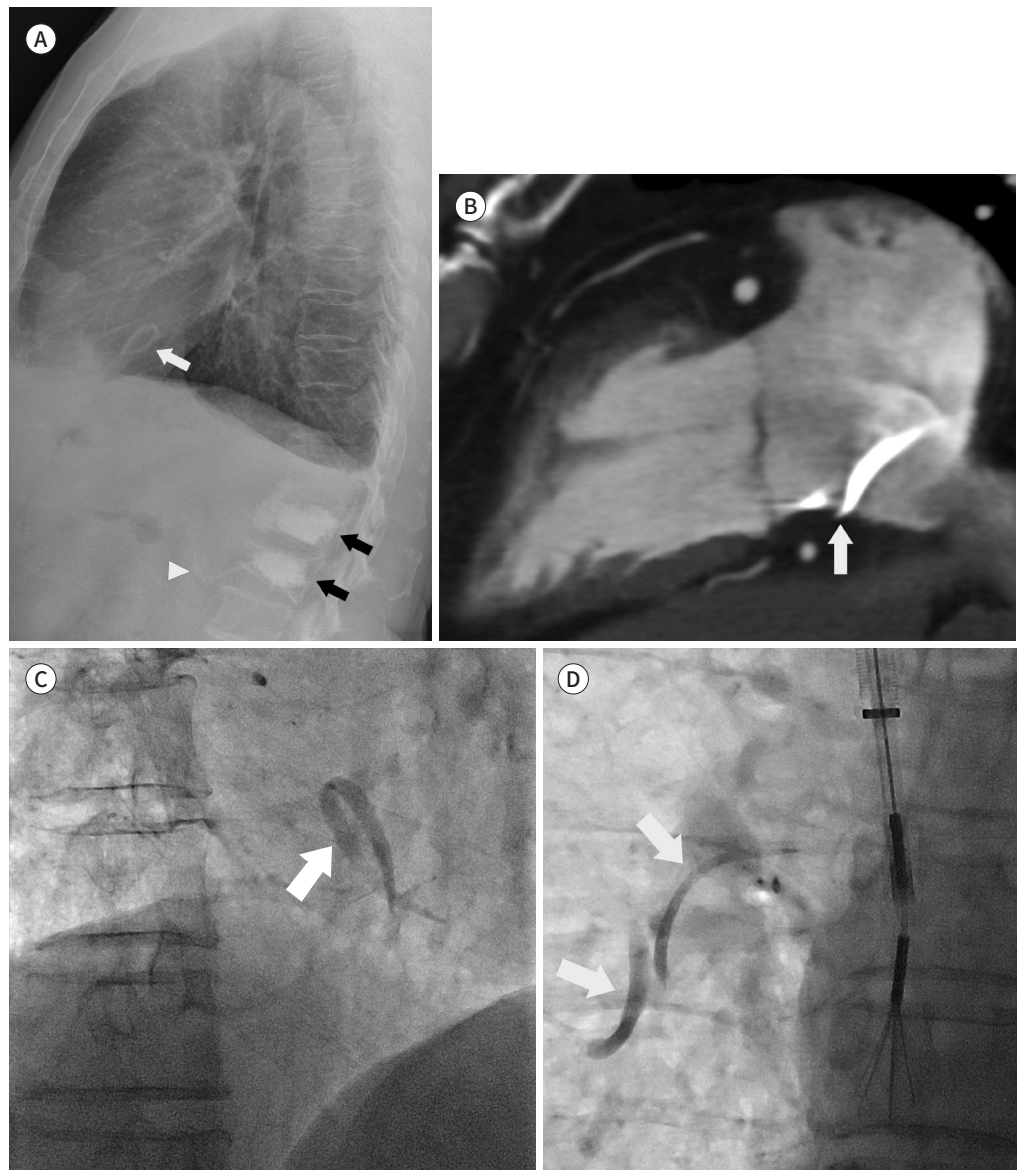
Fig. 1. A 72-year-old male with a foreign body in the RA, identified as bone cement embolism.

A. Left lateral view of chest radiography shows a curvilinear opacity (white arrow) in the RA. Further, it shows bone cements injected into the lumbar vertebrae (black arrows) with possible extravasation of cement from the L2 to the inferior vena cava (arrowhead).

B. Two-chamber view of cardiac CT with contrast enhancement shows a bright curvilinear bone cement embolism in the RA, adjacent to the inferior wall (arrow).

C. Fluoroscopic spot image demonstrates an embolus (arrow) within the RA.

D. The embolus is broken in half, and the fragments (arrows) have migrated to the right pulmonary artery. RA = right atrium



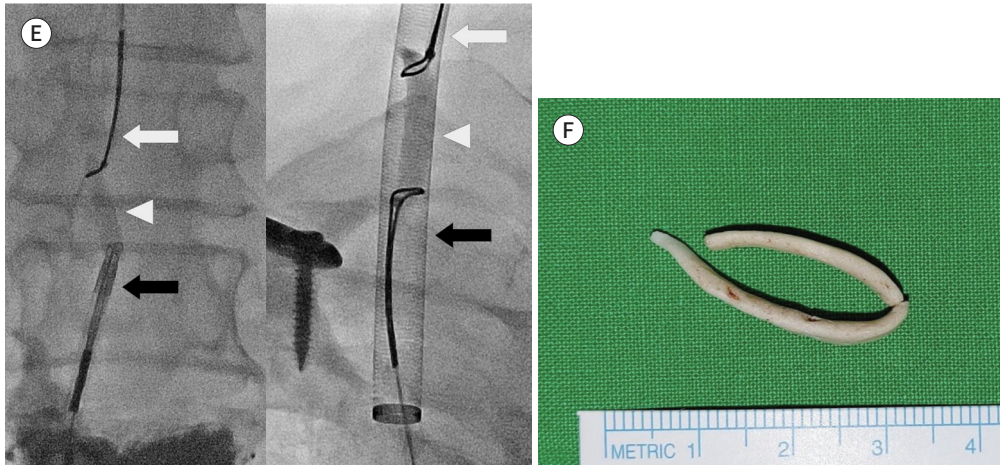
jugular vein (RIJV) after ultrasound-guided access. Heparin was not administered. Fluoroscopy showed that the entire cement embolism appeared within the RA and was fluttering along with the heartbeat (Fig. 1C). An ALN vena cava filter retrieval device (ALN Implants Chirurgicaux; Ghisonaccia, France) was advanced through the sheath into the RA. The device was advanced over the superior end of the embolus and pulled superiorly. At that time,

Fig. 1. A 72-year-old male with a foreign body in the RA, identified as bone cement embolism.

E. The emboli were removed using the two-snare technique: the left embolus first and then the right embolus. The two snares were aligned with the embolus to pass through the vertically oriented sheath. The internal jugular snare (white arrows), embolus (white arrowheads), and femoral filter retrieval device (left, black arrow)/snare (right, black arrow) are seen.

F. Clinical photograph shows a 6-cm-long U-shaped cement material, with the arms measuring 3.5 cm and 2.5 cm, which was finally removed from the right pulmonary artery.

RA = right atrium



the embolus broke in half and migrated to the RPA (Fig. 1D). To remove the migrated fragments and ensure successful removal, a different technique was needed. We additionally placed an 18-French sheath in the right common femoral vein (RCFV) and advanced the filter retrieval device, with the tip positioned in the RA. Through the RIJV sheath, a 20 mm Amplatz Goose Neck Snare Kit (ev3 Inc; Plymouth, MI, USA) was advanced into the RPA over the end of one embolus. The snare was tightened firmly onto the embolus and carefully pulled it from the RPA to the RA. Then, the filter retrieval device caught the embolus inferiorly, with the snare from the RIJV sheath still firmly holding the superior end of the embolus. The retrieval device was pulled slowly and steadily, aligning the inferior tip of the embolus, and the device was pulled directly into the orifice of the sheath in the RCFV (Fig. 1E, left). The other embolus remaining in the RPA was pulled superiorly into the RIJV sheath, with both snares attached (Fig. 1E, right). All emboli were removed through the sheath and were identified as two solidified cement materials, totally about 6 cm long (Fig. 1F). All sheaths were removed, and hemostasis was achieved with direct pressure. He was observed overnight. The following morning, a chest X-ray and echocardiogram were performed, confirming normal heart size and no pericardial or pleural effusion. He was discharged without any sequelae.

DISCUSSION

PVP for compression fracture has been a treatment of choice for more than 30 years. Bone cement leakage is the main complication of PVP. The suggested pathophysiology of cardiopulmonary cement embolism is that cement leakage into the paravertebral intravascular space and IVC can drift toward the right heart and pulmonary arterial system (4). The incidence of cardiopulmonary cement embolism after PVP varies from 2.1% to 26%, since the

patients are not routinely screened for cement embolism and its symptoms occur more commonly days to months after, rather than during the procedure (1). Symptoms of cardiopulmonary cement embolism include chest pain, dyspnea, cyanosis, palpitation, and arrest, although some patients are asymptomatic (8).

The bone cement used in PVP has a high density; thus, the visualization of cement emboli on CXR can be obvious. However, it is difficult to identify subtle scattered strands of cement emboli in certain cases (3). Multiple branching opacities can also be commonly seen scattered randomly or diffusely throughout the lungs (1). In our patient, CXR showed an opaque curvilinear lesion in the RA without significant scattered lesions in the lung. Echocardiography is a good modality to evaluate hemodynamic status and to probably detect echogenic material in cardiac chambers. Our patient also showed an echogenic material in RA on echocardiography (not shown). A CT scan can show more details of the locations, lengths, and the number of cement emboli. In our case, the CT showed a pointed tip of the embolus against the RA lateral wall, increasing the concern of RA wall perforation by the tip.

Intracardiac cement embolism is a rare complication of PVP. A review of the literature revealed only 21 case reports of intracardiac cement embolism (1, 4-7, 9). Most of them were diagnosed within the short term after PVP due to the symptoms. Because our patient was asymptomatic except for hypertension, the intracardiac cement embolism was found by chance about a year after the PVP.

The treatment of cardiopulmonary cement embolism can be variable, commonly by close cardiopulmonary monitoring for asymptomatic peripheral cases, anticoagulation for symptomatic peripheral and asymptomatic central emboli, and surgical treatment for symptomatic central embolism. Above all, intracardiac emboli can cause serious complications, such as perforation, pericardial tamponade, and pericardial perforation, which may result in the need for major surgical procedures or fatalities (4). For example, Prokop et al. (8) reported a surgical case of cardiac perforation that developed 2.5 years after PVP in an asymptomatic patient. It could be reasonable to remove large intracardiac cement embolism based on this case, even if asymptomatic. In the previous 21 cases of intracardiac cement embolism, 17 patients underwent open-heart surgery, 3 patients' cements were removed by catheterization (5-7), and 1 patient's 13 cm long cement embolism was removed through a combination of an endovascular procedure and IVC exploration due to its large size (9).

Transcatheter retrieval of a foreign body is usually performed using a single snare catheter or other retrieval device, as we initially attempted to do. When the filter retrieval device captured the embolus in the beginning of the procedure, because it was curvilinear-shaped, long, and very rigid structure, it was extremely difficult to remove through the sheath. Continued pulling of the retrieval device might have broken the embolus in half and freed the fragments, allowing them to embolize pulmonary arteries. We had already considered the possibility of embolus fracture, so we separated the fragment from the RPA using the snare. By using the bidirectional retrieval technique, while continuing to hold onto the fragment using the snare, we use the filter retrieval device to manipulate the inferior tip of the rigid fragment directly into the 18-French sheath orifice, removing it completely. Second, we used two snares instead of the filter retrieval device, because it felt easier to handle. With the second fragment removed through the RIJV 20-French sheath without residual fragment, the

patient had an uneventful recovery and was discharged to home. Based on 4 cases, including our case, which used an endovascular procedure to remove intracardiac cement embolism, all of the cases used the second snare catheter for the 180° direction to the first snare (5-7). Two vascular sheaths and the bidirectional retrieval technique, using two snare catheters, can facilitate a quicker and more favorable outcome for certain types of intracardiac cement embolism: linear-shaped and less than 6 cm long.

In conclusion, intracardiac cement embolism after PVP was diagnosed and successfully removed by bidirectional retrieval technique using two snares and a filter retrieval device. Because intracardiac cement embolism can cause severe outcomes, surgeons should consider the possibility of intracardiac cement embolism after PVP though the patient has minimal symptoms or is even asymptomatic. An endovascular procedure may be a reasonable treatment option to minimize the surgical procedure in cases of a linear intracardiac cement embolism. The interventionist must be aware of the possibility of embolic fracture during endovascular removal.

Author Contributions

Writing—original draft, L.S., Y.J.W.; and writing—review & editing, all authors.

Conflicts of Interest

The authors have no potential conflicts of interest to disclose.

Funding

None

REFERENCES

1. Rahimi B, Boroofeh B, Dinparastisaleh R, Nazifi H. Cement pulmonary embolism after percutaneous vertebroplasty in a patient with cushing's syndrome: a case report. *Respir Med Case Rep* 2018;25:78-85
2. Hatzantonis C, Czyz M, Pyzik R, Boszczyk BM. Intracardiac bone cement embolism as a complication of vertebroplasty: management strategy. *Eur Spine J* 2017;26:3199-3205
3. Adu-Gyamfi KO, Patri S. Symptomatic cardiopulmonary cement embolism following vertebroplasty. *BMJ Case Rep* 2019;12:e230603
4. Audat ZA, Alfawareh MD, Darwish FT, Alomari AA. Intracardiac leakage of cement during kyphoplasty and vertebroplasty: a case report. *Am J Case Rep* 2016;17:326-330
5. Braiteh F, Row M. Right ventricular acrylic cement embolism: late complication of percutaneous vertebroplasty. *Heart* 2009;95:275
6. Mattis T, Knox M, Mammen L. Intracardiac methylmethacrylate embolism resulting in right atrial wall perforation and pericarditis following percutaneous vertebroplasty. *J Vasc Interv Radiol* 2012;23:719-720
7. Grifka RG, Tapio J, Lee KJ. Transcatheter retrieval of an embolized methylmethacrylate glue fragment adherent to the right atrium using bidirectional snares. *Catheter Cardiovasc Interv* 2013;81:648-650
8. Prokop A, Hägele M, Pfeilsticker U, Koll S, Chmielnicki M. Pericardial perforation 2.5 years after kyphoplasty. A rare complication after cement extravasation. *Unfallchirurg* 2013;116:80-84
9. Park JS, Kim J, Lee Y, Gwon JG, Park YS. Intra-cardiac embolism of a large bone cement material after percutaneous vertebroplasty removed through a combination of an endovascular procedure and an inferior vena cava exploration: a case report. *J Korean Med Sci* 2018;33:e141

경피적 척추성형 후 발생한 우심방 내 골 시멘트 색전의 도관경유제거술: 시술 중 두 동강나 우폐동맥으로 이동한 색전

이선희¹ · 연재우^{1*} · 권진태² · 김혁중¹ · 장석기¹

골 시멘트 색전은 경피적 척추성형 후 드물지 않게 발생하는 합병증이다. 이는 보통 작은 폐동맥 색전이고 대부분 무증상이기 때문에 치료를 필요로 하지 않는다. 하지만 심장 내에 생긴 골시멘트 색전은 매우 드물며, 치명적인 결과를 야기할 수 있다. 이전 보고된 증례들은 심장 내 골시멘트 색전을 주로 개심수술을 통해 제거하였으며, 중재시술로 제거한 것은 3개 증례만 보고되어 있었다. 따라서 저자들은 경피적 척추성형 후 발생한 우심방 내 6 cm 크기의 골 시멘트 색전을 도관경유로 안전하게 제거한 1예를 보고하고자 한다. 색전이 시술 중에 두 동강나 우폐동맥으로 이동하였으나 두 개의 스네어와 하나의 필터 제거 장치를 이용하여 서로 반대 방향에서 접근시켜 우폐동맥 내의 색전 조각들을 조심스럽게 잡아 끌어낸 후 쉬스와 일렬로 만들어 제거하였으며, 시술 후 합병증은 발생하지 않았다.

분당제생병원 ¹영상의학과, ²흉부외과