



Tumor Seeding after Percutaneous Transthoracic Needle Biopsy of Metastatic Pulmonary Ameloblastoma

경피적 흉부 생검 이후에 발생한 전이성 폐 법랑모세포종의 종양 파종

Hye Mi Park, MD¹ , Yun Hyeon Kim, MD^{2*} , Hyo Soon Lim, MD¹ ,
So Yeon Ki, MD¹ , Hyo-jae Lee, MD¹ ,
Jong Eun Lee, MD² , Won Gi Jeong, MD¹

¹Department of Radiology, Chonnam National University Hwasun Hospital, Hwasun, Korea

²Department of Radiology, Chonnam National University Hospital, Gwangju, Korea

Percutaneous transthoracic needle biopsy (PTNB) is a minimally-invasive procedure that is an indispensable tool for evaluating pulmonary lesions. Though extremely rare, tumor seeding of the pleura and chest wall can occur as a complication. Given that the breast is located anterior to the thorax, needle tracking through the breast is inevitable when PTNB is performed using the anterior approach. We describe tumor seeding of metastatic pulmonary ameloblastoma in the pectoralis muscle layer of the breast along the needle track of PTNB in a 51-year-old female presenting with a palpable lump in the right breast.

Index terms Biopsy; Neoplasm Metastasis; Ameloblastoma

INTRODUCTION

CT-guided percutaneous transthoracic needle biopsy (PTNB) is frequently performed and an effective, highly accurate, and safe method for the diagnosis of pulmonary disease requiring pathological confirmation (1). Pneumothorax and pulmonary hemorrhage are the most common complications of PTNB of the chest, whereas air embolism and tumor seeding are extremely rare (2). The reported incidence of tumor seeding after PTNB is 0.01–0.06% (3, 4).

Herein we report a rare case of tumor seeding along the needle track after PTNB of metastatic pulmonary ameloblastoma in a 51-year-old female.

Received September 7, 2020

Revised October 12, 2020

Accepted October 29, 2020

*Corresponding author

Yun Hyeon Kim, MD
Department of Radiology,
Chonnam National University
Hospital, 42 Jebong-ro, Dong-gu,
Gwangju 61469, Korea.

Tel 82-62-220-5746

Fax 82-62-226-4380

E-mail yhkim001@jnu.ac.kr

This is an Open Access article distributed under the terms of the Creative Commons Attribution Non-Commercial License (<https://creativecommons.org/licenses/by-nc/4.0>) which permits unrestricted non-commercial use, distribution, and reproduction in any medium, provided the original work is properly cited.

ORCID iDs

Hye Mi Park

[https://](https://orcid.org/0000-0002-9920-3400)

orcid.org/0000-0002-9920-3400

Yun Hyeon Kim

[https://](https://orcid.org/0000-0002-0047-0729)

orcid.org/0000-0002-0047-0729

Hyo Soon Lim

[https://](https://orcid.org/0000-0001-6742-499X)

orcid.org/0000-0001-6742-499X

So Yeon Ki

[https://](https://orcid.org/0000-0002-8387-3135)

orcid.org/0000-0002-8387-3135

Hyo-jae Lee

[https://](https://orcid.org/0000-0001-7770-6800)

orcid.org/0000-0001-7770-6800

Jong Eun Lee

[https://](https://orcid.org/0000-0003-1476-6608)

orcid.org/0000-0003-1476-6608

Won Gi Jeong

[https://](https://orcid.org/0000-0003-2821-2788)

orcid.org/0000-0003-2821-2788

CASE REPORT

A 51-year-old female visited our hospital complaining of a palpable mass in her right breast. On physical examination, an approximately 3 cm mass was palpated in the upper inner quadrant of the right breast. No axillary lymphadenopathy was palpable. She had an operation history of right upper lobe lobectomy for pulmonary mass after PTNB approximately 8 months ago. She had an operation history of surgical resection for odontogenic tumor about 13 years ago. She knew it was a benign neoplasm, but could not remember the exact histological diagnosis.

8 months ago, a 2.6 cm lobulated enhancing nodule was incidentally detected in the anterior segment of the right upper lobe. For the histologic diagnosis of the nodule, the patient underwent PTNB. Before the biopsy, the patient was verified to be able to follow the breathing instructions. With the patient lying in the supine position, a radiopaque marker is placed on the patient's skin over the area of interest to focus on the optimal access point. The depth from the skin entry site to the lesion was approximately 3.5 cm. The local anesthetic was infiltrated into the subcutaneous tissues. Then, an experienced chest radiologist advanced a 20-gauge cutting needle into the lesion of interest vertically and obtained the specimen twice. Following removal of the biopsy needle, a small amount of hemorrhage was seen in the right upper lobe of the lung.

The bilateral mammogram showed no mass or microcalcifications in either breast. On sonographic examination, an approximately 2.8 cm, oval circumscribed hypoechoic mass was detected within the pectoralis muscle layer of the right inner breast (Fig. 1A). Because she had a history of right upper lobe lobectomy after PTNB 8 months previously with metastasizing ameloblastoma, an ultrasound-guided core needle biopsy was performed to rule out metastasis. On microscopic examination, histologic features of the mass were similar to those of the lung; therefore, the lesion was diagnosed as metastatic ameloblastoma.

For evaluation of palpable breast mass, chest CT was scanned. Chest CT images showed an oval heterogeneous enhancing mass with a well-defined margin in the right pectoralis muscle. Compared to previous biopsy scans, the developing chest wall mass corresponds to the path of the previous biopsy needle canal (Fig. 1B, C). It was considered as tumor seeding through the needle track after PTNB. The patient underwent fluorine-18-fluorodeoxyglucose PET/CT (¹⁸F-FDG PET/CT) for staging. PET/CT revealed hypermetabolic lesions in the thoracic vertebra, left 2nd and 3rd ribs, sacrum, and right pectoralis muscle (Fig. 1D). These were not visible on the previous PET/CT scan about 8 months ago (Fig. 1E). The patient underwent systemic chemotherapy; however, the patient showed progressive disease.

DISCUSSION

CT-guided PTNB is widely performed to evaluate the nature of pulmonary nodules. Although the procedure is very safe when performed by appropriately trained and experienced physicians, several complications such as pneumothorax, hemorrhage, air embolism, and tumor seeding can occur (2). Pneumothorax is the most common complication of needle aspiration or biopsy of the lung, which is reported to occur in 17–23% of patients, and pulmo-

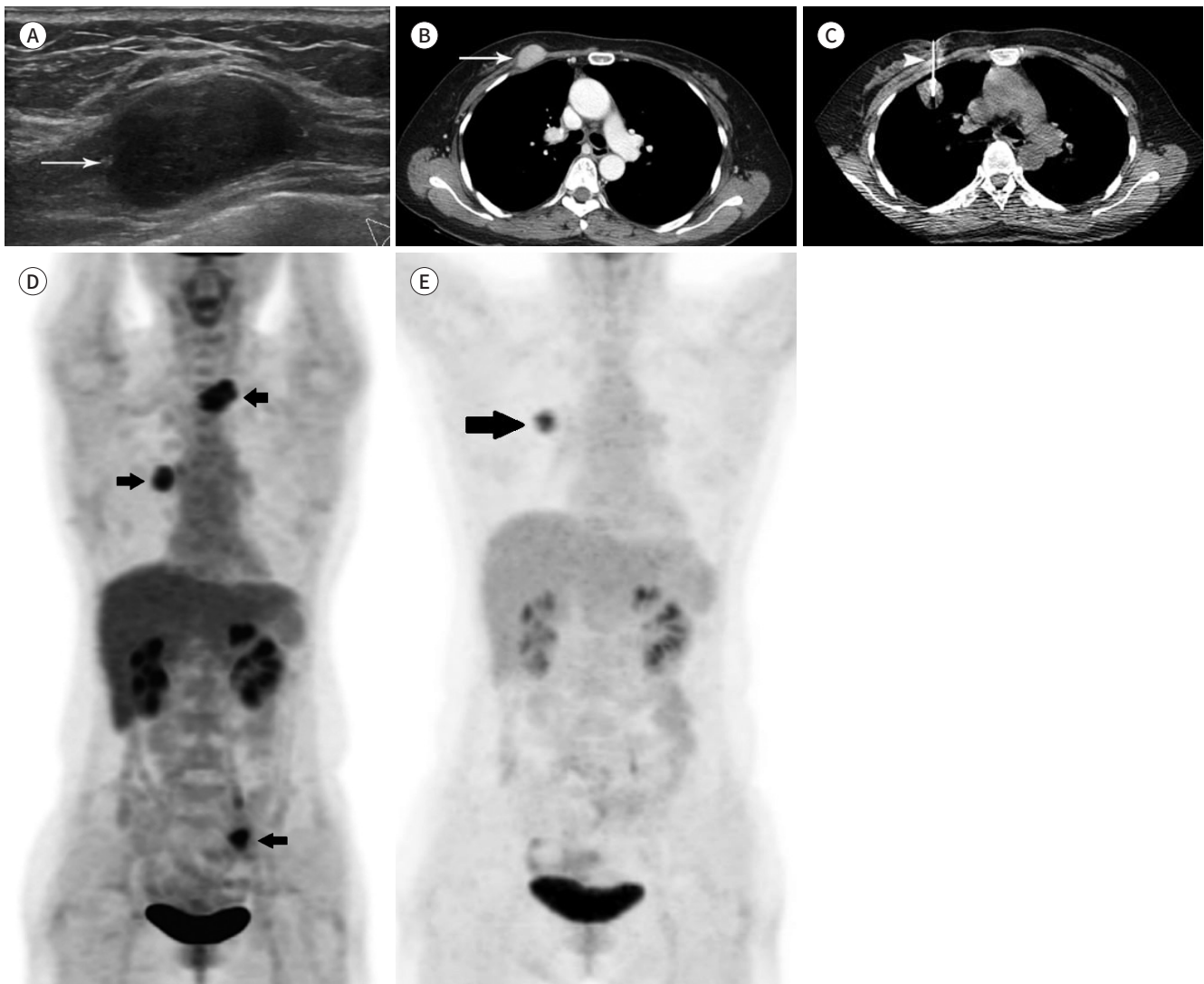
Fig. 1. Tumor seeding in the needle track after PTNB.

A. Sonogram shows an oval hypoechoic mass (arrow) in the pectoralis muscle of the right inner breast.

B, C. Chest CT image shows an oval enhancing mass (arrow in **B**) with a well-defined margin in the pectoralis muscle layer of the right breast. The mass is located in the pathway of needle insertion of PTNB (arrowhead in **C**). Chest CT image obtained during PTNB through the anterior approach 8 months before (**C**).

D, E. Maximum intensity projection reconstruction of a PET image shows FDG uptake in the right thoracic wall, vertebrae and left ribs, and sacrum (arrows in **D**). These lesions were not visible on previous PET images about 8 months ago. Maximum intensity projection reconstruction of a previous PET image shows only FDG uptake of pulmonary ameloblastoma in the right upper lobe of the lung (arrow in **E**).

FDG = fluorodeoxyglucose, PTNB = percutaneous transthoracic needle biopsy



nary hemorrhage is the second most common complication, with reported frequencies ranging from 4% to 27% (5, 6).

Tumor seeding of the pleura or chest wall along the needle track is extremely rare, and the exact mechanism of tumor cell implantation is still unclear. Ayar et al. (3) reported that the incidence of tumor seeding after PTNB was 0.012% and the average interval between PTNB and needle-track metastasis was 2.6 months. There were no predictable risk factors related to needle size, tumor size, or tumor location. In contrast, Tomiyama et al. (4) reported that

tumor seeding appeared to depend on the size of the needle; therefore, large-bore needles carry a relatively greater risk of tumor seeding. They suggested that CT-guided biopsy performed using the coaxial method has a lower frequency of tumor seeding as the outer cannula minimizes direct contact of the tumor cells with the biopsy route (4). Although we used the coaxial method in our case, tumor seeding was unavoidable. Wide en bloc resection can be performed if the needle track metastasis is isolated to the chest wall without evidence of distant metastases (2).

Patient positioning during PTNB should be chosen based on the location and size of the lesion and the patient's ability to tolerate positioning (1). It is recommended that the patient be positioned in the supine or prone position to avoid crossing the interlobar fissure with the biopsy needle, thus reducing the risk of pneumothorax (7). During the anterior approach in the supine position for mid-lung lesions, needle tracking through the breast is inevitable and tumor seeding to the chest wall after PTNB can occur. This patient underwent right lobectomy after CT-guided PTNB for the mass in the anterior segment of the right upper lobe, which revealed metastatic pulmonary ameloblastoma.

Ameloblastomas are rare, slow-growing, benign odontogenic epithelial tumors. Tumor metastasis has been reported to be a remarkably late event by 18 years after primary tumor treatment (8). The incidence of metastasis has been reported to be only 2% (9). Van Dam et al. (8) reported a summary of the clinical findings of 27 patients with metastasizing ameloblastoma. In this report, the rate of metastatic site is as follows: 78% of lung and extrapulmonary metastasis (15% of lymph nodes and 7% of the spine). Metastasis to the lungs reveals multiple pulmonary nodules bilaterally, usually followed by multiple failed attempts at primary tumor control. The mechanism by which ameloblastoma metastasizes has been controversial, but the hematogenous route has been generally favored as the most likely route of spread because most tumors metastasized to bilateral and multiple lung fields, without accompanying lymph node metastasis (8). In this case, the presence of a tumor along the previous biopsy needle canal in the chest wall, where metastasis is rare, supports that metastatic tumor occurred by tumoral seeding after PTNB.

In summary, we report a case of tumor seeding after PTNB who presented with a palpable breast lump. Although rare, it should be included in the differential diagnosis of chest wall or breast mass, especially for the mass occurring along the needle track in a patient with a history of PTNB or percutaneous procedure. In addition, histological examination should be performed to rule out the possibility of tumor seeding despite benign imaging findings.

Author Contributions

Conceptualization, K.Y.H., P.H.M.; data curation, L.H.S., P.H.M.; investigation, P.H.M.; supervision, K.Y.H.; visualization, L.H.S.; writing—original draft, P.H.M., K.Y.H.; and writing—review & editing, all authors.

Conflicts of Interest

Yun Hyeon Kim has been an Editorial Board Member of Journal of the Korean Society of Radiology since 2003; however, he was not involved in the peer reviewer selection, evaluation, or decision process of this article. Otherwise, no other potential conflicts of interest relevant to this article were reported.

Funding

None

REFERENCES

1. Winokur RS, Pua BB, Sullivan BW, Madoff DC. Percutaneous lung biopsy: technique, efficacy, and complications. *Semin Intervent Radiol* 2013;30:121-127
2. Wu CC, Maher MM, Shepard JA. Complications of CT-guided percutaneous needle biopsy of the chest: prevention and management. *AJR Am J Roentgenol* 2011;196:W678-W682
3. Ayar D, Golla B, Lee JY, Nath H. Needle-track metastasis after transthoracic needle biopsy. *J Thorac Imaging* 1998;13:2-6
4. Tomiyama N, Yasuhara Y, Nakajima Y, Adachi S, Arai Y, Kusumoto M, et al. CT-guided needle biopsy of lung lesions: a survey of severe complication based on 9783 biopsies in Japan. *Eur J Radiol* 2006;59:60-64
5. Yeow KM, Su IH, Pan KT, Tsay PK, Lui KW, Cheung YC, et al. Risk factors of pneumothorax and bleeding: multivariate analysis of 660 CT-guided coaxial cutting needle lung biopsies. *Chest* 2004;126:748-754
6. Khan MF, Straub R, Moghaddam SR, Maataoui A, Gurung J, Wagner TO, et al. Variables affecting the risk of pneumothorax and intrapulmonary hemorrhage in CT-guided transthoracic biopsy. *Eur Radiol* 2008;18:1356-1363
7. Wu CC, Maher MM, Shepard JA. CT-guided percutaneous needle biopsy of the chest: preprocedural evaluation and technique. *AJR Am J Roentgenol* 2011;196:W511-W514
8. Van Dam SD, Unni KK, Keller EE. Metastasizing (malignant) ameloblastoma: review of a unique histopathologic entity and report of Mayo Clinic experience. *J Oral Maxillofac Surg* 2010;68:2962-2974
9. Yun JS, Kim DW, Kim SS, Choi YD, Song SY, Na KJ. Metastatic pulmonary ameloblastoma misdiagnosed as primary squamous cell carcinoma preoperatively. *Korean J Thorac Cardiovasc Surg* 2014;47:63-65

경피적 흉부 생검 이후에 발생한 전이성 폐 법랑모세포종의 종양 파종

박혜미¹ · 김윤현^{2*} · 임호순¹ · 기소연¹ · 이효재¹ · 이종은² · 정원기¹

경피적 흉부 생검은 폐 병변을 병리학적으로 진단하는 데 있어서 필수적인 최소 침습 시술이다. 매우 드물기는 하지만 흉막과 흉벽에 종양의 파종이 경피적 흉부 생검의 합병증으로 생길 수 있다. 유방은 흉곽의 앞쪽에 위치하기 때문에 경피적 흉부 생검 시 흉곽의 앞쪽에서 접근할 때 바늘이 유방을 지나는 것을 피할 수 없는 경우가 있다. 이에 저자들은 유방의 만져지는 종괴로 내원한 51세 여성에서 경피적 흉부 생검 경로를 따라 생긴 전이성 폐 법랑모세포종의 파종을 경험하였기에 영상 소견과 함께 증례 보고한다.

¹화순전남대학교병원 영상의학과,

²전남대학교병원 영상의학과