








Efficacy of Fluoroscopy-Guided Lumbar Facet Joint Synovial Cyst Rupture with Intra-Articular Steroid Injection after Laminectomy

척추 후궁절제술 이후 발생한 요추 후관절 활액낭에서 투시유도 하 낭종파열술 및 관절 내 스테로이드 주입술의 임상적 경험

Hyo Jin Kim, MD^{1,2} , Eugene Lee, MD^{1*} , Joon Woo Lee, MD¹ ,
Yusuhn Kang, MD¹ , Joong Mo Ahn, MD¹ 

¹Department of Radiology, Seoul National University Bundang Hospital, Seongnam, Korea

²Department of Radiology, SMG-SNU Boramae Hospital, Seoul, Korea

Purpose We retrospectively evaluated the technical success rate and long-term efficacy of fluoroscopy-guided synovial cyst rupture followed by an intra-articular steroid injection at the post-laminectomy lumbar facet.

Materials and Methods We selected subjects who had undergone a fluoroscopy-guided synovial cyst rupture with simultaneous intra-articular steroid injection within 6 months of MRI and demonstrated a symptomatic facet joint synovial cyst at the level of a previous lumbar laminectomy. Fourteen patients were enrolled, and we determined whether cyst rupture and symptom improvement were achieved after each procedure. The degrees of symptom improvement were categorized into 4: 1) symptoms improved (30% or more reduction, based on pre-procedural and post-procedural Numerical Pain Rating Scale scores), 2) symptoms not improved, 3) patient underwent surgery after injection, and 4) loss of follow-up.

Results The success rate of percutaneous synovial cyst rupture decreased with repeated procedures (62.5% for the first procedure and 0% to 33.3% for additional procedures). However, 80% of the patients had symptom improvement with the procedures, overall. The surgery rate was 14.3% in 14 patients.

Conclusion For patients with post-laminectomy symptomatic lumbar facet joint synovial cysts, fluoroscopy-guided synovial cyst rupture with intra-articular steroid injection may be an effective and less invasive treatment before considering a surgical approach.

Index terms Spine; Synovial Cyst; Radiculopathy; Fluoroscopy; Laminectomy

Received November 14, 2019

Revised March 11, 2020

Accepted July 15, 2020

*Corresponding author

Eugene Lee, MD

Department of Radiology,

Seoul National University

Bundang Hospital,

82 Gumi-ro 173beon-gil,

Bundang-gu, Seongnam 13620,

Korea.

Tel 82-31-787-7627

Fax 82-31-787-4011

E-mail eugene801027@gmail.com


This is an Open Access article distributed under the terms of the Creative Commons Attribution Non-Commercial License (<https://creativecommons.org/licenses/by-nc/4.0>) which permits unrestricted non-commercial use, distribution, and reproduction in any medium, provided the original work is properly cited.

ORCID iDs

Hyo Jin Kim 


<https://>

orcid.org/0000-0002-0549-5722

Eugene Lee 

<https://>

orcid.org/0000-0003-4205-2362

Joon Woo Lee 


<https://>

orcid.org/0000-0002-7106-5229

Yusuhn Kang 

<https://>

orcid.org/0000-0003-1838-2564

Joong Mo Ahn 

<https://>

orcid.org/0000-0002-1157-0020

INTRODUCTION

Synovial cysts of the spine are connected to the facet joint, and contain synovial lining. Degenerative spondylosis, spinal instability, and trauma can all promote the development of synovial cysts (1). Synovial cysts occur most frequently in the lumbar spine, with up to 80% being found at the level of L4–L5 (2, 3), and the incidence of these cysts detected on MRI ranges from 0.8% to 2.0%. Synovial cysts can cause both thecal sac and lateral recess nerve root compression, resulting in lower limb radicular pain, neurogenic claudication, sensory loss, and motor weakness (4). These cysts seldom resolve spontaneously (5).

Surgical excision with or without segmental fusion is the standard treatment of symptomatic synovial cysts; however, complications can result from surgery, including cerebrospinal fluid leak, epidural hematoma, discitis, and the risks inherent to general anesthesia (3). Therefore, patients, especially the elderly and those with medical comorbidities can benefit from fluoroscopy or CT-guided percutaneous procedures (6, 7) such as percutaneous lumbar facet joint synovial cyst rupture with intra-articular steroid injection (8). Previous studies have reported that fluoroscopy or CT-guided lumbar facet joint synovial cyst rupture was technically successful in 76.7% to 100% of procedures (9-11), and repeat procedures were required in 20% to 50.5% (9-12). After percutaneous procedures, lumbar spine surgery was needed in 10% to 54.5% of patients (9-12). Serial reports have confirmed the efficacy of this percutaneous therapy, which may delay or negate the need for surgical resection of the cyst(s) (10, 12, 13).

Contrary to studies regarding the success rate and long-term effects of percutaneous procedures for primary pre-operative synovial cysts, there is a lack of research regarding whether the results of performing a cyst rupture with subsequent facet joint injection differs between primary pre-operative and post-laminectomy synovial cysts. Post-laminectomy synovial cysts occur in approximately 8% of lumbar laminectomy cases (14), and can cause symptoms including radiculopathy. The cause of post-operative intra-spinal cyst development remains unknown, but the creation of iatrogenic instability and/or the removal of the ligamentum flavum that normally fuses with the facet capsule (14, 15) have been suggested as possible pathogenic mechanisms for post-operative synovial cysts.

In this study we retrospectively reviewed the technical success rate and long-term efficacy of fluoroscopy-guided synovial cyst rupture with subsequent intra-articular steroid injection to treat lumbar facet joint synovial cyst(s) after laminectomy.

MATERIALS AND METHODS

This study was approved by our institutional review board (IRB No. B-1911-577-110). Given the retrospective nature of this investigation and the use of anonymized patient data, the requirement for informed consent was waived.

STUDY POPULATION

We performed a retrospective search for patients who underwent fluoroscopy-guided facet joint injection at our tertiary hospital from January 1, 2010 to December 31, 2017, whose elec-

tronic medical records contained the keywords “facet cyst”, “facet joint cyst”, “facet joint synovial cyst”, or “synovial cyst,” and selected 72 patients. Among them, we chose subjects who underwent fluoroscopy-guided synovial cyst rupture with a simultaneous intra-articular steroid injection within 6 months of having an MRI demonstrating one or more symptomatic facet joint synovial cysts at the level of a surgical lumbar laminectomy. “A symptomatic facet joint synovial cyst” was defined as a cyst that could explain patient’s radicular pain without other possible cause on MRI. Of the initial 72 subjects, 14 subjects (male:female = 1:1, mean age 69.4 ± 2.9 years) and 16 synovial cysts were enrolled. The reason for the lumbar laminectomy was stenosis in 10 subjects, herniated intervertebral disc in 3 subjects, and unknown in 1 subject (surgery was performed from the outside). The most commonly level operated on was L4–L5, followed by L5–S1 (Table 1).

FLUOROSCOPY-GUIDED PROCEDURE TECHNIQUE

All facet joint injections were performed in the department of radiology by one of three spine interventional radiologists, each having 1 year, 7 years, and 16 years of experience in spinal injections. With the patient in the prone position under single plane fluoroscopy (Integris Allura Xper FD 20; Philips, Amsterdam, the Netherlands), appropriate sterile preparation was performed. To define the lumbar facet joints, the image intensifier was obliquely tilted and a 22-gauge spinal needle was inserted parallel to the X-ray beam, targeting the inferior recess of the facet joints. Accurate needle position was confirmed with a trace amount of contrast agent (Omnipaque 300, 300 mg iodine per mL; Amersham Health, Princeton, NJ, USA). Then cyst rupture was performed with 5 cc normal saline through the spinal needle. After the cyst rupture, a mixture of 40 mg triamcinolone acetonide suspension (Tanceton, 40 mg per mL; Hanall Pharmaceutical, Seoul, Korea) and 7.5 mg of ropivacaine hydrochloride (Ropiva, 7.5 mg/mL; Hanlim Pharmaceutical, Seoul, Korea) was injected. Patients were monitored for at least 20 minutes following the procedure.

RETROSPECTIVE ASSESSMENT OF FLUOROSCOPY-GUIDED PROCEDURE

One radiologist specialized in musculoskeletal radiology (with 7 years of experience in

Table 1. Details of Laminectomies Previously Performed in Patients

Details	Number
Patients with laminectomy history	14 (male:female = 1:1, mean age 69.4 ± 2.9 years)
Laminectomy only	13
Laminectomy + α	1 (L4–S1 posterior fixation)
Unilateral laminectomy	8 (6 right, 2 left)
Bilateral laminectomy	6
1 level laminectomy	10
2 level laminectomy	4
L2–L3 laminectomy	1
L3–L4 laminectomy	2
L4–L5 laminectomy	11
L5–S1 laminectomy	4

musculoskeletal radiology) retrospectively reviewed whether 1) the needle was successfully placed into the facet joint, 2) visualization of the cyst was achieved, 3) the cyst was successfully ruptured, and 4) any extraspinal leakage of the contrast material existed, based on each procedural image stored in a picture archiving and communication system database. The placement of the needle into the facet joint was considered successful if the contrast material revealed a sigmoid or ovoid shape over the facet joint. Cyst visualization was considered achieved if the contrast material demonstrating the round shape of the cyst correlating with MR imaging. Cyst rupture was considered successful if the contrast material spread into the central intraspinal space. Extraspinal leakage was divided into four categories; the contrast material spreading into the ipsilateral lateral recess, into the ipsilateral neural foramen, into the back muscles, or the contrast material showing a horizontal communication with the contralateral facet joint.

RETROSPECTIVE ASSESSMENT OF CLINICAL COURSE

One radiologist specialized in musculoskeletal radiology (with 1 year of experience in musculoskeletal radiology) evaluated whether symptom improvement was achieved after the procedure by reviewing the patients' electronic medical records. The degree of symptom improvement was divided into 4 categories: 1) symptoms improved [30% or more reduction between the pre-procedural and post-procedural Numerical Pain Rating Scale (NPRS) scores] (16), 2) symptoms not improved, 3) the patient underwent surgery after the injection procedure, and 4) follow-up was lost. Patients' NPRS was routinely checked during their spinal intervention center outpatient clinic visit. For patients who did not revisit the spinal intervention center, we checked their medical records to see if there was any mention of change documented by other departments regarding their NPRS after the spinal injection. In addition, the presence of post-procedural complications was retrospectively reviewed.

RETROSPECTIVE ASSESSMENT OF MR IMAGING CHARACTERISTICS OF THE CYSTS

One radiologist specialized in musculoskeletal radiology (with 1 year of experience in musculoskeletal radiology) reviewed the pre-procedural MRI and recorded the signal intensity of cyst contents [based on T2-weighted images, (a) high signal intensity cysts were cerebrospinal fluid (CSF) isointense or hyperintense, (b) intermediate signal intensity cysts were CSF hypointense but muscle hyperintense, (c) low signal intensity cysts were muscle isointense or hypointense, and when the cyst signal intensity was mixed, the predominant signal was used] (17), and the maximum diameter of the cysts (based on either T2-weighted axial or sagittal plane images, measuring from the outer wall of the hypointense cyst rim to the opposite outer wall) (17, 18).

STATISTICAL ANALYSIS

We evaluated the relationship between the imaging findings of the cysts and the success rate of the cyst rupture after the first procedure. Also, the relationship between the imaging findings of the cysts and surgery rate after the overall procedures was calculated. In addition, the relationship between successful cyst rupture and symptom improvement was analyzed.

Independent *t* test and Fisher’s exact test was used. *p* < 0.05 was considered to indicate statistical significance. All statistical analyses were performed using SPSS Version 23.0 (IBM Corp., Armonk, NY, USA).

RESULTS

Symptoms occurred a mean of 663.8 ± 330.4 days after laminectomy. Mean NPRS score before the first procedure was 7.8 ± 1.2. Mean total follow-up days from the first percutaneous procedure to follow-up loss or surgery was 828.7 ± 646.5 days. Mean interval between the first and the second injection was 242.6 ± 419.1 days (ranged from 35 to 992 days), between the second and the third injection was 95.3 ± 34.2 days (ranged from 56 to 118 days), and between the third and fourth injection was 69.3 ± 18.9 days (ranged from 56 to 91 days). There were no procedure-related complications. The placement of the needle into the facet joint was successful in 100% of the procedures. The rates of cyst visualization, cyst rupture and extraspinal leakage are demonstrated in Table 2. The visualization of cysts was achieved in 66.7 to 100% in each procedure. The success rate of synovial cyst rupture decreased with repeated procedures (62.5% at the first procedure and 0% to 33.3% at repeated procedures). The cysts that did not burst in the prior procedure did not rupture in the subsequent procedure either. The rate of extraspinal leakage was higher in failed rupture cases.

Although the success rate of synovial cyst rupture decreased (from 62.5% to 0%) with repeated procedures, overall 80% of patients (20/25 patients) experienced symptom improvement by procedures (Table 3). In patients with successful cyst rupture, 100% reported ‘improved symptom’. In patients with failed cyst rupture, 61.5% reported ‘improved symptom’. There was a significant relationship between the successful cyst rupture and the rate of patients experiencing ‘improved symptom’ after procedures (*p* = 0.039). However, no significant relationship was observed between the successful cyst rupture and the rate of patients experi-

Table 2. The Rates of Cyst Visualization, Cyst Rupture, and Extraspinal Leakage for Each Procedure

		Cyst Visualization	Cyst Rupture	Extraspinal Leakage			
				Recess	Foramen	Back Muscle	Contralateral Facet Joint
First procedure (<i>n</i> = 16, 59.3%)	(+)	15 (93.8)	(+) 10 (62.5)	1	1	2	
	(-)	1	(-) 5	3	1	1	
			(-) 1				
Second procedure (<i>n</i> = 5, 18.5%)	(+)	5 (100)	(+) 1 (20)				
	(-)	0	(-) 4			3	1
			(-) 0				
Third procedure (<i>n</i> = 3, 11.1%)	(+)	2 (66.7)	(+) 1 (33.3)				
	(-)	1	(-) 1			1	
			(-) 1				1
Fourth procedure (<i>n</i> = 3, 11.1%)	(+)	2 (66.7)	(+) 0 (0)				
	(-)	1	(-) 2				
			(-) 1				1

Table 3. Outcomes of the Percutaneous Procedure for Synovial Cysts at the Post-Laminectomy Level

No. of Injection (The Number of Patients/ The Number of Cysts)	The Rate of Successful Cyst Rupture (n, %)	Response After Injection (n, %)	
1st injection (14/16)	10/16 (62.5)	Improved	13/14 (92.9)
		Not improved	0
		Surgery	1/14 (7.1)
		Loss of follow-up	0
2nd injection (5/5)	1/5 (20)	Improved	3/5 (60)
		Not improved	1/5 (20)
		Surgery	0
		Loss of follow-up	1/5 (20)
3rd injection (3/3)	1/3 (33.3)	Improved	3/3 (100)
		Not improved	0
		Surgery	0
		Loss of follow-up	0
4th injection (3/3)	0/3 (0)	Improved	1/3 (33.3)
		Not improved	0
		Surgery	1/3 (33.3)
		Loss of follow-up	1/3 (33.3)

encing surgery ($p = 0.480$). The overall rate of surgical intervention was 14.3% (2/14 patients).

In details, after the first procedure (14 patients and 16 cysts), all 10 patients with a successful cyst rupture (Fig. 1) reported 'symptoms improved' after the procedure. Among 4 patients with a failed cyst rupture, 3 reported 'symptoms improved' and the other one underwent surgery. Among the 13 patients who did not subsequently undergo surgery, 5 patients with 5 cysts (including 3 who experienced a successful cyst rupture in the first procedure) had repeated procedures due to recurrent symptoms, and cyst rupture was visible in one patient. Including this case, 3 patients reported 'symptoms improved'. These 3 patients with 3 cysts underwent a third procedure due to recurrent symptoms, and all reported 'symptoms improved' after the procedure, although cyst rupture was successful in only one.

The mean maximum diameter of the cysts was 12.0 ± 2.3 mm (range 6.7 mm to 15 mm), 68.8% of the cysts showed high signal intensity, and 31.2% of the cysts showed intermediate signal intensity on T2-weighted images. There was no statistically significant relationship between the success rate of cyst rupture and the size of cysts ($p = 0.224$), the success rate of cyst rupture and the signal intensity of cysts ($p = 1.000$), the surgery rate and the size of cysts ($p = 0.318$), the surgery rate and the signal intensity of cysts ($p = 1.000$).

DISCUSSION

According to previous studies regarding percutaneous procedures for primary pre-operative lumbar facet joint synovial cysts, the success rate of synovial cyst rupture is 76.7% to 100% (9-11). In the present study, specifically focusing on facet joint synovial cyst at the level

of the laminectomy, the success rate of percutaneous synovial cyst rupture (62.5% with the first procedure and 0% to 33.3% with repeated procedures) was lower than that of previous studies, and decreased as the procedure was repeated. This is possibly due to post-operative

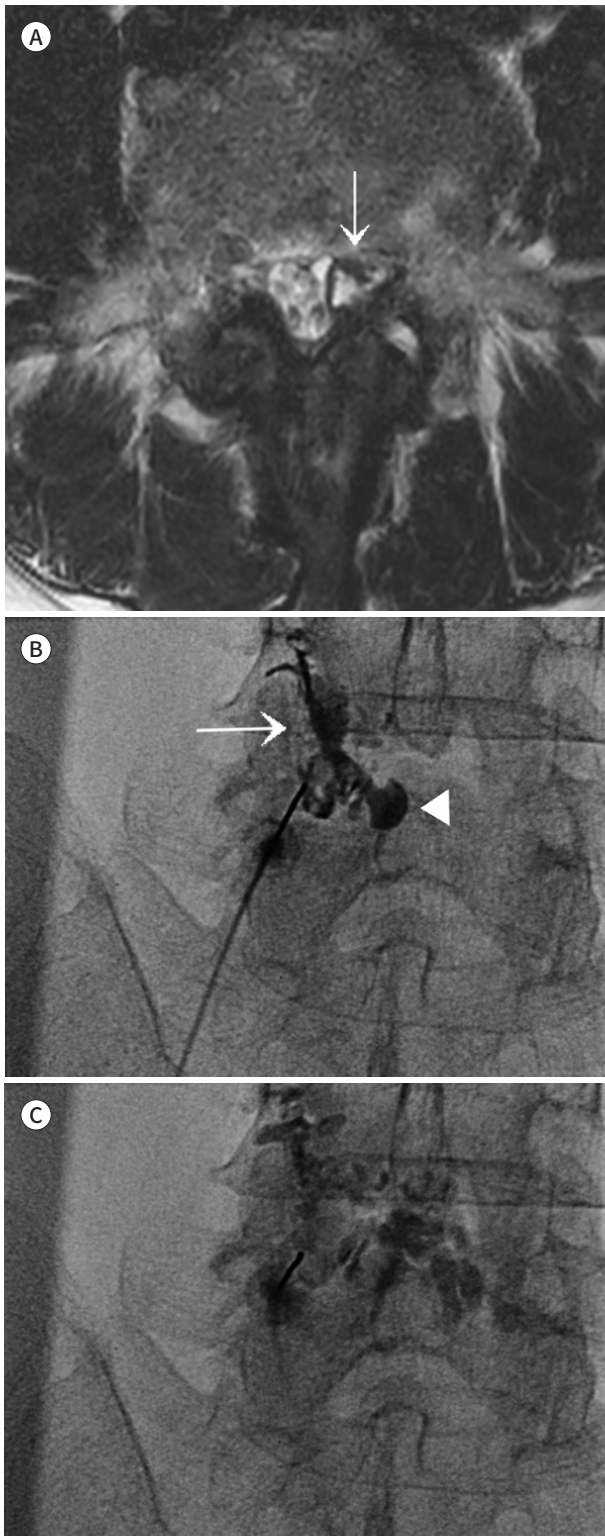


Fig. 1. Fluoroscopy-guided facet joint synovial cyst rupture in a 64-year-old female.

A. A T2-weighted image shows a symptomatic synovial cyst (arrow) at the L4–L5 left facet joint at the post-laminectomy level.

B. During a fluoroscopy-guided facet joint cyst rupture procedure, the facet joint space is successfully accessed guided by its visualization (arrow). An MR imaging-proven synovial cyst is re-demonstrated with a continuation from the joint space (arrowhead).

C. Immediately after a saline push through the spinal needle, the contrast media spreads with a concomitant loss of the synovial cyst outline, which is interpreted as a successful cyst rupture. After this procedure, the patient reported an improvement in the left side radiculopathy.

adhesion created initially by the laminectomy and secondarily by the synovial cyst rupture procedure(s). The fibrosis may make it challenging to rupture a cyst that is adherent to the dura (8), making it difficult to verify the rupture by visualizing contrast outside of the cyst. In addition, in the present study the rate of extraspinal leakage was higher in failed rupture cases, and this might be also related to post-operative adhesion.

Despite the success rate of the cyst ruptures in this study being lower compared to that of previous studies focusing on primary pre-operative cysts, the overall rate (80%) of patients reporting symptom improvement was similar to that (54% to 82%) of previous studies (3, 9). Although there was a significant relationship between the successful cyst rupture and the rate of patients experiencing 'improved symptom' after procedures ($p = 0.039$), even in patients with failed cyst rupture, 61.5% reported 'improved symptom', which was also comparable to the results (54% to 82%) of previous studies. The rate of patients who needed recurrent percutaneous intervention (35.7% of patients needed at least one repeated procedure) was comparable to that (20% to 50.5%) of preceding studies (9-12). Also, in our results, the final rate of surgical intervention (surgical excision of synovial cyst with or without segmental fusion) was 14.3%, which is similar to the 10% to 54.5% rates seen in previous studies (9-12). Walcott and Coumans (14) reported on patients who presented symptomatic synovial cyst at post-laminectomy level of lumbar spine. In that study, patients did not undergo percutaneous synovial cyst rupture with a subsequent steroid injection, and the rate of surgery for symptom relief was 55.6%. Compared to this, in our study the surgery rate was lower (14.3%), which could mean the intra-articular facet joint procedure may delay or negate the need for surgical resection of the cysts, as proved in the pre-operative setting.

Our results suggest that attempting to rupture the cyst using facet joint injection in the treatment of synovial cyst after laminectomy, can be an effective treatment tool. Furthermore, several attempts of steroid injections into the facet joint 'alone' may be effective in improving symptoms of lumbar facet joint synovial cyst (in the present study, although patients with successful cyst rupture had significantly better outcomes, patients with failed cyst rupture also reported symptom relief comparable to that of previous studies). Synovial cyst formation is caused by repeated microtrauma of the degenerated facet joint, with herniation of the synovial membrane containing synovial cells and fluid (19). Therefore, the synovial cyst bears an underlying degenerated facet joint, which itself can produce pain, including local pain and pseudo-radicular pain with a variable distribution of referral pain (20). Due to the presence of inflammatory mediators into degenerative facet joint, pain relief occurs after steroid injection in facet joint (21). Also, in the present study, during the procedures extraspinal leakage was observed, and this leakage might contribute to lower intra-cyst pressure and decrease patients' symptom without successful cyst rupture.

To the authors' knowledge, there is a lack of research comparing the efficacy of transforaminal epidural injection and facet joint intra-articular procedure, for treatment of facet joint synovial cysts at post-laminectomy levels. According to Karamouzian et al. (22), the response rate for transforaminal epidural steroid injection was 40% in patients having recurrent herniated discs after previous open discectomy history. It was considerably lower than 84% efficacy (23) for the transforaminal injection method in the treatment of the primary lumbar disc herniation, which may have been due to post-operative epidural fibrosis restrict-

ing the distribution of the drug. Therefore, patients suffering from radiating pain, generated by facet joint synovial cysts at post-laminectomy levels with post-operative epidural fibrosis, may benefit from facet joint procedure more than transforaminal epidural injection.

In our study the mean maximum diameter of the cysts was 12.0 ± 2.3 mm, 68.8% of the cysts showed high signal intensity, and 31.2% of the cysts showed intermediate signal intensity on T2-weighted image. There was no statistically significant relationship between the success rate of cyst rupture, the surgery rate, and imaging findings. According to prior studies, cysts with T2 hyperintense and intermediate signal intensity are easier to rupture. Perhaps the cysts contain a higher proportion of fluid and are less gelatinous or calcified than T2 hypointense cysts (7, 17). In our study all cysts had either T2 hyperintense or intermediate signal intensity, therefore in terms of signal intensity of cyst there was no unfavorable factor hindering successful cyst rupture. Another study (18) reported a larger synovial cyst size was associated with patients requiring subsequent surgical management. In that study average size of synovial cyst before rupture for cases not undergoing surgery was 1.21 cm (range 0.6 cm to 2.0 cm) and for those undergoing surgery was 1.57 cm (range 0.9 cm to 2.2 cm). In our study, the average cyst size was 1.20 cm, similar in size with that of cysts not requiring surgery and this might affect final surgical rate in our study which is comparable to that of other antecedent studies.

There are several limitations in our study. First, relatively small number of patients were included in this retrospective study. Further research with a larger number of patients comparing the efficacy of cyst rupture with and without subsequent intra-articular steroid injection might be required. Also, although we estimate that facet joint intra-articular procedure will be more effective than transforaminal epidural steroid injection in patients having symptomatic facet joint synovial cysts at post-laminectomy levels with post-operative epidural fibrosis, we did not actually analyze the efficacy difference between the two treatments. Further research on this topic is needed. Second, we did not routinely perform follow-up MRI between cyst rupture procedures, therefore the actual presence of recurrent synovial cyst was not confirmed. During percutaneous procedure facet joint was delineated with contrast media under fluoroscopy but confident differentiation between degenerative facet joint space with and without synovial cyst was not always possible, especially in the case of facet joint bearing small cyst. Therefore, recurrent symptoms after the first percutaneous procedure might not always mean recurred synovial cyst and was possibly related to other pathologies such as facet joint arthrosis or herniated intervertebral disc. However, enrolled patients requiring repeat procedure always complained of similar recurred radicular pain each time, therefore we assumed that the cause of symptoms would be the same as demonstrated on pre-procedural MR imaging. Third, we could not review changes in functional score such as the Oswestry Disability Index, before and after procedure, because this was a retrospective study and there was no consistent documentation of patients' functional score on electronic medical record.

In conclusion, for patients having symptomatic lumbar facet joint synovial cysts at post-laminectomy levels, fluoroscopy-guided synovial cyst rupture with intra-articular steroid injection can be effective less invasive and safe management before considering surgical approach.

Author Contributions

Conceptualization, K.H.J., L.E., L.J.W.; data curation, K.H.J., L.E.; investigation, K.H.J., L.E.; methodology, L.J.W., K.Y., A.J.M.; project administration, L.E.; resources, K.H.J., L.E.; supervision, L.E.; visualization, K.H.J.; writing—original draft, K.H.J., L.E., L.J.W.; and writing—review & editing, L.J.W., K.Y., A.J.M.

Conflicts of Interest

The authors have no potential conflicts of interest to disclose.

REFERENCES

1. Bydon M, Papadimitriou K, Witham T, Wolinsky JP, Sciubba D, Gokaslan Z, et al. Treatment of spinal synovial cysts. *World Neurosurg* 2013;79:375-380
2. Themistoklis KM, Papasilekas TI, Boviatsis KA, Giakoumettis DA, Vlachakis EN, Themistocleous MS, et al. Spinal synovial cysts. A case series and current treatment options. *J Clin Neurosci* 2018;57:173-177
3. Chazen JL, Leeman K, Singh JR, Schweitzer A. Percutaneous CT-guided facet joint synovial cyst rupture: success with refractory cases and technical considerations. *Clin Imaging* 2018;49:7-11
4. Lutz GE, Nicoletti MR, Cyril GE, Harrison JR, Lutz C, Solomon JL, et al. Percutaneous rupture of zygapophyseal joint synovial cysts: a prospective assessment of nonsurgical management. *PM R* 2018;10:245-253
5. Shuang F, Hou SX, Zhu JL, Ren DF, Cao Z, Tang JG. Percutaneous resolution of lumbar facet joint cysts as an alternative treatment to surgery: a meta-analysis. *PLoS One* 2014;9:e111695
6. Eshraghi Y, Desai V, Cajigal Cajigal C, Tabbaa K. Outcome of percutaneous lumbar synovial cyst rupture in patients with lumbar radiculopathy. *Pain Physician* 2016;19:E1019-E1025
7. Huang AJ, Bos SA, Torriani M, Simeone FJ, Chang CY, Pomerantz SR, et al. Long-term outcomes of percutaneous lumbar facet synovial cyst rupture. *Skeletal Radiol* 2017;46:75-80
8. Haider SJ, Na NR, Eskey CJ, Fried JG, Ring NY, Bao MH, et al. Symptomatic lumbar facet synovial cysts: clinical outcomes following percutaneous CT-guided cyst rupture with intra-articular steroid injection. *J Vasc Interv Radiol* 2017;28:1083-1089
9. Amoretti N, Huwart L, Foti P, Boileau P, Amoretti ME, Pellegrin A, et al. Symptomatic lumbar facet joint cysts treated by CT-guided intracystic and intra-articular steroid injections. *Eur Radiol* 2012;22:2836-2840
10. Martha JF, Swaim B, Wang DA, Kim DH, Hill J, Bode R, et al. Outcome of percutaneous rupture of lumbar synovial cysts: a case series of 101 patients. *Spine J* 2009;9:899-904
11. Ortiz AO, Tekchandani L. Improved outcomes with direct percutaneous CT guided lumbar synovial cyst treatment: advanced approaches and techniques. *J Neurointerv Surg* 2014;6:790-794
12. Allen TL, Tatli Y, Lutz GE. Fluoroscopic percutaneous lumbar zygapophyseal joint cyst rupture: a clinical outcome study. *Spine J* 2009;9:387-395
13. Parlier-Cuau C, Wybier M, Nizard R, Champsaur P, Le Hir P, Laredo JD. Symptomatic lumbar facet joint synovial cysts: clinical assessment of facet joint steroid injection after 1 and 6 months and long-term follow-up in 30 patients. *Radiology* 1999;210:509-513
14. Walcott BP, Coumans JV. Postlaminectomy synovial cyst formation: a possible consequence of ligamentum flavum excision. *J Clin Neurosci* 2012;19:252-254
15. Kato M, Konishi S, Matsumura A, Hayashi K, Tamai K, Shintani K, et al. Clinical characteristics of intraspinal facet cysts following microsurgical bilateral decompression via a unilateral approach for treatment of degenerative lumbar disease. *Eur Spine J* 2013;22:1750-1757
16. Farrar JT, Young JP Jr, LaMoreaux L, Werth JL, Poole RM. Clinical importance of changes in chronic pain intensity measured on an 11-point numerical pain rating scale. *Pain* 2001;94:149-158
17. Cambron SC, McIntyre JJ, Guerin SJ, Li Z, Pastel DA. Lumbar facet joint synovial cysts: does T2 signal intensity predict outcomes after percutaneous rupture? *AJNR Am J Neuroradiol* 2013;34:1661-1664
18. Kwan BYM, Salehi F, Jia S, McGregor S, Duggal N, Pelz D, et al. Retrospective review of percutaneous synovial cyst ruptures: increased thickness of the T2 hypointense rim on post-rupture MRI may be associated with need for subsequent surgery. *J Neurointerv Surg* 2017;9:797-800
19. Rauchwerger JJ, Candido KD, Zoarski GH. Technical and imaging report: fluoroscopic guidance for diagnosis and treatment of lumbar synovial cyst. *Pain Pract* 2011;11:180-184

20. Perolat R, Kastler A, Nicot B, Pellat JM, Tahon F, Attye A, et al. Facet joint syndrome: from diagnosis to interventional management. *Insights Imaging* 2018;9:773-789
21. Cohen SP, Raja SN. Pathogenesis, diagnosis, and treatment of lumbar zygapophysial (facet) joint pain. *Anesthesiology* 2007;106:591-614
22. Karamouzian S, Ebrahimi-Nejad A, Shahsavarani S, Keikhosravi E, Shahba M, Ebrahimi F. Comparison of two methods of epidural steroid injection in the treatment of recurrent lumbar disc herniation. *Asian Spine J* 2014;8:646-652
23. Lee JH, An JH, Lee SH. Comparison of the effectiveness of interlaminar and bilateral transforaminal epidural steroid injections in treatment of patients with lumbosacral disc herniation and spinal stenosis. *Clin J Pain* 2009;25:206-210

척추 후궁절제술 이후 발생한 요추 후관절 활액낭에서 투시유도 하 낭종파열술 및 관절 내 스테로이드 주입술의 임상적 경험

김효진^{1,2} · 이영준^{1*} · 이준우¹ · 강유선¹ · 안중모¹

목적 요추 후궁절제술 시행 부위 후관절 활액낭에 대해 투시유도 하 경피적 낭종파열술 및 스테로이드 주입술을 시행 받은 환자에 관하여 후향적으로 시술의 성공률 및 임상적 효과를 분석하였다.

대상과 방법 투시유도 하 경피적 후관절 낭종파열술과 관절 내 스테로이드 주입술을 시행 받은 환자이면서, 시술 전 6개월 이내 촬영한 요추 자기공명영상 상 이전 후궁절제술 부위와 후관절 활액낭종의 위치가 일치하는 것이 증명된 환자, 그리고 그 낭종의 위치가 신경학적 증상을 설명하는 것으로 판단되는 환자를 대상(14명)으로 하였으며 시술 후 낭종파열의 성공 유무와 증상의 호전 정도를 조사하였다.

결과 시술이 반복될수록 낭종파열의 성공률은 감소하였지만(첫 시술에서는 62.5%, 그 이후의 시술에서는 0~33%), 80%의 환자가 시술 후 증상 호전을 보였다. 추적관찰 기간 내 낭종에 대한 수술률은 14.3%였다.

결론 요추 후궁절제술 시행 부위 후관절 활액낭에 대한 투시유도 하 경피적 낭종파열술 및 스테로이드 주입술은 효과적인 치료 방법으로서, 수술적 치료를 고려하기 전에 먼저 시도해 볼 수 있다.

¹분당서울대학교병원 영상의학과, ²서울특별시보라매병원 영상의학과