



# Mid-Term Results of Thoracic Endovascular Aortic Repair for Complicated Acute Type B Aortic Dissection at a Single Center

Young Kwang Hong, M.D.<sup>1</sup>, Won Ho Chang, M.D., Ph.D.<sup>1</sup>, Dong Erk Goo, M.D., Ph.D.<sup>2</sup>, Hong Chul Oh, M.D.<sup>1</sup>, Young Woo Park, M.D., Ph.D.<sup>1</sup>

Departments of <sup>1</sup>Thoracic and Cardiovascular Surgery and <sup>2</sup>Radiology, Soonchunhyang University Seoul Hospital, Seoul, Korea

## ARTICLE INFO

**Received** December 14, 2020

**Revised** February 3, 2021

**Accepted** February 16, 2021

## Corresponding author

Won Ho Chang

**Tel** 82-2-710-3084

**Fax** 82-2-709-9083

**E-mail** changwh@schmc.ac.kr

**ORCID**

<https://orcid.org/0000-0002-0234-4478>

**Background:** Complicated acute type B aortic dissection is a life-threatening condition with high morbidity and mortality. The aim of this study was to report a single-center experience with endovascular stent-graft repair of acute type B dissection of the thoracic aorta and to evaluate the mid-term outcomes.

**Methods:** We reviewed 18 patients treated for complicated acute type B aortic dissection by thoracic endovascular aortic repair (TEVAR) from September 2011 to July 2017. The indications for surgery included rupture, impending rupture, limb ischemia, visceral malperfusion, and paraplegia. The median follow-up was 34.50 months (range, 12–80 months).

**Results:** The median interval from aortic dissection to TEVAR was 5.50 days (range, 0–32 days). There was no in-hospital mortality. All cases of malperfusion improved except for 1 patient. The morbidities included endoleak in 2 patients (11.1%), stroke in 3 patients (16.7%), pneumonia in 2 patients (11.1%), transient ischemia of the left arm in 1 patient (5.6%), and temporary visceral ischemia in 1 patient (5.6%). Postoperative computed tomography angiography at 1 year showed complete thrombosis of the false lumen in 15 patients (83.3%).

**Conclusion:** TEVAR of complicated type B aortic dissection with a stent-graft was effective, with a low morbidity and mortality rate.

**Keywords:** Aortic dissection, Ischemia, Outcomes

## Introduction

Medical treatment to control hypertension and relieve pain is recommended as the initial treatment for uncomplicated acute type B aortic dissection. Surgery is considered for complications, including aortic rupture, hemothorax, visceral malperfusion, limb ischemia, end-organ failure, impending rupture of the dissected aorta, or persistent pain not responding to medical treatment [1,2]. The conventional surgical treatment for complicated acute type B aortic dissection is open repair of the aorta, including resection of the primary tear site. However, an early mortality rate of up to 40% after surgery for complicated acute type B aortic dissection has been reported [3]. Because the morbidity and mortality rates associated with conventional open repair are very high, endovascular stent-grafting has emerged as a less invasive alternative to surgical graft

placement. Better early outcomes and less perioperative morbidity relative to conventional surgery could be achieved using thoracic endovascular aortic repair (TEVAR) for complicated acute type B aortic dissection [4].

The aim of this study was to report the mid-term clinical outcomes of a single-center experience with the endovascular repair of complicated acute type B aortic dissection.

## Methods

From September 2011 to July 2017, 18 patients were treated with TEVAR for a diagnosis of complicated acute type B aortic dissection. This retrospective study was approved by the Institutional Review Board of Soonchunhyang University Hospital (SCHUH 2020-05-018), which waived the requirement for informed patient consent.



## Preoperative management and surgical indications

Open repair of the aorta for type B aortic dissection was not performed in any cases during this time. All of the patients (14 men and 4 women) were treated with TEVAR (median age, 54.0 years). Immediate medical treatment, including calcium antagonists and beta-blockers, was initiated after diagnosis, with a systolic blood pressure goal of 100–120 mm Hg and heart rate below 50 beats/min. All diagnoses were confirmed by computed tomography (CT) of the whole aorta and branch vessels. The indications for TEVAR included aortic rupture, hemothorax with impending rupture (defined as aneurysmal dilatation with hemothorax without active contrast extravasation on CT), visceral malperfusion (renal, celiac, and mesenteric), paraplegia, and limb ischemia. Visceral malperfusion was defined on the basis of symptoms such as persistent abdominal pain and oliguria, laboratory findings such as elevated creatinine or liver enzyme levels, and CT findings such as hypoperfusion of the bowel, liver, or kidney. All patient demographics, comorbidities, and indications for TEVAR are described in Table 1.

## Surgical techniques

We applied an endovascular prosthesis at least 2 cm proximal from the entry site for the proximal landing zone, as was necessary for an optimum seal. For patients who presented with thoracic aortic pathology, including aortic aneurysms, the proximal landing zone was extended to the

aortic arch. Most left subclavian arteries were occluded without revascularization for TEVAR to prevent type II endoleak in patients with landing zones 1 and 2. However, left subclavian artery revascularization (left carotid-to-left subclavian artery bypass graft with landing zone 2) was necessary for patients with a hypoplastic or stenotic contralateral vertebral artery on CT angiography before stent-grafting. The left subclavian artery was surgically divided during bypass surgery in these patients. For the distal landing zone, we tried to avoid covering above 20 cm of the descending thoracic aorta with stent-graft to prevent spinal cord ischemia. Preoperative CT angiography was useful in the evaluation of the length of coverage and graft selection. Orthogonal reconstructions were helpful for estimating the length required to cover the affected aorta and achieve sufficient landing zones. We considered stent-grafts with a longer graft or with the most distal extension possible to avoid risking type Ib endoleak. Choosing a relatively straight segment of the aorta for the distal landing zone would help facilitate sufficient sealing of the entry site, but this must be balanced against the risk of spinal cord ischemia associated with covering long aortic segments. When a single stent-graft was not sufficient to achieve an adequate seal, an additional stent-graft for proximal or distal extension could be used. A telescoping technique, involving initial deployment of a smaller stent-graft and proximal or distal extension with a larger graft, was used to achieve sufficient sealing. Commercially available stent-grafts, including 17 Valiant thoracic stent-grafts with the Captivia delivery system (Medtronic, Minneapolis, MN, USA) and 1 Conformable GORE TAG Thoracic Endoprosthesis (Gore, Flagstaff, AZ, USA), were delivered through the transfemoral approach involving a standard longitudinal inguinal incision to expose the common femoral artery under general endotracheal anesthesia. A 5F pigtail catheter was introduced into the ascending aorta through the contralateral femoral artery or left brachial artery percutaneously to identify the orifice of the left subclavian artery and for intraoperative angiography. For patients undergoing revascularization of the carotid or subclavian artery, graft patency was ensured by selective angiography before sealing. A larger diameter stent-graft, 10%–15% larger than the non-dissected proximal aorta, was chosen to secure and tightly seal the intimal tearing. Titration of the systolic blood pressure to 80 mm Hg with nicardipine was needed to prevent displacement of the stent-graft during delivery. Systemic anticoagulation was accomplished by intravenous injection of heparin (100 IU/kg) before stent-graft instillation.

**Table 1.** Clinical characteristics of patients

Characteristic	Value
Age (yr)	54.0 (26–85)
Sex (male:female)	14:4
Hypertension	18 (100.0)
Chronic obstructive pulmonary disease	3 (16.7)
Diabetes	2 (11.1)
Peripheral arterial obstructive disease	2 (11.1)
Coronary artery disease	1 (5.6)
Indication for thoracic endovascular aortic repair	
Rupture	2 (11.1)
Impending rupture	3 (16.7)
Visceral malperfusion	
Renal	5 (27.8)
Celiac	1 (5.6)
Mesenteric	1 (5.6)
Paraplegia	1 (5.6)
Limb ischemia	5 (27.8)

Values are presented as median (range) or number (%).

## Clinical outcomes and statistical analysis

The characteristics and preoperative comorbidities of the patients, indications, and postoperative outcomes were collected retrospectively. Follow-up CT angiography was obtained 1 week after surgery and annually thereafter to evaluate the extent of thrombosis in the aortic false lumen, enlargement of the aortic true lumen, and perfusion of the branch vessels for each patient.

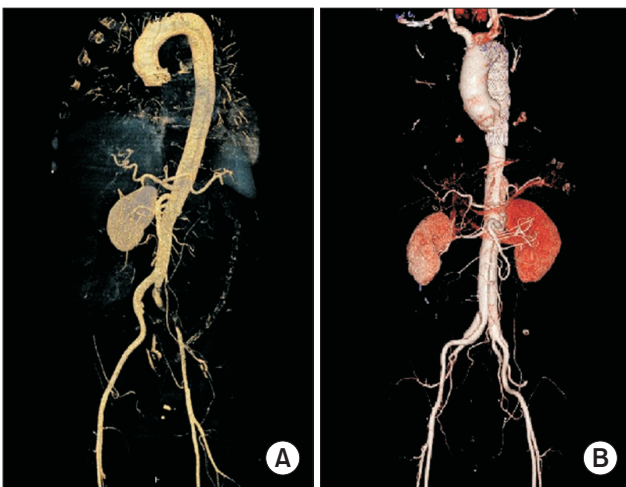
Continuous variables are expressed as the median (range). The statistical analysis was done using IBM SPSS ver. 24.0 (IBM Corp., Armonk, NY, USA).

## Results

The median interval from the onset of dissection to TEVAR was 5.5 days (range, 0–32 days). Complete sealing of the primary intimal tear site in all patients and relief of malperfusion was achieved in 17 patients (Fig. 1). An additional stent-graft to reinforce and expand the first stent-graft in the distal aortic arch was deployed when type I endoleak was persistent on intraoperative angiography in 1 case. The left subclavian artery was occluded by a vascular plug (2 in proximal landing zone 1 and 8 in proximal landing zone 2). In all these patients, the left brachial artery pressure was over 60 mm Hg and revascularization by a bypass graft for arm perfusion was not considered. A left carotid-to-left subclavian bypass graft with an 8-mm Da-

cron artificial graft for hypoplasia or stenosis of the contralateral vertebral artery was performed in 3 patients before aortic stent-grafting. Carotid-carotid crossover bypass was needed for 2 patients with landing zone 1. The median operation time including revascularization with a graft was 190 minutes (range, 85–314 minutes). All surgical procedures for these patients are described in Table 2.

Early complications occurred in 10 patients postoperatively. Residual blood flow to the false lumen from the proximal landing zone (type I endoleak) newly developed on postoperative CT angiography in 2 patients. However, expansion of the true lumen and relief of the malperfusion were achieved after stent-grafting, and no additional stent-grafting or surgical intervention was considered. Endoleaks disappeared in these patients during the follow-up period. One patient had transient ischemia of the left arm postoperatively, but it resolved without complications after 2 weeks. In the patient with a dissection extending into the superior mesenteric artery, bowel ischemia presented as postprandial epigastric pain. After resting the bowel by restricting enteral feeding, the symptoms subsided without significant bowel infarction. Pneumonia developed as a pulmonary complication after general anesthesia in 2 current smokers. A case of lower extremity ischemia associated with dynamic and static involvement of the right common iliac artery did not improve after stent-graft placement across the intimal tear in the descending thoracic aorta. For this patient, we deployed an additional stent into the right external iliac artery 8 days after aortic stent-grafting. Other early complications including collapse of the distal true lumen, retrograde dissection, or paraplegia did not occur in this study. Three years after TEVAR, a patient was admitted to another hospital for cerebral infarction. Cerebral angiographic CT revealed a partial occlusion of the left common carotid artery caused by the migrated stent-graft. Catheter-directed thrombolysis failed and right subclavian artery-to-left common carotid artery bypass surgery was performed using a polytetrafluoroethylene graft, which resolved the hypoperfusion of the left cerebrum. Follow-up CT scans were performed 12 months after the stent-graft insertion and compared with the initial CT scans. Thrombosis of the false lumen was analyzed at the following levels: proximal descending aorta (2 cm below the origin of the left subclavian artery), distal descending aorta (20 cm below the origin of the left subclavian artery), visceral aorta (between the origin of the celiac trunk and superior mesenteric artery) and infra-renal aorta (below the origin of the renal artery). Complete thrombosis, defined as thrombosis without residual blood



**Fig. 1.** Preoperative computed tomography showing malperfusion of the left renal artery and left common iliac artery (A). Postoperative computed tomography 1 week after surgery showing complete relief of the malperfusion of the left kidney and left lower extremity (B).

**Table 2.** Surgical procedures

Variable	Value
Manufacture of stent graft	
Valiant stent-grafts with the Captivia delivery system	17 (94.4)
Conformable GORE TAG Thoracic Endoprosthesis	1
Proximal landing zone	
Zone 1	2 (11.1)
Zone 2	11 (61.1)
Zone 3	3 (16.7)
Zone 4	2 (11.1)
Length of stent-graft (mm)	150 (100–250)
Shape of stent-graft	
Straight	13 (72.2)
Tapered	5 (27.8)
Diameter of stent-graft (mm)	
Proximal	35 (26–46)
Distal	34 (26–45)
Additional procedure	
Embolization of left subclavian artery	10 (55.6)
Debranching arch vessels	
Carotid	2 (11.1)
Left subclavian artery	3 (16.7)
Interval from dissection to thoracic endovascular aortic repair (day)	5.5 (0–32)
Operative time (min)	190 (85–314)

Values are presented as number (%) or median (range).

flow in the false lumen of the affected aorta at each level, was achieved in 15 patients (83.3%). Although partial residual flow of the false lumen in the dissected thoracoabdominal aorta was observed in 3 patients, there was no aneurysmal change of the dissected aorta, so we decided to follow-up with CT angiography annually rather than performing an additional intervention or open repair. The early- and mid-term clinical outcomes after TEVAR are described in Table 3.

## Discussion

Aortic dissection is a catastrophic condition with various clinical manifestations. Dissection of the intima results in true and false lumina, which may occlude the origin of the branch vessel, occasionally resulting in life-threatening ischemia of the visceral organs and limb extremities. Rupture of the dissected aorta is less common in type B aortic dissection, but still occurs in 20% of patients and may be a cause of death [4]. The International Registry of Acute Aortic Dissection data showed that complicated acute type B dissection patients with malperfusion or impending rupture undergoing open repair had significant morbidity and mortality [5].

TEVAR has been proposed as a less invasive and effective

**Table 3.** Early and mid-term clinical outcomes

Variable	Value
Morbidity	
Endoleak	2 (11.1)
Re-intervention	2 (11.1)
Percutaneous transluminal angioplasty	1
Carotid bypass	1
Stroke	3 (16.7)
Pneumonia	2 (11.1)
Transient visceral ischemia	1 (5.6)
Transient arm ischemia	1 (5.6)
In hospital mortality	0
Hospital stay (day)	18.5 (4–92)
Thrombosis of false lumen at 12 months	
Complete thrombosis	15 (83.3)
Partial thrombosis	3
Survival after 1 year	18 (100.0)

Values are presented as number (%) or median (range).

therapeutic alternative for the treatment of complicated acute aortic type B dissection [6]. Five patients with acute type B dissection with rupture or impending rupture were included in our study, all of whom survived after successful endovascular aortic repair. For ruptured or impending rupture of the dissected aorta, the primary tear site should be covered. Longer coverage zones are necessary for com-

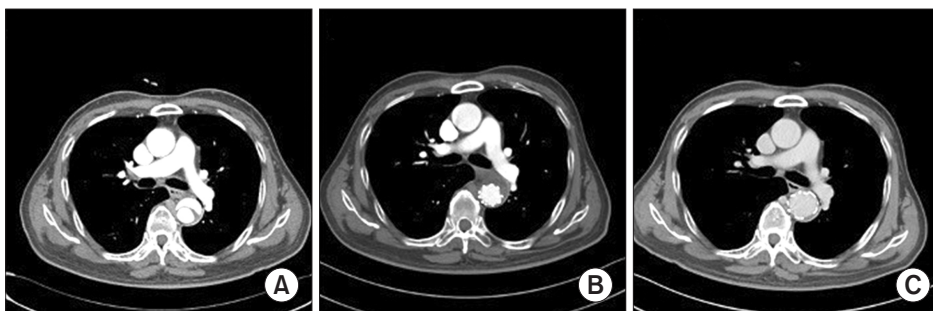
plete exclusion of the dissected aorta in ruptures than in isolated traumatic aortic injuries. Hemothorax is an uncommon complication of thoracic aortic dissection, but in some cases, a pleural effusion of the hemithorax, rather than chest or back pain, may be the first sign of acute aortic dissection. For small amounts of hemothorax or pleural effusion, no special treatment is needed. However, intensive care is needed for significant amounts of hemothorax affecting pulmonary function. In these cases, mechanical ventilation may be required for respiratory dysfunction [7]. Most cases of progressive hemothorax in our study recovered after the deployment of an aortic stent-graft. However, additional treatment for hemothorax, including tube thoracostomy, was needed in 3 cases. Pulmonary complications had no significant relationship with hemothorax in our study.

Acute mortality in type B aortic dissections has been associated with ischemic complications in up to 30% of patients. The stent-graft was deployed to enlarge the true lumen, obliterate the false lumen, and resolve the malperfusion for complicated cases with malperfusion syndrome. Malperfusion associated with acute type B aortic dissection can be classified as dynamic or static based on the mechanism of impaired blood flow. Dynamic malperfusion, which occurs when the orifice of the aortic branch vessel is occluded by the mobile aortic dissection flap, is typically resolved by TEVAR to enlarge the true lumen and decompress the false lumen. In contrast, static malperfusion occurs when the dissection flaps extend over the aortic side branch and the true lumen is compressed by the false lumen. In these cases, branch vessel stenting in addition to TEVAR might be required to resolve the malperfusion syndrome simultaneously. If static obstruction of the branch vessels is present, self-expandable stent insertion into the arch vessels will be necessary and fenestration of the stent graft or the use of a separate bare stent should be considered for communication between the true lumen and branch vessel origins. However, only obliteration of the entry site by the

stent-graft, preventing intermittent expansion of the intimal flap during the systolic phase, is sufficient for dynamic obstruction of the branch vessels [8]. Dynamic obstruction of the branch vessel may cause renal failure, mesenteric infarction, or limb ischemia. Urgent TEVAR can restore the blood flow of the true lumen and improve renal function [9]. Most patients with malperfusion of the lower extremity showed improvements in limb ischemia, except for 1 patient. Persistent ischemic branch vessel obstruction involving the right iliac artery has both dynamic and static mechanisms. After placement of the stent over the iliac artery, the dynamic obstruction was immediately resolved. For persistent malperfusion affected by the static component, deploying an uncovered stent within the true lumen of the obstructed artery showed excellent results in a recent study [10]. In patients with mesenteric malperfusion who presented with abdominal pain, no exploratory laparotomy was required after TEVAR in our experience.

A careful evaluation for the proximal landing zone and a plan for revascularization of the arch vessels are essential for optimal clinical outcomes and preventing complications. Using an oversized stent-graft may enhance the radial force and help maintain a good proximal sealing at TEVAR, but the correct percentage of oversizing has not been determined. Inappropriate oversizing of the stent graft has been associated with postoperative mortality and complications, such as endoleak, migration, rupture, and reinterventions. The mean oversizing at the proximal landing zone was 10%–20% and did not significantly affect the incidence of device-related complications after TEVAR for thoracic aortic aneurysm [11]. Less than 5% oversizing of the stent-graft may be a suitable option for TEVAR to treat type B aortic dissection. A smaller degree of oversizing could lower the incidence of retrograde type A dissection without increasing the risk of stent migration or type I endoleak [12].

The most common site of aortic type B dissection is located immediately distal to the origin of the left subclavian



**Fig. 2.** Preoperative computed tomography showing the dissected thoracic aorta (A). Computed tomography 1 week after surgery showing complete thrombosis of the false lumen in the dissected thoracic aorta (B). Computed tomography 12 months after surgery showing enlargement of the true lumen and obliteration of the false lumen in the thoracic aorta (C).

artery. Intentionally covering the left subclavian artery with a stent-graft can avoid the tendency for the proximal landing zone of the stent-graft to tilt, thereby achieving structural stability and preventing the collapse of the stent-graft [13]. The 2 stent-graft endoleaks in our series demonstrated the difficulty of landing stent-grafts due to curvature of the aortic arch [14]. For aortic disease requiring zone 2 TEVAR, multiple strategies for management of the left subclavian artery have been considered. Intentional coverage of the left subclavian artery could increase the risk of various complications such as ischemic stroke, spinal cord ischemia, arm ischemia, and vertebral artery insufficiency. Revascularization of the left subclavian artery including carotid-subclavian bypass, subclavian-carotid transposition, and in situ laser fenestration could protect against neurological complications such as stroke and spinal cord ischemia, but this advantage remains debatable [15]. In fact, when treating aortic arch pathology, embolic stroke is a potential complication. It can also occur when the left subclavian artery is not covered and may be related to the navigation and deployment of devices within the thoracic aorta, especially the aortic arch. Postoperative stroke occurred in 3 patients in our study, and brain magnetic resonance imaging revealed multiple, tiny thromboembolic infarctions rather than hypoperfusion in these patients. The use of an additional stent-graft in a single patient may have the advantage of overlapping multiple endoprotheses. Longer portions of the thoracic aorta could be covered and a higher number of intimal tears could be sealed with multiple stent-grafts. The length of the stent-graft has been identified as a risk factor for paraplegia. However, no patients in this study developed paraplegia and we could not confirm this relationship [16].

Despite an increasing frequency of reinterventions and additional procedures, TEVAR could be the first-line therapy for complicated acute type B aortic dissections, with low in-hospital mortality and a high success rate. TEVAR can remodel the thoracic aorta, and complete obliteration of the false lumen in the proximal and distal thoracic aorta can be achieved, especially in acute DeBakey type IIIa dissections. Because a patent false lumen, especially in the abdominal aorta, could become an aortic aneurysm and require reintervention in the long term, close surveillance might be needed [17].

Our experience with TEVAR for complicated acute type B aortic dissection showed favorable outcomes without severe complications. No early mortality, postoperative paraplegia, or conversion to open surgery was demonstrated in our study. However, the long-term results related to the

false lumen in aortic remodeling after TEVAR remain unclear, although 15 of 18 patients (83.3%) had complete thrombosis of the false lumen and re-expansion of the true lumen 12 months after TEVAR (Fig. 2).

This current study had several limitations. It was a retrospective, non-randomized, observational single-institutional study. There was also no risk-adjusted control group that received open surgery or medical treatment.

In conclusion, endovascular repairs with a stent-graft may be beneficial for the early treatment of complicated acute type B aortic dissection based on the findings of this study. The clinical results of the mid-term follow-up demonstrated an acceptable survival advantage related to stent-grafting, but a secondary intervention might be needed for endoleak or retrograde flow of the false lumen. Long-term follow-up studies are necessary to confirm the results of this study.

## Conflict of interest

No potential conflict of interest relevant to this article was reported.

## ORCID

Young Kwang Hong: <https://orcid.org/0000-0001-8993-8983>  
 Won Ho Chang: <https://orcid.org/0000-0002-0234-4478>  
 Dong Erk Goo: <https://orcid.org/0000-0003-1042-8265>  
 Hong Chul Oh: <https://orcid.org/0000-0003-1338-2397>  
 Young Woo Park: <https://orcid.org/0000-0001-7858-178X>

## References

1. Botsios S, Schuermann K, Maatz W, Keck N, Walterbusch G. *Complicated acute type B dissections: a single-center experience with endovascular treatment*. *Thorac Cardiovasc Surg* 2010;58:280-4.
2. Nienaber CA, Eagle KA. *Aortic dissection: new frontiers in diagnosis and management: part I: from etiology to diagnostic strategies*. *Circulation* 2003;108:628-35.
3. Lauterbach SR, Cambria RP, Brewster DC, et al. *Contemporary management of aortic branch compromise resulting from acute aortic dissection*. *J Vasc Surg* 2001;33:1185-92.
4. Dake MD, Kato N, Mitchell RS, et al. *Endovascular stent-graft placement for the treatment of acute aortic dissection*. *N Engl J Med* 1999;340:1546-52.
5. Trimarchi S, Nienaber CA, Rampoldi V, et al. *Role and results of surgery in acute type B aortic dissection: insights from the International Registry of Acute Aortic Dissection (IRAD)*. *Circulation* 2006;114:1357-64.

6. Khoynezhad A, Donayre CE, Omari BO, Kopchok GE, Walot I, White RA. *Midterm results of endovascular treatment of complicated acute type B aortic dissection*. J Thorac Cardiovasc Surg 2009;138:625-31.
7. Shu C, He H, Li QM, Li M, Jiang XH, Luo MY. *Endovascular repair of complicated acute type-B aortic dissection with stentgraft: early and mid-term results*. Eur J Vasc Endovasc Surg 2011;42:448-53.
8. Kim JT, Yoon YH, Lim HK, Yang KH, Baek WK, Kim KH. *Thoracic endovascular stent graft repair for aortic aneurysm*. Korean J Thorac Cardiovasc Surg 2011;44:148-53.
9. Greenberg R, Khwaja J, Haulon S, Fulton G. *Aortic dissections: new perspectives and treatment paradigms*. Eur J Vasc Endovasc Surg 2003;26:579-86.
10. van Bogerijen GH, Williams DM, Patel HJ. *TEVAR for complicated acute type B dissection with malperfusion*. Ann Cardiothorac Surg 2014;3:423-7.
11. Tolenaar JL, Jonker FH, Moll FL, et al. *Influence of oversizing on outcome in thoracic endovascular aortic repair*. J Endovasc Ther 2013;20:738-45.
12. Liu L, Zhang S, Lu Q, Jing Z, Zhang S, Xu B. *Impact of oversizing on the risk of retrograde dissection after TEVAR for acute and chronic type B dissection*. J Endovasc Ther 2016;23:620-5.
13. Han DK, Jokisch C, McKinsey J. *Expanding the landing zone for TEVAR*. Endovasc Today 2016;15:85-90.
14. Dias NV, Sonesson B, Koul B, Malina M, Ivancev K. *Complicated acute type B dissections: an 8-years experience of endovascular stent-graft repair in a single centre*. Eur J Vasc Endovasc Surg 2006;31:481-6.
15. Bradshaw RJ, Ahanchi SS, Powell O, et al. *Left subclavian artery revascularization in zone 2 thoracic endovascular aortic repair is associated with lower stroke risk across all aortic diseases*. J Vasc Surg 2017;65:1270-9.
16. Gravereaux EC, Faries PL, Burks JA, et al. *Risk of spinal cord ischemia after endograft repair of thoracic aortic aneurysms*. J Vasc Surg 2001;34:997-1003.
17. Leshnowar BG, Duwayri YM, Chen EP, et al. *Aortic remodeling after endovascular repair of complicated acute type B aortic dissection*. Ann Thorac Surg 2017;103:1878-85.