




First Clinical Cases of Spirometrosis in Two Cats in Korea

Joohyung Kim¹, Younsung Ock², Kihwan Yang¹, Seongjun Choe³ , Kyung-Mee Park⁴, Wan-Kyu Lee⁴,
Kyung-Chul Choi⁵, Soochong Kim⁴, Dongmi Kwak⁶ , Seung-Hun Lee^{4,*} 

¹Shinsegae Animal Medical Center, Yangsan 50653, Korea; ²Myeonggok Station Animal Hospital, Daegu 42956, Korea; ³Department of Parasitology, Parasite Research Center and Parasite Resource Bank, School of Medicine, Chungbuk National University, Cheongju 28644, Korea; ⁴College of Veterinary Medicine, Chungbuk National University, Cheongju 28644, Korea; ⁵Laboratory of Biochemistry and Immunology, College of Veterinary Medicine, Chungbuk National University, Cheongju 28644, Korea; ⁶College of Veterinary Medicine, Kyungpook National University, Daegu 41566, Korea

Abstract: This study reports the first two clinical cases of spirometrosis caused by *Spirometra* sp. in cats in Korea. In these two cases, the cats vomited, and long proglottids of tapeworm were recovered. The sick cats presented with anorexia and lethargy. However, they unexpectedly showed no diarrhea, which is the main symptom of spirometrosis. Based on a fecal floatation test as well as morphological and molecular analyses, the parasite was diagnosed as *Spirometra* sp. The 2 cases were treated with praziquantel. This study suggests regular monitoring of health and deworming in companion animals, even when animals are well cared for, with regular preventive medication. Additionally, spirometrosis should be considered in the differential diagnosis in cases of gastrointestinal symptoms in *Spirometra* endemic areas.

Key words: Cat, clinical case, praziquantel, spirometrosis, zoonosis

INTRODUCTION

Spirometra (Cestoda: Diphylobothridae) is a small-to-medium-sized tapeworm that is found globally [1]. Unlike other cestodes that infect cats, *Spirometra* has a distinctive life cycle requiring two intermediate hosts [1,2]. Crustaceans, such as cyclops, act as the first intermediate host. The second intermediate hosts, including amphibians and reptiles, play a role in hosting the plerocercoid form. In definitive hosts, *Spirometra* becomes an adult worm and resides in the small intestine of carnivores and in domestic cats and dogs.

The plerocercoid larvae of *Spirometra* have a zoonotic characteristic. The plerocercoid larvae, which are called spargana, can invade various human tissues, such as the brain, eyes, breast, spinal cord, and subcutaneous tissue [3]. Sparganosis, caused by infection of spargana, occurs due to the ingestion of contaminated water or undercooked meat; on the other hand, infection by adult *Spirometra* is called spirometrosis [1,4]. In Korea, more than 200 human cases of sparganosis have been reported due to infection by the plerocercoid of *S. decipiens*

and *S. erinaceieuropaei* [4-6]. Animals can also be infected by spargana, and their symptoms are similar to those of humans [7-10].

There has been a debate on the species classification of *Spirometra* spp. [3,11-13]. Traditionally, species classification is achieved by evaluating the shape and number of uterine coils of adult worms. However, some studies have suggested that this method is insufficient to clearly differentiate various species [11,12]. Additionally, without significant consideration of morphological or molecular analysis, many *Spirometra* species have been recorded as *S. erinaceieuropaei*, which makes it difficult to determine the regional distribution of *Spirometra* spp. [8,9,13,15,16]. Owing to advances in molecular techniques, recent studies have attempted to identify *Spirometra* spp. based on the mitochondrial genome, especially based on the cytochrome c oxidase subunit 1 (*cox1*) gene [1-4,12,14]. However, morphological features that correspond to molecular data are required from the population of worms worldwide. Because the taxonomical debate on *Spirometra* spp. is far from the objective of this study, we described the *Spirometra* obtained in this study as *Spirometra* sp., and the species names originating from other studies are described as in their original study.

Although there are different studies on *Spirometra* in humans in Korea, studies in animals are insufficient. Most previous studies on cats in Korea have focused on identifying *Spirometra* at the genus level using coproscopic examination [15-

•Received 2 November 2020, revised 6 February 2021, accepted 15 March 2021.

*Corresponding author (dvmsilee@chungbuk.ac.kr)

© 2021, Korean Society for Parasitology and Tropical Medicine

This is an Open Access article distributed under the terms of the Creative Commons Attribution Non-Commercial License (<https://creativecommons.org/licenses/by-nc/4.0>) which permits unrestricted non-commercial use, distribution, and reproduction in any medium, provided the original work is properly cited.

17]. To the best of our knowledge, there are no reports on clinical cases on spirometrosis or sparganosis occurring in cats in Korea [15-18]. Therefore, this study reports the first clinical cases of spirometrosis in cats in Korea and the treatment regimen implemented.

CASE DESCRIPTION

Case 1

A 3-year-old, 4.5 kg spayed female cat (domestic shorthair), living in Yangsan, Korea, had been vomiting irregularly for several days with anorexia and lethargy, without showing any signs of diarrhea. The cat was a stray cat, and after being adopted by the current owner, the cat was reared indoors for more than half a year. Additionally, the cat was regularly treated with preventive medicine (Advocate for cat; Bayer, Seoul, Korea) to prevent endo- and ecto-parasites. Initially, the sick cat was diagnosed with inflammatory bowel disease based on the history, clinical symptoms, and ultrasonography (data not shown). For the treatment, peroral prednisolone (Solondo Tab. 5 mg; Yuhan, Seoul, Korea) (1 mg/kg) was prescribed twice a day for three months. Although the symptoms improved with treatment, the cat did not appear to be completely cured. One day after the treatment, the cat vomited, and two long proglottids of tapeworms, approximately 30 cm each, were recovered without a scolex (Fig. 1A).

For the diagnosis, fecal floatation tests were performed using a saturated sodium nitrate solution (specific gravity 1.33). Based on the fecal examination and gross morphological characteristics of the worms, the parasite was identified as *Spirometra* sp. (Fig. 1A-C). In the fecal floatation test, no other parasite eggs were identified. For exact species identification, based on morphological and molecular methods, the recovered proglot-

tids of worms were kept in 70% ethyl alcohol and were submitted to the College of Veterinary Medicine, Chungbuk National University, Cheongju, Korea.

Broadline spot-on solution (Boehringer Ingelheim; Seoul, Korea) containing praziquantel was applied twice a month according to the manufacturer's instructions. One month after the last application, a fecal examination was performed; however, *Spirometra* eggs were still observed. Before additional treatment, complete blood count was evaluated using Exigo eos (Boule Diagnostics AB, Spånga, Sweden), and certain hematological values, including mean corpuscular volume, mean corpuscular hemoglobin, and platelets, showed abnormalities (Supplementary Table S1). Thereafter, praziquantel (Distocide® Tab.; Shinpoong Pharm, Seoul, Korea) was administered orally at 35 mg/kg twice, once every two weeks. One month after the last administration, no eggs were observed from the feces and additional fecal examination was performed more than two months later, verifying the completion of treatment.

Case 2

A 3-year-old, 3 kg female cat (domestic shorthair), living in Daegu, Korea, had been vomiting, and proglottids of a tapeworm, approximately 15 cm long, were recovered. Before vomiting, the cat showed symptoms such as anorexia and lethargy without diarrhea. This cat was a stray cat and had been adopted by the current owner and was reared indoors. After adoption, vaccination was not administered. For the diagnosis, a fecal floatation test was performed, and *Spirometra* eggs were identified. Praziquantel (DS Anthelmine Puppy Tab.; Daesung Microbiological Labs., Uiwang, Korea) (12.5 mg) was administered four times daily. Following the treatment, no additional proglottids of *Spirometra* were recovered either through vomiting or feces. Subsequently, anorexia and




Fig. 1. Macroscopical and microscopical characteristics of *Spirometra* sp. recovered from cats in Korea. (A) Adult *Spirometra* recovered from vomiting. (B) Eggs of *Spirometra*. (C) Whole mounted specimens of proglottids (acetocarmine stained). TV, testes and vitelline follicles; Ci, cirrus; Ut, uterus; GP, genital pore; Ov, ovary.

lethargy disappeared. However, an additional fecal flotation test was not performed owing to the owner's refusal.

For exact species identification, proglottids of adult worms were kept in 70% ethyl alcohol and were submitted to the College of Veterinary Medicine, Chungbuk National University, Cheongju, Korea.

Morphological and molecular identification of *Spirometra*

Species identification was performed using both morphological and molecular examinations. The size of the proglottid from Case 1 was 5.69 mm (width, standard deviation 0.30) × 0.68 mm (length, standard deviation 0.05) and the proglottid from Case 2 was sized 5.88 mm (width, standard deviation 0.21) × 1.26 mm (length, standard deviation 0.13). For each sample, at least 10 gravid proglottids were measured. For morphological analysis, the proglottids of adult worms were stained with acetocarmine, and the morphological characteristics confirmed the parasite belonging to *Spirometra* sp. Addi-

tionally, molecular techniques were applied to target *cox1* gene analysis. In brief, genomic DNA of adult worms was extracted from the proglottids using the QIAamp® DNA Mini Kit (Qiagen, Hilden, Germany) according to the manufacturer's instructions. The complete sequence of the *Spirometra cox1* gene was amplified by PCR using the AccuPower HotStart PCR Pre-mix kit (Bioneer, Daejeon, Korea), as previously described [12]. The amplified PCR products were sent to Macrogen (Daejeon, Korea) for sequencing, and two additional internal primers were used (forward: GTT TAC CTC GGC GTG TTT GT; reverse: ATC ACC ACC ACC CAA AGG AT).

Using direct sequencing, two complete *Spirometra* sp. *cox1* sequences (1,566-bp) were obtained. Based on the phylogenetic analysis, both *Spirometra* sp. belonged to Type I (Fig. 2), as suggested by Yamasaki et al. [11]. The phylogenetic tree was constructed using MEGA based on the Maximum Likelihood method with 500 bootstrap replications. Nucleotide analysis showed that the sequences in this study shared 99.7% identity

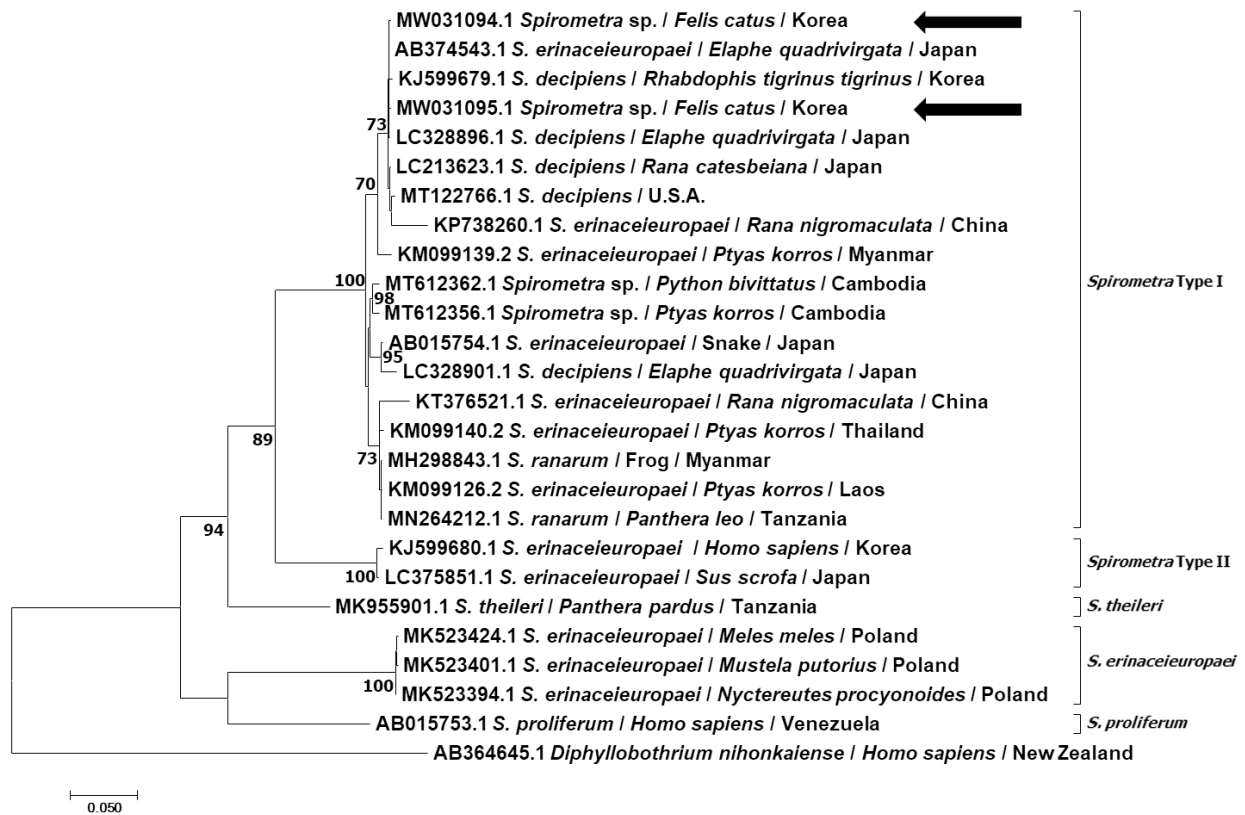


Fig. 2. Phylogenetic relationship of *Spirometra* sp. recovered from cats in Korea based on the complete cytochrome c oxidase subunit 1 gene (1,566 bp). The trees were constructed using MEGA 7.0 using the Maximum Likelihood method with 500 replications. *Diphyllobothrium* was used as outgroups. The sequences identified in this study are indicated by arrows. Bootstrap values of <70 were omitted. Note that the species names in the analysis are as described in the original papers and the clades are designated as described by Yamasaki et al. [11].

with each other, and BLASTn revealed a high genetic identity of 99.7% and 99.4%, respectively, to *S. decipiens* (MT122766) from the USA. The sequences identified in this study were submitted to the GenBank database MW031094-MW031095.

DISCUSSION

The nationwide distribution of *Spirometra* spp. in humans and animals in Korea is well known [2,4]. In cats, previous studies have investigated the epidemiological status of *Spirometra* in restricted regions of Korea, e.g., 41.3% (181/438) of *S. erinacei* in feral cats in Busan [17], 15.8% (34/215) of *S. erinacei* in feral cats in other regions [16], and 41.5% (17/41) of *S. erinacei* in stray cats in Seoul [15]. However, these studies assessed *Spirometra* spp. based on microscopic examination and did not obtain corresponding molecular data. Therefore, additional data on the morphology of adult worms and molecular information are required for clear species identification. [2]. Additionally, to the best of our knowledge, none of the previous studies have reported clinical spirometrosis or sparganosis in animals in Korea.

Previous studies conducted in various countries have reported sparganosis in cats [7,10,19]. However, there are limited reports on the clinical cases of spirometrosis in cats [13]. Spirometrosis is known to cause gastrointestinal symptoms, including vomiting, diarrhea, and weight loss. However, not all infected cats show clinical symptoms [10,11,13]. In our cases, the cat in Case 1 was initially diagnosed as having intestinal bowel disease, which has clinical symptoms similar to those of spirometrosis. The cat had been regularly treated with preventive medicine (Advocate for cat, Bayer). However, it does not contain effective components against cestodes.

In this report, both cats were strays, who are highly potential carriers of different pathogens. However, the cats were reared indoors after they were adopted by their owners. Therefore, we suspect that the cats had been infected by the plerocercoid of *Spirometra* before adoption. Spirometrosis can be treated with praziquantel and mebendazole [20]. In Case 1, the initial treatment was attempted with a spot-on solution type; however, it was unsuccessful. After oral treatment with praziquantel, the cat was successfully cured. In Case 2, unfortunately, after the oral treatment with praziquantel, the owner refused permission to re-examine; therefore, we failed to perform a follow-up of the case.

Stray cats are important reservoir hosts for helminth, and

cestodes infecting felids include *Echinococcus*, *Taenia*, *Dipylidium*, *Mesocestoides*, *Diphyllobothrium*, and *Spirometra* [17,21]. The diagnosis of these parasites at the genus level can be achieved by coproscopic examination. *Diphyllobothrium* has a similar shaped egg as *Spirometra*; however, *Spirometra* eggs have more pointed poles. Exact species identification requires morphological analysis of adult worms or molecular analysis.

In conclusion, this study is the first to report clinical spirometrosis in 2 cats in Korea. Considering the low pathogenicity of spirometrosis in cats, it is uncommon for cats to show clinical symptoms. This report suggests that regular monitoring of health and deworming in companion animals is needed, even when animals are well cared for with regular preventive medical treatment. Additionally, spirometrosis should be considered for differential diagnosis in cases of gastrointestinal symptoms in *Spirometra* endemic areas.

ACKNOWLEDGMENTS

This work was supported by a research grant from the Chungbuk National University in 2019; the Korea Institute of Planning and Evaluation for Technology in Food, Agriculture, Forestry, and Fisheries (IPET) through the Agriculture, Food, and Rural Affairs Convergence Technologies Program for Educating Creative Global Leader, funded by the Ministry of Agriculture, Food, and Rural Affairs (MAFRA) (grant number: 320005-4); and “Regional Innovation Strategy (RIS)” through the National Research Foundation of Korea (NRF) funded by the Ministry of Education (MOE).

CONFLICT OF INTEREST

The authors declare no conflicts of interest related to this work.

REFERENCES

1. Iodziej-Sobocińska M, Stojak J, Kondzior E, Ruczyńska I, Wójcik JM. Genetic diversity of two mitochondrial DNA genes in *Spirometra erinacei* (Cestoda: Diphylobothridae) from Poland. *J Zool Syst Evol Res* 2019; 57: 764-777. <https://doi.org/10.1111/jzs.12319>
2. Jeon HK, Huh S, Sohn WM, Chai JY, Eom KS. Molecular genetic findings of *Spirometra decipiens* and *S. ranarum* in Korea. *Korean J Parasitol*. 2018; 56: 359. <https://doi.org/10.3347/kjp.2018.56.4.359>
3. Jeon HK, Eom KS. Mitochondrial DNA sequence variability of *Spirometra* species in Asian countries. *Korean J Parasitol* 2019;

- 57: 481-487. <https://doi.org/10.3347/kjp.2019.57.5.481>
4. Jeon HK, Park H, Lee D, Choe S, Kim K-H, Huh S, Sohn WM, Chai JY, Eom KS. Human infections with *Spirometra decipiens* plerocercoids identified by morphologic and genetic analyses in Korea. Korean J Parasitol 2015; 53: 299-305. <https://doi.org/10.3347/kjp.2015.53.3.299>
 5. Min DY. Cestode infections in Korea. Korean J Parasitol 1990; 28 (suppl): 123-144. <https://dx.doi.org/10.3347/kjp.1990.28.Suppl.123>
 6. Cho SY, Bae JH, Seo BS. Some aspects of human sparganosis in Korea. Korean J Parasitol 1975; 13: 60-77. <http://dx.doi.org/10.3347/kjp.1975.13.1.60>
 7. Woldemeskel M. Subcutaneous sparganosis, a zoonotic cestodiasis, in two cats. J Vet Diagn Invest 2014; 26: 316-319. <https://doi.org/10.1177/1040638713517697>
 8. Kołodziej-Sobocińska M, Tokarska M, Kowalczyk R. The first report of sparganosis (*Spirometra* sp.) in Eurasian badger (*Meles meles*). Parasitol Int 2014; 63: 397-399. <https://doi.org/10.1016/j.parint.2013.12.011>
 9. Bauchet AL, Joubert C, Helies JM, Lacour SA, Bosquet N, Le Grand R, Guillot J, Lachapelle F. Disseminated sparganosis in a cynomolgus macaque (*Macaca fascicularis*). J Comp Pathol 2013; 148: 294-297. <https://doi.org/10.1016/j.jcpa.2012.08.003>
 10. Schmidt RE, Reid JS, Garner FM. Sparganosis in a cat. J Small Anim Pract 1968; 9: 551-553. <https://doi.org/10.1111/j.1748-5827.1968.tb04581.x>
 11. Yamasaki H, Sanpool O, Rodpai R, Sadaow L, Laummaunwai P, Un M, Thanchomnang T, Laymanivong S, Aung WPP, Intapan PM, Maleewong W. *Spirometra* species from Asia: Genetic diversity and taxonomic challenges. Parasitol Int 2020; 80: 102181. <https://doi.org/10.1016/j.parint.2020.102181>
 12. Scholz T, Kuchta R, Brabec J. Broad tapeworms (Diphyllobothriidae), parasites of wildlife and humans: recent progress and future challenges. Int J Parasitol Parasites Wildl 2019; 9: 359-369. <https://doi.org/10.1016/j.ijppaw.2019.02.001>
 13. Ugarte CE, Thomas DG, Gasser RB, Hu M, Scott I, Collett MG. *Spirometra erinacei*/*S. erinacei* in a feral cat in Manawatu with chronic intermittent diarrhoea. N Z Vet J 2005; 53: 347-351. <https://doi.org/10.1080/00480169.2005.36573>
 14. Eom KS, Park H, Lee D, Choe S, Kim KH, Jeon HK. Mitochondrial genome sequences of *Spirometra erinacei* and *S. decipiens* (Cestoidea: Diphylobothriidae). Korean J Parasitol 2015; 53: 455-463. <http://dx.doi.org/10.3347/kjp.2015.53.4.455>
 15. Huh S, Sohn WM, Chai JY. Intestinal parasites of cats purchased in Seoul. Korean J Parasitol 1993; 31: 371-373. <https://doi.org/10.3347/kjp.1993.31.4.371>
 16. Kang MI, Han DU. Intestinal parasite infections in stray cats. J Vet Clin 2003; 20: 413-418 (in Korean).
 17. Sohn WM, Chai JY. Infection status with helminthes in feral cats purchased from a market in Busan, Republic of Korea. Korean J Parasitol 2005; 43: 93-100. <http://dx.doi.org/10.3347/kjp.2005.43.3.93>
 18. Jeon HK, Park H, Lee D, Choe S, Eom KS. *Spirometra decipiens* (Cestoda: Diphylobothriidae) collected in a heavily infected stray cat from the Republic of Korea. Korean J Parasitol 2018; 56: 87-91. <https://doi.org/10.3347/kjp.2018.56.1.87>
 19. Buergelt CD, Greiner EC, Senior DF. Proliferative sparganosis in a cat. J Parasitol 1984; 70: 121-125. <https://doi.org/10.2307/3281933>
 20. Tappe D, Berger L, Haeupler A, Muntau B, Racz P, Harder Y, Specht K, da Costa CP, Poppert S. Molecular diagnosis of subcutaneous *Spirometra erinacei* sparganosis in a Japanese immigrant. Am J Trop Med Hyg 2013; 88: 198-202. <https://doi.org/10.4269/ajtmh.2012.12-0406>
 21. Taylor MA, Coop RL, Wall RL. Parasites of dogs and cats. In Taylor MA, Coop RL, Wall RL eds, Veterinary Parasitology. 4th ed. Chichester, UK. Wiley Blackwell; 2016, pp 599-677.