

Reliability of panoramic radiography in predicting proximity of third molars to the mandibular canal: A comparison using cone-beam computed tomography

Willy James Porto Nunes¹, Aline Lisboa Vieira¹, Letícia Drumond de Abreu Guimarães², Carlos Eduardo Pinto de Alcântara³, Francielle Silvestre Verner⁴, Matheus Furtado de Carvalho^{3,*}

¹Department of Clinical Dentistry, Federal University of Juiz de Fora, Brazil

²Department of Stomatology, University of São Paulo, Brazil

³Department of Oral and Maxillofacial Surgery, Federal University of Juiz de Fora, Brazil

⁴Department of Oral and Maxillofacial Radiology, Federal University of Juiz de Fora, Brazil

ABSTRACT

Purpose: The purpose of this study was to analyze the reliability of 7 panoramic radiographic signs for predicting proximity of the root apices of mandibular third molars to the mandibular canal using cone-beam computed tomography and to correlate these findings with the Pell and Gregory and the Winter classification systems.

Materials and Methods: An observational, cross-sectional, descriptive study was conducted on 74 patients with bilateral impacted mandibular third molars. Four panoramic radiographic signs were observed in the tooth root (darkening, deflection, and narrowing of the root apices, and bifid apices), and another 3 in the mandibular canal (diversion, narrowing, and interruption of the mandibular canal). Cone-beam computed tomography images were analyzed to identify disruption and diversion of the mandibular canal and root deflection.

Results: Binary logistic regression showed that only 4 of the 7 panoramic radiographic signs were able to predict proximity of the root apices of the mandibular third molars to the mandibular canal: darkening of the root, deflection of the root, narrowing of the root, and interruption of the mandibular canal ($P < 0.05$).

Conclusion: Darkening, deflection, and narrowing of the root, in tandem with the interruption of the mandibular canal on panoramic radiographs, indicate that cone-beam computed tomography should be performed when planning the extraction of impacted mandibular third molars. Proximity between mandibular third molars and the mandibular canal is correlated with the Winter classification. (*Imaging Sci Dent 2021; 51: 9-16*)

KEY WORDS: Cone-beam Computed Tomography; Mandibular Nerve; Radiography, Panoramic; Third Molar

Introduction

Mandibular third molar extraction is one of the most common procedures performed in oral surgery, and is capable of causing transitory complications (e.g., pain, bleeding, and swelling) or permanent sequelae (e.g., paresthesia), which may have a profound effect on quality of life.¹⁻³

Paresthesia of the inferior alveolar nerve involves spontaneous and unpleasant sensations (tingling, numbing, or burning) in the lower third of the face due to exposure of

the inferior alveolar nerve.⁴ Most of these injuries are transitory and show spontaneous regression. However, severe damage may cause permanent paresthesia. Therefore, a pre-surgical analysis of the mandibular anatomy through imaging is recommended.⁵

The Winter and the Pell and Gregory classification systems identify the dental crown position of the third molars without describing the relationship between the root apices and mandibular canal.^{6,7} According to Rood and Shehab,⁸ 7 signs of panoramic radiography are suggestive of proximity between the root apices and the mandibular canal: darkening of the root, deflection of the root, narrowing of the root, bifid root apex, diversion of the mandibular canal, narrowing of the canal, and interruption of the canal.

Received April 25, 2020; Revised July 17, 2020; Accepted September 25, 2020

*Correspondence to : Prof. Matheus Furtado de Carvalho

Universidade Federal de Juiz de Fora, Rua José Lourenço Kelmer, s/n°, São Pedro, Juiz de Fora, Minas Gerais, CEP: 36036-900, Brazil

Tel) 55-32-2102-3851, E-mail) dr.matheusfurtado@yahoo.com.br

Copyright © 2021 by Korean Academy of Oral and Maxillofacial Radiology

This is an Open Access article distributed under the terms of the Creative Commons Attribution Non-Commercial License (<http://creativecommons.org/licenses/by-nc/3.0>) which permits unrestricted non-commercial use, distribution, and reproduction in any medium, provided the original work is properly cited.

Imaging Science in Dentistry · pISSN 2233-7822 eISSN 2233-7830

However, it has been suggested that not all of these panoramic signs are reliable due to the distortion of linear measurements and overlapping of underlying structures.⁹⁻¹¹ Costa et al.¹² did not find a positive correlation between the presence of panoramic signs of the third molar and proximity to the inferior alveolar nerve.

In this context, there is a case to be made for the use of cone-beam computed tomography (CBCT), in which the images can be reformatted and viewed in multiplanar reconstructions.¹³ Ghai and Choudhury¹⁴ concluded that darkening with deflection of the root, interruption of the white line on panoramic radiography, and an interradicular location of the mandibular canal with thinning of the lingual cortex by the root tips on CBCT, were highly predictive of paresthesia.

No previous study has evaluated predictive panoramic signs of proximity between the dental apices and the mandibular canal using cone-beamed computed tomography and correlated these findings with the Pell and Gregory and the Winter classification systems; therefore, this study was conducted to address that gap in the literature.

Materials and Methods

This study was approved by the Human Research Ethics Committee of the Federal University of Juiz de Fora (No. 2424,513/2017) in accordance with the Helsinki Declaration of the World Medical Association.

This observational, cross-sectional, and descriptive study involved the evaluation of panoramic radiography and cone-beam computed tomography of 150 patients from a public university database. Imaging examinations containing bilateral impacted mandibular third molars were included, whereas those with pathological changes (cysts, tumors, fibro-osseous lesions) and incomplete root development were excluded. The final sample consisted of 74 patient examinations (148 teeth).

Panoramic radiography was obtained using an Orthopantomograph[®] OP300 machine (Instrumentarium Dental, Tuusula, Finland) with the patient with a semi-open mouth, positioned according to the light indications of the device, with peak kilovoltage (kVp) and current (mA) selected according to the patient's biotype. CBCT images were obtained using the ICAT[®] Next Generation device (Imaging Sciences International, Hatfield, PA, USA) with the patient in maximum habitual intercuspation, operating at 120 kVp for 26.9 s at 8 mA, with a field of view of 6 cm × 13 cm and a voxel size of 0.25 mm.

The images were analyzed by 3 oral radiologists, who were previously trained and calibrated in a pilot test with a

smaller sample (n = 20) that was not part of the final sample of the study. The images were viewed on a 21.5-inch high-definition LCD monitor (1920 × 1080), (Dell S2240L, Dell Computers of Brazil Ltda., Eldorado do Sul, Rio Grande do Sul, Brazil) in a room with dimmed lighting and standardized conditions.

The exams were coded, randomized, and evaluated at different times, without patient identification. First, panoramic radiographs were evaluated in the Windows[®] photo viewer. The images were exported in TIFF format without compression. Fifteen days later, the CBCT images were evaluated using Xoran Cat[®] software version 3.0.34 (Xoran Technologies, Ann Arbor, MI, USA), using coronal, sagittal, and axial reconstructions, as well as panoramic and oblique sections when necessary. A limit of 20 daily assessments was standardized to avoid visual fatigue and impaired analysis. The zoom, brightness, and contrast tools could be used. Thirty days later, 20% of the samples were reassessed to calculate intra-rater agreement.

The panoramic radiographs were analyzed dichotomously with regard to the presence or absence of any of the 7 radiographic signs proposed by Rood and Shehab:⁸ darkening (loss of density), deflection (abrupt diversion of direction), and narrowing (taper) of the root apices; bifid apices (double shadow of the periodontal membrane); and diversion, narrowing, and interruption of the mandibular canal (Fig. 1).

The CBCT images were analyzed qualitatively using 3 variables to assess proximity between the third molars and the mandibular canal: 1) intimate contact (interruption of the canal; 0: absence, 1: presence) (Fig. 2A); 2) root deflection (abrupt diversion in the direction of the root; 0: absent, 1: present) (Fig. 2B); and 3) mandibular canal diversion (0: absent, 1: present) (Fig. 2C). Also analyzed were interruption of the buccal or lingual mandibular cortex (0: both cortices preserved, 1: discontinuity of the buccal cortex, 2: discontinuity of the lingual cortex) (Fig. 2D) and the location of the mandibular canal in relation to the root apices of third molars (1: inferior [Fig. 3A], 2: buccal [Fig. 3B], 3: lingual [Fig. 3C], 4: interradicular [Fig. 3D]).

The positioning of the teeth was also analyzed according to the Pell and Gregory classification system, as follows: grade I: the radiographic space between the distal face of the second molar and the anterior edge of the mandibular ramus is greater than the mesiodistal diameter of the third molars; grade II: the radiographic space between the distal face of the inferior second molar and the anterior edge of the mandibular ramus is equal to the mesiodistal measurement of the third molars; grade III: the radiographic space distal to the second molar is insufficient to accommodate

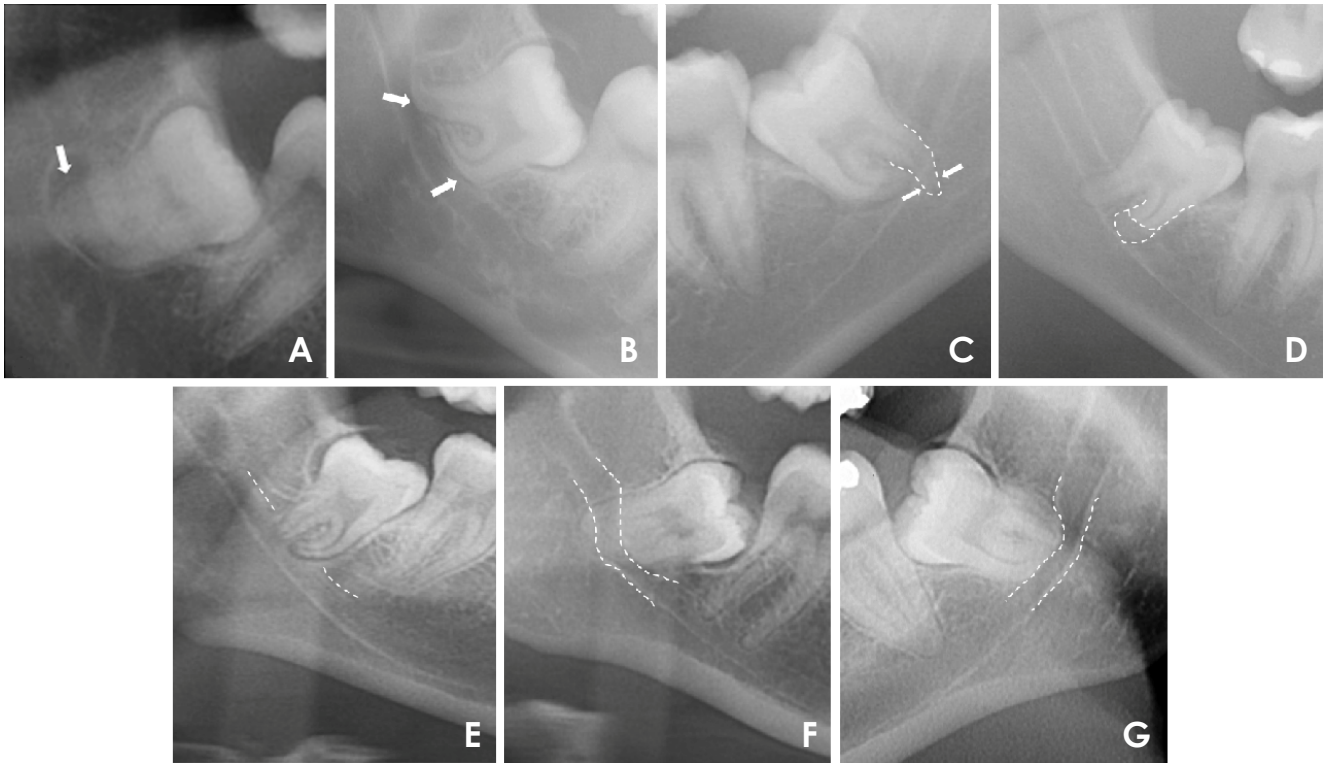


Fig. 1. Radiographic images of the relationship between the root apices of the mandibular third molar and mandibular canal. A. Darkening of the root apices. B. Deflection of the root apices in contact with the mandibular canal. C. Abrupt narrowing of the distal root. D. Bifid apices. E. Interruption of the mandibular canal. F. Abrupt diversion of the mandibular canal. G. Abrupt narrowing of the mandibular canal.

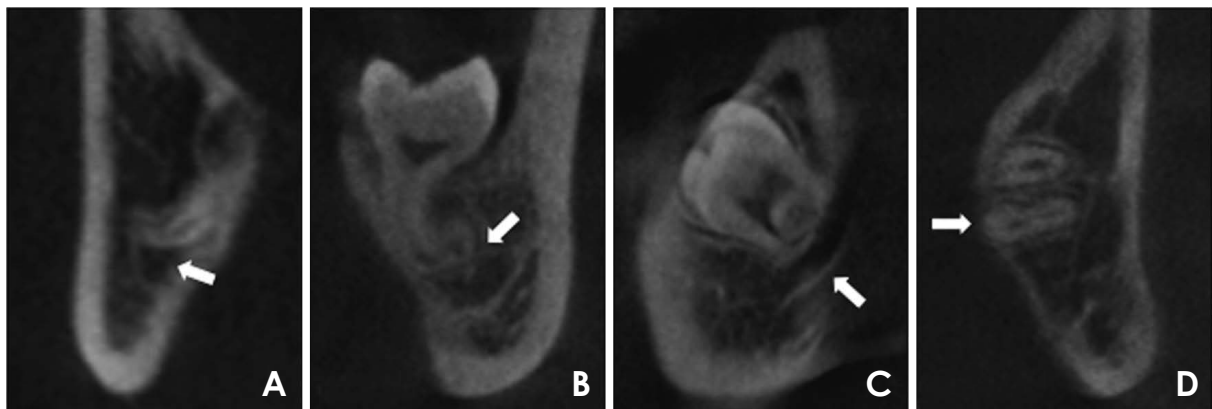


Fig. 2. Cone-beam computed tomography coronal (A and D) and sagittal (B and C) sections show the relationship between the mandibular third molar and mandibular canal. A. intimate contact with interruption of the mandibular canal. B. Deflection of the root, emphasizing the path of the mandibular canal. C. Diversion of the mandibular canal. D. Interruption of the mandibular lingual cortex.

the mandibular third molars; depth A: the occlusal face of the third molar is on the same level as the occlusal plane of the second molar; depth B: the occlusal face of the third molars is between the occlusal and cervical surfaces of the second molar depth; and depth C: the occlusal face of the third molars is below the cervical face of the second molar crown.⁷ The mandibular third molars were further assessed

using the Winter classification system based on the angulation of their long axis with the long axis of the second molar, as vertical, mesioangular, distoangular, horizontal, inverted, and transverse (buccal or lingual).⁸

The data were analyzed using descriptive statistics for both panoramic radiography and CBCT. Intra-rater agreement was assessed using the kappa (dichotomous variables)

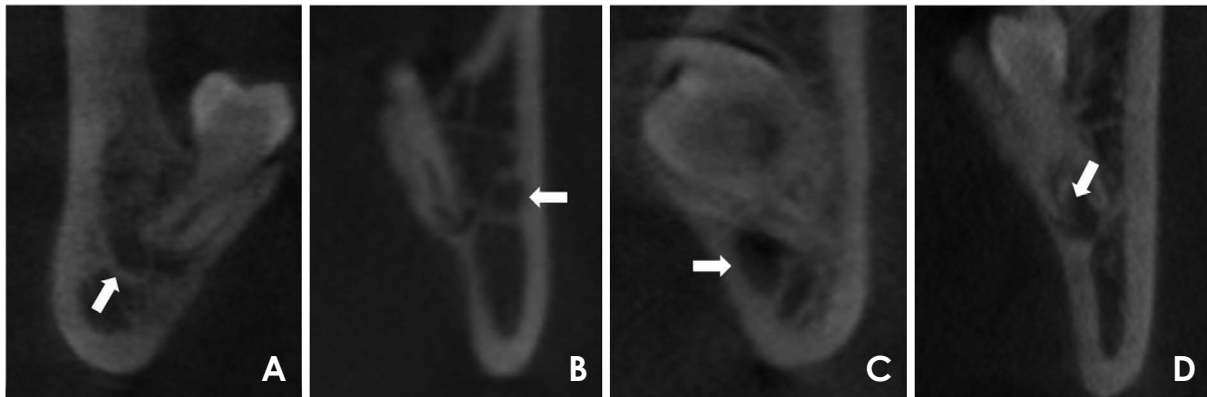


Fig. 3. Cone-beam computed tomography coronal sections show the position of the mandibular canal in relation to the third molar. A. Inferior. B. Buccal. C. Lingual. D. Interradicular.

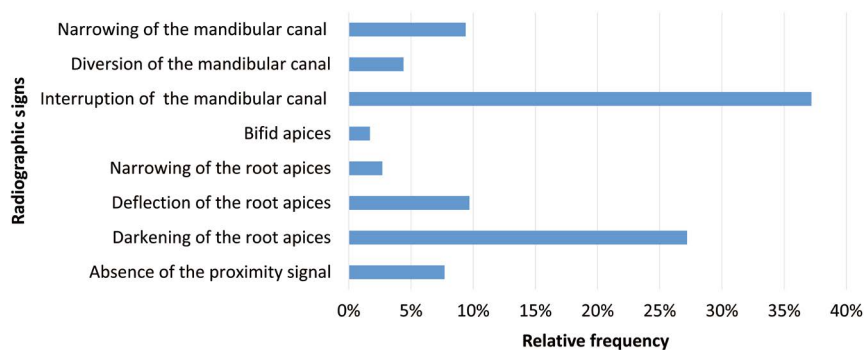


Fig. 4. Distribution of radiographic signs identified on panoramic radiographs.

and weighted kappa (qualitative variables with more than 2 scores) tests. A binary logistic regression model, showing odds ratios (ORs), was constructed to verify whether panoramic signs could predict maximum contact of the mandibular third molars with the mandibular canal, and Spearman rank correlation analysis was conducted to assess the correlation of the number of panoramic radiography signs with maximum contact. Associations between CBCT variables and proximity to the mandibular canal were assessed using the chi-square test. The data were then analyzed using SPSS version 23.0 (IBM Corp., Armonk, NY, USA), with a significance level of 95%.

Results

The intra-rater kappa values for the panoramic radiography and CBCT images ranged from 0.91 to 0.97 and from 0.93 to 0.96, respectively.

Interruption of the mandibular canal (37.2%) and darkening of the root (27.2%) were the most frequently observed signs on panoramic radiographs (Fig. 4). Most of the analy-

zed teeth showed 2 panoramic signs suggestive of proximity between mandibular third molars and the mandibular canal. Also noteworthy was the association between interruption of the mandibular canal and darkening of the root in 20% of these teeth. Ten teeth showed a combination of 5 panoramic signs (Fig. 5). In the Spearman correlation analysis, a higher number of signs for a single tooth increased the chances of close contact between a mandibular third molar and the mandibular canal ($P=0.451$ and $P<0.001$).

No significant difference was found when comparing the position of the third molars on the right and left sides. The positioning of the teeth according to the Pell and Gregory classification was not associated with proximity between mandibular third molars and the mandibular canal ($P>0.05$). However, this proximity was associated with the Winter classification (Table 1).

Table 2 shows that root deflection, interruption, and diversion of the mandibular canal were strongly associated with panoramic radiography signs when analyzed using CBCT ($P<0.05$, Table 2). Finally, binary logistic regression analysis (Table 3) showed that darkening, deflection, and nar-

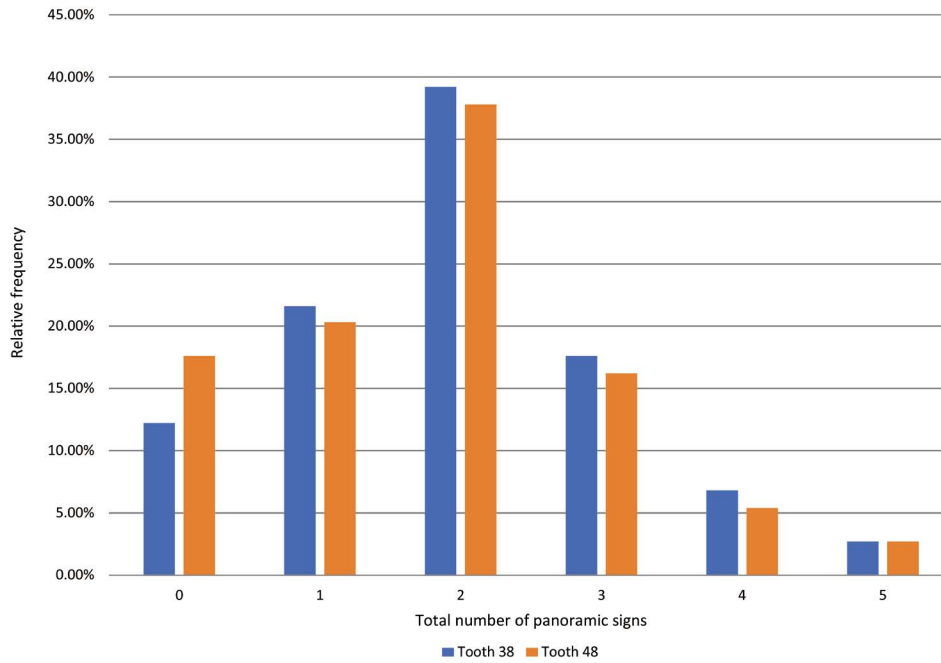


Fig. 5. Distribution of the number of panoramic signs found on the same tooth.

Table 1. Distribution of teeth according to the Pell and Gregory and the Winter classification systems and their association with the mandibular canal when assessed using cone-beam computed tomography

	Left third molar	Right third molar	Intimate contact with mandibular canal	P value
Pell and Gregory				
Class I	12 (16.2%)	16 (21.6%)	23/28 (82.1%)	0.57
Class II	60 (81.1%)	55 (74.3%)	94/115 (81.7%)	
Class III	2 (2.7%)	3 (4.1%)	5/5 (100.0%)	
A	34 (45.9%)	38 (51.4%)	60/72 (83.3%)	0.86
B	36 (48.6%)	32 (43.2%)	55/68 (80.9%)	
C	4 (5.4%)	4 (5.4%)	7/8 (87.5%)	
Winter				
Vertical	24 (32.4%)	24 (32.4%)	42/48 (87.5%)	<0.05
Mesioangular	30 (40.5%)	31 (41.9%)	48/61 (78.7%)	
Distoangular	7 (9.5%)	10 (13.5%)	17/17 (100.0%)	
Horizontal	12 (16.2%)	7 (9.5%)	12/19 (63.2%)	
Inverted	0	0	–	
Buccal transverse	0	0	–	
Lingual transverse	1 (1.4%)	2 (2.7%)	3/3 (100%)	

P value: chi-square test

rowing of the root and interruption of the mandibular canal predicted proximity between the third molar and mandibular canal ($P < 0.05$).

Discussion

Shahidi et al.¹¹ highlighted that, although CBCT provides

a better assessment of anatomical structures and greater intraoperative safety, panoramic radiography is still the most widely used modality to analyze proximity between the third molars and the mandibular canal. The present study showed that, among the 148 impacted mandibular third molars, 11 teeth did not present panoramic signs suggestive of proximity to the mandibular canal.

Table 2. Distribution of tomographic variables and their association with proximity between mandibular third molars and the mandibular canal

	Left third molar	Right third molar	P value
Interruption of the mandibular canal	60 (81.1%)	62 (83.8%)	<0.05
Location of mandibular canal to third molar			0.40
Vestibular	19 (25.7%)	21 (28.4%)	
Among the root apices	2 (2.7%)	1 (1.4%)	
Lingual	12 (16.2%)	6 (8.1%)	
Inferior	41 (55.4%)	46 (62.2%)	
Interruption of the mandible			0.52
Buccal	3 (4.1%)	2 (2.7%)	
Lingual	16 (21.6%)	21 (28.4%)	
Deflection of the root	37 (50%)	40 (54.1%)	<0.05
Diversion of the mandibular canal	25 (33.8%)	23 (31.1%)	<0.05

P value: chi-square test

Table 3. Binary logistic regression to predict intimate contact of mandibular third molars with the mandibular canal from radiographic proximity signs on panoramic radiographs

Radiographic signs	β	SE	Wald test	Odds ratio test	95% confidence interval of the odds ratio		P value
					Minimum	Maximum	
Darkening of the root apices	3.18	.60	28.04	24.16	7.43	78.54	<.00
Deflection of the root apices	4.15	1.11	13.93	64.00	7.21	568.12	<.00
Narrowing of the root apices	2.77	1.16	5.70	16.00	1.64	155.76	.01
Bifid apices	22.03	17974.84	.00	3692513926.51	0.00	–	.99
Interruption of the mandibular canal	3.38	.58	33.63	29.42	9.38	92.28	<.00
Diversion of the mandibular canal	22.03	11147.52	.00	3692513926.51	0.00	–	.99
Narrowing of the mandibular canal	22.03	7595.75	.00	3692513926.51	0.00	–	.99
Constant	–.82	.45	3.32	0.43			.06

Having prior knowledge of these signs could prevent surgical complications such as temporary or permanent paresthesia. Cheung et al.¹ showed that postoperative recovery deficits were most prominently noted at 3 months. By the end of the follow-up period, 67% of the patients had recovered completely. Although the present study was not clinical in nature, the authors nonetheless suggest that all patients facing extraction of an impacted third molar sign an informed consent form and recommend that surgery be performed by an experienced oral surgeon.

Concerns about preserving the inferior alveolar nerve led Rood and Shehab⁸ to identify 7 signs suggestive of proximity between the root apices and the mandibular canal. Gomes et al.¹⁵ concluded that panoramic radiography is not capable of predicting neurosensory complications because only 3.5% of patients developed paresthesia despite these

signs having been identified in 61% of the cases.

Conversely, Huang et al.² reported that 3 panoramic signs (interruption of the mandibular canal, deflection, and narrowing of the root apices) were significantly associated with sensory impairment. In the present study, the incidence of paresthesia was not evaluated; nonetheless, these 3 signs predicted intimate contact.

Peker et al.¹⁶ investigated correlations between panoramic signs suggestive of contact between the roots of mandibular third molars and the mandibular canal on CBCT in 191 patients and concluded that interruption of the mandibular canal and darkening of the root apices were predictive of intimate contact. The same authors further concluded that panoramic radiographs could not accurately identify the number of root apices of the mandibular third molar. Similar results were also found in the present study, where

darkening, deflection, and narrowing of the root and interruption of the mandibular canal predicted proximity of the root apices to the mandibular canal. In addition, there was a strong association between interruption of the mandibular canal and darkening of the roots in 20% of cases.

The statistical results for these 4 panoramic signs were significant. Deflection of the root presented an odds ratio (OR) of 64, meaning it was 64 times more likely to be associated with intimate contact. Interruption of the mandibular canal presented an OR of 29.42, while darkening of the root presented an OR of 24.16, and an OR of 16 was found for narrowing of the root, reinforcing the findings of previous studies.^{17,18} The other evaluated signs showed a prevalence of less than 10%, being, in decreasing order, deflection of the root, diversion of mandibular canal, and bifid apices. Kim et al.¹⁹ demonstrated that narrowing of the root was the most significant radiographic sign as a risk factor for injury to the inferior alveolar nerve, with an OR of 22.98.

Some authors^{1,9,18} have suggested that third molar angulation does not represent a risk factor for inferior alveolar nerve injury. Other authors have defended using the Winter classification as a strategy to prevent surgical complications that might result from impacted third molar extraction.^{20,21} The present study found statistically significant results ($P=0.032$) for the Winter classification. Blondeau and Daniel⁹ reported that most cases of paresthesia involved mesioangular teeth. The present study found a high prevalence of mesioangular teeth (78.7%). However, the lingual transversal and distoangular positions showed the best results (100%) for proximity between the third molar and the mandibular canal.

In our study, the Pell and Gregory classification was not associated with close contact between the third molar and the mandibular canal ($P>0.05$), aligning with the findings of Carmichael and McGowan.²² Notwithstanding, teeth with more significant bone inclusions (III and C) showed the highest percentages of intimate contact.

All 3 variables analyzed on CBCT (interruption and diversion of the mandibular canal and root deflection) were strongly associated with panoramic signs ($P<0.05$). Wang et al.²³ affirmed that intimate contact between the third molar and the mandibular canal on CBCT was significantly associated with injuries to the inferior alveolar nerve. Therefore, it is suggested that a study should explore the correlations of darkening, deflection, and narrowing of the root and interruption of the mandibular canal, as visualized on CBCT, with postoperative clinical findings.

In conclusion, darkening, deflection, and narrowing of the root, in tandem with interruption of the mandibular canal

on panoramic radiographs, indicate that CBCT should be performed when planning the extraction of an impacted mandibular third molar. The proximity between mandibular third molars and the mandibular canal was correlated with the Winter classification.

Conflicts of Interest: None

References

- Cheung LK, Leung YY, Chow LK, Wong MC, Chan EK, Fok YH. Incidence of neurosensory deficits and recovery after lower third molar surgery: a prospective clinical study of 4338 cases. *Int J Oral Maxillofac Surg* 2010; 39: 320-6.
- Huang CK, Lui MT, Cheng DH. Use of panoramic radiography to predict postsurgical sensory impairment following extraction of impacted mandibular third molars. *J Chin Med Assoc* 2015; 78: 617-22.
- Carter K, Worthington S. Predictors of third molar impaction: a systematic review and meta-analysis. *J Dent Res* 2016; 95: 267-76.
- Sarikov R, Juodzbalys G. Inferior alveolar nerve injury after mandibular third molar extraction: a literature review. *J Oral Maxillofac Res* 2014; 5: e1.
- Nakayama K, Nonoyama M, Takaki Y, Kagawa T, Yuasa K, Izumi K, et al. Assessment of the relationship between impacted mandibular third molars and inferior alveolar nerve with dental 3-dimensional computed tomography. *J Oral Maxillofac Surg* 2009; 67: 2587-91.
- Pell GJ, Gregory GT. Impacted third molars: classification and modified technique for removal. *Dent Digest* 1933; 39: 330-8.
- Winter GB. Principles of exodontia as applied to the impacted mandibular third molars; a complete treatise on the operative technic with clinical diagnoses and radiographic interpretation. St Louis: American Medical Book Co; 1926.
- Rood JP, Shehab BA. The radiological prediction of inferior alveolar nerve injury during third molar surgery. *Br J Oral Maxillofac Surg* 1990; 28: 20-5.
- Guerrero ME, Nackaerts O, Beinsberger J, Horner K, Schoenaers J, Jacobs R, et al. Inferior alveolar nerve sensory disturbance after impacted mandibular third molar evaluation using cone beam computed tomography and panoramic radiography: a pilot study. *J Oral Maxillofac Surg* 2012; 70: 2264-70.
- Patel V, Moore S, Sproat C. Coronectomy - oral surgery's answer to modern day conservative dentistry. *Br Dent J* 2010; 209: 111-4.
- Shahidi S, Zamiri B, Bronoosh P. Comparison of panoramic radiography with cone beam CT in predicting the relationship of the mandibular third molar roots to the alveolar canal. *Imaging Sci Dent* 2013; 43: 105-9.
- Costa FW, Fontenele EH, Bezerra TP, Ribeiro TR, Carneiro BG, Soares EC. Correlation between radiographic signs of third molar proximity with inferior alveolar nerve and postoperative occurrence of neurosensory disorders: a prospective, double-blind study. *Acta Cir Bras* 2013; 28: 221-7.
- Ahmad M, Jenny J, Downie M. Application of cone beam com-

- puted tomography in oral and maxillofacial surgery. *Aust Dent J* 2012; 57 Suppl 1: 82-94.
14. Ghai S, Choudhury S. Role of panoramic imaging and cone beam CT for assessment of inferior alveolar nerve exposure and subsequent paresthesia following removal of impacted mandibular third molar. *J Maxillofac Oral Surg* 2018; 17: 242-7.
 15. Gomes AC, Vasconcelos BC, Silva ED, Caldas Ade F Jr, Pita Neto IC. Sensitivity and specificity of pantomography to predict inferior alveolar nerve damage during extraction of impacted lower third molars. *J Oral Maxillofac Surg* 2008; 66: 256-9.
 16. Peker I, Sarikir C, Alkurt MT, Zor ZF. Panoramic radiography and cone-beam computed tomography findings in preoperative examination of impacted mandibular third molars. *BMC Oral Health* 2014; 14: 71.
 17. Leung YY, Cheung LK. Correlation of radiographic signs, inferior dental nerve exposure, and deficit in third molar surgery. *J Oral Maxillofac Surg* 2011; 69: 1873-9.
 18. Blaeser BF, August MA, Donoff RB, Kaban LB, Dodson TB. Panoramic radiographic risk factors for inferior alveolar nerve injury after third molar extraction. *J Oral Maxillofac Surg* 2003; 61: 417-21.
 19. Kim JW, Cha IH, Kim SJ, Kim MR. Which risk factors are associated with neurosensory deficits of inferior alveolar nerve after mandibular third molar extraction? *J Oral Maxillofac Surg* 2012; 70: 2508-14.
 20. Valmaseda-Castellón E, Berini-Aytés L, Gay-Escoda C. Inferior alveolar nerve damage after lower third molar surgical extraction: a prospective study of 1117 surgical extractions. *Oral Surg Oral Med Oral Pathol Oral Radiol Endod* 2001; 92: 377-83.
 21. Blackburn CW, Bramley PA. Lingual nerve damage associated with the removal of lower third molars. *Br Dent J* 1989; 167: 103-7.
 22. Carmichael FA, McGowan DA. Incidence of nerve damage following third molar removal: a West of Scotland Oral Surgery Research Group study. *Br J Oral Maxillofac Surg* 1992; 30: 78-82.
 23. Wang D, Lin T, Wang Y, Sun C, Yang L, Jiang H, et al. Radiographic features of anatomic relationship between impacted third molar and inferior alveolar canal on coronal CBCT images: risk factors for nerve injury after tooth extraction. *Arch Med Sci* 2018; 14: 532-40.