

# Acute Diaphragmatic Injuries Associated with Traumatic Rib Fractures: Experiences of a Major Trauma Centre and the Importance of Intra-Pleural Assessment

Azhar Hussain, M.R.C.S., Ian Hunt, F.R.C.S. (C.Th.)

*Department of Cardiothoracic Surgery, St. George's Hospital, London, UK*

## ARTICLE INFO

**Received** September 28, 2020

**Revised** November 10, 2020

**Accepted** November 17, 2020

## Corresponding author

Azhar Hussain

**Tel** 44-2087253287

**Fax** 44-2087250068

**E-mail** azharhussain@nhs.net

## ORCID

<https://orcid.org/0000-0003-3941-4553>

**Background:** Diaphragmatic injuries following blunt or penetrating thoraco-abdominal trauma are rare, but can be life-threatening. Rib fractures are the most common associated injury in patients with a traumatic diaphragmatic injury (TDI). We hypothesized that the pattern of rib fracture injuries could dictate the likelihood of acute TDIs.

**Methods:** A retrospective study was carried out between April 2014 and October 2018 to analyze patients with TDIs and rib fractures at a major trauma center in London, United Kingdom.

**Results:** Over the study period, 1,560 patients had rib fractures, of whom 14 had associated diaphragmatic injuries. Left-sided diaphragmatic injuries were found in 8 patients (57%). A significant proportion of the rib fractures were located posterolaterally (44.9%). The highest frequency of fractures was found in ribs 5–10, which accounted for 74% of all the fractures. Ten patients underwent surgery, of whom 7 were diagnosed with a diaphragmatic injury intraoperatively after video-assisted thoracoscopic surgery assessment of the pleural cavity. Two patients died due to severe injuries of other organs and the remaining 2 patients were managed conservatively.

**Conclusion:** Our series of patients demonstrates a relationship between significant rib fractures and diaphragmatic injuries in trauma patients, and the diagnostic difficulties in identifying the condition. We found that the location of the rib fractures and the pattern of injury in patients with TDIs were much lower and posterolateral in the chest wall without a preference for laterality. We suggest using a thoracoscope in patients undergoing chest wall surgery post-trauma to aid in diagnosing this condition.

**Keywords:** Rib fractures, Trauma, Traumatic diaphragmatic hernia, Video-assisted thoracic surgery

## Introduction

Diaphragmatic injuries following blunt or penetrating thoraco-abdominal trauma are rare, but can potentially be life-threatening. The diagnosis of these injuries is difficult and is often overlooked despite the use of several imaging techniques. The rate of missed diagnoses using computed tomography can be as high as 63% [1], leading to delays in treatment and subsequent increases in morbidity and mortality [2]. The true incidence of traumatic diaphragmatic injury (TDI) is unknown, but has been reported to be approximately 2.1% for blunt trauma and 3.4% for penetrat-

ing trauma [3]. The mechanism of TDI is predominantly thought to involve increased intra-abdominal pressure secondary to blunt abdominal trauma [4]. This is thought to lead to a laceration of the posterolateral part of the diaphragm, which is the weakest part during embryonic development.

In contrast to TDI, rib fractures are one of the most common traumatic injuries in patients who present with blunt thoracic trauma and are found in approximately 10% of all trauma patients. Rib fractures are also the most common associated injury in patients who have a diagnosed TDI [5]. The number, location, and degree of displacement of the

fractured ribs dictate the likelihood of further intra-abdominal or intra-thoracic injuries. In particular, fractures of the lower ribs have been associated with a higher likelihood of diaphragmatic injury. We hypothesize that such diaphragmatic injuries may be secondary to penetrating trauma from the fractured lower ribs (in the presence of raised intra-abdominal pressure). The aim of this retrospective study was to focus on this less well described subgroup of TDI patients with concomitant rib fractures. In particular, we analyzed their clinical presentation, methods of diagnosis, and the surgical management at our institution.

## Methods

### Patients

This was a retrospective evaluation of patients admitted to a major trauma center based in London. Patients admitted with chest wall injuries and diagnosed with a diaphragmatic injury were identified between April 2014 and October 2018 from the prospectively maintained UK Trauma and Research Network Database, which records all injuries sustained. Patients with TDI diagnosed at the intraoperative stage were identified by evaluating the medical records of all patients who underwent a thoracic surgical procedure at St. George's University Hospital, London. Medical records were reviewed concerning sex, age, mechanism of injury, pattern of injury, diagnostic methods, associated injuries, surgical approach, hospital stay, and postoperative morbidity and mortality.

### Ethical approval

All procedures performed in studies involving human participants were in accordance with the ethical standards of the institutional and/or national research committee and with the 1964 Helsinki declaration and its later amendments or comparable ethical standards. It should be noted that this was a retrospective study and the study design, review, and analysis were in compliance with our institution's ethical standards for retrospective studies. The study was approved by the Institutional Review Board of St. George's University NHS Hospital (IRB approval no., 00010095).

### Human and animal rights and informed consent

This article does not contain any studies with animals

performed by any of the authors. Informed consent was obtained from all individual participants included in the study. No identifying information is present in the presented work.

## Results

During the study period, a total of 1,560 patients were identified who were admitted with chest wall trauma out of a total of 40,000 trauma patients admitted to the emergency department. Seventy-five patients had isolated sternal fractures and were excluded. Of these, 14 patients were eventually diagnosed with associated diaphragmatic injuries. The median age of these 14 patients was 49 years (range, 16–84 years) with 10 males and 4 females. There were 8 left-sided and 6 right-sided diaphragmatic injuries.

Although the mechanism of injury of rib fractures is usually blunt traumatic injury, 2 patients admitted with a penetrating stab wound to the thorax had radiological evidence of rib fractures (and hence were included in our study). The remaining patients all had blunt traumatic injuries to the thorax (and abdomen in some cases) with the majority being either involved in a motor vehicle accident (5 patients) or a mechanical fall (6 patients). One patient was physically assaulted. All patients were admitted via the trauma pathway. A summary of the patients' clinical characteristics is given in Table 1.

All patients were admitted to the emergency department through the trauma pathway and subsequently underwent a computed tomography (CT) scan as part of their initial investigations. Only 7 patients (50%) had their diaphragmatic injuries identified on the initial CT scan. The re-

**Table 1.** Baseline patient characteristics

Characteristic	Value
No. of patients	14
Sex	
Male	10
Female	4
Age (yr)	49.0 (16–84)
Side	
Left	8 (57)
Right	6 (43)
Mechanism of trauma	
Motor vehicle accident	5
Blunt: mechanical fall	6
Blunt: assault	1
Penetrating	2
Mortality	2 (14)

Values are presented as number, median (range), or number (%).

mainder were diagnosed intraoperatively whilst undergoing internal fixation of rib fractures within the thoracic cavity/wall. The injury was on the left side in 8 patients (57%) and the right side in 6 patients (43%). A description of the associated injuries is given in Table 2.

Due to the nature of the study design all of our patients had rib fractures. Of the patients with a blunt mechanism of injury (n=12), 7 (58%) had a left-sided diaphragmatic injury associated with left-sided rib fractures. In this same sub-group of patients with a blunt mechanism of injury, 8 patients (67%) had rib injuries consistent with a flail pattern on imaging. The average number of ribs fractured was 5.7 across all 14 patients. Rib fractures of the fifth through 10th ribs were more common with diaphragmatic injuries, as shown in the graphical representation of the frequency of each rib fracture in Fig. 1. There was a significant tendency for fractures to be located posterolaterally, as displayed in Fig. 2. It should be noted that each of multiple fractures on an individual rib (at varying locations) were counted separately.

Ten patients underwent operative treatment of the diaphragmatic injury. Of the remaining 4 patients who received non-surgical management (diagnosed with both di-

aphragmatic injuries and chest wall trauma on initial CT scans), 2 died from their injuries (1 patient had severe uncontrollable bleeding from a kidney laceration, and the other patient had a severe traumatic brain injury). The remaining 2 non-surgical patients were managed conservatively; 1 patient had a stab injury and it was felt that the CT-diagnosed diaphragmatic injury was small enough to be managed non-surgically, while the other patient had several co-morbidities with high surgical risk and declined surgical treatment. Attempts were made to follow both of these patients 12 months after discharge, but unfortunately, they were non-responsive.

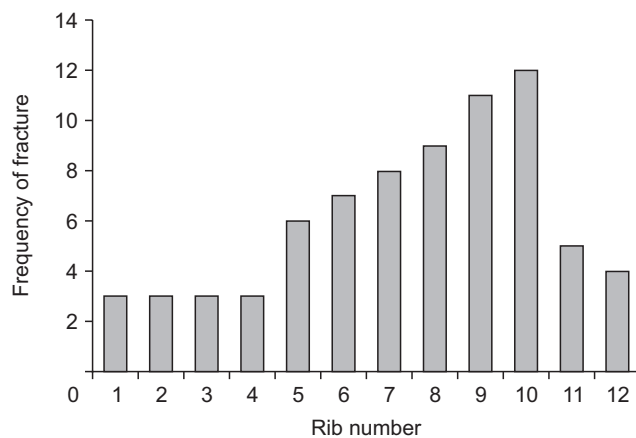
Seven of the 10 patients who underwent surgical treatment for their traumatic injuries had diaphragmatic injuries diagnosed intraoperatively. These patients had initially undergone surgery for rib fixation or washout of a hemothorax.

A video-assisted thoracoscopic surgery (VATS) approach was planned in all patients. However, this approach was used in only 5 patients, all of whom had an intraoperative diagnosis of diaphragmatic injury and subsequently underwent VATS-assisted repair. The other 5 patients went directly to thoracotomy due to instability; 3 patients had a confirmed CT diagnosis of diaphragmatic injury prior to surgery and the remaining 2 patients were diagnosed intraoperatively.

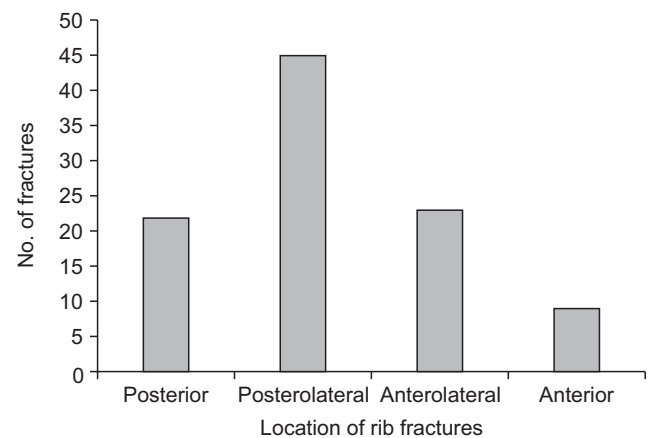
The operative approach was direct closure using non-absorbable stitches in 8 patients. This involved a combination of interrupted and continuous stitches. Two of the patients had an injury that was deemed too large for direct closure and therefore underwent insertion of a prosthetic mesh to ensure tension-free closure of the defect. There were no instances of mortality among the patients who underwent surgery. Morbidities depended significantly on the associ-

**Table 2.** Associated injuries in patients with concomitant chest wall and diaphragmatic injuries

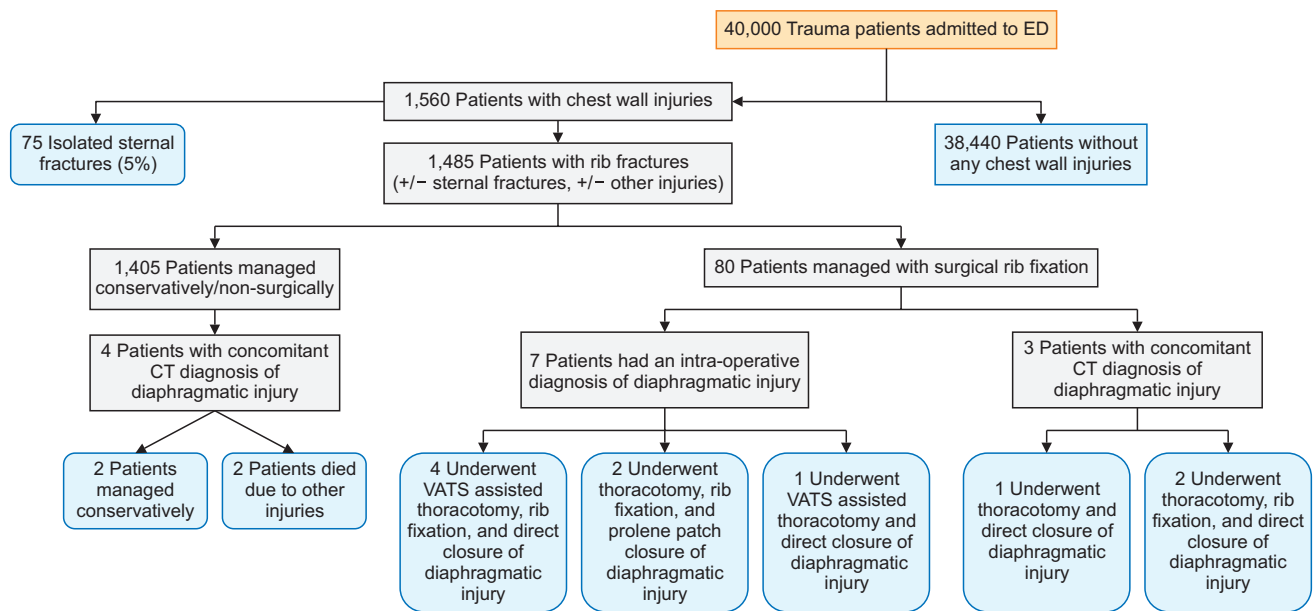
Associated injuries	No. (%)
Splenic rupture	4 (29)
Pelvic fracture	1 (7)
Pulmonary contusion	3 (21)
Liver laceration	3 (21)
Spinal fracture	4 (29)
Kidney laceration	2 (14)



**Fig. 1.** Frequency of individual rib fractures.



**Fig. 2.** Frequency of fracture locations.



**Fig. 3.** Flow chart illustrating the patient pathway. ED, emergency department; CT, computed tomography; VATS, video-assisted thoracoscopic surgery.

ated extra-thoracic injuries sustained during the initial trauma. A flow chart illustrating the pathways of all the patients is shown in Fig. 3. Extra-thoracic injuries were managed by the appropriate non-thoracic surgical team.

## Discussion

TDIs are a rare accompaniment to blunt and penetrating trauma to the torso. The majority of TDIs are caused by blunt abdominal trauma, and most of these injuries typically occur on the posterolateral aspect of the left side of diaphragm [6]. This is thought to be due to a combination of the congenitally weaker left side of the diaphragm and the protection afforded by the liver on the right side. The rate of left-sided TDR is thought to be roughly 70%–80% in blunt trauma [7]. The mechanism of injury is thought to involve an abrupt change in intra-abdominal pressure causing rupture of the diaphragm in the chest cavity. The algorithm for managing patients with TDI has traditionally focused on intra-abdominal injuries and subsequent surgical management via laparotomy. In contrast, our study analyzed a smaller subgroup of patients who had TDI with associated chest wall trauma. Patients without chest wall trauma and TDI were not analyzed in this study.

Interestingly, our study found that the laterality of the TDI in patients with associated chest wall trauma was relatively evenly spread (58% left versus 42% right). This could be explained, in part, by the possibility that the protective

effect of the liver on the right side is negated if we hypothesize that the diaphragmatic injuries are caused directly by the chest wall fractures themselves, rather than solely by an acute increase in intra-abdominal pressure.

Rib fractures are one of the most common injuries, found in almost 20% of all patients with thoracic trauma [8]. They are often associated with a number of other injuries including pulmonary contusion, hemothorax, pneumothorax, and even cardiac injury. Patients with rib fractures often have high morbidity and mortality and there has been an exponential interest worldwide in definitively managing rib fractures via surgery over the last decade. Associated diaphragmatic injuries are rare in patients with thoracic trauma and often suggest a more severe traumatic injury. At our institution there has been a growing interest in the surgical management of rib fractures. Over the last few years, we have established a chest wall injury algorithm for the surgically treatment and management of rib fractures. Routine thoracoscopy is used in all of our cases and over the last few years we have diagnosed and treated several diaphragmatic injuries intraoperatively. As a result, we have retrospectively analyzed TDIs that we have diagnosed and treated in our chest wall injury patients.

The number of rib fractures, their location, and even the degree of their displacement can influence the degree of further intra-thoracic or even intra-abdominal injury. We found that in our overall population of patients with normal chest wall injuries, rib fractures were fairly evenly

spread out over ribs 3–10. However, in the population focused upon in this study (Fig. 1) there was a much greater tendency for fractures to involve the lower ribs, particularly ribs 7–10. Indeed, the average rib fixed in our TDI population was much lower in the chest wall than the overall population of patients with chest wall injuries. Furthermore, as depicted in Fig. 2, the rib fractures tended to be located more posteriorly and laterally than in our general chest wall injury patients. This suggests that the mechanism of diaphragmatic injury in patients with chest wall injuries may be one of penetrating injury to the diaphragm at its weakest point (posterolaterally) rather than an acute and abrupt change in intra-abdominal pressure. It may well be the case that diaphragmatic injuries involve a combination of both processes.

Patients diagnosed with a TDI require urgent surgery due to the high morbidity and mortality associated with such injuries [2]. The true incidence of TDIs is unknown, but data from the literature suggest that TDI is a rare event [3]. The diagnosis of TDI remains elusive for physicians and a high level of suspicion is required to identify this lesion. Patients are often found at both ends of the spectrum of symptoms associated with TDIs, from mild symptoms such as nausea to acute symptoms secondary to visceral obstruction/strangulation. Preoperative diagnostic methods that have reported useful for TDI include plain chest X-rays, ultrasonography, gastrointestinal contrast studies, and CT scans. The most commonly used diagnostic method is CT, and in our cohort all trauma patients underwent a full-body CT scan as per protocol. However, TDIs are notoriously difficult to diagnose on CT, which is only diagnostic in as few as 30% of patients [9]. CT has a reported sensitivity of 61%–87% and a specificity of 72%–100% [10]. Nonetheless, CT is the most useful diagnostic modality in the emergency setting and, in our study, only 50% of the patients with a TDI (and chest wall injuries) were diagnosed on a CT scan. The remaining patients were all diagnosed intraoperatively via a VATS/thoracotomy approach. Most of these patients underwent surgery for either fixation of their ribs or washout of a large hemothorax. The diaphragmatic injury was identified after a systematic inspection of the thoracic cavity using the thoracoscope to adequately visualize the diaphragm in its entirety. Indeed, we were able to diagnose TDI with 100% sensitivity and simultaneously offer repair at the same time using a completely minimally invasive approach in certain cases. This, of course raises the possibility that the true incidence of diaphragmatic injuries is much greater than has been previously described, especially at centers where ribs are not

fixed or where a thoracoscope is not used.

While the optimal surgical approach for rib fixation is still controversial, at our institution we routinely use a VATS-assisted approach in all chest wall injury cases [11]. A VATS approach has the potential to identify injuries to other intra-thoracic structures as well as the diaphragm and also allows us to adequately plan incisions for rib fixation. Furthermore, the increasing use of VATS (for all types of surgery) has included patients who would not otherwise be surgical candidates, thereby potentially extending the indications for TDI surgery. We strongly advocate the use of a thoracoscopic approach/assistance in all trauma cases if available.

Surgical approaches to repairing TDI usually involve either laparotomy or thoracotomy, or sometimes both. Given the nature of our series, all patients underwent a thoracoscopic/thoracotomy approach due to their thoracic injuries. Four patients in our series did not undergo an operative procedure despite a CT diagnosis of diaphragmatic rupture. This was due to the severe nature of the trauma, which affected multiple systems and was not deemed survivable. These patients would likely have required both laparotomy and thoracotomy.

There is no doubt regarding the necessity of a surgical repair in TDI, although controversy still exists regarding the best surgical approach and repair technique. The cavity that is entered depends on the nature of the trauma and the presence of an intra-abdominal or intra-thoracic injury, laterality, and the surgeon's own experience. In our series, of the 10 patients upon whom we operated, 7 had an intraoperative diagnosis of TDI after careful inspection. Only 3 of the patients upon whom we operated had a pre-operative diagnosis of TDI, highlighting the occult nature of this injury and the need for a high degree of suspicion. Furthermore, we found that the use of a VATS approach significantly helped us not only to identify the injury, but also to repair it through a minimally invasive approach in some cases. The operative steps consist of hernia reduction (if any), repair of any visceral structures (if any), and closure of the diaphragmatic defect. Several repair techniques have been described in the literature and there seems to be a consensus that a non-absorbable suture should be used to approximate the defect (if possible) [5]. We used non-absorbable sutures in all our defect closures using a combination of interrupted and continuous sutures. Where defects were large, we used a Prolene mesh to repair the defect. To our knowledge, there was no recurrence after our repairs during the study period.

In conclusion, our series of patients re-iterates the occult



nature of diaphragmatic injuries in trauma patients and the diagnostic difficulties in identifying the condition. In addition, it also demonstrates a clear relationship between significant rib fractures and diaphragmatic injuries. As a major trauma center, our institution sees a disproportionately high number of blunt trauma patients, especially patients with thoracic injuries. We noted that a significant proportion of our patients were diagnosed intraoperatively using the assistance of a thoracoscope rather than pre-operative imaging. This suggests that the true incidence of TDI is much greater than we thought, particularly in patients with thoracic trauma. We also observed that the location of the rib fractures and the pattern of injury in patients with TDI were lower and posterolateral in the chest wall than in our general chest wall injury population, without a trend for laterality. This has the potential to change the traditional concept of TDIs as involving an intra-abdominal mechanism of injury secondary to abrupt pressure changes to one of a penetrating diaphragmatic injury secondary to a fractured rib. We strongly recommend the use of a thoracoscope in patients undergoing chest wall surgery, as it not only facilitates the diagnosis of diaphragmatic injuries, but also has the potential for thoracoscopic repair of the injury.

## Conflict of interest

No potential conflict of interest relevant to this article was reported.

## ORCID

Azhar Hussain: <https://orcid.org/0000-0003-3941-4553>

Ian Hunt: <https://orcid.org/0000-0001-6672-291X>

## References

1. Panda A, Kumar A, Gamanagatti S, Patil A, Kumar S, Gupta A. *Traumatic diaphragmatic injury: a review of CT signs and the difference between blunt and penetrating injury*. *Diagn Interv Radiol* 2014;20:121-8.
2. Mihos P, Potaris K, Gakidis J, et al. *Traumatic rupture of the diaphragm: experience with 65 patients*. *Injury* 2003;34:169-72.
3. Rubikas R. *Diaphragmatic injuries*. *Eur J Cardiothorac Surg* 2001; 20:53-7.
4. Ties JS, Peschman JR, Moreno A, et al. *Evolution in the management of traumatic diaphragmatic injuries: a multicenter review*. *J Trauma Acute Care Surg* 2014;76:1024-8.
5. Hofmann S, Kornmann M, Henne-Bruns D, Formentini A. *Traumatic diaphragmatic ruptures: clinical presentation, diagnosis and surgical approach in adults*. *GMS Interdiscip Plast Reconstr Surg DGPW* 2012;1:Doc02.
6. Lim KH, Park J. *Blunt traumatic diaphragmatic rupture: single-center experience with 38 patients*. *Medicine (Baltimore)* 2018;97: e12849.
7. Zarour AM, El-Menyar A, Al-Thani H, Scalea TM, Chiu WC. *Presentations and outcomes in patients with traumatic diaphragmatic injury: a 15-year experience*. *J Trauma Acute Care Surg* 2013;74:1392-8.
8. De Moya M, Nirula R, Biffl W. *Rib fixation: who, what, when?* *Trauma Surg Acute Care Open* 2017;2:e000059.
9. Larici AR, Gotway MB, Litt HI, et al. *Helical CT with sagittal and coronal reconstructions: accuracy for detection of diaphragmatic injury*. *AJR Am J Roentgenol* 2002;179:451-7.
10. Bodanapally UK, Shanmuganathan K, Mirvis SE, et al. *MDCT diagnosis of penetrating diaphragm injury*. *Eur Radiol* 2009;19:1875-81.
11. Fraser SF, Tan C, Kuppusamy MK, Gukop P, Hunt IJ. *The role of a video-assisted thoracic approach for rib fixation*. *Eur J Trauma Emerg Surg* 2017;43:185-90.