

Original Article



Intraperitoneal Paclitaxel Combined with S-1 Plus Oxaliplatin for Advanced Gastric Cancer with Peritoneal Metastasis: a Phase I Study

Dong-Wook Kim ^{1,*}, Won Jun Seo ^{2,*}, Sang Il Youn ¹, Ye Seob Jee ¹,
You-Jin Jang ², Jong-Han Kim ², Perioperative Intra-Peritoneal & Systemic
Chemotherapy for Gastric Cancer (PIPS-GC) study group

¹Department of Surgery, Dankook University College of Medicine, Cheonan, Korea

²Division of Foregut Surgery, Department of Surgery, Korea University College of Medicine, Seoul, Korea

OPEN ACCESS

Received: Sep 9, 2021

Revised: Dec 17, 2021

Accepted: Dec 17, 2021

Correspondence to

Jong-Han Kim

Division of Foregut Surgery, Department of Surgery, Korea University College of Medicine, 148 Gurodong-ro, Guro-gu, Seoul 08308, Korea.

E-mail: ppongttai@gmail.com

*Dong-Wook Kim and Won Jun Seo contributed equally to this work.

Copyright © 2021. Korean Gastric Cancer Association

This is an Open Access article distributed under the terms of the Creative Commons Attribution Non-Commercial License (<https://creativecommons.org/licenses/by-nc/4.0>) which permits unrestricted noncommercial use, distribution, and reproduction in any medium, provided the original work is properly cited.

ORCID iDs

Dong-Wook Kim

<https://orcid.org/0000-0002-3552-5988>

Won Jun Seo

<https://orcid.org/0000-0003-3447-7790>

Sang Il Youn

<https://orcid.org/0000-0002-4029-8572>

Ye Seob Jee

<https://orcid.org/0000-0003-3280-6351>

You-Jin Jang

<https://orcid.org/0000-0002-3216-0282>

Jong-Han Kim

<https://orcid.org/0000-0002-3862-8501>

ABSTRACT

Purpose: We designed a new regimen by combining intraperitoneal (IP) paclitaxel (PTX) with systemic S-1 plus oxaliplatin (SOX) for the treatment of advanced gastric cancer with peritoneal metastasis. This dose-escalation study aimed to determine the maximum tolerated dose (MTD) and recommended dose (RD) of IP PTX administered weekly to patients.

Materials and Methods: Eight cycles of IP PTX plus SOX regimen were administered to the patients. S-1 was administered orally twice daily at a dose of 80 mg/m²/day for 14 consecutive days, followed by 7 days of rest. Intravenous oxaliplatin was administered at a fixed dose of 100 mg/m² on day 1, while IP PTX was administered on days 1 and 8. The initial dose of IP PTX was 40 mg/m², and the dose escalation was set in units of 20 mg/m² up to 80 mg/m². Dose-limiting toxicities (DLTs) were defined as grade 3 non-hematologic toxicities, grade 4 leukopenia, grade 3 febrile neutropenia, and grade 3 thrombocytopenia.

Results: Nine patients were included in the study. No DLTs were observed in any of the enrolled patients. Therefore, the MTD was not reached, and the RD of IP PTX was determined to be 80 mg/m². Four patients (44%) showed a decreased peritoneal cancer index score on second-look laparoscopic examination.

Conclusions: The present study determined the dose for further clinical trials of IP PTX to be 80 mg/m², when combined with a systemic SOX regimen.

Keywords: Stomach neoplasm; Peritoneal neoplasm; Injections, Intraperitoneal; Clinical trial, phase I

INTRODUCTION

Peritoneal metastasis (PM) is categorized as stage IV disease, which is the most frequent type of metastasis and recurrence in patients with advanced gastric cancer (AGC) [1]. Palliative systemic chemotherapy is the gold standard treatment for this devastating disease. However, the prognosis of AGC with PM remains extremely poor [2-5]. Recently, clinical studies on intraperitoneal (IP) administration of chemotherapeutic agents have been conducted to improve the prognosis of AGC with PM [6-8]. IP chemotherapy could be a promising treatment option for patients with PM, allowing direct administration of anticancer drugs into the peritoneal space.

Author Contributions

Conceptualization: K.J.H., J.Y.S.; Data curation: K.D.W., S.W.J., Y.S.I.; Formal analysis: K.D.W., S.W.J., Y.S.I., J.Y.J.; Funding acquisition: K.J.H., J.Y.S.; Investigation: S.W.J., J.Y.J., J.Y.S., K.J.H.; Methodology: K.D.W., S.W.J., Y.S.I., J.Y.J.; Project administration: J.Y.J., J.Y.S., K.J.H.; Resources: J.Y.J., J.Y.S., K.J.H.; Software: K.D.W., S.W.J., Y.S.I.; Supervision: J.Y.J., J.Y.S., K.J.H.; Validation: J.Y.S., K.J.H.; Visualization: S.W.J.; Writing - original draft: K.D.W., S.W.J.; Writing - review & editing: K.D.W., S.W.J.

Conflict of Interest

The drugs used for this clinical trial were provided by multiple companies. Paclitaxel was provided by Shinpoong Pharm. Co., Ltd., S-1 was provided by Myungmoon Pharm. Co., Ltd., and oxaliplatin was supplied by Chong Kun Dang Pharm. Co.

Previous studies have shown the safety of IP administration of paclitaxel (PTX) with systemic chemotherapy for AGC with PM [7,9,10]. However, the dosage of IP PTX differed according to the particular study design, and the minimum dose of IP PTX failed to show efficacy when compared with systemic chemotherapy [7]. Efficacy evaluation of IP PTX is usually represented by survival, which is the most important factor for cancer patients. However, we have no information on the effect of IP PTX on disease regression, in relation to the limited quantitative characteristics of PM by the imaging modality [11].

To overcome the limitations of previous studies, the perioperative IP and systemic chemotherapy for gastric cancer (PIPS-GC) study group was established in 2017 to manage AGC with PM in Korea. A multicenter retrospective study on IP chemotherapy has been performed, which showed satisfactory results [12]. Based on these results, we planned to conduct a phase I/II clinical trial. We designed a new regimen by combining IP PTX with systemic S-1 plus oxaliplatin (SOX), which is regarded as one of the standard first-line treatments for metastatic gastric cancer [13,14]. This dose-escalation study aimed to determine the maximum tolerated dose (MTD) and recommended dose (RD) of IP PTX administered weekly.

MATERIALS AND METHODS

Objectives and study design

A multicenter, non-randomized, open-label, dose-escalation phase I study (KCT0004670) of IP PTX was performed in AGC patients with PM between June 2020 and December 2020. IP PTX was administered in combination with systemic SOX.

The primary endpoint of this study was to determine the MTD and RD of the IP PTX. The secondary endpoints included tumor response, toxicity profile of chemotherapeutic agents, and IP port-related or catheter-related complications.

Eligibility criteria

Patients with histologically confirmed unresectable or recurrent gastric adenocarcinoma, whose PM was diagnosed by laparoscopic examination or diagnostic imaging, had an Eastern Cooperative Oncology Group performance status of 0–1, aged 20–80 years, and who had adequate bone marrow, liver, and renal function were eligible for the study. Patients with concomitant primary malignancy, human epidermal growth factor receptor 2 overexpression, uncontrolled gastrointestinal bleeding, or obstruction were excluded. Pregnant or lactating women and patients with severe systemic disease, overt infection, or inflammation were also excluded.

This study was approved by the institutional review board of each institution (approval number: 2019GR0459 at the institution of the principal investigator) and the Korea Ministry of Food and Drug Safety (2019132469). Written informed consent was obtained from all the participants prior to study commencement.

Treatment

All eligible patients underwent diagnostic laparoscopy or laparotomy to confirm and evaluate the extent of PM. The extent of PM was measured using the peritoneal cancer index (PCI) [15]. A specialized peritoneal implantable device with an IP catheter and a port (BardPort™; Bard Access Systems Inc., Salt Lake City, MA, USA) was used for IP PTX administration. The

catheter tip was placed in the pelvic cavity; however, owing to its multipunctured structure, as in the Tenkhoff catheter, which is usually used for peritoneal dialysis, the drug could be effectively delivered throughout the peritoneal cavity without obstruction. The main body of the port was implanted in the right lower costal suprafascial area. Multiple anchoring sutures with fascia and ports can prevent complications associated with port overturning. The catheter was connected to the port through a distance of 5–10 cm of subcutaneous tunnelling to avoid drug or ascites overflow to the port implantation site. The IP port was removed during post-chemotherapeutic exploratory laparotomy.

Eight cycles of the IP PTX plus SOX regimen were planned (**Fig. 1**). S-1 was administered orally twice a day at a dose of 80 mg/m²/day for 14 consecutive days, followed by 7 days of rest. Intravenous oxaliplatin was administered at a dose of 100 mg/m² on day 1, and IP PTX was infused on days 1 and 8. The initial dose of IP PTX was 40 mg/m², and dose escalation was set in units of 20 mg/m² up to 80 mg/m². PTX was diluted in 500 mL of normal saline and infused for 60 minutes. IP PTX was not drained after administration of the drug; thus, IP PTX could be maintained in the peritoneal cavity for more than 24 hours [16]. The traditional 3+3 dose escalation model was used to determine the MTD and RD of IP PTX, and MTD was determined based on the dose-limiting toxicity (DLT) in the first cycle. A minimum of three patients were treated at each dose level if none of the patients experienced DLTs.

Tumor response and toxicity

Laboratory examinations, chest radiography, and echocardiography were performed on the patient's subjective symptoms after every cycle. Computed tomography was performed after every 4th cycle. A second-look operation was performed to assess the tumor response after completion of the 8th cycle of treatment, if need be. Adverse events were graded and reported according to the National Cancer Institute's Common Terminology Criteria for Adverse Events (version 4.03) during the 1st cycle of chemotherapy to determine DLT. DLTs were defined as grade 3 or higher non-hematologic toxicities, grade 4 or higher leukopenia, grade 3 or higher neutropenia, and grade 3 or higher thrombocytopenia. IP catheter- or port-related complications were recorded separately. Objective tumor responses were evaluated according to the Response Evaluation Criteria in Solid Tumors version 1.1 [17]. However, since peritoneal carcinomatosis is usually unmeasurable through imaging modalities, we planned to compare the interval change of the PCI and the Japanese classification system for peritoneal carcinomatosis between pre- and post-chemotherapeutic exploratory laparotomy, especially for patients with no measurable disease on radiologic evaluation.

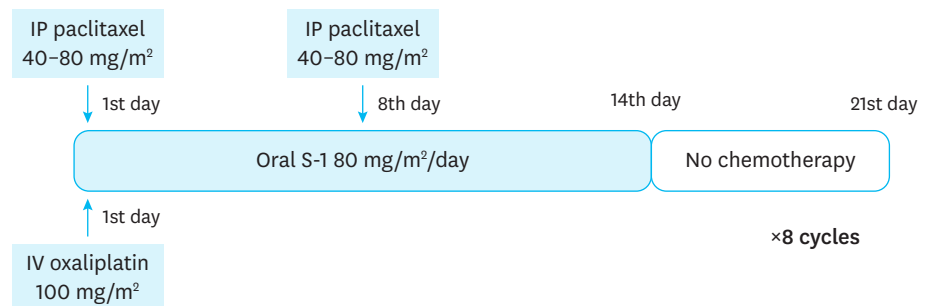


Fig. 1. Chemotherapy schedule of PIPS-GC phase I trial.

PIPS-GC = Perioperative Intraperitoneal and Systemic Chemotherapy for Gastric Cancer; IP = intraperitoneal; IV = intravenous.

RESULTS

Nine eligible patients were recruited at the Korea University Guro Hospital and Dankook University Hospital in Korea. The baseline characteristics of the patients (five men and four women) are shown in **Table 1**. The median age was 61 years (range, 42–76 years). Synchronous PM and metachronous PM were identified in six (66.7%) and three (33.3%) patients, respectively. The median PCI grade was 21 (range, 7–39).

The toxicity profiles reported during the 1st cycle of the protocol are listed in **Table 2**. None of the three patients developed DLTs after receiving a Level 1 dose. A level 2 dose of 60 mg/m² of IP PTX was subsequently administered to the other three patients. At this level, the patients developed grade I leukopenia and grade I–II anemia with grade I–II non-hematological toxicity. Among these non-hematologic toxicities, the first patient experienced grade I abdominal pain with grade I anorexia, the second patient experienced grade II constipation, and the third patient experienced grade I anorexia and grade I peripheral neuropathy. No surgical complications or technical problems associated with IP administration were observed.

The targeted maximum dose of IP PTX (80 mg/m²) was administered to the final three patients. The patients did not experience hematological adverse events. However, they were treated for grade I abdominal pain, nausea, or grade II vomiting. Finally, none of the enrolled patients developed DLTs. Hence, the MTD was not reached, and the RD of IP PTX was determined to be 80 mg/m² (level 3). All patients received eight cycles of IP PTX with a systemic SOX regimen, as per the study protocol. Median treatment duration was 5.5 months (range, 5.4–6.1).

Four patients (44%) showed disappearance or shrinkage of the PM (decreasing PCI score) on second-look laparoscopic examination (**Table 3**). All four patients in the partial response

Table 1. Patients' demographic data and baseline characteristics (n=9)

Characteristics	Values
Median age, yr (range)	61 (42–76)
Sex	
Male	5
Female	4
ECOG performance status	
0	9
1	0
Disease presentation	
Synchronous	6
Metachronous	3
Histological subtypes	
Differentiated	2
Undifferentiated	7
Lauren classification (synchronous)	
Intestinal	1
Diffuse	3
Mixed	2
PCI grade, median (range)	21 (7–39)
Combined distant metastasis	
Distant lymph node	4
Liver	1
Ovary	1
Other organs	2

ECOG = Eastern Cooperative Oncology Group; PCI = peritoneal cancer index.

Intraperitoneal Chemotherapy for Gastric Cancer

Table 2. Toxicity profile

Grade (CTCAE version 4.03)	Dose level 1 (n=3) IP PTX 40 mg/m ²			Dose level 2 (n=3) IP PTX 60 mg/m ²			Dose level 3 (n=3) IP PTX 80 mg/m ²		
	1	2	3	1	2	3	1	2	3
Hematological toxicity									
Leukopenia				2					
Neutropenia									
Anemia				2	1				
Thrombocytopenia									
Non-hematological toxicity									
Abdominal pain				1			1		
Nausea	1						1		
Vomiting	2							1	
Fatigue	1								
Anorexia				2					
Sensory neuropathy				1					
Diarrhea						1			
Constipation	1					1			
Hand foot syndrome	1								

CTCAE = National Cancer Institute Common Terminology Criteria for Adverse Events; IP = intraperitoneal; PTX = paclitaxel.

Table 3. Tumor response

No.	Sex	Age	Dose of IP PTX (mg/m ²)	Disease presentation	Pre-chemotherapy PCI score	Post-chemotherapy PCI score
1	F	76	40	Synchronous	28	8
2	F	72	40	Synchronous	39	11
3	F	60	40	Synchronous	21	19
4	M	74	60	Metachronous	7	Not-checked
5	M	61	60	Metachronous	39	Not-checked
6	M	51	60	Metachronous	39	Not-checked
7	M	63	80	Synchronous	11	6
8	F	42	80	Synchronous	21	0
9	M	58	80	Synchronous	11	16

IP = intraperitoneal; PTX = paclitaxel; PCI = peritoneal cancer index; F = female; M = male.

group showed decreased PCI scores, distant lymph node metastasis, or liver metastasis. One patient with synchronous PM showed a decreased PCI score, but no size change in the main tumor in the stomach. Another synchronous cancer patient showed an increased PCI score and a stable main tumor. Three patients had metachronous peritoneal carcinomatosis, and none of the patients underwent post-chemotherapy exploratory laparotomy. Two of these patients showed no change in the small amount of ascites and were accordingly classified as having stable disease, while the third patient showed an increased amount of ascites.

DISCUSSION

This study demonstrated that IP PTX at a dose of 80 mg/m² could be safely combined with standard systemic SOX chemotherapy for AGC patients with PM. No DLTs occurred after administration of the level III dose of IP PTX. Abdominal pain, which could be observed after IP retention of anticancer drugs, occurred in only two patients with grade I toxicity. Hematological adverse events were also tolerable (**Table 2**).

This PIPS-GC clinical trial had several unique characteristics compared with those of previous studies. First, we designed an IP PTX dosage escalation to control PM without increasing systemic toxicity. Previous studies used different dosages of IP PTX, and the minimum dose failed to show a survival benefit over systemic chemotherapy [7,9,10]. This study was planned to start at a higher dose than the previously published minimum dose

(20 mg/m²) and up to the maximum dose (80 mg/m²). Post-chemotherapeutic exploratory laparotomy is another distinctive aspect of this study. Peritoneal carcinomatosis cannot be properly evaluated using imaging modalities [11]. By comparing the PCI score directly with exploratory laparotomy, we determined the effect of IP PTX with a systemic SOX regimen on PM from gastric cancer.

We previously reported significant complications associated with an implanted access port and catheter system (18.3%) in a multicenter retrospective study [12]. Among these complications, abscess and infection can be fatal. However, neither IP port- nor catheter-related complications were observed in this study. Although the follow-up period was short with a limited number of patients, the fact that no complications were observed could be attributed to several reasons. First, we implanted a specially designed chemoport for peritoneal chemotherapy. This product (BardPort™; Bard Access Systems Inc.) was a 14.3 French, open-ended catheter that prevented inflow obstruction with a relatively large diameter. Second, regular workshops were held within this study group to reduce the rate of IP port- and catheter-related complications. To determine the best technical method, we discussed the cases of patients with complications and conducted a debate to prevent technical failures, such as malposition.

In this study, four out of nine patients (44.4%) showed decreased PCI scores (**Table 3**). The median PCI score (range) of these patients dramatically decreased from 20 (11–28) to 8 (0–19) after administration of the IP PTX plus SOX regimen. Among the three patients with stable disease, one showed a reduction in the PCI score (from 39 to 11), but a stable primary lesion in the stomach. Despite the short follow-up period and without survival results, we could see the changes in PM by comparing pre- and post-chemotherapy exploratory laparotomy.

There are several limitations to this study that must be considered. First, distant metastases, which could be confounding factors, were accompanied by PM in most of the enrolled patients. However, we designed this IP approach combined with systemic chemotherapy to control the systemic disease status of the patient to reflect real-world situations, as approximately 20% of patients with PM show combined distant metastasis [18]. Second, only two institutions participated in the study. To the best of our knowledge, this is the first report of a multi-institutional prospective clinical trial of IP chemotherapy. We ensured that the initial phase I trial would be at a central, experienced institution to ensure the safety of the trial. The participation of various institutions is planned for future phase II–III studies.

In conclusion, our phase I study determined the RD for further clinical trials of IP PTX to be 80 mg/m², when combined with SOX systemic chemotherapy. Further phase II and III clinical studies are warranted to confirm the feasibility and efficacy of this regimen.

ACKNOWLEDGMENTS

We especially appreciate the enthusiasm and dedication of the PIPS-GC study group.

REFERENCES

1. Lee JH, Son SY, Lee CM, Ahn SH, Park DJ, Kim HH. Factors predicting peritoneal recurrence in advanced gastric cancer: implication for adjuvant intraperitoneal chemotherapy. *Gastric Cancer* 2014;17:529-536.
[PUBMED](#) | [CROSSREF](#)
2. Koizumi W, Narahara H, Hara T, Takagane A, Akiya T, Takagi M, et al. S-1 plus cisplatin versus S-1 alone for first-line treatment of advanced gastric cancer (SPIRITS trial): a phase III trial. *Lancet Oncol* 2008;9:215-221.
[PUBMED](#) | [CROSSREF](#)
3. Kang YK, Kang WK, Shin DB, Chen J, Xiong J, Wang J, et al. Capecitabine/cisplatin versus 5-fluorouracil/cisplatin as first-line therapy in patients with advanced gastric cancer: a randomised phase III noninferiority trial. *Ann Oncol* 2009;20:666-673.
[PUBMED](#) | [CROSSREF](#)
4. Wilke H, Muro K, Van Cutsem E, Oh SC, Bodoky G, Shimada Y, et al. Ramucirumab plus paclitaxel versus placebo plus paclitaxel in patients with previously treated advanced gastric or gastro-oesophageal junction adenocarcinoma (RAINBOW): a double-blind, randomised phase 3 trial. *Lancet Oncol* 2014;15:1224-1235.
[PUBMED](#) | [CROSSREF](#)
5. Bang YJ, Van Cutsem E, Feyereislova A, Chung HC, Shen L, Sawaki A, et al. Trastuzumab in combination with chemotherapy versus chemotherapy alone for treatment of HER2-positive advanced gastric or gastro-oesophageal junction cancer (ToGA): a phase 3, open-label, randomised controlled trial. *Lancet* 2010;376:687-697.
[PUBMED](#) | [CROSSREF](#)
6. Kobayashi D, Koderu Y. Intraperitoneal chemotherapy for gastric cancer with peritoneal metastasis. *Gastric Cancer* 2017;20:111-121.
[PUBMED](#) | [CROSSREF](#)
7. Ishigami H, Fujiwara Y, Fukushima R, Nashimoto A, Yabusaki H, Imano M, et al. Phase III trial comparing intraperitoneal and intravenous paclitaxel plus S-1 versus cisplatin plus S-1 in patients with gastric cancer with peritoneal metastasis: PHOENIXGC trial. *J Clin Oncol* 2018;36:1922-1929.
[PUBMED](#) | [CROSSREF](#)
8. Chia DKA, So JBY. Recent advances in intra-peritoneal chemotherapy for gastric cancer. *J Gastric Cancer* 2020;20:115-126.
[PUBMED](#) | [CROSSREF](#)
9. Takahashi N, Kanda M, Yoshikawa T, Takiguchi N, Fujitani K, Miyamoto K, et al. A randomized phase II multicenter trial to explore efficacy of weekly intraperitoneal in comparison with intravenous paclitaxel administered immediately after gastrectomy to the patients with high risk of peritoneal recurrence: final results of the INPACT trial. *Gastric Cancer* 2018;21:1014-1023.
[PUBMED](#) | [CROSSREF](#)
10. Imano M, Imamoto H, Itoh T, Satou T, Peng YF, Yasuda A, et al. Safety of intraperitoneal administration of paclitaxel after gastrectomy with en-bloc D2 lymph node dissection. *J Surg Oncol* 2012;105:43-47.
[PUBMED](#) | [CROSSREF](#)
11. Esquivel J, Chua TC, Stojadinovic A, Melero JT, Levine EA, Gutman M, et al. Accuracy and clinical relevance of computed tomography scan interpretation of peritoneal cancer index in colorectal cancer peritoneal carcinomatosis: a multi-institutional study. *J Surg Oncol* 2010;102:565-570.
[PUBMED](#) | [CROSSREF](#)
12. Kim DW, Jee YS, Kim CH, Kim JJ, Park S, Choi SI, et al. Multicenter retrospective analysis of intraperitoneal paclitaxel and systemic chemotherapy for advanced gastric cancer with peritoneal metastasis. *J Gastric Cancer* 2020;20:50-59.
[PUBMED](#) | [CROSSREF](#)
13. Guideline Committee of the Korean Gastric Cancer Association (KGCA), Development Working Group & Review Panel. Korean Practice Guideline for Gastric Cancer 2018: an evidence-based, multi-disciplinary approach. *J Gastric Cancer* 2019;19:1-48.
[PUBMED](#) | [CROSSREF](#)
14. Japanese Gastric Cancer Association. Japanese gastric cancer treatment guidelines 2018 (5th edition). *Gastric Cancer* 2021;24:1-21.
15. Jacquet P, Sugarbaker PH. Clinical research methodologies in diagnosis and staging of patients with peritoneal carcinomatosis. *Cancer Treat Res* 1996;82:359-374.
[PUBMED](#) | [CROSSREF](#)
16. Mohamed F, Sugarbaker PH. Intraperitoneal taxanes. *Surg Oncol Clin N Am* 2003;12:825-833.
[PUBMED](#) | [CROSSREF](#)

17. Therasse P, Arbuck SG, Eisenhauer EA, Wanders J, Kaplan RS, Rubinstein L, et al. New guidelines to evaluate the response to treatment in solid tumors. European Organization for Research and Treatment of Cancer, National Cancer Institute of the United States, National Cancer Institute of Canada. *J Natl Cancer Inst* 2000;92:205-216.
[PUBMED](#) | [CROSSREF](#)
18. Tan HL, Chia CS, Tan GH, Choo SP, Tai DW, Chua CW, et al. Gastric peritoneal carcinomatosis - a retrospective review. *World J Gastrointest Oncol* 2017;9:121-128.
[PUBMED](#) | [CROSSREF](#)