

# Combination of Stades Forced Granulation Method and Hotz-Celsus Procedure for Treatment of Upper and Lower Eyelid Entropion-Trichiasis in Three Dogs

Youngsam Kim<sup>\*,\*\*</sup>, Seonmi Kang<sup>\*\*</sup> and Kangmoon Seo<sup>\*\*1</sup>

*\*Dana Animal Hospital Eye Center, Seoul 07014, Korea*

*\*\*Department of Veterinary Clinical Sciences, College of Veterinary Medicine and Research Institute for Veterinary Science, Seoul National University, Seoul 08826, Korea*

(Received: September 14, 2020 / Accepted: October 07, 2020)

**Abstract :** Three dogs (a 30-month-old spayed female English bulldog; a 12-month-old castrated male English bulldog; a 19-month-old castrated male Shar-pei dog) were presented to the Dana Animal Hospital Eye Center with clinical signs of blepharospasm, epiphora, and ocular discharge (serous to mucopurulent) in one or both eyes. Through ophthalmic examination, the dogs (5 eyes) were diagnosed with trichiasis caused by upper and lower eyelid entropion, including the lateral canthus. To correct upper and lower eyelid entropion, modification using a combination of the Stades forced granulation method for upper eyelid entropion and Hotz-Celsus procedure for lower eyelid entropion was performed in all cases. At the last follow-up, mean 274 days after surgery, clinical signs disappeared and no recurrences of entropion were observed in any of the 3 dogs (5 eyes). Therefore, the combination of the Stades forced granulation method and Hotz-Celsus procedure may be an effective treatment for trichiasis caused by upper and lower eyelid entropion in dogs.

**Key words :** dog, entropion, Hotz-Celsus, stades forced granulation, trichiasis.

## Introduction

Entropion in dogs is a common eyelid disorder in which the eyelid margin rolls inward toward the corneal surface and causes trichiasis irritating the cornea (2,9,12). Entropion is classified into primary (conformational or congenital) and secondary (spastic or cicatricial) entropion (9,12). Conformational entropion rarely occurs at birth, but redundant skin folds of the forehead, a deep-set eyeball that does not support the eyelid, a change in the tensional direction of the lateral canthal ligament in a mesaticephalic breed with a wide head, or blepharospasm due to conjunctivitis or distichiasis are known as predisposing factors (9). Entropion occurs in various breeds, and causes symptoms, including blepharospasm, excessive lacrimation, conjunctival hyperemia, ocular discharge, corneal ulcer, corneal pigmentation, neovascularization, periocular alopecia, and moist, discolored lid margins caused by tear contact (2,6,9,12).

Various surgical treatments, such as temporary tacking suture, subdermal hyaluronic acid filler injection, wedge resection, Hotz-Celsus procedure, lateral arrowhead procedure, Y-V procedure, and medial canthoplasty are performed depending on the species, degree of maturity of the facial skin according to the age, severity, extent, and site of entropion (2,4,8,9). However, ptosis, in which the frontal redundant

skin presses down the upper eyelid, preventing the eyelid from lifting normally, occurs with entropion in breeds such as English bulldog, Shar-pei, and Chow Chow (9). In this situation, the entropion is not fully corrected by any single method, and recurrence of entropion is frequently observed (9). Therefore, to solve this problem, the Stades forced granulation method, stellate or coronal rhytidectomy, and Mersilene sling technique have been applied in veterinary ophthalmology (1,5,7,9,11,14).

In this case report, a modification using a combination of the Stades forced granulation method for the correction of upper eyelid entropion and Hotz-Celsus procedure for lower eyelid entropion (1,2,4) was performed in three dogs (5 eyes).

The purpose of this study is to describe the combination of the two methods for treatment of upper and lower eyelid entropion in three dogs and to discuss the effectiveness of this modification.

## Case Reports

Three dogs were presented to the Dana Animal Hospital Eye Center with ophthalmic signs including blepharospasm, epiphora, and mucoid to purulent ocular discharge. Ophthalmic examinations, including slit-lamp biomicroscopy (SL-D7, Topcon Corp, Tokyo, Japan), intraocular pressure (IOP) measured using a Tonovet<sup>®</sup> tonometer (Icare Finland Oy; Vantaa, Finland), tear production (Schirmer tear test<sup>®</sup>, Merck; NJ, USA), and fluorescein dye test (Fluorescein sodium<sup>®</sup>,

<sup>1</sup>Corresponding author.  
E-mail : kmseo@snu.ac.kr

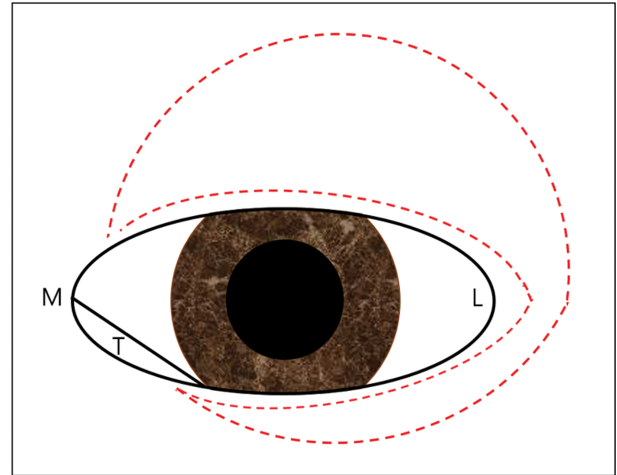
**Table 1.** Summary of signalment, affected eye, clinical signs at examination, and follow-up time for 3 dogs

	Breed	Sex	Age (months)	Affected eye	Clinical signs		Follow-up time (days)
					OD	OS	
Case 1	EB	SF	30	OU	B, E, D	B, E, D, U, NV	240
Case 2	EB	CM	12	OS		B, E, D, U	405
Case 3	SP	CM	19	OU	B, E, D	B, E, D, U, NV	179

EB, English bulldog; SP, Shar-pei; SF, spayed female; CM, castrated male; OS, left eye; OU, both eye; B, blepharospasm; E, epiphora; D, ocular discharge; U, corneal ulcer; NV, corneal neovascularization.

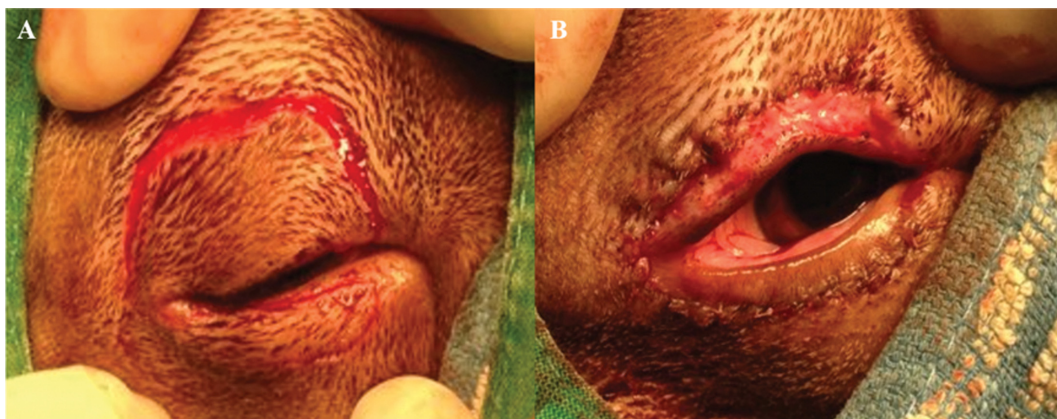
Optitech Eyecare; Allahabad, India) were performed. IOP and tear production were within normal range in all dogs and FDT was positive in 3 eyes, as shown in Table 1. The dogs were diagnosed with upper and lower eyelid entropion, including the lateral canthus, causing trichiasis. We decided to perform a combination of the Stades forced granulation method with the Hotz-Celsus technique at the same time in consideration of the entropion site and the breeds involved.

The dogs were premedicated with atropine 0.02 mg/kg SC (Atropine<sup>®</sup>, Daewon Pharm, Korea), acepromazine 0.2 mg/kg SC (Sedaject<sup>®</sup>, Samu median, Korea), tramadol 2 mg/kg SC (Tramadol<sup>®</sup>, Bukwang Pharm, Korea), cefazolin 20 mg/kg SC (Cefazolin<sup>®</sup>, Chongkundang, Korea), and meloxicam 0.2 mg/kg SC (Metacam<sup>®</sup>, Boehringer Ingelheim, Spain). After induction using 5 mg/kg ketamine IV (Ketamine<sup>®</sup>, Huons, Korea), general anesthesia was maintained with isoflurane (Ifran<sup>®</sup>, Hana Pharm, Korea) inhalation and oxygen. To correct the entropion of the upper eyelid, the Stades forced granulation method was used (Fig 1). With the eyelid lifted using a Jaeger lid plate, the first surgical incision was made with No.15 surgical blade was made, starting 2-3 mm lateral to the medial canthus of the upper eyelid, parallel to a distance of 0.5-1 mm from the meibomian gland orifice to 5 mm lateral to the lateral canthus (4). The second incision was performed at a distance of 20-25 mm dorsally from the first incision line, parallel to the dorsal orbital rim, and an additional incision was made to a distance of 3-5 mm temporally from the end of the lateral canthus of the first incision line (4). Then then, to correct the entropion of the lower eyelid using



**Fig 1.** Schematic diagram explaining the incision line (red dotted line) for the combination of Stades forced granulation method and Hotz-Celsus procedure in this report (M, Medial canthus; L, Lateral canthus; T, Leading edge of third eyelid).

the Hotz-Celsus procedure, an additional incision was made 1-2 mm further than the actual entropion lesion from the lateral canthus to the medial canthus, parallel to a distance of 1-2 mm from the lower eyelid margin, and the second incision was made 3-6 mm ventrally from the first incision line (Fig 1, Fig 2A). After all skin incisions were made, the skin strip and the orbicularis oculi muscle were resected and removed with Steven's curved tenotomy scissors. The dorsal skin



**Fig 2.** Photographs of Case 3 undergoing entropion correction of the upper and lower eyelid by the combination of Stades forced granulation method and Hotz-Celsus procedure. (A) Skin incisions were made as shown in Fig 1. (B) After removing the incised skin with Stevens curved tenotomy scissors, the dorsal skin margin was sutured to subcutaneous layers of upper eyelid 5-6 mm apart from the eyelid margin, and ventral removed skin margins of lower eyelid were sutured using a simple interrupted suture pattern.

wound margin of the upper eyelid was sutured to the base of the meibomian gland (5-6 mm from the meibomian gland orifice) using a simple continuous pattern with 6-0 polyglactin 910 (Vicryl<sup>®</sup>, Johnson & Johnson, Germany) with a spatula needle (Fig 2B). The incised skin wound in the lower eyelid and lateral canthus was sutured with a simple interrupted suture pattern (Fig 2B).

For post-operative management, topical 0.5% levofloxacin TID (Eyelevo<sup>®</sup>, Kolmar Pharm, Korea), 0.15% sodium hyaluronate TID (Eyelein free<sup>®</sup>, Kolmar Pharm), and carbomer gel TID (Liposic Gel<sup>®</sup>, Bausch & Lomb, Germany) were applied for 21 days, and 0.15% sodium hyaluronate TID was instilled throughout the follow-up period. Systemic clavulanic acid-amoxicillin (Yucla<sup>®</sup>, Yuhan Pharm, Korea) 12.5 mg/kg BID was administered for 21 days, and an Elizabethan collar was applied to prevent self-trauma for 30 days. Sutures were removed 14-16 days postoperatively. Corneal ulcers (3 eyes) healed within 8 days. Re-epithelialization of the excised skin wound of the upper eyelid by secondary granulation was complete at a mean of 12 days (7-16 days) postoperatively (Fig 3). The mean follow-up time was 274 days (179-405 days), and clinical signs related to upper and

lower eyelid entropion, such as blepharospasm, epiphora, and ocular discharge, disappeared, and entropion recurrences were not observed at the last visit for recheck in all three dogs.

## Discussion

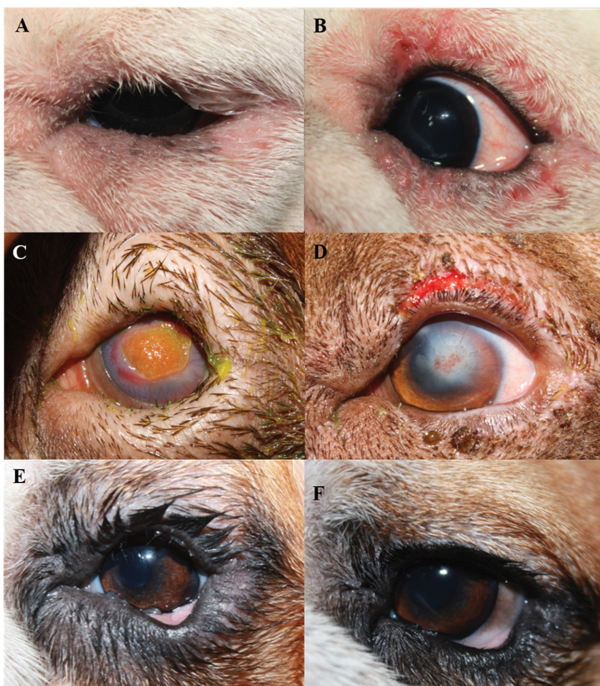In this case report, 3 dogs (5 eyes) were all diagnosed with conformational entropion because their entropion, including the upper and lower eyelids and lateral canthus, were not corrected even after instillation of 0.5% proparacaine (Alcaine<sup>®</sup>, Alcon, Korea). Since the age at the time of entropion onset was 12 months or more, the Stades forced granulation method, combined with Hotz-Celsius procedure were performed together for permanent correction of entropion rather than temporary correction, such as temporary tacking suture or subdermal hyaluronic acid filler injection. It was considered that it would be better to use the above combined entropion surgery in the chronic severe trichiasis and entropion cases.

Two English bulldogs and a Shar-pei dog presented with clinical signs of blepharospasm, epiphora, and ocular discharge caused by trichiasis secondary to the upper and lower eyelid entropion in one or both eyes (5 total eyes affected) in this case report. Pickett (9) and Stades (12) stated that entropion is known to occur commonly in the temporal third of the upper eyelid and the temporal half of the lower eyelid in Bulldog, Shar-pei, Rottweiler, Chow Chow, and spaniels dog breeds. It has also been reported that medial lower and upper eyelid entropion frequently occurred in English bulldog, toy poodle, pug, Pekingese, and Shih Tzu breeds.

Since English bulldog, Shar-pei, and Chow Chow are breeds with excessive redundant frontal skin folds, it has been reported that Hotz-Celsius procedure alone was not sufficient for correcting upper eyelid entropion (12,13). Therefore, for correction of upper eyelid entropion in these breeds, the Stades forced granulation method (4,9,11,12), brow suspension technique (3,14), and coronal rhytidectomy with deep plane walking suture (7) are performed.

The advantage of brow suspension is that it reduces anesthetic time and facial changes, but it can cause complications such as suture rupture, abscess formation, granuloma formation, and entropion recurrence (3). Although coronal rhytidectomy reduces pressure on the upper eyelid and lateral canthus, it has the disadvantage of recurring trichiasis irritation on the cornea because the corrective effect of the eyelid margin itself is small (12). The Stades forced granulation method can remove upper eyelid skin and cilia by inducing second granulation after wide radical excision of excessive skin fold over the upper eyelid (Fig 1). It is also possible to correct both upper eyelid entropion and lateral canthal entropion by Hotz-Celsius procedure and its modification (12).

A study in which the Stades method was performed to correct the entropion of the upper eyelid reported no recurrence of clinical signs for up to 36 months in 21 dogs, including English cocker spaniel, Basset hound, Bloodhound, Fila Brasileiro, and mongrel dogs (5). On the other hand, when the upper and lower eyelid entropion occur together, Hotz-Celsius procedure and lateral eyelid wedge resection (10), or the



**Fig 3.** Pre- and postoperative appearances in case 1 OS (A, B), case 2 OS (C, D), and case 3 OS (E, F). External appearances at initial examination in case 1 (A), case 2 (C), and case 3 (E), respectively. (B) Appearance immediately after sutures removal. Apposed skins areas were healed, and corrected entropion was observed 16 days after surgery. (D) Granulation tissue and corneal superficial vessels were significantly reduced 7 days after surgery. (F) At 405 days after surgery, epiphora and blepharospasm were not observed. [Note that entropion of upper and lower eyelid, and lateral canthus, causing trichiasis and severe granulation tissue formation, neovascularization, and corneal edema were observed in case 2 (C). Marked tear staining of eyelid margin and periocular surface before surgery was also observed in case 3 (E)].

classic Hotz Celsus procedure (12) were performed with Stades method. In addition, in another study (1) treating upper and lower eyelid entropion with Stades method in 27 Sharpei dogs (54 eyes), it was reported that ocular signs were resolved in 50 eyes at 4 weeks after surgery, and evaluation of whether to further correct the lower eyelid entropion was recommended in recurrent cases.

Laus et al. (5) reported that re-epithelialization of excised upper eyelid skin was completed 1 month after the Stades method surgery, and there was no recurrence of clinical signs of entropion at 36 months after the surgery. In our case report, re-epithelialization was completed within an average of 12 days postoperatively, and the corneal ulcer in 3 eyes healed in a maximum of 8 days postoperatively. In particular, it was observed that severe corneal granulation almost disappeared 7 days after surgery in case 2 (Fig 3C, 3D).

However, since Asti et al. (1) reported that the upper and lower eyelid entropion were corrected only by the Stades method, in the future, a comparative study on the prognosis between the surgical modification used in this case report and single Stades method application is needed in larger populations.

## Conclusions

Three dogs with trichiasis caused by upper and lower eyelid entropion, including the lateral canthus, were treated by a combination of the Stades forced granulation method with the Hotz-Celsus procedure in this case report. At the last follow-up recheck after a mean of 274 days after surgery, clinical signs disappeared, and no recurrences of entropion were observed in any of the 3 dogs (5 eyes). Therefore, the combination of the Stades forced granulation method and Hotz-Celsus procedure could be effective intervention for the treatment of trichiasis caused by upper and lower eyelid entropion in dogs.

## Conflict of Interest

All authors declare no conflicts of interest.

## References

1. Asti M, Nardi S, Barsotti G. Surgical management of bilateral, upper and lower eyelid entropion in 27 Shar Pei dogs, using the Stades forced granulation procedure of the upper eyelid only. *N Z Vet J* 2020; 68: 112-118.
2. Bettenay S, Mueller RS, Maggs DJ. Diseases of the eyelids. In: *Slatter's Fundamentals of Veterinary Ophthalmology*, 6<sup>th</sup> ed. (Maggs DJ, Miller PE, Ofri R. eds.), Saint Louis, Elsevier. 2018: 127-157.
3. Cairó M, Leiva M, Costa D, Peña MT. Marti Cairo, Modified brow suspension technique for the treatment of pseudoptosis due to redundant frontal skin in the dogs: a retrospective study of 25 cases. *Vet Ophthalmol* 2018; 21: 112-118.
4. Gelatt KN, Whitley RD. Surgery of the eyelids. In: *Veterinary ophthalmic surgery*, 1<sup>st</sup> ed. (Gelatt KN, Gelatt JP. Eds.), Maryland Height, Elsevier Saunders. 2011: 89-140.
5. Laus JL, Vicenti FAM, Bolzan AA, Galera PD, Sanches RC. Stades method for surgical correction of upper eyelid trichiasis-entropion: results and follow-up in 21 cases. *Cienc Rural* 2000; 30: 651-654
6. Manning S. The eyelid. In: *BSAVA manual of canine and feline ophthalmology*. 3<sup>rd</sup> ed. Gloucester: BSAVA. 2014: 133-166.
7. McCallum P, Welser J. Coronal rhytidectomy in conjunction with deep plane walking sutures, modified Hotz-Celsus and lateral canthoplasty procedure in a dog with excessive brow droop. *Vet Ophthalmol* 2004; 7: 376-379.
8. McDonald JE, Knollinger AM. The use of hyaluronic acid subdermal filler for entropion in canines and felines: 40 cases. *Vet Ophthalmol* 2019; 22: 105-115.
9. Pickett JP. Eyelids. In: *Ophthalmic disease in veterinary medicine*, 2<sup>nd</sup> ed. Boca Raton: CRC Press. 2019: 173-234.
10. Read RA, Broun HC. Entropion correction in dogs and cats using a combination Hotz-Celsus and lateral eyelid wedge resection: results in 311 eyes. *Vet Ophthalmol* 2007; 10: 6-11.
11. Stades FC. A new method for surgical correction of upper eyelid trichiasis-entropion: operation method. *J Am Vet Med Assoc* 1987; 23: 603-606.
12. Stades FC, Gelatt KN. Diseases and surgery of the canine eyelid. In: *Veterinary ophthalmology*, 4<sup>th</sup> ed. (Gelatt KN. Eds), Ames, Blackwell Publishing. 2007: 563-617.
13. Van der Woerd A. Adnexal surgery in dogs and cats. *Vet Ophthalmol* 2004; 214: 284-290.
14. Willis AM, Martin CL, Stiles J, Kirschner SE. Brow suspension for treatment of ptosis and entropion in dogs with redundant facial skin folds. *J Am Vet Med Assoc* 1999; 214: 660-662.