

# Diagnostic accuracy of imaging examinations for peri-implant bone defects around titanium and zirconium dioxide implants: A systematic review and meta-analysis

Mariana Murai Chagas<sup>1,\*</sup>, Solange Kobayashi-Velasco<sup>1</sup>, Thais Gimenez<sup>2</sup>,  
Marcelo Gusmão Paraiso Cavalcanti<sup>1</sup>

<sup>1</sup>Department of Stomatology, School of Dentistry, University of São Paulo, São Paulo, Brazil

<sup>2</sup>Graduate Program in Dentistry, Ibirapuera University, São Paulo, São Paulo, Brazil

## ABSTRACT

**Purpose:** This systematic review and meta-analysis assessed the diagnostic accuracy of imaging examinations for the detection of peri-implant bone defects and compared the diagnostic accuracy between titanium (Ti) and zirconium dioxide (ZrO<sub>2</sub>) implants.

**Materials and Methods:** Six online databases were searched, and studies were selected based on eligibility criteria. The studies included in the systematic review underwent bias and applicability assessment using the Quality Assessment of Diagnostic Accuracy Studies 2 (QUADAS-2) tool and a random-effect meta-analysis. Summary receiver operating characteristic (sROC) curves were constructed to compare the effect of methodological differences in relation to the variables of each group.

**Results:** The search strategy yielded 719 articles. Titles and abstracts were read and 61 studies were selected for full-text reading. Among them, 24 studies were included in this systematic review. Most included studies had a low risk of bias (QUADAS-2). Cone-beam computed tomography (CBCT) presented sufficient data for quantitative analysis in ZrO<sub>2</sub> and Ti implants. The meta-analysis revealed high levels of inconsistency in the latter group. Regarding sROC curves, the area under the curve (AUC) was larger for the overall Ti group (AUC=0.79) than for the overall ZrO<sub>2</sub> group (AUC=0.69), but without a statistically significant difference between them. In Ti implants, the AUCs for dehiscence defects (0.73) and fenestration defects (0.87) showed a statistically significant difference.

**Conclusion:** The diagnostic accuracy of CBCT imaging in the assessment of peri-implant bone defects was similar between Ti and ZrO<sub>2</sub> implants, and fenestration was more accurately diagnosed than dehiscence in Ti implants. (*Imaging Sci Dent* 2021; 51: 363-72)

**KEY WORDS:** Diagnostic Imaging; Cone-Beam Computed Tomography; Zirconium; Dental implants

## Introduction

Dental implants are a clinical resource widely used in oral rehabilitation with a high success rate (97%) if the variables that influence their longevity are appropriately considered.<sup>1</sup> Despite clinical success, there is still a high prevalence of patients who experience diseases of the peri-

implant tissue. After 5 years of follow-up, approximately 8.6% to 9.7% of dental implants exhibit chronic inflammation of the soft and hard tissues around them. Peri-implantitis is characterised by increased probing depth, bleeding, and progressive alveolar bone loss and can result in bone defects such as dehiscence, fenestration and intrabony defects.<sup>2-4</sup>

The diagnosis of peri-implantitis and bone defects is based on clinical and imaging examinations. Early detection may lead to a more favourable prognosis. In contrast, an inaccurate diagnosis and unsatisfactory management can lead to gingival recession, aesthetic complications, and loss of implant osseointegration.<sup>4-6</sup>

This study was financed in part by the Coordenação de Aperfeiçoamento de Pessoal de Nível Superior - Brasil (CAPES) - Finance Code 001.

Received May 13, 2021; Revised September 8, 2021; Accepted September 24, 2021

Published online November 18, 2021

\*Correspondence to : Dr. Mariana Murai Chagas

Department of Radiology, School of Dentistry, University of São Paulo, Av. Lineu Prestes, 2227, CEP 05508-000, São Paulo, SP, Brazil

Tel) 55-11-9-5975-0770, E-mail) mariana.chagas@usp.br

Copyright © 2021 by Korean Academy of Oral and Maxillofacial Radiology

This is an Open Access article distributed under the terms of the Creative Commons Attribution Non-Commercial License (<http://creativecommons.org/licenses/by-nc/3.0>) which permits unrestricted non-commercial use, distribution, and reproduction in any medium, provided the original work is properly cited.

Imaging Science in Dentistry · pISSN 2233-7822 eISSN 2233-7830

Periapical radiographs (PRs), panoramic radiography (PAN), magnetic resonance imaging (MRI), computed tomography (CT), and cone-beam computed tomography (CBCT) are imaging modalities used to detect peri-implant bone defects. Some authors have suggested the initial acquisition of PRs,<sup>7,8</sup> which allow the visualization of mesial and distal aspects of the implant. However, 2-dimensional radiography can underestimate incipient lesions and intrabony defects.<sup>8</sup>

CBCT has become an important diagnostic tool to assess the peri-implant region. Although PR allows the visualization of mesial and distal bone areas around the implant, CBCT images prevent overlapping of anatomical structures,<sup>9,10</sup> thus assisting in distinguishing buccal and lingual cortical bone plates in addition to mesial and distal bone tissue. The limitations of this modality include the metallic artifacts generated by the presence of high-atomic-number materials.

Metallic artifacts result from the beam-hardening phenomenon, which occurs due to the distinct absorption of low-energy X-ray photons by materials with high atomic numbers. This creates localised hypodensities or dark voids close to dense objects, such as titanium (Ti) and zirconium (Zr), and impairs assessment of the image.<sup>11</sup>

Ti has been used for decades to manufacture dental implants due to its biocompatibility and osseointegration, but several other materials have also been used to manufacture dental implants in order to overcome the limitations of Ti. Zirconium dioxide (ZrO<sub>2</sub>) implants are usually installed in maxillary or mandibular anterior rehabilitations for aesthetic reasons because they closely match the tooth colour, thereby avoiding darkened areas that are visible upon cervical exposure or through transparent gingival tissue.<sup>12,13</sup> However, both types of implants produce metallic artifacts.<sup>11,14,15</sup>

The demand for ZrO<sub>2</sub> implants in recent years has raised concerns about the presence of metallic artifacts in CBCT images. Several studies<sup>14-18</sup> have reported a greater number of artifacts in images of ZrO<sub>2</sub> implants using some imaging modalities than in images of Ti implants. Based on these reports, it is fundamental to investigate the diagnostic accuracy of the imaging and the degree of artifact interference at the implant-bone interface for both Ti and ZrO<sub>2</sub> implants.

A systematic review is an important pre-specified tool that compiles available evidence to answer a defined question. Through meta-analysis it is possible to statistically analyse results from different individual studies. Both methods improve the synthesis of the best evidence, in order to guide clinicians in the decision-making process.<sup>19</sup>

Thus, this study aimed to perform a systematic review and meta-analysis to assess the diagnostic accuracy of imaging modalities in the detection of peri-implant bone defects and to compare the diagnostic accuracy between Ti and ZrO<sub>2</sub> implants.

## Materials and Methods

This systematic review was conducted in accordance with Preferred Reporting Items for Systematic Reviews and Meta-Analyses for Diagnostic Test Accuracy (PRISMA-DTA).<sup>20</sup> Studies reporting the accuracy of imaging exams in the evaluation of peri-implant bone defects were extracted from the following databases: MEDLINE (PubMed), EMBASE, Web of Science, ScienceDirect, Scopus, and ProQuest. Keywords related to concepts addressed by the pre-defined question of this study were used to gather all relevant articles. The PubMed search strategy included a combination of Medical Subject Headings (MeSH) terms and text words described as follows: (“accuracy”) OR (“sensitivity”) OR (“specificity”) OR (“physical measurement”) AND (“peri-implantitis” [MeSH Terms]) OR (“periimplantitis”) OR (“bone”) OR (“bone defect”) OR (“bone loss”) OR (“bone-implant interface” [MeSH Terms]) OR (“bone-implant interface/diagnosis” [MeSH Terms]) OR (“bone-implant interface/diagnostic imaging” [MeSH Terms])) OR (“peri-implantitis/diagnostic imaging” [MeSH Terms]) OR (“peri-implantitis/chemically induced” [MeSH Terms]) OR (“peri-implantitis/diagnosis” [MeSH Terms]) OR (“peri-implantitis/classification” [MeSH Terms]) AND (“cone-beam computed tomography” [MeSH Terms]) OR (“spiral cone-beam computed tomography” [MeSH Terms]) OR (“diagnostic imaging” [MeSH Terms]) OR (“dental radiography”) OR (dental radiography [MeSH Terms])) OR (panoramic radiography [MeSH Terms])) OR (“periapical radiography”) OR (“ultrasound”) OR (“magnetic resonance”) OR (“tomography” [MeSH Terms]) OR (“radiography, dental, digital” [MeSH Terms]) OR (“radiography, dental” [MeSH Terms]) AND (“dental implants” [MeSH Terms]) OR (“dental implants, single-tooth” [MeSH Terms]).

For other databases, the search strategy was modified using appropriate Boolean strategies. A manual search was also conducted of reference lists in the included studies. The search was carried out in June 2020 and updated in December 2020.

The articles were evaluated by 2 independent and calibrated reviewers (kappa: 0.81). Through the Rayyan website (Qatar Computing Research Institute, URL: <http://rayyan.qcri.org>), duplicated files were excluded and titles and abs-

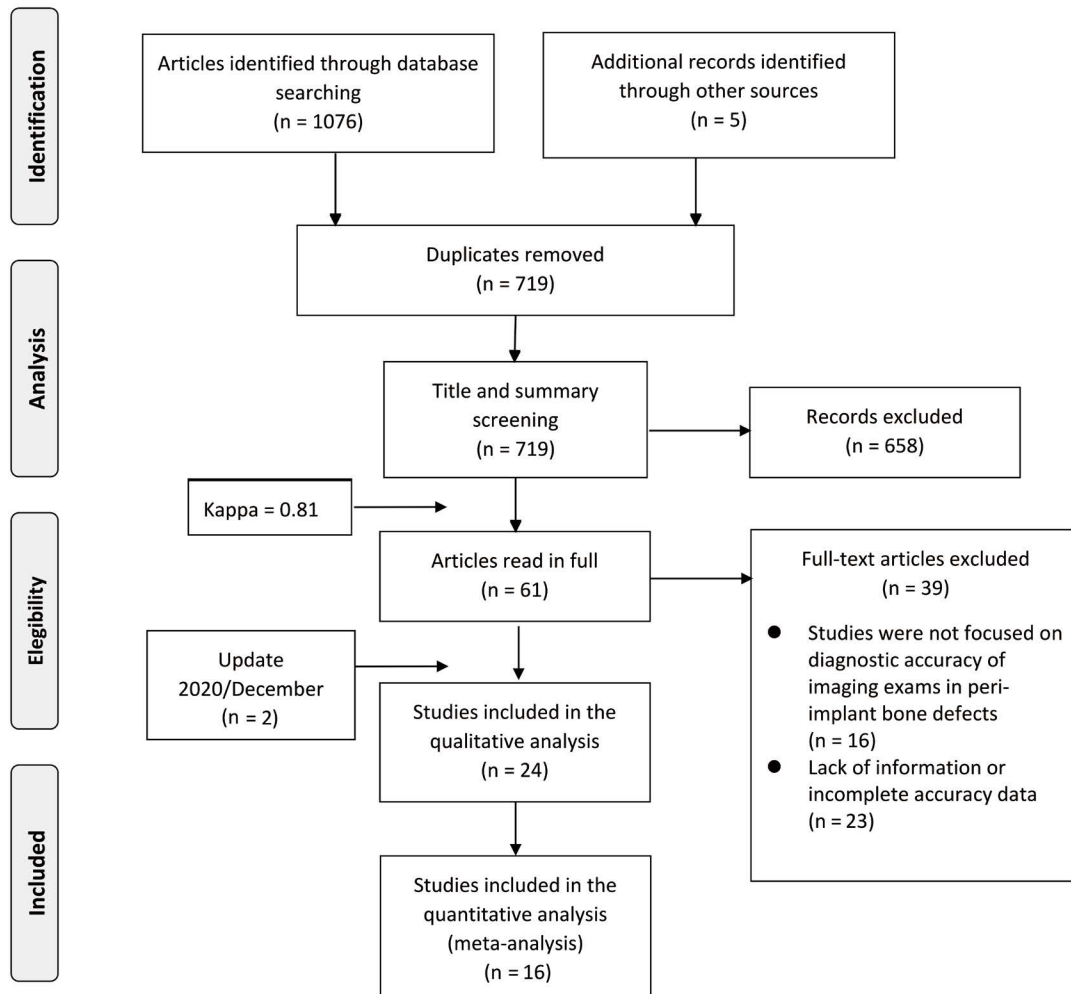


Fig. 1. Flow diagram of the systematic search.

tracts were screened according to the eligibility criteria. The initial screening included studies that evaluated the peri-implant region using any diagnostic imaging method. Studies that were not in English or Portuguese, systematic reviews, narrative reviews, letters, and case reports were excluded. The selected articles were then read in full and studies that evaluated the accuracy of diagnostic imaging methods in Ti or ZrO<sub>2</sub> peri-implant bone defects were included. These criteria were applied to full-text readings because titles and abstracts might not exhibit accurate or complete data. Reviewers discussed any disagreements between themselves to reach a consensus or a third reviewer was consulted. Studies that met the inclusion criteria and did not have any of the exclusion criteria were then accepted for data extraction and bias assessment.

The risk of bias and the applicability of the included studies were assessed independently by 2 reviewers using the Quality Assessment Tool for Diagnostic Accuracy

Studies 2 (QUADAS-2) and Review Manager version 5.4 (The Cochrane Collaboration, London, UK). Four domains were addressed: patient selection, index test, reference test, and flow and timing. Questions related to the study design could be answered with ‘yes’ if there was a low risk of bias, ‘uncertain’ when it was not possible to determine the risk, and ‘no’ for a high risk of bias.

Data extraction was performed by 2 independent reviewers. The meta-analysis included studies that presented precise numbers or any other data enabling the calculation of diagnostic performance. The extracted data included sensitivity, specificity, true/false and positive/negative results, and the disease prevalence in each sample. The Meta-Disc software (Ramón y Cajal Hospital, Madrid, Spain) was used to perform the random-effect meta-analysis and to identify sources of heterogeneity (the Cochran Q and I<sup>2</sup> tests).

Summary receiver operating characteristic (sROC) curves were constructed using RStudio software version

1.4.1106 (Integrated Development Inc., Boston, MA, USA) to compare the effect of methodological differences in relation to the variables of each group.

### Results

#### Selection of studies

The search strategy yielded 1,076 studies. After removing duplicates, 719 articles were included for title and abstract assessment reading, and 61 articles were selected for full reading. After reading the studies in full, the reviewers excluded 39 articles. An updated search was carried out in December 2020 and 2 new articles were included, totalling 24 final articles for the systematic review. A summary of the results of the systematised search is illustrated in Figure 1.

#### Risk of bias and applicability assessment

The QUADAS-2 analysis of the 24 studies is summarised in Figure 2. Regarding applicability, patient selection in 17 studies was classified as high risk due to *in vitro* models that used animal samples (bovine rib, sheep and porcine jaws) or artificial material (plaster). Concerning the risk of bias, 2 studies<sup>21,22</sup> were classified as high risk by the index test, since their results were interpreted with some knowledge of the reference standard. For the other studies classified as uncertain risk, that information could not be confirmed.<sup>23-25</sup> For the item reference standard regarding applicability, only 1 study<sup>26</sup> was classified as uncertain risk because it used the “water volume displacement” technique as a standard. Except for the conditions mentioned, most studies had a low risk of bias in all categories. The QUADAS-2 assessment is illustrated in Figure 2.

#### Description of the included studies

All included studies had *in vitro* designs, experimentally simulating peri-implant bone defects in Ti and ZrO<sub>2</sub> implants. Artificial defects were created mechanically, chemically, or using both methods on the same sample. The defect morphology included 4-wall defects, dehiscence, fenestration, and any other shape created by chemical substances. Most studies applied CBCT to analyse diagnostic performance; i-CAT (Imaging Sciences International, Hatfield, PA, USA) and 3D Accuitomo (J Morita Mfg. Corp., Kyoto, Japan) were the most frequently selected devices. To assess diagnostic accuracy, all studies used a 5-point Likert scale.

The studies used PR, PAN, MRI, CT, and CBCT, in Ti<sup>12,13,22-42</sup> and ZrO<sub>2</sub><sup>12,13,23,36,43</sup> implants. The descriptive characteristics of the studies are shown in Table 1.

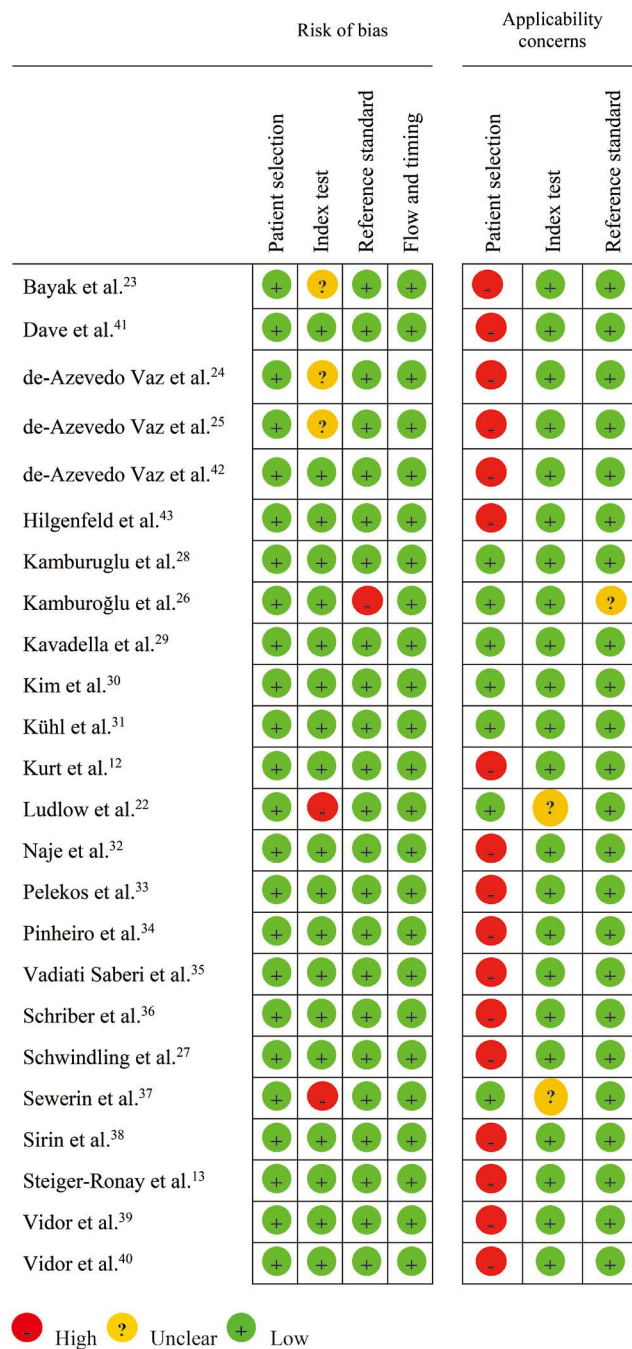


Fig. 2. Summary of Quality Assessment of Diagnostic Accuracy Studies-2 (QUADAS-2) of the included studies.

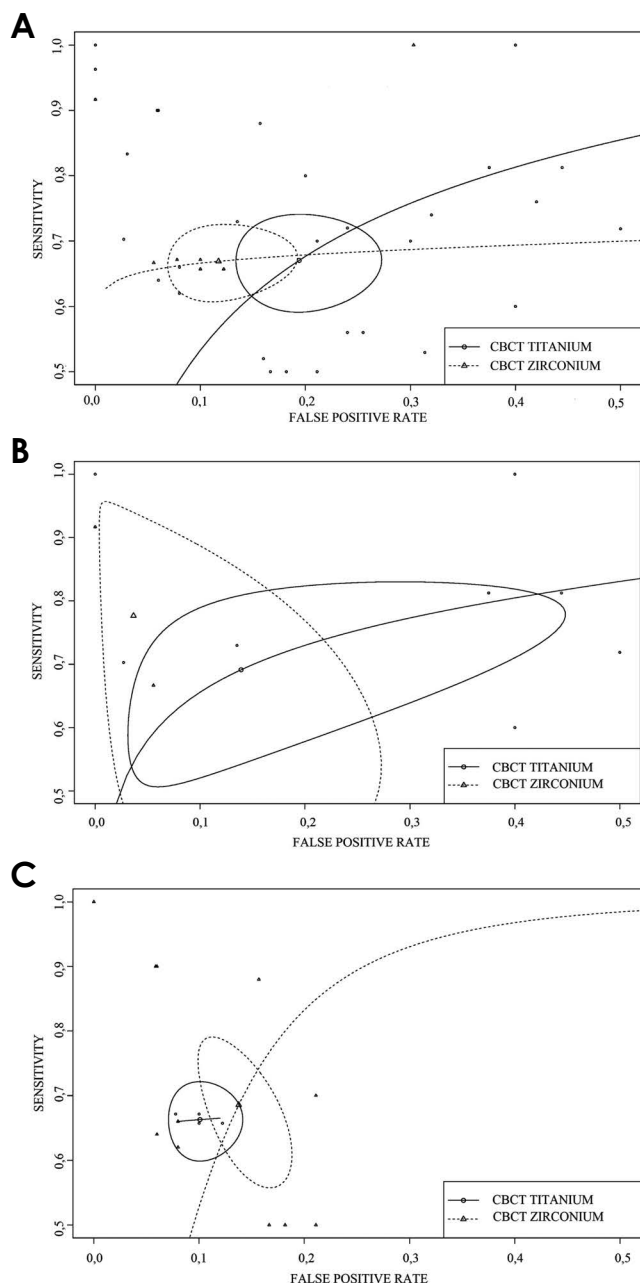
#### Statistical analysis

Only CBCT studies presented sufficient information for the quantitative analysis. All meta-analyses and source of heterogeneity analyses were conducted considering the Ti and ZrO<sub>2</sub> implant groups, including the following subgroups: fenestration defects, 4-wall defects, and dehiscence (the latter only for the Ti group). The sROC curves (Fig. 3) were performed considering the same subgroups.

**Table 1.** Descriptive characteristics of the included studies

Authors	Sample/Implant	Objectives	Findings and conclusions
Bayrak et al. <sup>23</sup>	Sheep jaw/Ti and ZrO <sub>2</sub>	Tested filter and MAR	Diagnostic efficacy was higher in Ti implants. MAR may improve performance.
Dave et al. <sup>41</sup>	Bovine rib/Ti	Compared CBCT and PR	PR performed better than CBCT with a defect of 0.35 mm.
de-Azevedo-Vaz et al. <sup>24</sup>	Bovine rib/Ti	Tested voxel sizes in dehiscence and fenestration	Voxel size did not affect the evaluation of the 2 types of bone defects.
de-Azevedo-Vaz et al. <sup>25</sup>	Bovine rib/Ti	Tested filter in dehiscence	Some filters may improve diagnosis compared to original images.
de-Azevedo-Vaz et al. <sup>42</sup>	Bovine rib/Ti	Tested MAR and voxel sizes in dehiscence and fenestration	MAR did not improve the diagnosis in both defects and in the two voxel sizes.
Hilgenfeld et al. <sup>43</sup>	Bovine rib/ZrO <sub>2</sub>	Tested PR, MRI, and CBCT	CBCT and MRI were more accurate for identifying the morphology of major defects.
Kamburoglu et al. <sup>28</sup>	Human jaw/Ti	Tested MAR	No difference was found with and without MAR application.
Kamburoğlu et al. <sup>26</sup>	Human jaw/Ti	Tested acquisition protocol and FOVs	Different FOVs performed similarly in diagnostic accuracy.
Kavadella et al. <sup>29</sup>	Human jaw/Ti	Tested conventional and digital inverse images	Peri-implant defects might need to have a certain size to be detected.
Kim et al. <sup>30</sup>	Human jaw/Ti	Tested CBCT devices and acquisition protocols	Different devices and acquisition protocols did not affect the diagnostic performance.
Kühl et al. <sup>31</sup>	Human jaw/Ti	Accuracy in CT, CBCT, PAN, and PR	PR showed better performance in all modalities. CBCT and PR showed similar sensitivity.
Kurt et al. <sup>12</sup>	Sheep jaw/Ti and ZrO <sub>2</sub>	Tested acquisition protocol, voxel sizes in fenestration	Accuracy values were similar for all voxel sizes. Ti had higher AUC values than ZrO <sub>2</sub> .
Ludlow et al. <sup>22</sup>	Human jaw/Ti	Accuracy of PR and CT in distinct defect sizes	CT provided better results than PR for all defect sizes.
Naje et al. <sup>32</sup>	Bovine rib/Ti	Accuracy of PAN and CBCT in distinct defect sizes	Accuracy, specificity, and predictive value were higher in CBCT.
Pelekos et al. <sup>33</sup>	Porcine rib/Ti	Accuracy of PR and CBCT in distinct defect sizes, thickness and morphology	CBCT performed better than PR. The examiner's experience affected the accuracy.
Pinherio et al. <sup>34</sup>	Bovine rib/Ti	Tested acquisition protocol and FOVs	Better performance for expert observers. No significant difference between the 2 FOVs.
Vadiati Saberi et al. <sup>35</sup>	Bovine rib/Ti	Accuracy of CBCT and PR in distinct angulations	High sensitivity of CBCT for all types of defects.
Schriber et al. <sup>36</sup>	Porcine jaw/Ti and ZrO <sub>2</sub>	CBCT accuracy in Ti and ZrO <sub>2</sub> implants	ZrO <sub>2</sub> implants showed lower accuracy (0.78) than Ti (0.91).
Schwindling et al. <sup>27</sup>	Bovine rib/Ti	Accuracy of low/high-dose CBCT	High-dose-CBCT accuracy was slightly higher but not statistically significant.
Sewerin et al. <sup>37</sup>	Human jaw/Ti	Tested PR accuracy in 2 angulations and defect sizes	PR was an unreliable method for identifying peri-implant gaps.
Sirin et al. <sup>38</sup>	Bovine rib/Ti	Accuracy of PR, PAN, CBCT, MSCT	PR and CBCT were accurate in detecting bone defects over 0.5 mm.
Steiger-Ronay et al. <sup>13</sup>	Artificial model/Ti and ZrO <sub>2</sub>	Accuracy of PR and CBCT in Ti and ZrO <sub>2</sub> implants	Higher accuracy in PR and in Ti implants than in ZrO <sub>2</sub> implants.
Vidor et al. <sup>39</sup>	Bovine rib/Ti	PR, CBCT accuracy in different devices	Highest accuracy for PR. The size of the voxel did not change performance.
Vidor et al. <sup>40</sup>	Bovine rib/Ti	Accuracy of PR with filters	Filters may improve the diagnosis of the bone-implant interface.

Ti: titanium, ZrO<sub>2</sub>: zirconium dioxide, MAR: metallic artifact reduction, CBCT: cone-beam computed tomography, PR: periapical radiography, MRI: magnetic resonance imaging, FOV: field of view, CT: computed tomography, PAN: panoramic radiography, AUC: area under curve, MSCT: multi-slice computed tomography



**Fig. 3.** A. Comparison of all subgroups (overall) for cone-beam computed tomographic (CBCT) imaging of titanium versus zirconium implants. B. Comparison of 4-wall defects using CBCT imaging for titanium implants versus CBCT imaging for zirconium implants overall. C. Comparison of fenestration defects using CBCT imaging for titanium implants versus CBCT imaging for zirconium implants. CBCT: cone-beam computed tomography.

The overall Ti implant analysis for sensitivity, specificity, and diagnostic odds ratio yielded lower values than the same parameters for ZrO<sub>2</sub> implants. The levels of inconsistency were higher in the first group.

The sensitivity values for Ti in the identification of 4-

wall defects, fenestration, and dehiscence were similar, with statistically significant results for the last 2 subgroups, which presented a high level of inconsistency (according to the criteria of Higgins et al.<sup>44</sup>). The pooled values for the diagnostic odds ratio ranged from 4.21 (95% CI, 2.53-7.03) to 19.03 (95% CI, 6.55-55.33) for Ti, with the diagnostic odds ratio for dehiscence having the lowest value and the diagnostic odds ratio for 4-wall defects the highest.

The specificity values in the ZrO<sub>2</sub> group for the identification of 4-wall and fenestration defects were close (0.97 and 0.90, respectively) and higher than those of the Ti implant group, with no statistical significance. The pooled value diagnostic odds ratio was higher for 4-wall defects in ZrO<sub>2</sub> implants than in Ti implants (99.09; 95% CI, 6.77-1451.0), while the diagnostic odds ratio for fenestration was similar for both materials. These inconsistencies were considered moderate and minor, respectively, in relation to the Ti group.

The comparison between the sROC curves of Ti and ZrO<sub>2</sub> implants and their subgroups is demonstrated in Figure 3A-C. The area under the curve (AUC) was higher for the overall Ti group (AUC=0.79) than in the overall ZrO<sub>2</sub> group (AUC=0.69), and the 2 groups of implants showed similar AUCs for fenestration defects (Ti AUC=0.87 and ZrO<sub>2</sub> AUC=0.68), with no statistically significant difference. However, a significant difference was found between dehiscence and fenestration defects in Ti implants (Ti dehiscence AUC=0.73 and Ti fenestration AUC=0.87).

## Discussion

The correct choice of an imaging examination is essential for the dental surgeon to identify, treat, and monitor bone defects and pathologies such as peri-implantitis.

The relevance of this study relates to the current popularity of ZrO<sub>2</sub> implants, primarily due to aesthetic demands. The tooth-like colour, reduced plaque accumulation (when compared to Ti implants), and promising osseointegration results<sup>45,46</sup> have also contributed to the appeal of this material.

Recent studies have demonstrated that, in some imaging modalities, ZrO<sub>2</sub> implants generated more metallic artifacts than Ti implants.<sup>14-17</sup> The presence of more metallic artifacts impacts image quality and the diagnosis of peri-implant bone defects.<sup>12,23,36,43</sup>

The formation of greater numbers of artifacts in images may be associated with the higher atomic number (Z) of Zr (Z=40) than that of Ti (Z=22). A higher Z correlates with

a greater expression of artifacts, modifying the grey scale that affects image contrast, hence decreasing the visibility of anatomical structures.<sup>17</sup>

Sancho-Puchades et al.<sup>17</sup> analyzed the increased formation of metallic artifacts close to ZrO<sub>2</sub> implants when compared to Ti and Ti-Zr in CBCT, which may explain the high number of false-positive diagnoses and lower accuracy.<sup>23,36</sup> Steiger-Ronay et al.<sup>13</sup> noticed similar results in terms of peri-implant bone defect measurements in CBCT images. Schriber et al.<sup>36</sup> observed measurement overestimations of 1.1 mm and underestimations of 1.28 mm. The imprecisions were attributed to the magnified negative influence of the ZrO<sub>2</sub> metallic artifacts. According to the studies, clinicians should be aware of these discrepancies when assessing ZrO<sub>2</sub> implants in CBCT images.

When assessing study samples, diagnostic studies can have a wide array of variables, resulting in potential heterogeneity. For this study, heterogeneity was assessed by the Q test (Higgins et al.<sup>44</sup>). The levels of inconsistency were quantified through the I<sup>2</sup> statistic. The obtained values were considered high for the Ti group (92.5%) and low/moderate for the ZrO<sub>2</sub> group (76%). The meta-analysis outcomes presented significant inconsistency, reinforcing the importance of using this statistical method to consider this divergence among studies and produce more accurate results.

To assess heterogeneity, a meta-analysis of random effects was conducted. For both types of implants, defects were divided into 4-wall and fenestration defects. This subdivision of bone defect types was important for determining the accuracy in various clinical situations.

The sROC curves (Fig. 3) illustrate the data compiled from several studies. The grouping of data through simple pooled weighted averages can produce inaccurate interpretations as the data from individual studies may vary in terms of sample, methodology, and other characteristics. Two previous systematic reviews<sup>47,48</sup> analysed the accuracy of imaging methods in detecting bone defects in Ti implants: Bohner et al.<sup>47</sup> used the aforementioned simple grouping of data, not exploring potential sources of heterogeneity, while Pelekos et al.<sup>48</sup> performed an analysis of random effects but studied only Ti implants.

In the present study, sensitivity and specificity values were higher for the detection of 4-wall defects than for the other subgroups of both implant types. The AUC values (ZrO<sub>2</sub>: 0.95 and Ti: 0.80) were also high, although not statistically significant. Hilgenfeld et al.<sup>43</sup> evaluated the diagnostic performance of CBCT, PR, and MRI for bone defects at the implant-bone interface in ZrO<sub>2</sub> implants that underwent chemical induction of bone defects. As in our system-

atic review, CBCT and MRI showed better performance, mainly in large 4-wall defects.

Four-wall bone defects are among the most frequently observed defects in clinical situations.<sup>4</sup> Although there is still no consensus in the literature that the morphology of the defect influences the prognosis, it has been demonstrated that some factors related to implant location and patient habits can be associated with morphological characteristics of bone defects, implying a potential relationship with disease severity. It is important to use the imaging modality that best identifies the morphology to better plan the treatment approach.<sup>4,7,49</sup>

Several methodologies were found in the assessed diagnostic studies, either regarding the type of artificially induced bone defect or the different CBCT protocols applied. Schwindling et al.<sup>27</sup> analysed the accuracy of PR, low-dose CBCT, and high-dose CBCT for identification, classification, and measurement of peri-implant bone lesions in Ti implants. The accuracy of PR and CBCT were similar in the identification of defects, although low-dose CBCT images provided more accurate identification of defect morphology than PRs. High-dose CBCT slightly increased the diagnostic performance, albeit at the expense of a 14 times higher dose. This study was corroborated by Schriber et al.<sup>36</sup> who determined that low- or high-dose protocols did not significantly affect diagnostic accuracy.

Metallic artifact reduction (MAR) algorithms are designed to reduce the expression of metallic artifacts by increasing the imaging quality during reconstruction. Some researchers<sup>23,28,42</sup> tested the effectiveness of MAR algorithms in detecting peri-implant bone defects, showing no improvement for either Ti or ZrO<sub>2</sub> implants. Comparisons among different acquisition protocols, with variation in terms of voxel size<sup>12,24,40,42</sup> and field of view (FOV),<sup>26,34</sup> resulted in similar diagnostic performance in both types of implants.

The use of filters is a post-processing image manipulation that has yielded positive results in improving diagnostic performance in both Ti and ZrO<sub>2</sub> implants.<sup>25,39</sup> For ZrO<sub>2</sub>, Bayrak et al.<sup>23</sup> found that the adaptive image noise optimiser filter with MAR improved interobserver agreement in the detection of bone defects. Another aspect that positively influenced diagnostic performance was the size of bone defects. In PR, Kühl et al.<sup>31</sup> found that major defects (3 mm) demonstrated higher values of sensitivity and specificity. For CBCT, both a larger size of the bone defect and an increased number of affected bone walls resulted in improved diagnostic performance.<sup>34,41,43</sup>

In addition to variability among the studies, another limitation was the *in vitro* design of all included studies. In exp-

perimental conditions, movement artifacts and gingival tissue attenuation are not reproducible.<sup>50</sup> Furthermore, fewer studies have investigated Zr implants since these implants were developed more recently than Ti implants. These factors hindered the formulation of a systematically analysed dataset with an acceptable level of evidence.

There were insufficient data to analyse quantitatively the performance of imaging methods (PR, PAN, MRI, and CT) for Ti and ZrO<sub>2</sub> implants. PR has already been extensively studied using Ti implants. However, with the recent advent of Zr in implant dentistry, only 1 study<sup>43</sup> used PR with Zr implants, and the accuracy results were lower than with CBCT and MRI.

Hilgenfeld et al.<sup>43</sup> emphasised the potential of MRI, which demonstrated a diagnostic accuracy similar to CBCT for ZrO<sub>2</sub> implants and even greater accuracy in small defects, as well as the advantage of non-ionising radiation. However, more studies evaluating the use of this imaging method are required.

No studies were found that evaluated diagnostic performance for PAN and CT in ZrO<sub>2</sub> implants. The radiographic detection of bone defects using both PAN and CT was inferior to other methods (PR and CBCT) in Ti implants.<sup>31,32,38</sup> This implies that these imaging modalities (PAN and CT) are not appropriate for peri-implantitis assessment.

CBCT diagnostic accuracy in Ti and ZrO<sub>2</sub> implant defects was assessed by applying several methodologies; in most studies, CBCT was superior to PR, at the expense of a higher dose of radiation. According to the American Academy of Oral and Maxillofacial Radiology,<sup>51</sup> before the decision to perform a CBCT examination is made, its use should always be weighted and clinically justified by the patient's clinical signs or symptoms.

In this analysis, high variability was found in imaging studies reporting the detection of bone defects in Ti and ZrO<sub>2</sub> implants. The use of CBCT imaging in the assessment of peri-implant bone defects in ZrO<sub>2</sub> implants seems to impair analysis and decrease accuracy, but statistical significance was observed. Furthermore, for Ti implants, fenestration was more accurately diagnosed than dehiscence. The use of different protocols with modification of the FOV, voxel size, MAR, and the application of filters did not significantly alter the diagnostic performance of the imaging methods for both types of implants.

In order to answer the guiding question of this systematic review with more certainty, further studies are needed using ZrO<sub>2</sub> implants to analyse diagnostic accuracy in different situations.

## Acknowledgments

We would like to thank Jéssica Conti Reus, MSc, for the initial evaluation of our statistical analysis for data accuracy.

**Conflicts of Interest:** None

## References

1. Del Fabbro M, Testori T, Kekovic V, Goker F, Tumedei M, Wang HL. A systematic review of survival rates of osseointegrated implants in fully and partially edentulous patients following immediate loading. *J Clin Med* 2019; 8: 2142.
2. Koldslund OC, Scheie AA, Aass AM. Prevalence of peri-implantitis related to severity of the disease with different degrees of bone loss. *J Periodontol* 2010; 81: 231-8.
3. Jung RE, Pjetursson BE, Glauser R, Zembic A, Zwahlen M, Lang NP. A systematic review of the 5-year survival and complication rates of implant-supported single crowns. *Clin Oral Implants Res* 2008; 19: 119-30.
4. Schwarz F, Derks J, Monje A, Wang HL. Peri-implantitis. *J Clin Periodontol* 2018; 45 Suppl 20: S246-66.
5. Mombelli A, Müller N, Cionca N. The epidemiology of peri-implantitis. *Clin Oral Implants Res* 2012; 23 Suppl 20: 67-76.
6. Academy report. Peri-implant mucositis and peri-implantitis: a current understanding of their diagnoses and clinical implications. *J Periodontol* 2013; 84: 436-43.
7. Bender P, Salvi G, Buser D, Sculean A, Bornstein M. Correlation of three-dimensional radiologic data with subsequent treatment approach in patients with peri-implantitis: a retrospective analysis. *Int J Periodontics Restorative Dent* 2017; 37: 481-9.
8. García-García M, Mir-Mari J, Benic GI, Figueiredo R, Valmaseda-Castellón E. Accuracy of periapical radiography in assessing bone level in implants affected by peri-implantitis: a cross-sectional study. *J Clin Periodontol* 2016; 43: 85-91.
9. Rios HF, Borgnakke WS, Benavides E. The use of cone-beam computed tomography in management of patients requiring dental implants: an American Academy of Periodontology best evidence review. *J Periodontol* 2017; 88: 946-59.
10. Pinheiro LR, Scarfe WC, Augusto de Oliveira Sales M, Gaia BF, Cortes AR, Cavalcanti MG. Effect of cone-beam computed tomography field of view and acquisition frame on the detection of chemically simulated peri-implant bone loss in vitro. *J Periodontol* 2015; 86: 1159-65.
11. Schulze R, Heil U, Gross D, Bruellmann DD, Dranischnikow E, Schwanecke U, et al. Artefacts in CBCT: a review. *Dentomaxillofac Radiol* 2011; 40: 265-73.
12. Kurt MH, Bağış N, Evli C, Atakan C, Orhan K. Comparison of the different voxel sizes in the estimation of peri-implant fenestration defects using cone beam computed tomography: an ex vivo study. *Int J Implant Dent* 2020; 6: 58.
13. Steiger-Ronay V, Krcmaric Z, Schmidlin PR, Sahrman P, Wiedemeier DB, Benic GI. Assessment of peri-implant defects at titanium and zirconium dioxide implants by means of periapical radiographs and cone beam computed tomography: an in-vitro examination. *Clin Oral Implants Res* 2018; 29: 1195-201.



14. Vasconcelos TV, Leandro Nascimento EH, Bechara BB, Freitas DQ, Noujeim M. Influence of cone beam computed tomography settings on implant artifact production: zirconia and titanium. *Int J Oral Maxillofac Implants* 2019; 34: 1114-20.
15. Klink T, Daboul A, Maron J, Gredes T, Puls R, Jaghsi A, et al. Artifacts in magnetic resonance imaging and computed tomography caused by dental materials. *Plos One* 2012; 7: e31766.
16. Smeets R, Schöllchen M, Gauer T, Aarabi G, Assaf AT, Rendebach C, et al. Artefacts in multimodal imaging of titanium, zirconium and binary titanium-zirconium alloy dental implants: an in vitro study. *Dentomaxillofac Radiol* 2017; 46: 20160267.
17. Sancho-Puchades M, Hämmerle CH, Benic GI. In vitro assessment of artifacts induced by titanium, titanium-zirconium and zirconium dioxide implants in cone-beam computed tomography. *Clin Oral Implants Res* 2015; 26: 1222-8.
18. Demirturk Kocasarac H, Ustaoglu G, Bayrak S, Katkar R, Geha H, Deahl ST 2nd, et al. Evaluation of artifacts generated by titanium, zirconium, and titanium-zirconium alloy dental implants on MRI, CT, and CBCT images: a phantom study. *Oral Surg Oral Med Oral Pathol Oral Radiol* 2019; 127: 535-44.
19. Leeflang MM, Deeks JJ, Gatsonis C, Bossuyt PM, Cochrane Diagnostic Test Accuracy Working Group. Systematic reviews of diagnostic test accuracy. *Ann Intern Med* 2008; 149: 889-97.
20. Sharifabadi AD, McInnes MD, Bossuyt PM. PRISMA-DTA: an extension of PRISMA for reporting of diagnostic test accuracy systematic reviews. *Clin Chem* 2018; 64: 985-6.
21. Sewerin IP. Comparison of radiographic image characteristics of Brånemark and IMZ implants. *Clin Oral Implants Res* 1991; 2: 151-6.
22. Ludlow JB, Gates W, Nason R Jr. Radiographic evaluation of implant-obscured bone. Comparison of digitally subtracted tomographic and periapical techniques. *Oral Surg Oral Med Oral Pathol Oral Radiol Endod* 1995; 80: 351-7.
23. Bayrak S, Orhan K, Kursun Çakmak ES, Görürğöz C, Odabaşı O, Yılmaz D, et al. Evaluation of a metal artifact reduction algorithm and an optimization filter in the estimation of peri-implant dehiscence defects by using cone beam computed tomography: an in-vitro study. *Oral Surg Oral Med Oral Pathol Oral Radiol* 2020; 130: 209-16.
24. de-Azevedo-Vaz SL, Vasconcelos Kde F, Neves FS, Melo SL, Campos PS, Haiter-Neto F. Detection of periimplant fenestration and dehiscence with the use of two scan modes and the smallest voxel sizes of a cone-beam computed tomography device. *Oral Surg Oral Med Oral Pathol Oral Radiol* 2013; 115: 121-7.
25. de-Azevedo-Vaz SL, Alencar PN, Rovaris K, Campos PS, Haiter-Neto F. Enhancement cone beam computed tomography filters improve in vitro periimplant dehiscence detection. *Oral Surg Oral Med Oral Pathol Oral Radiol* 2013; 116: 633-9.
26. Kamburoğlu K, Murat S, Kılıç C, Yüksel S, Avsever H, Farman A, et al. Accuracy of CBCT images in the assessment of buccal marginal alveolar peri-implant defects: effect of field of view. *Dentomaxillofac Radiol* 2014; 43: 20130332.
27. Schwindling FS, Hilgenfeld T, Weber D, Kosinski MA, Rammeberg P, Tasaka A. In vitro diagnostic accuracy of low-dose CBCT for evaluation of peri-implant bone lesions. *Clin Oral Implants Res* 2019; 30: 1200-8.
28. Kamburoglu K, Kolsuz E, Murat S, Eren H, Yüksel S, Paksoy CS. Assessment of buccal marginal alveolar peri-implant and periodontal defects using a cone beam CT system with and without the application of metal artefact reduction mode. *Dentomaxillofac Radiol* 2013; 42: 20130176.
29. Kavarella A, Karayiannis A, Nicopoulou-Karayianni K. Detectability of experimental peri-implant cancellous bone lesions using conventional and direct digital radiography. *Aust Dent J* 2006; 51: 180-6.
30. Kim JH, Abdala-Júnior R, Munhoz L, Cortes AR, Watanabe PC, Costa C, et al. Comparison between different cone-beam computed tomography devices in the detection of mechanically simulated peri-implant bone defects. *Imaging Sci Dent* 2020; 50: 133-9.
31. Kühl S, Zürcher S, Zitzmann NU, Filippi A, Payer M, Dagassan-Berndt D. Detection of peri-implant bone defects with different radiographic techniques - a human cadaver study. *Clin Oral Implants Res* 2016; 27: 529-34.
32. Naje AR, Drobie BF, Falah A. A comparison of cone beam computed tomography and panoramic radiography in the detection of mechanical created peri-implant bone defects. *J Res Med Dent Sci* 2019; 7: 222-5.
33. Pelekos G, Tse JM, Ho D, Tonetti MS. Defect morphology, bone thickness, exposure settings and examiner experience affect the diagnostic accuracy of standardized digital periapical radiographic images but not of cone beam computed tomography in the detection of peri-implant osseous defects: an in vitro study. *J Clin Periodontol* 2019; 46: 1294-302.
34. Pinheiro LR, Gaia BF, Oliveira de Sales MA, Umetsubo OS, Santos Junior O, Cavalcanti MG. Effect of field of view in the detection of chemically created peri-implant bone defects in bovine ribs using cone beam computed tomography: an in vitro study. *Oral Surg Oral Med Oral Pathol Oral Radiol* 2015; 120: 69-77.
35. Vadiati Saberi B, Khosravifard N, Ghandari F, Hadinezhad A. Detection of peri-implant bone defects using cone-beam computed tomography and digital periapical radiography with parallel and oblique projection. *Imaging Sci Dent* 2019; 49: 265-72.
36. Schriber M, Yeung AW, Suter VG, Buser D, Leung YY, Bornstein MM. Cone beam computed tomography artefacts around dental implants with different materials influencing the detection of peri-implant bone defects. *Clin Oral Implants Res* 2020; 31: 595-606.
37. Sewerin IP, Gotfredsen K, Stoltze K. Accuracy of radiographic diagnosis of peri-implant radiolucencies - an in vitro experiment. *Clin Oral Implants Res* 1997; 8: 299-304.
38. Sirin Y, Horasan S, Yaman D, Basegmez C, Tanyel C, Aral A, et al. Detection of crestal radiolucencies around dental implants: an in vitro experimental study. *J Oral Maxillofac Surg* 2012; 70: 1540-50.
39. Vidor MM, Liedke GS, Vizzotto MB, da Silveira HL, da Silveira PF, Araujo CW, et al. Imaging evaluating of the implant/bone interface - an in vitro radiographic study. *Dentomaxillofac Radiol* 2017; 46: 20160296.
40. Vidor MM, Liedke GS, Fontana MP, da Silveira HL, Arus NA, Lemos A, et al. Is cone beam computed tomography accurate for postoperative evaluation of implants? An in vitro study. *Oral Surg Oral Med Oral Pathol Oral Radiol* 2017; 124: 500-5.
41. Dave M, Davies J, Wilson R, Palmer R. A comparison of cone beam computed tomography and conventional periapical radio-

- graphy at detecting peri-implant bone defects. *Clin Oral Implants Res* 2013; 24: 671-8.
42. de-Azevedo-Vaz SL, Peyneau PD, Ramirez-Sotelo LR, Vasconcelos Kde F, Campos PS, Haiter-Neto F. Efficacy of a cone beam computed tomography metal artifact reduction algorithm for the detection of peri-implant fenestrations and dehiscences. *Oral Surg Oral Med Oral Pathol Oral Radiol* 2016; 121: 550-6.
  43. Hilgenfeld T, Juerchott A, Deisenhofer UK, Krisam J, Rammelsberg P, Heiland S, et al. Accuracy of cone-beam computed tomography, dental magnetic resonance imaging, and intraoral radiography for detecting peri-implant bone defects at single zirconia implants - an in vitro study. *Clin Oral Implants Res* 2018; 29: 922-30.
  44. Higgins JP, Thompson SG, Deeks JJ, Altman DG. Measuring inconsistency in meta-analyses. *BMJ* 2003; 327: 557-60.
  45. Pieralli S, Kohal RJ, Lopez Hernandez E, Doerken S, Spies BC. Osseointegration of zirconia dental implants in animal investigations: a systematic review and meta-analysis. *Dent Mater* 2018; 34: 171-82.
  46. Sanz-Martín I, Sanz-Sánchez I, Carrillo de Albornoz A, Figueroa E, Sanz M. Effects of modified abutment characteristics on peri-implant soft tissue health: a systematic review and meta-analysis. *Clin Oral Implants Res* 2018; 29: 118-29.
  47. Bohner LO, Mukai E, Oderich E, Porporatti AL, Pacheco-Pereira C, Tortamano P, De Luca Canto G. Comparative analysis of imaging techniques for diagnostic accuracy of peri-implant bone defects: a meta-analysis. *Oral Surg Oral Med Oral Pathol Oral Radiol* 2017; 124: 432-40.e5.
  48. Pelekos G, Acharya A, Tonetti MS, Bornstein MM. Diagnostic performance of cone beam computed tomography in assessing peri-implant bone loss: a systematic review. *Clin Oral Implants Res* 2018; 29: 443-64.
  49. Monje A, Pons R, Insua A, Nart J, Wang HL, Schwarz F. Morphology and severity of peri-implantitis bone defects. *Clin Implant Dent Relat Res* 2019; 21: 635-43.
  50. Yeung AW, Azevedo B, Scarfe WC, Bornstein MM. Patient motion image artifacts can be minimized and re-exposure avoided by selective removal of a sequence of basis images from cone beam computed tomography data sets: a case series. *Oral Surg Oral Med Oral Pathol Oral Radiol* 2020; 129: e212-23.
  51. Tyndall DA, Price JB, Tetradis S, Ganz SD, Hildebolt C, Scarfe WC, et al. Position statement of the American Academy of Oral and Maxillofacial Radiology on selection criteria for the use of radiology in dental implantology with emphasis on cone beam computed tomography. *Oral Surg Oral Med Oral Pathol Oral Radiol* 2012; 113: 817-26.